

Observational Study

High-Resolution Three-Dimensional Computed Tomography for Assessing Complications Related to Intrathecal Drug Delivery

Matthias Morgalla, MD, PhD, Marcos Fortunato, MD, Ala Azam, BS,
Marcos Tatagiba, MD, PhD, and Guilherme Lepski, MD, PhD

From: ¹University of Tuebingen, University Hospital, Dept. of Neurosurgery, Tuebingen, Germany

Address Correspondence:
Matthias Morgalla, MD, PhD
University of Tuebingen
Dept. of Neurosurgery
Hoppe-Seyler – Str. 3
Tuebingen, Germany
E-mail:
matthias.morgalla@gmail.com

Disclaimer: There was no external funding in the preparation of this manuscript.
Conflict of interest: Each author certifies that he or she, or a member of his or her immediate family, has no commercial association (i.e., consultancies, stock ownership, equity interest, patent/licensing arrangements, etc.) that might pose a conflict of interest in connection with the submitted manuscript.

Manuscript received: 03-12-2016
Revised manuscript received: 07-18-2015
Accepted for publication: 01-04-2016

Free full manuscript:
www.painphysicianjournal.com

Background: The assessment of the functionality of intrathecal drug delivery (IDD) systems remains difficult and time-consuming. Catheter-related problems are still very common, and sometimes difficult to diagnose.

Objectives: The aim of the present study is to investigate the accuracy of high-resolution three-dimensional computed tomography (CT) in order to detect catheter-related pump dysfunction.

Study Design: An observational, retrospective investigation.

Setting: Academic medical center in Germany.

Methods: We used high-resolution three dimensional (3D) computed tomography with volume rendering technique (VRT) or fluoroscopy and conventional axial-CT to assess IDD-related complications in 51 patients from our institution who had IDD systems implanted for the treatment of chronic pain or spasticity.

Results: Twelve patients (23.5%) presented a total of 22 complications. The main type of complication in our series was catheter-related (50%), followed by pump failure, infection, and inappropriate refilling. Fluoroscopy and conventional CT were used in 12 cases. High-resolution 3D CT VRT scan was used in 35 instances with suspected yet unclear complications.

Using 3D-CT (VRT) the sensitivity was 58.93% – 100% (CI 95%) and the specificity 87.54% – 100% (CI 95%). The positive predictive value was 58.93% – 100% (CI 95%) and the negative predictive value: 87.54% – 100% (CI 95%).

Fluoroscopy and axial CT as a combined diagnostic tool had a sensitivity of 8.3% – 91.7% (CI 95%) and a specificity of 62.9% – 100% (CI 95%). The positive predictive value was 19.29% – 100% (CI 95%) and the negative predictive value: 44.43% – 96.89% (CI 95%).

Limitations: This study is limited by its observational design and the small number of cases.

Conclusion: High-resolution 3D CT VRT is a non-invasive method that can identify IDD-related complications with more precision than axial CT and fluoroscopy.

Key words: Volume rendering technique (VRT), intrathecal drug delivery systems, high-resolution 3D computed tomography, complications, spasticity, chronic pain, cost effectiveness, fluoroscopy

Pain Physician 2016; 19:E775-E780

Intrathecal drug administration is considered efficacious for the treatment of severe spasticity and pain (1-4). Moreover, the cost-effective analysis favors the indication, despite higher costs in the implanted group (5).

In spite of the clinical efficacy, a high level of adverse events (AE) is reported during chronic intrathecal therapy (3-7). Indeed, adverse effects occur in 18% – 37% of the cases (1,2,4) and a monthly incidence rate of 0.023 has been reported (1). These complications may be procedure-related (wound dehiscence, infection, pump pocket hematoma, cerebrospinal fluid leakage), drug-related side effects, or device-related dysfunction (8-11). Among these, catheter-related problems are by far the most common (8.5% – 19%) (1). These include migration, disconnection, obstruction, strictures, kinks, micro-leaks, and false placement (12-15). Although several publications have addressed complications related to intrathecal therapy (16-18), a better diagnostic workflow is highly desirable. Indeed, many patients undergo surgical revision without a precise definition of the cause of the malfunction (19-21). Here, we investigated the role of computed tomography (CT) with the aid of three dimensional (3D) volumetric rendering techniques (VRT) for the diagnosis of catheter-related complications after pump implantation (22-24).

In this study, we describe our experience using this technique on a group of 51 patients from our institution.

METHODS

This retrospective observational study was conducted on patients treated between 2003 and 2013 at the Neurosurgical Clinic of the University Hospital of Tuebingen, Germany.

Inclusion Criteria

- Patients with a disorder of chronic pain or spasticity who had received an intrathecal drug delivery (IDD) system.
- Age > 18 years.

Exclusion Criteria

- Age < 18 years.

In all patients, an IDD system was implanted using a standardized surgical protocol. Data were retrospectively collected from electronic files, as well as from surgical and follow-up charts, to identify any IDD system-

related complications during the follow-up period. All patients were evaluated prior to surgery and the risks and benefits of IDD implantation were explained to the patients and their relatives or caregivers. The follow-up was performed only at our institution.

The implanted systems were purchased from different companies: Medtronic Synchronomed® II (n = 31), Tricumed® (n = 14), Medstream® Codman (n = 8), Medtronic Isomed® (n = 4), Infusaid® Fa. Bitzer (n = 2), and Archimed-Typ® (n = 1).

If we suspected a catheter-related problem such as a disconnection, kink, stricture, or catheter dislocation, we routinely performed an abdomen CT with VRT reconstruction (SOMATOM® Definition Flash Scanner, Siemens). First, the medication was aspirated from the catheter via the access port of the pump, and a contrast agent was injected prior to CT-scan acquisition of the abdomen. Next, the images were reconstructed using VRT. Specifically, we used maximum intensity projection (MIP), which is a data visualization method that enables the detection of structures that give off high intensity signals, probably suitable for visualization of IDD systems (23-24). With MIP, the pump and the associated catheter were visualized continuously in a 3D fashion. Additionally, a perception of rotation was created in order to permit pump visualization from different angles.

Pain patients were predominantly implanted with non-programmable Tricumed® pumps (Tricumed® Medizintechnik GmbH, Röntgenstr. 27, 24143 Kiel, Germany), whereas spastic patients needing baclofen mainly received programmable Synchronomed® II systems (Medtronic GmbH, Earl-Bakken-Platz 1, 40670 Meerbusch, Germany).

Statistics

The patients with suspected catheter-related complications were analyzed. Correct and false assessments regarding catheter-related complications using 3D-CT VRT or axial CT and fluoroscopy were examined. We calculated the sensitivity, specificity, and the positive predictive value of the 3D-CT and fluoroscopy.

RESULTS

We enrolled in this study 51 patients, 24 women (47%) and 27 men (53%). The median age was 54 years (18 – 78 years). The main indications for surgery were as follows: 28 patients for spastic disease (54.9%), 2 for generalized dystonia (3.9%), and 21 for chronic pain (41.2%). A total of 60 pumps were implanted, includ-

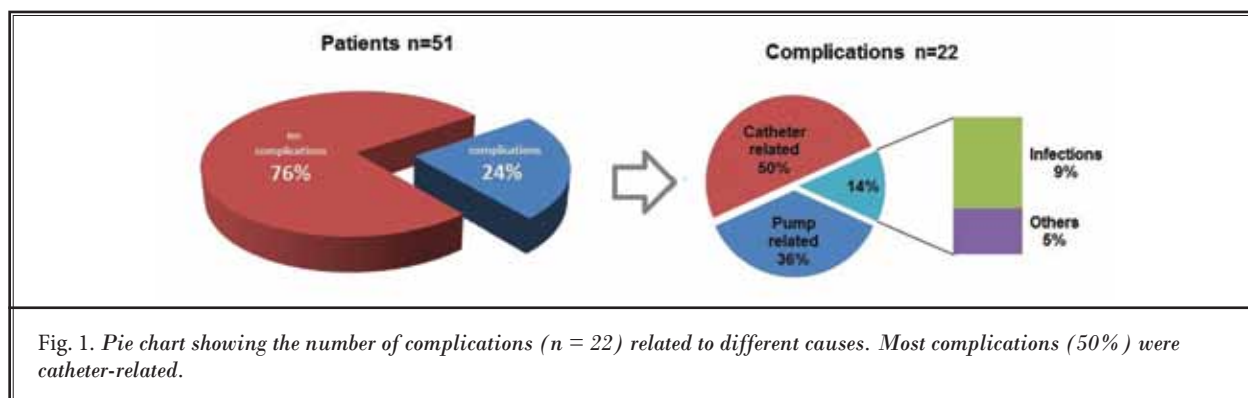


Fig. 1. Pie chart showing the number of complications ($n = 22$) related to different causes. Most complications (50%) were catheter-related.

ing those used in re-operations due to complications. Of those 60 pumps, 36 were used for baclofen delivery and 24 for morphine. We detected a total of 22 complications (Fig. 1), half of which were catheter-related. Among the catheter-related problems, one case (9.1%) was a pump disconnection, 3 were spinal catheter disconnections (27.3%), 3 were intrathecal catheter dislocations (27.3%), one was a minor catheter leak (9.1%), and 2 were strictures or obstruction of the catheter (18.2%).

Pump-related complications were found in 8 patients: in 2, the position of the pump had changed and needed to be revised; and in 6, we detected a pump malfunctioning based on a discrepancy between the expected and actual residual volume in the pump by the time of filling.

Two of the pumps were infected and in both cases, the whole system needed to be removed. In one case, the patient developed baclofen intoxication signs because of hyperdosage after revision. The patient was immediately readmitted and had an uneventful recovery after dosage adjustment.

We observed 4 complications among 36 programmable pumps and 4 dysfunctions with 24 non-programmable pumps.

We performed conventional x-rays in all cases with possible malfunction of the system. In 35 instances with suspected but uncertain complications after conventional diagnosis, high-resolution 3D CT VRT was used. In 7 of these cases, catheter-related problems were detected and needed further surgical treatment (Fig. 2A-C). In all cases, where the high-resolution 3D CT VRT scans revealed a cause for the dysfunction, the diagnosis was confirmed intra-operatively. In 28 cases in which high-resolution 3D CT VRT was used, no abnormalities were detected and surgical revision was avoided.

This method rendered a sensitivity of 58.93% –

100% (CI 95%) and a specificity of 87.54% – 100% (CI 95%). The positive predictive value was 58.93% – 100% (CI 95%) and the negative predictive value was 87.54% – 100% (CI 95%).

Fluoroscopy was used in 12 early cases when high-resolution 3D CT VRT was not available. However, we also included these cases of fluoroscopy in this series in order to show the improvement which has been achieved by using 3D CT imaging. In this group, 4 cases underwent revision, which confirmed catheter problems in 4 cases. With this technique, in only 2 cases was the underlying cause determined preoperatively (catheter disconnection).

Thus the sensitivity was 8.3% – 91.7% (CI 95%) and the specificity was 62.9% – 100% (CI 95%). The positive predictive value was 19.29% – 100% (CI 95%) and the negative predictive value was 44.43% – 96.89% (CI 95%).

Taken together, the investigation of IDD-malfunctioning with 3D CT VRT scans allowed higher sensitivity and specificity in comparison with the standard methods (conventional x-ray and fluoroscopy). With this strategy, even small catheter leaks, minimal kinking, or obstruction can be easily identified.

DISCUSSION

The evaluation of complications related to IDD systems is difficult, time-consuming, and dependent on ample clinical experience (12,13,25,26). Most patients complain of nonspecific symptoms such as increased pain or spasticity. Obvious signs such as a fluid collection around the pump or a swelling near the wound are less common. Plain x-rays may only reveal gross abnormalities and often do not allow the visualization of the catheter behind the pump. An ordinary axial CT of the abdomen can improve visualization somewhat, but a high-resolution 3D CT of the abdomen using VRT

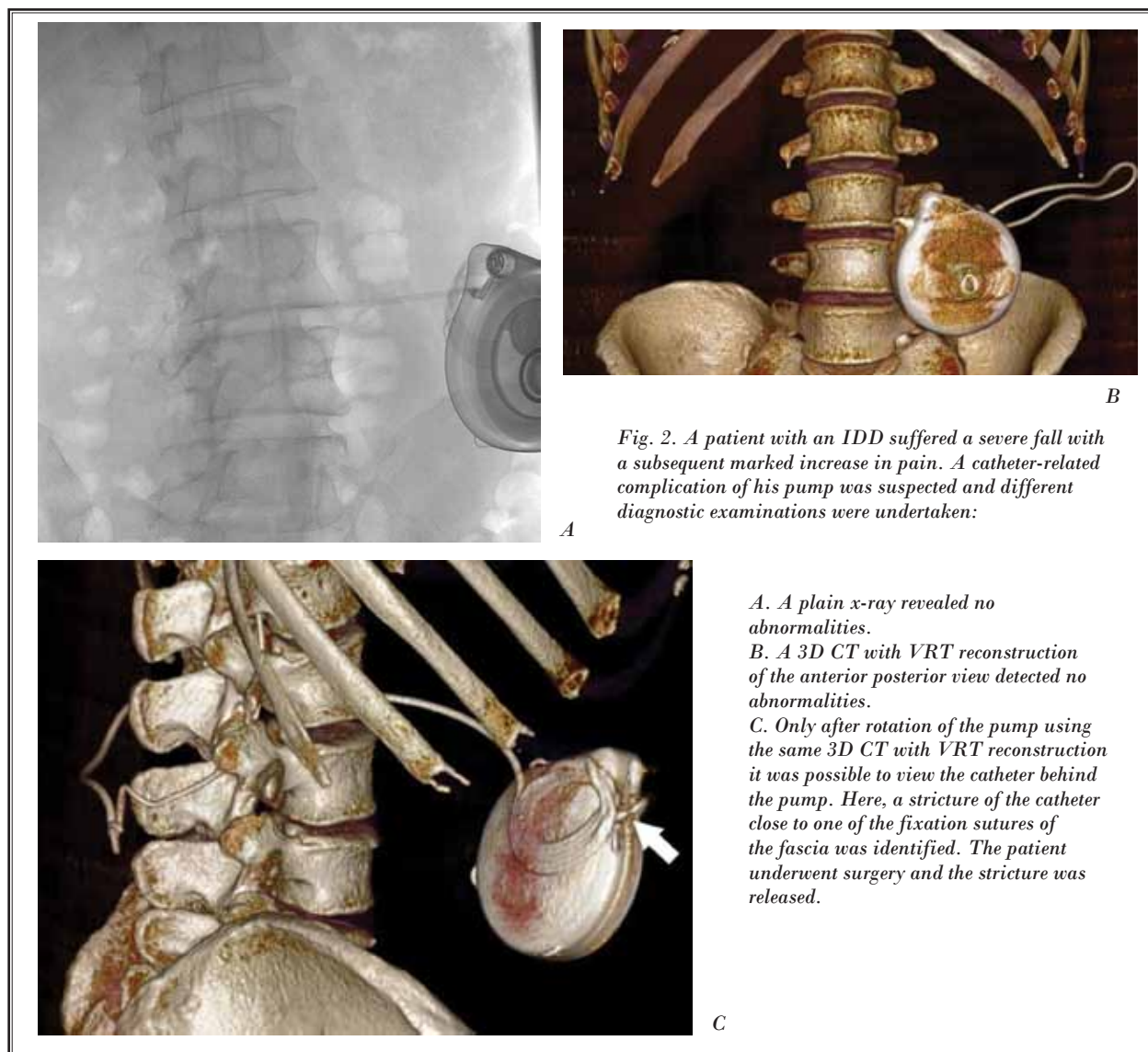


Fig. 2. A patient with an IDD suffered a severe fall with a subsequent marked increase in pain. A catheter-related complication of his pump was suspected and different diagnostic examinations were undertaken:

- A. A plain x-ray revealed no abnormalities.*
- B. A 3D CT with VRT reconstruction of the anterior posterior view detected no abnormalities.*
- C. Only after rotation of the pump using the same 3D CT with VRT reconstruction it was possible to view the catheter behind the pump. Here, a stricture of the catheter close to one of the fixation sutures of the fascia was identified. The patient underwent surgery and the stricture was released.*

reconstruction provides visualization of the full length of the catheter at crucial locations: the connection at the pump, the area behind the pump, the connection of the catheter at the spine, as well as its intrathecal course. This technique can be performed quickly on an outpatient basis. CT offers different VRTs, such as MIP, minimum intensity projection (MinIP), shaded surface display (SSDP), and virtual endoscopy (VE). Multidetector computed tomography (MDCT) has continued to advance since its introduction in 1998, when the first 4 slice CT scanners capable of MDCT became available for clinical use (23). One of the features of MDCT is its ability to produce reliable multiplanar and 3D reconstruc-

tions, which permit the visualization of specific details that are difficult to evaluate using axial reconstructions alone, such as implanted drug delivery pumps and their associated catheters.

In the beginning we used multiplanar imaging (coronal, sagittal, and axial reconstructions). But now we hardly use these reconstructions any more. High resolution surface rendered 3D CT using VRT has the advantage to view the pump and its catheters as a whole in different rotational projections. Other tissues than bone are not visualized. We think that possible problems regarding the catheters can be identified thoroughly that way. VRT reconstructions are current-

ly not yet a routine method in most of the imaging departments.

In the literature, there is only one case report describing the utility of this method for identification of a small leak (14). Here, we strengthen the value of this technique for the diagnosis of pump dysfunctions when simple diagnostic tests fail to demonstrate the underlying cause.

Usually, potential complications fit into 3 main categories: device-related complications, surgical complications, and pharmacological side effects (27). In their case series, Gooch et al (28) reported that the main complication was catheter disconnection, which occurred in 9% of patients, followed by catheter dislodgement from the intrathecal space in 8%. In a recent review of 158 patients (1), AEs occurred in 18% of the patients, at a rate of 0.023 per month. Of these, 53% were related to the procedure (wound dehiscence or infection, pocket hematoma, etc.), and 19% related to the device itself. Finally, 18% of the AEs were related to the medication. In another recent series from 2013 (2), including 400 patients followed up for up to one year, AEs were documented in 37% of the patients. Among these, catheter-related problems represented the major cause, accounting for 8.5% of the cases (these included migration in 6.3%, breakage in 1.5%, obstruction in 0.5%, kinking in 0.3%, dislodgement in 0.3%, pump failure in 0.3%, malfunction in 0.9%, infection in 3%, and leakage in 3.3%). Provided we suspect a catheter-related granuloma, high resolution 3D CT will also show the pathology. However, on CT the spinal cord and possible changes caused by the granuloma cannot be visualized as well as by magnetic resonance imaging (MRI). Therefore, in the case of a granuloma, we would still perform a MRI in order to identify possible injuries to the neural structures more clearly.

Our data suggest that high-resolution 3D CT VRT seems to be superior to the current standard di-

agnostic techniques for diagnosing catheter-related complications.

However, our study is an observational study. It lacks the direct comparison of fluoroscopy and 3D-CT on the same patient. The number of comparable complications is also small in order to perform statistical comparisons between the different methods. Therefore, prospective studies which address these needs are still necessary.

In an interesting study of cost effectiveness of intrathecal therapy for spasticity in children, de Lissovoy et al (5) calculated US\$ 49,000,00 higher costs in the implanted group, as compared with conservative treatment. Nevertheless, they estimated an average gain of 1.2 quality-adjusted life-years, which supports an overall good use for the money. Undoubtedly, one of the cost components is the need for surgical revisions and hospitalizations due to malfunctioning of the system. In this sense, it seems of central importance to define an optimal diagnostic workflow in order to reduce the time of the hospitalization and unnecessary surgical interventions in patients with the suspicion of a malfunctioning IDD. In our series, surgery was avoided in 28 out of 35 patients after investigation with 3D CT. This approach may represent an important economical advantage for the health system.

CONCLUSION

The evaluation of complications associated with the use of IDD systems remains challenging. High-resolution 3D CT VRT improves the identification of catheter-related complications. Slow catheter leaks can also be located more accurately using this technique than with fluoroscopy. Therefore, we recommend high-resolution 3D CT VRT as a first line examination method whenever catheter-related IDD system complications are suspected.

REFERENCES

- Borrini L, Bensmail D, Thiebaut JB, Hugeron C, Rech C, Jourdan C. Occurrence of adverse events in long-term intrathecal baclofen infusion: A 1-year follow-up study of 158 adults. *Arch Phys Med Rehabil* 2014; 95:1032-1038.
- Taira T, Ueta T, Katayama Y, Kimizuka M, Nemoto A, Mizusawa H, Liu M, Koito M, Hiro Y, Tanabe H. Rate of complications among the recipients of intrathecal baclofen pump in Japan: A multicenter study. *Neuromodulation* 2013; 16:266-272; discussion 272.
- Koulousakis A, Kuchta J. Intrathecal antispastic drug application with implantable pumps: Results of a 10 year follow-up study. *Acta Neurochir Suppl* 2007; 97:181-184.
- Guillaume D, Van Havenbergh A, Vloeberghs M, Vidal J, Roeste G. A clinical study of intrathecal baclofen using a programmable pump for intractable spasticity. *Arch Phys Med Rehabil* 2005; 86:2165-2171.
- de Lissovoy G, Matza LS, Green H, Werner M, Edgar T. Cost-effectiveness of intrathecal baclofen therapy for the treatment of severe spasticity associated with cerebral palsy. *J Child Neurol* 2007; 22:49-59.

6. Ghosh D, Mainali G, Khera J, Luciano M. Complications of intrathecal baclofen pumps in children: Experience from a tertiary care center. *Pediatr Neurosurg* 2014; 49:138-144.
7. Motta F, Antonello CE. Analysis of complications in 430 consecutive pediatric patients treated with intrathecal baclofen therapy: 14-year experience. *J Neurosurg Pediatr* 2014; 13:301-306.
8. Hoarau X, Richer E, Dehail P, Cuny E. A 10-year follow-up study of patients with severe traumatic brain injury and dysautonomia treated with intrathecal baclofen therapy. *Brain Inj* 2012; 26:927-940.
9. Vender JR, Hester S, Waller JL, Reki-to A, Lee MR. Identification and management of intrathecal baclofen pump complications: A comparison of pediatric and adult patients. *J Neurosurg* 2006; 104:9-15.
10. Falco FJ, Patel VB, Hayek SM, Deer TR, Geffert S, Zhu J, Onyewu O, Coubarous S, Smith HS, Manchikanti L. Intrathecal infusion systems for long term management of chronic non-cancer pain: An update of assessment of evidence. *Pain Physician* 2013; 16:SE185-SE216.
11. Kumar K, Kelly M, Pirlot T. Continuous intrathecal morphine treatment for chronic pain of nonmalignant etiology: Long-term benefits and efficacy. *Surg Neurol* 2001; 55:79-86.
12. Varhabhatla NC, Zuo Z. Rising complication rates after intrathecal catheter and pump placement in the pediatric population: Analysis of national data between 1997 and 2006. *Pain Physician* 2012; 15:65-74.
13. Coffrey RJ, Owens ML, Broste SK, Dubois MY, Ferrante FM, Schultz DM, Stearns LJ, Turner MS. Medical practice perspective: Identification and mitigation of risk factors for mortality associated with intrathecal opioids for non-cancer pain. *Pain Med* 2010; 11:1001-1009.
14. Ellis JA, Leung R, Winfree CJ. Spinal infusion pump-catheter leak detected by high-resolution 3D computed tomography. *J Neurosurg Spine* 2011; 15:555-557.
15. Prager J, Deer T, Levy R, Bruel B, Buchser E, Caraway D, Cousins M, Jacobs M, McGlothlen G, Rauck R, Staats P, Stearns L. Best practices for intrathecal drug delivery for pain. *Neuromodulation* 2014; 17:354-372.
16. Azouvi P, Mane M, Thiebaut JB, Denys P, Remy-Neris O, Bussel B. Intrathecal baclofen administration for control of severe spinal spasticity: Functional improvement and long-term follow-up. *Arch Phys Med Rehabil* 1996; 77:35-39.
17. Plassat R, Perrouin Verbe B, Menei P, Menegalli D, Mathé JF, Richard I. Treatment of spasticity with intrathecal baclofen administration: Long-term follow-up, review of 40 patients. *Spinal Cord* 2004; 42:686-693.
18. Ben Smail D, Peskine A, Roche N, Mailhan L, Thiébaud I, Bussel B. Intrathecal baclofen for treatment of spasticity of multiple sclerosis patients. *Mult Scler* 2006; 12:101-103.
19. Zdolsek HA, Olesch C, Antolovich G, Reddihough D. Intrathecal baclofen therapy: Benefits and complications. *J Intellect Dev Disabil* 2011; 36:207-213.
20. Haranhalli N, Anand D, Wisoff JH, Harter DH, Weiner HL, Blate M, Roth J. Intrathecal baclofen therapy: Complication avoidance and management. *Childs Nerv Syst* 2011; 27:421-427.
21. Stetkarova I, Yablon SA, Kofler M, Stokic DS. Procedure- and device related complications of intrathecal baclofen administration for management of adult muscle hypertonia: A review. *Neurorehabil Neural Repair* 2010; 24:609-619.
22. Deer TR, Levy R, Prager J, Buchser E, Burton A, Caraway D, Cousins M, De Andrés J, Diwan S, Erdek M, Grigsby E, Huntoon M, Jacobs MS, Kim P, Kumar K, Leong M, Liem L, McDowell GC II, Panchal S, Rauch R, Saulino M, Sitzman BT, Staats P, Stanton-Hicks M, Stearns L, Wallace M, Willis KD, Witt W, Yaksh T, Mekhail N. Polyanalgesic Consensus Conference—2012: Recommendations to reduce morbidity and mortality in intrathecal drug delivery in the treatment of chronic pain. *Neuromodulation* 2012; 15:467-482.
23. Shin JH, Lee HK, Choi CG, Suh DC, Lim TH, Kang W. The quality of reconstructed 3D images in multidetector-row helical CT: Experimental study involving scan parameters. *Korean J Radiol* 2002; 3:49-56.
24. Salgado R, Mulkens T, Bellinck P, Termote JL. Volume rendering in clinical practice. A pictorial review. *JBR-BTR* 2003; 86:215-220.
25. Peen RD, Corcos DM. Management of spasticity by central nervous system infusion techniques. In: Quiñones-Hinojosa A (ed). *Schmidke and Sweet: Operative Neurosurgical Techniques: Indications, Methods and Results*. Elsevier, Philadelphia, 2012, pp 1038-1048.
26. Awaad Y, Rizk T, Siddiqui I, Roosen N, McIntosh K, Waines GM. Complications of intrathecal baclofen pump: Prevention and cure. *ISRN Neurol* 2012; 2012:575168.
27. Turner JA, Sears JM, Loeser JD. Programmable intrathecal opioid delivery systems for chronic noncancer pain: A systematic review of effectiveness and complications. *Clin J Pain* 2007; 23:180-195.
28. Gooch JL, Oberg WA, Grams B, Ward LA, Walker ML. Complications of intrathecal pumps in children. *Pediatr Neurosurg* 2003; 39:1-6.