

Original Article

Spinal Endoscopy and Lysis of Epidural Adhesions in the Management of Chronic Low Back Pain

Laxmaiah Manchikanti, MD*, Bhupinder Saini, MD**, and Vijay Singh, MD#

Spinal endoscopy with epidural adhesiolysis is an interventional pain management technique which emerged during the 1990s. It is an invasive but important treatment modality in managing chronic low back pain that is nonresponsive to other modalities of treatment, including percutaneous spring guided adhesiolysis and transforaminal epidural injections. While epidural adhesions most commonly result following surgical intervention of the spine, leakage of disc material into the epidural space following an annular tear, or an inflammatory response can also result in their formation. Even though advanced technology, including computerized tomography and magnetic resonance imaging,

have made significant advances in the diagnosis of epidural fibrosis, it is believed that epidural adhesions resulting in chronic persistent pain are poorly managed.

Percutaneous endoscopic lysis of epidural scar tissue has been shown to be cost effective and a safe modality. This review discusses various aspects of endoscopic adhesiolysis, including clinical effectiveness, complications, rationale, and indications.

Keywords: Epidural fibrosis, endoscopic lysis of epidural adhesions, chronic low back pain, spinal endoscopy

Interventional techniques in the management of low back pain, including spinal endoscopy and epidural adhesiolysis, continue to be some of the most contentious modalities, along with surgical interventions and other modalities (1-6). Among all the chronic painful conditions, low back pain is the most common, burdening approximately 15% to 39% of the population with serious financial and social consequences (7-18). Apparently, low back pain ranks first among musculoskeletal disorders (7). Even though it is widely believed that most episodes of low back pain are short-lived and that 90% of patients recover in about 6 weeks (12), multiple studies (10, 11, 15, 16) have shown evidence to the contrary. It has been shown that as many as 79% of patients continue to suffer with chronic or recurrent low back pain at 12 months.

While disorders of the disc and joints play a major role in causation of low back pain, failed low back surgery syn-

drome, also known as failed management syndrome or postlumbar laminectomy syndrome, is a growing entity in modern medicine, with an estimated 5% to 40% of lumbar surgeries resulting in failed back surgery syndrome; staggering statistics show failure rates reaching as high as 68% (3-6, 19-103). Though these often result from surgery that was inadequate, incorrect, or unnecessary, this syndrome also results following a well-indicated and well-performed surgical intervention.

Endoscopic adhesiolysis is based on the premise that the epidural space can be accessed safely by using flexible fiberoptic catheters entering via the sacral hiatus. It facilitates three-dimensional visualization of the contents of the epidural space and provides the operator with the ability to steer the catheter toward structures of interest. This procedure allows examination of a specific nerve root and its pathology and treatment by injection of a drug directly in the root, along with the ability to expand the epidural space with normal saline.

HISTORICAL CONSIDERATIONS

Epidural injection for chronic low back pain was performed by Pasquier and Leri in 1901 (104). Eight years later, reports on cures of sciatica with epidural anesthesia were made by Caussade and Queste (105). The initial epidurography was performed in 1921 by Sicard and Forestier (106). Cyriax (107) reported his extensive experi-

From Pain Management Center of Paducah, Paducah, Kentucky; Advanced Pain Management, Milwaukee, Wisconsin; and Pain Diagnostic Associates, Niagara, Wisconsin. *Dr. Manchikanti is Medical Director of Pain Management Center of Paducah, **Dr. Saini is Medical Director of Advanced Pain Management, and #Dr. Singh is Medical Director of Pain Diagnostic Associates. Address correspondence: Laxmaiah Manchikanti, MD, 2831 Lone Oak Road, Paducah, Kentucky 42003. E-mail: drm@asipp.org

Table 1. *Historical evolution of spinal endoscopy*

◆	1931 Burman	-	Direct visualization of spinal canal
◆	1936 Stern	-	Described a spinascope for in vivo examination of spinal canal
◆	1937 Pool	-	First examination with myeloscope
◆	1942 Pool	-	Used diagnostically in preparation for surgery
◆	1967 to 1997 Ooi et al	-	Developed endoscope in 1960s
		-	Miniaturized with advent of fiberoptic light source in 1970s
◆	1981 Ooi et al	-	Published changes in the cauda equina during Laseque’s test
◆	1985 Blomberg	-	Epidural space contents varied in regard to fat and connective tissue
◆	1989 Blomberg and Olson	-	10 epiduroscopies on patients scheduled for partial laminectomies
◆	1990s Heavner et al	-	Endoscopic evaluation of epidural and subarachnoid spaces in animals and cadavers
◆	1991 Shimoji et al	-	0.5- to 1.4-mm flexible fiberoptic scopes
◆	1991 Saberski and Kitahata-	-	Started evaluations of several fiberoptic systems
◆	1996 Saberski and Kitahata-	-	Review of clinical basis
◆	1999 Manchikanti et al	-	Endoscopy in postlumbar laminectomy
◆	2000 Manchikanti et al	-	Safety of endoscopic adhesiolysis
◆	2001 Richardson et al	-	Prospective case series

ence with 20,000 patients who showed significant improvement with large volumes of caudal epidural anesthetic. Brown (108) also injected large volumes ranging from 40 to 100 mL of normal saline, followed by the injection of 80 mg of methylprednisolone in an attempt to mechanically disrupt and prevent preformation of presumably fibrotic lesions in patients with sciatica. Over the years, various authors (109-118) have studied the effectiveness of percutaneous adhesiolysis facilitated by a spring guided catheter. Development of endoscopic adhesiolysis added another dimension to percutaneous adhesiolysis, with three-dimensional visualization of epidural contents (119, 120).

A review of the medical literature indicates that clinicians have been working with various types of endoscopes for over 60 years, with varying degrees of success (119). Integration of fiberoptic technology with computer-enhanced imaging provided a new medium for viewing the CNS (120). The possibility of direct visualization of the spinal canal and its contents first surfaced in 1931 based on the pioneering work of Burman (121); however, until the advent of flexible fiberoptic light sources and optics (122), direct visualization of spinal contents could not be achieved. Burman (121) concluded that myeloscopy was limited by the

available technology, but that with higher quality instrumentation, a better postmortem examination of the cauda equina could be performed in situ. He felt that the ability to visualize the contents of the spinal canal might be especially important in establishing a diagnosis of tumor or inflammation. Stern (123), in 1936, described a spinascope, which was specifically designed for the in vivo examination of the spinal canal contents during spinal anesthesia. Stern (123) predicted that this technology could obviate the necessity for extensive exploratory laminotomies, even though the instrument was never used clinically.

Pool (124), in 1937, attempted to improve the preoperative diagnostic assessment of lumbar-sciatic syndrome by examining an anesthetized patient. However, only a fleeting glimpse of the lumbosacral nerve roots was possible due to hemorrhage which obscured the field of vision. In subsequent evaluations, seven volunteer patients without complications were examined (125, 126). In these evaluations, the cauda equina and blood vessels, and blood flow through epidural vessels were first visualized and reported (125, 126). Pool (125, 126) published a summary of his experience with 400 patients with endoscopic evaluation, used to identify neuritis, herniated nucleus pulposus, hypertrophied ligamentum flavum, primary and metastatic

neoplasms, varicose vessels, and arachnoid adhesions. Despite his successes and the relative ease of performing such examinations, no further reports of this technique appeared in the literature until 1967.

In the late 1960s and 1970s, Ooi et al (127-131) developed an endoscope for intradural and extradural examinations, which was miniaturized enough to be inserted between lumbar spinous processes. Ooi et al (132-134) performed 208 myeloscopies using various types of equipment from 1967 to 1977, with publication of their technique of myeloscopy and cauda equina blood flow changes during Lasègue’s test in 1981. Ooi et al (135), however, reported that abdominal straining, coughing and sneezing did not alter the blood flow; it only caused mild movements of the cauda equina in the lateral position.

Blomberg (136) was the next to describe a method of epiduroscopy and spinaloscopy in 1985, studying the anatomical variations of the epidural space and the appropriate delivery of epidural anesthetics. Blomberg (136) reported the wide variation of the contents of the epidural space. He reported that epidural adhesions between the dura mater and the ligamentum flavum restricted the opening of the epidural space. Blomberg and Olsson (137), in 1989, reported experience with 10 epiduroscopies of patients scheduled for partial laminectomies for herniated lumbar discs. Following the experience of endoscopy in live patients, Blomberg (138) felt that the conclusions drawn from previous autopsy work were not necessarily applicable to the clinical setting. He determined that the epidural space was indeed only a potential space that remained open for brief periods of time when fluid or air was injected. Blomberg (138) also confirmed the presence of a dorsomedian connective tissue band that divided the epidural space into compartments. Blomberg (138), in addition, determined that the midline approach to the epidural space was often associated with bleeding and that a paramedian approach was less likely to cause this complication.

In 1991, Saberski and Kitahata began evaluations of several fiberoptic systems for use in clinical epiduroscopy (119, 120). Heavner et al (139, 140) in the early 1990s reported endoscopic evaluation of the epidural and subarachnoid spaces in rabbits, dogs and human cadavers, with the aid of a flexible endoscope. Since then multiple publications (141-150) have described various aspects of spinal endoscopy, including clinical basis, safety, and cost effectiveness. Table 1 illustrates the historical evolution of spinal endoscopy.

ENDOSCOPIC ADHESIOLYSIS

Since the introduction of epidural corticosteroids, it has always been the objective of pain specialists to deliver them close to the site of pathology, presumably onto an inflamed nerve root (1). For many reasons, this objective has been hindered in caudal as well as interlaminar delivery of epidural corticosteroids (10). Consequently, the reports of effectiveness of epidural corticosteroids have shown a wide disparity, ranging from 18% to 90% effectiveness (1).

The purpose of endoscopic epidural lysis of adhesions is to directly visualize the contents of the epidural space, lyse the adhesions and eliminate deleterious effects of scar and direct application of drug, thus assuring delivery of high concentrations of injected drugs to the target areas. Thus, spinal endoscopy with lysis of adhesions incorporates multiple therapeutic goals into one treatment, similar to percutaneous lysis of adhesions with a spring guided catheter, with added advantages of direct visualization of the epidural space and its contents, a three-dimensional view, and increased steerability of endoscopic equipment with a fiberoptic catheter.

Epidural endoscopy is gaining popularity as a minimally invasive technique for adhesiolysis and accurate placement of injectate intended for delivery in the epidural space. However, similar to the many therapeutic interventions already available for the treatment of chronic low back pain, including surgery, drugs, manipulation, physical therapy, behavioral therapy, and neural blockade, the effectiveness of spinal endoscopy has not been demonstrated conclusively (1). Nomenclature used to describe spinal endoscopy is summarized Table 2.

Table 2. *Nomenclature utilized in description of spinal endoscopy*

◆	Spinal endoscopy
◆	Spinal canal endoscopy
◆	Spinal epiduroscopy
◆	Lumbar epiduroscopy
◆	Myeloscopy
◆	Spinal epidural endoscopy
◆	Endoscopic adhesiolysis
◆	Endoscopic epidural neuroplasty
◆	Endoscopic epidural adhesiolysis

PATHOPHYSIOLOGY

Epidural fibrosis is a progressive disease. It is an inflammatory reaction of the arachnoid, a fine nonvascular and elastic tissue enveloping the CNS (103). There are many possible etiologies of epidural fibrosis, including an anular tear, hematoma, infection, surgical trauma, or intrathecal contrast media. LaRocca and McNab (151) have demonstrated the invasion of fibrous connective tissue into the postoperative hematoma as a cause of epidural fibrosis. McCarron et al (152) investigated the irritative effect of material from the nucleus pulposus upon the dural sac, adjacent nerve roots, and nerve root sleeves independent of the influence of direct compression upon these structures. McCarron (153) further explored epidural fibrosis in an experimental model in adult mongrel dogs. He reported an inflammatory reaction in the spinal cord sections taken from dogs sacrificed after an initial injection of homogenized nucleus pulposus, whereas the spinal cord was grossly normal after an initial injection of normal saline.

Postlaminectomy syndrome, or pain following surgical procedures, including laminectomy, fusion and microsurgical procedures on the lumbar spine, is a common entity in modern medicine (3-6, 19-103). Even though the exact incidence and prevalence of postlumbar laminectomy syndrome is not known, it is estimated to be occasionally as high as 68%.

The recurrence of back or sciatic pain after lumbar surgery may be secondary to a multitude of causes. Various causes for continued pain after lumbar surgery leading to failed back surgery syndrome are epidural fibrosis, true recurrent disc herniation, new disc herniation at a different level, local arachnoiditis, facet joint arthritis, secondary spinal stenosis, instability, and spondylitis or spondylodiscitis (65, 154-156). Therefore, epidural fibrosis is a major cause of continued pain following surgical intervention, if not surgical failure. Recurrent disc herniation and new disc herniation at a different disc are considered as major causes of surgical failure. Even though epidural fibrosis is seen as a common phenomenon which contributes to almost 60% of cases of recurring symptoms in conjunction with instability in postlumbar surgery syndrome, the role of epidural fibrosis as a causative factor of chronic pain or a pain generator has been questioned (103, 153, 157-161). In spite of the debate, whether epidural fibrosis causes pain or not, it is widely accepted that postoperative scar tissue renders the nerve susceptible to injury (162).

Ross et al (21), in a study of the relationship between peri-

dural scar evaluated by magnetic resonance imaging and radicular pain after lumbar discectomy, showed that subjects with extensive peridural scarring were 3.2 times more likely to experience recurrent radicular pain. Parke and Watanabe (23) analyzed the frequency and location of lumbar dural adhesions in cadavers with lumbar disc herniation, showing significant evidence of adhesions in 40% at L4/5 levels, in 36% at L5/S1 levels, and in 16% at L3/4 levels. Berger and Davis (41) showed that, in a group of 600 patients with a single operation, periradicular fibrosis was diagnosed preoperatively in 0.67% and postoperatively in 11%. They also showed that, in 400 patients with multiple operations, at the time of the second operation, the incidence of periradicular fibrosis had risen to 47%. However, epidural adhesions have also been seen without surgery. Leakage of the irritants of the nucleus pulposus into the epidural space has been documented to cause an inflammatory response, resulting in an increase in fibrocytic deposition, which results in epidural fibrosis (23, 109, 110, 118, 152, 153, 157, 162-164).

Numerous authors (109, 110, 118, 152, 153, 163-196) have identified the likely role of chemical irritation of the nerve root by the nucleus pulposus. In 1934, Mixter and Barr (197) demonstrated that a herniated disc could cause nerve root encroachment, ultimately producing back pain. Soon after that it was noticed that the removal of the disc did not always result in pain relief (198). In 1951, Barr (199) reported that a patient may have persistent low back pain, sciatica, or both, in spite of surgical intervention. Mixter and Ayers (200) also reported, soon after their discovery of neurocompressive lesion, that low back and leg pain may occur without disc herniation and normal appearance of a disc. Thus, the concept of noncompressive lesion and irritation of the nerve root, as well as the definition of failed back surgery syndrome or postlumbar laminectomy syndrome with persistent or recurring low back pain, with or without radiculitis following one or more lumbar operations, evolved. Various proposed mechanisms for radicular pain include axonal damage, neuroma formation, focal demyelination, intraneural edema, impaired microcirculation, epidural fibrosis and nerve damage. Evidence for the inflammatory mechanism, though, continues to emerge and is convincing.

Epidural fibrosis or arachnoiditis was a relatively rare entity prior to the introduction of lumbar spine surgery for degenerative conditions. Prior to 1935, the condition of chronic adhesional arachnoiditis was generally described as chronic spinal meningitis (157). A multitude of reports in which epidural fibrosis was found at repeat surgery ap-

parently led to the speculation of the association of recurrent symptomatology with perineural scarring (157, 167, 201). While the causes of prevalence of failed back syndrome, including epidural scarring, arachnoiditis and mechanical instability, are not accurately known, the prevalence of recurrent disc herniation and facet joint pain in postlumbar laminectomy syndrome was shown to be 5% to 11% (58) and 32%, (202) consecutively.

Kuslich et al (203) concluded that the presence of scar tissue compounded pain associated with the nerve root by fixing it in one position and thus increasing the susceptibility of the nerve root to tension or compression. They also concluded that sciatica can only be reproduced by direct pressure or stretch on the inflammatory, stretched, or compressive nerve root. Even though considerable debate exists as to whether epidural fibrosis causes pain, it is widely accepted that postoperative scar tissue renders the nerves susceptible to injury (162). Scar tissue is generally found in the three compartments of the epidural space. Dorsal epidural scar tissue is formed by resorption of surgical hematoma and may be involved in pain generation (204). In the ventral epidural space, dense scar tissue is formed by ventral defects in the disc, which may persist despite surgical treatment and continue to produce either chronic low back or lower extremity pain after the surgical healing phase (103). Finally, the lateral epidural space includes epiradicular structures out of the root canals, termed *sleeves*, containing the exiting nerve root and dorsal root ganglia, susceptible to lateral disc defects, facet overgrowth and neuroforaminal stenosis, etc., (205). Thus, it is postulated that various changes producing low back pain and lower extremity pain include inflammation, edema, fibrosis, venous congestion, mechanical pressure on the posterior longitudinal ligament, reduced or absent nutrient delivery to the spinal nerve or nerve root, and central sensitization. It is well known that inflammation may render nociceptors more sensitive to mechanical stimuli (206).

It has been stated that epidural adhesions are not readily diagnosed by conventional studies such as myelography, computerized tomography, and MRI; even though modern technology has made significant improvements in this area (1, 109, 110-118, 164, 206-210). It is believed that epidural adhesions are best diagnosed by performing an epidurogram, which is most commonly performed via the caudal route, followed by the other routes, including the lumbar interlaminar route (110-118, 206-210). Epidural filling defects have also been seen in a significant number of patients with no history of prior surgery (164).

While peridural scarring in itself is not painful, it can produce pain by “trapping” spinal nerves so that movement places tension on the nerves, thus eliciting pain in an inflamed nerve (112, 115, 203). Kuslich et al (203) reported that back pain was produced by stimulation of several lumbar tissues. However, the outer layer of the anulus fibrosus and posterior longitudinal ligament innervated by synovial vertebral nerves were the most common tissues of origin (112).

RATIONALE

The rationale for spinal endoscopy and adhesiolysis in the management of chronic, resistant spinal pain stems from the fact that epidural adhesions are a common source of chronic low back pain. The epidural space restricted by adhesions is safely accessible to a fiberoptic endoscope. Removal or correction of structural abnormalities of the lumbar spine may fail to cure and may even worsen painful conditions; degenerative processes of the lumbar spine and the origin of spinal pain are complex; the effectiveness of a large variety of therapeutic interventions in managing low back pain has not been demonstrated conclusively; the reasonable effectiveness of percutaneous adhesiolysis with spring guided catheter has been demonstrated (1); and spinal endoscopy and therapeutic application of drugs in selected cases have been shown to be clinically effective and safe.

Racz et al (115) rationalized percutaneous lysis of epidural adhesions on the basis that inflammation, edema, fibrosis, and venous congestion; mechanical pressure on posterior longitudinal ligaments, annulus fibrosus, and spinal nerve; reduced or absent nutrient delivery to the spinal nerve or nerve root; and central sensitization may be present in patients with chronic back pain and/or radiculopathy. Hence, it is reasonable to treat back pain with or without radiculopathy with local application of anti-inflammatory medication, eg, corticosteroids; agents aimed at reducing edema, eg, hypertonic sodium chloride solution, corticosteroids; local anesthetics, and hyaluronidase to promote lysis (115). Failure of percutaneous lysis of adhesions logically leads to spinal endoscopy with lysis of adhesions, with rationalization of indications for spinal endoscopy, which is less invasive than surgery, spinal cord stimulation and intrathecal delivery systems; but more invasive than percutaneous lysis of adhesions with a spring guided catheter. Spinal endoscopy with adhesiolysis is indicated only with appropriate diagnostic evaluation and after failure or ineffectiveness of other conservative or less invasive modalities of treatment has been proven.

Table 3. Results of published reports of spinal endoscopy

Author(s)	Study characteristic	Number of patients	Relief			
			1-4 weeks	3 months	6 months	1 year
Richardson et al (150)	P	34	Sig	Sig	Sig	Sig
Manchikanti et al (145)	R	60	100%	75%	40%	22%
Manchikanti et al (146)	R	85	100%	77%	52%	21%
Choi et al (147)	R	24	66%	45%	29%	29%

R = retrospective, P = prospective, Sig = significant number of patients

While most commonly used methods involve entry into the epidural space through the sacral hiatus, medication placed in the posterior or posterolateral epidural space may not reach pathology in an intravertebral foramen or in the anterior epidural space (171, 211-218). The rationale for the transforaminal approach is based on lesion-specific adhesiolysis and delivery of medication to fulfill the aim of reaching the primary site of pathology, thus improving the ultimate outcome. In fact, present evidence evaluating the effectiveness of transforaminal steroids is encouraging compared to interlaminar and caudal epidural steroid injections (1). While transforaminal endoscopes may be developed in the future, by utilizing the present modality of endoscopic adhesiolysis through the caudal epidural space, it is hoped that the anterior or ventral epidural space is accessed by distension of the epidural space and by mechanical means with steering of the catheter and lysis of adhesions.

Additional aspects of the rationale include the mechanical and hydrostatic effect of the procedure with high volume fluid administration and direct access to the target site, removing or diluting the chemical irritants.

CLINICAL EFFECTIVENESS

Clinical effectiveness of endoscopic adhesiolysis with direct visualization was evaluated in one prospective case series (150), four retrospective trials (144-147) and some case reports (141-143). The summary of results is shown in Table 3.

Richardson et al (150) evaluated the role of spinal endoscopy in 34 patients in a prospective case series suffering with chronic, severe low back pain, with 50% of the patients having failed back surgery syndrome. They reported the presence of epidural adhesions in 100% of the patients,

with 41% having dense adhesions. A follow-up over a 1-year period showed significant reductions in pain scores and disability.

Manchikanti et al (145), in a study evaluating the effectiveness of endoscopic adhesiolysis in postlumbar laminectomy syndrome in 60 patients, showed that 100% of the patients reported significant pain relief at 1 month, whereas 75% reported significant relief at 3 months; 40% reported significant relief at 6 months, and 22% reported significant relief at 12 months. They concluded that endoscopic adhesiolysis with administration of corticosteroids is a safe and possibly cost-effective technique for relief of chronic intractable pain failing to respond to other modalities of treatments.

Manchikanti et al (146) studied the value and safety of epidural endoscopic adhesiolysis. In a retrospective evaluation of 85 consecutive patients undergoing 112 epidural endoscopic procedures, they reported significant pain relief in 100% of the patients, initially decreasing to 94% at 1 to 2 months, to 77% at 2 to 3 months, to 52% at 3 to 6 months, to 21% at 6 to 12 months, and to 7% after 12 months. They concluded that epidural endoscopy with adhesiolysis is a relatively safe and possibly cost-effective technique in the management of chronic refractory low back pain.

Saberski (144), in a retrospective analysis of spinal endoscopy and laminectomy, reported outcome data in a pilot study that included two groups of patients, Group I, with 22 patients treated via spinal endoscopy; and Group II, with 13 patients treated via laminectomy. After spinal canal endoscopy, only 32% of Group I patients were continued on opioid medication; whereas 92% of Group II patients were continued on opioid medication after laminectomy. In addition, 72% from the spinal canal endoscopy group and only 28% from the laminectomy group returned

to work. He concluded that this study suggested remarkable differences in outcomes when comparing patients who underwent spinal canal endoscopy to a similar population who underwent lumbar laminectomy.

Choi et al (147) analyzed back and leg pain and the effectiveness of epiduroscopy and the treatment of failed back pain syndrome retrospectively in 24 patients. All patients failed to respond to a conservative and interventional pain management program including opioids; epidural injections; facet, sacroiliac and nerve root blocks; radiofrequency thermoneurolysis; cryoanalgesia; psychology and extended physiotherapy. All of the patients underwent a caudal epiduroscopy using a percutaneous flexible endoscope to investigate the pathology and an endoscopic epiduroplasty to release the fibrosis and to retrieve the epidural space. Following this, epidural injection with lidocaine and steroids was performed. Patients were followed up for 6 months. The results showed that there were 13 men and 11 women, with a mean age of 49.5 and a range of 28 to 70 years. Mean duration of pain was 7.1 years, with a range of 20 to 30 years. Of the 24 patients, 20 patients had postlumbar laminectomy syndrome. The authors reported that all patients showed inflammation of the epidural contents with loose fibrotic tissue extensively either bilaterally or locally. The preoperative mean visual analog scale score of back pain was 8.0 and relief with VAS less than 4 was obtained within 1 month in 12 patients (50%, 3 months in 7 patients, 29%, and 6 months in 3 patients, and 13%, 4 patients; 16% reported complete pain relief). Leg pain was relieved in all of the successful patients.

Based on the above, the type and strength of efficacy evidence analysis place spinal endoscopy into type IV-limited, which is defined as evidence from well-designed, nonexperimental studies from more than one center or research group: but this evidence is also complemented by clinical experience (1).

INDICATIONS

Epiduroscopy or spinal endoscopy is approved in the United States for directed delivery of normal saline and steroid by the Federal Drug Administration. Various devices have been manufactured for this purpose by Visionary Biomedical (Myelotec®) Clarus® in the mid 1990s and by EBI® in the year 2000. Spinal canal endoscopy was frequently used for delivery of epidural steroid medication rather indiscriminately; proper indications were not established. By the late 1990s numerous versions of the tech-

nique and numerous indications emerged; however, there was no standardized protocol for spinal endoscopy. Although there has not been appropriate peer-reviewed literature basing the evidence on randomized, controlled studies resulting in the decision that this technique was experimental, since then multiple evaluations have appeared in the literature. Concato et al (219) conducted a study of randomized, controlled trials and observational studies using a hierarchy of research designs. They described that, in the hierarchy of research designs, the results of randomized, controlled trials have been considered to be evidence of the highest grade, whereas observational studies have had less validity because such studies reportedly overestimate treatment effects. Concato et al (219) also showed that the average results of the observational studies were remarkably similar to those of randomized, controlled trials; and concluded that the results of well-designed observational studies (with either a cohort or a case-controlled design) do not systematically overestimate the magnitude of the effects of treatment as compared with those in randomized, controlled trials on the same topic. Yet the medical world continues to focus on randomized, controlled trials. Spinal endoscopy in the mid 1990s began to be used with high expectations, with anticipation of the first phase of the study requiring up to 60 investigators or so. The study was designed to assist the outcome and safety of epidural steroid injections made with fiberoptic endoscopic technique by improving the target delivery of the steroid in patients with persistent lumbar radiculopathy that did not respond to physical therapy or two to three volumetric caudal epidural injections (120). The premise behind the philosophy was that the majority of failures of epidural injections were arising from failure to deliver the injectate to the target area, owing to either a proliferation of connective tissue scar, the presence of fat or perhaps other morphologic anomalies around the nerve roots in question. Once again, the philosophy was based on indications described for nonendoscopic adhesiolysis with a spring guided catheter.

In 1998, an international group of experts drew up a consensus paper establishing a standard for epiduroscopy (120). This panel defined *spinal canal endoscopy* as “percutaneous, minimally invasive endoscopy investigation of the epidural space to enable color visualization of anatomic structures inside the spinal canal: dura mater, blood vessels, connective tissue, nerves, fat, and pathologic structures, including adhesions, inflammation, and stenotic change.” General indications were established for spinal endoscopy and diagnosis and treatment of spinal pain syndromes including:

1. Observation of pathology and anatomy,
2. Direct drug application,
3. Direct lysis of scarring (with medication, blunt dissection, laser, and other instruments),
4. Placement of catheter and electrode systems (epidural, subarachnoid), and
5. An adjunct to minimally invasive surgery.

However, this has been widely ignored in the United States. Indications in the United States include lysis of scarring with drug application under direct visualization. Thus, endoscopy epidural adhesiolysis is indicated in patients with chronic low back pain who have failed to respond to conservative modalities of treatment, including epidural injections administered under fluoroscopic guidance, percutaneous lysis of adhesions with a spring guided catheter, and other well-documented therapeutic modalities. Various conditions in which spinal endoscopy is indicated include postlumbar laminectomy syndrome; epidural adhesions; and disc disruption resulting in chronic, intractable pain nonresponsive to other modalities of treatment. Possible or even probable indications include low back pain nonresponsive to other modalities of treatments and chemical irritation.

Even though indications as described above are commonly utilized, it is of paramount importance that endoscopic lysis of epidural adhesiolysis in management of chronic low back pain should only be performed in patients who are ideal candidates without any major contraindications. It is also important to understand that the response of endoscopic epidural adhesiolysis in managing chronic low back pain secondary to facet joint mediated pain, and degenerative arthritis will be poor due to differing pathophysiology.

Contraindications include but are not limited to coagulopathy, pregnancy, renal insufficiency, chronic liver dysfunction, history of adverse reaction to local anesthetic or anti-inflammatory drugs, history of gastrointestinal (GI) bleeding or ulcers, urinary sphincter dysfunction, progressive neurological deficit, infection, increased intracranial pressure, pseudotumor cerebri, intracranial tumors, unstable angina, severe chronic obstructive pulmonary disease, inability to achieve appropriate positioning, and inability to understand informed consent and protocol. The procedure should never be performed under general anesthesia. Other minor or related contraindications include generalized symptomatology, active untreated or resistant psychiatric disorders affecting the physical condition, and visual deficiencies.

COST EFFECTIVENESS

Fortunately, the cost effectiveness of spinal endoscopy and adhesiolysis was determined in two separate groups of patients (145, 146). In the present environment of health-care cost explosion, heightened attention to fraud and abuse and rapidly developing new technology, confusion abounds over what is meant by the term *cost effectiveness*. *Cost-minimization analysis*, *cost-benefit analysis*, *cost effectiveness analysis* (CEA), and *cost-utility analysis* are multiple terms utilized in describing cost effectiveness. In chronic low back pain CEA would be the most appropriate method to use since in these studies the effects are measured in natural units and quality of life (220-235). The outcome measures used in CEA studies in chronic pain research mainly include functional outcomes, such as disability days saved; pain-free days or improved quality of life; etc.; evaluation of quality of life, which is also known as functional status, health status, or health-related quality of life; well-being of the patient; satisfaction with care; health service utilization/economic analysis, and medical findings (230).

Evaluation in assessment of quality of life focuses on the patient's major perceived functional impairments, and improvement in areas of individual importance such as having sexual relations, returning to work, going to school, homemaking, playing with children/grandchildren, or performing other activities of daily living. These assessments are designed to evaluate functional status in the real world with activities of daily living, rather than being limited to one aspect of life, i.e., return to work, which may or may not be possible due to various reasons, including retirement, long-term disability and other factors. Thus, quality of life is a practical measure in difficult situations, essentially measuring social functioning, along with activities of daily living determining the extent of the improvement in health problems affecting practical aspects of life.

The cost of outpatient treatment programs ranges from \$7,000 to \$10,000, whereas the cost of inpatient chronic pain programs ranges from \$17,000 to \$25,000 in 1988 dollars (231). Chronic pain patients may also incur health-care bills in excess of \$20,000 annually for repetitive and, in many cases, redundant diagnostic workups, drugs, and numerous interventions. It was estimated that back pain accounted for 150 million lost workdays in the United States every year, which worked out to be about \$14 billion in wage costs alone (228). Surprisingly, it was also shown that even a 1% reduction in overall prevalence could con-

siderably reduce morbidity and save billions of dollars considering the large magnitude of the back pain problem (228). The cost effectiveness of lumbar discectomy for the treatment of herniated intervertebral discs was published in 1996 (225). The cost effectiveness of lumbar discectomy for the treatment of herniated intervertebral discs has been based on the conclusion that surgery increases the average quality-adjusted life expectancy by 0.43 years during the decade following treatment compared to conservative treatment, a result comparable to extending a healthy life by 5 months. Malter et al (225) concluded that, for carefully selected patients with herniated discs, surgical discectomy is a cost-effective treatment at a discounted cost of \$12,000 per discectomy, or \$29,000 per life year adjusted for quality. However, this evaluation failed to take into consideration chronic pain patients following surgical treatment for herniated disc. It has been shown that, after the failure of the first surgery, the success of a second operation was only 50%, with an additional 20% considering themselves worse after surgery (20). However, it is even worse with further surgeries, as with a third procedure, the success rate was 30%, with 25% considering themselves worse; and, after four surgical interventions, only a 20% success rate was achieved, with 45% of these patients considering themselves worse (20). Thus, if additional cost of repeat surgery is taken into consideration, the cost of lumbar surgery will probably be much higher; the same may be applied to inflation.

Kuntz et al (227) found the cost effectiveness of fusion with and without instrumentation for patients with degenerative spondylolisthesis and spinal stenosis to be similar to the cost effectiveness of lumbar laminectomy. They demonstrated that laminectomy with a non-instrumented fusion costs \$56,500 per quality-adjusted year of life versus laminectomy without fusion. The cost effectiveness ratio of instrument infusion compared with noninstrument infusion was \$3,112,800, per quality-adjusted year of life (227). They were able to determine a reasonable cost effectiveness of \$82,400 per quality-adjusted year of life. The proportion of patients experiencing symptom relief after instrument infusion was 90% as compared with 80% for patients with noninstrument infusion.

The cost effectiveness of intrathecal therapy in failed back surgery syndrome was also evaluated, with publication of the results in 1999 (226). Authors compared intrathecal therapy with alternative therapies for achieving a defined outcome. They reported the cost of medical management to be \$17,037 per year or \$1,420 per month, in contrast to

intrathecal morphine delivery, which resulted in lower cumulative 60-month costs of \$16,579 per year, and \$1,382 per month.

The evaluation of cost effectiveness of three routes of epidural injections (blind interlaminar, fluoroscopically directed caudal and transforaminal epidural injections) for the management of low back pain showed the cost effectiveness of transforaminal steroids to be \$2,927 per year, and that of caudal epidural steroids to be \$3,635, in stark contrast to blind interlaminar lumbar epidural steroid injections at \$6,024 per year (212). The cost effectiveness of lumbar facet joint nerve blocks in managing chronic low back pain was shown to be \$3,461 for 1-year improvement of quality of life (229).

The cost effectiveness of percutaneous lysis of adhesions in three studies (114, 117, 145) for 1 year of improvement in the quality of life varied from \$2,693 in a randomized, clinical trial evaluation of 1-day epidural adhesiolysis in management of chronic low back pain in patients who failed to respond to fluoroscopically directed epidural steroid injections who were also demonstrated not to have facet joint mediated pain, to \$5,564 in chronic low back pain management in patients nonresponsive to numerous other modalities of treatments in an earlier study.

The literature showed the cost effectiveness of medical treatment of hypertension as \$16,330 for a 60-year-old man in 1974 (230), whereas treatment of depression with medical therapy is \$11,766 per year of quality-adjusted life (232). On the same lines, the cost effectiveness of total hip arthroplasty has been shown to be \$61,000 (233), that of coronary artery bypass grafting for patients with triple-vessel coronary artery disease and severe left ventricular function as \$41,800 (234), and that of surgical repair of a 4-cm abdominal aortic aneurysm as \$21,800 with improvement per quality-adjusted year of life gained (235).

The cost effectiveness of spinal endoscopy in patients failing to respond to all conservative modalities of treatments including percutaneous lysis with a spring guided catheter, was shown to be \$7020 to \$8127 (145, 146). Hence, spinal endoscopy with adhesiolysis for persistent low back pain, despite all other less invasive modalities of treatment, is in the approximate range as that of other well-accepted modalities of treatment. However, it is more than less invasive interventional techniques also well within reasonable limits for present-day cost effectiveness.

COMPLICATIONS

The most common and worrisome complications of spinal endoscopy with lysis of adhesions are related to instrumentation and administration of high volumes of fluids, resulting in excessive epidural hydrostatic pressures, which may cause spinal cord compression, excessive intraspinal and intracranial pressures, epidural hematoma, bleeding, infection, increased intraocular pressures with resultant visual deficiencies and even blindness and dural puncture (110, 145, 146, 233). Even though dural puncture was noted in 8 of 112 procedures (146), and 7 of 77 procedures (145), subarachnoid blockade was seen in only 30% to 40% of patients, without any other complications. However, excessive pressure development has the potential to affect both local and distant perfusion, possibly resulting in visual changes and even blindness. Even though the incidence is rare, it appears that it would be much higher with spinal endoscopic procedures with a combination of high volumes of fluid and generation of high hydrostatic pressures (236). Their incidence also has been reported with routine epidural injections, presumably resulting from transmission of spinal canal pressures cephalad into the brain while CSF and affecting retinal perfusion or macular hemorrhage.

Kushner and Olson (237) evaluated patients who complained of visual-field defects or blurred vision after receiving epidural steroid injections and concluded that retinal hemorrhage is uncommon but significant, and a previously unemphasized complication of epidural steroid injections in general. Retinal hemorrhages mainly have been attributed to rapid epidural injections of high volumes, causing a sudden increase in intracranial pressure, resulting in the increase of retinal venous pressure (237-243). Hence, it appears that there is a causal relationship between these complications and spinal endoscopy and adhesiolysis with administration of high volumes of saline, and other agents, specifically with rapid injections.

Epidural infection following this procedure is a distinct possibility due to the procedure itself, as well as potential immunosuppression secondary to steroid injection (244-284). Manchikanti et al (146) reported a serious infection in one patient requiring prolonged antibiotic therapy and skin grafting in a patient on anticoagulant therapy. Infection also occurred following 2 of 112 procedures. In this evaluation, infection was suspected in 6 of 112 procedures, managed by prophylactic antibiotics (146). Manchikanti et al (145) also reported suspicion of infection following 8 of 77 procedures, with no major complications in another study.

Sampath and Rigamonti (244), in a review of epidemiology, diagnosis, and treatment of spinal epidural abscess, noted that spinal nerve block was responsible for 7% of the patients, whereas a multitude of predisposing factors included intravenous (IV) drug use, diabetes neuritis, multiple medical illnesses, trauma, prior spinal surgery, morbid obesity, HIV disease, and end-stage renal disease in a descending order of frequency. Wang et al (245), in a 1-year study of the incidence of spinal epidural abscess after epidural analgesia, reported 9 cases of epidural abscess formation from a total of 17,372 epidural catheters. Rathmell et al (246) discussed various aspects of epidural abscess following epidural analgesia.

Direct trauma to the spinal cord following spinal endoscopy in the lumbar spine is only a theoretical possibility. Neural trauma is a potential complication, even though there are no such case reports. Subdural injection, neural trauma, injury to the spinal cord, and hematoma formation have been described with epidural injections, even though there are no specific descriptions relating to spinal endoscopy (285-289). Spinal gas collection and subdural intracranial air were also reported following epidural injections (290-292). Lumbar radiculopathy has been reported following intraspinal gas collection not associated with herniated discs (293-297). Neurological complications of spinal and epidural anesthesia were reviewed by Horlocker and Wedel (287). They reported a 0.2% to 2.9% cardiac arrest rate, 0.2% to 1.2% death rate, 0.4% to 3.6% neurological injury rate, 0.5 to 3.8% radiculopathy rate, 0% to 1.2% incidence of cauda equina syndrome and 0% to 1.8% incidence of paraplegia after reviewing 30,413 epidurals. They also reported anterior spinal artery syndrome leading to spinal cord ischemia resulting in flaccid paralysis of the lower extremities (298). Transient and neurologic symptoms after epidural analgesia also have been reported, including cauda equina syndrome (299).

Epidural hematoma following epidural analgesia in a patient receiving unfractionated heparin for thromboprophylaxis (288) and paraplegia after epidural anesthesia in a patient with peripheral vascular disease with the development of hematoma (289) have been reported. Cauda equina syndrome secondary to idiopathic spinal epidural lipomatosis also has been reported (300). However, spinal cord trauma or spinal cord or epidural hematoma formation is a catastrophic complication possible with spinal endoscopic adhesiolysis, although there are no case reports in the literature. Other potential complications include increased or continued pain, transient dysesthesias, paresis, paralysis, local surgical site bleed-

ing, allergic reactions, and side effects related to the administration of steroids. While paresis, paralysis, and intractable pain may be related to needle trauma, epidural hematoma, elevated hydrostatic pressures, ischemia, or nerve injury; severe headache, dysesthesia and intractable acute back pain may indicate epidural hematoma, cord ischemia, and elevated hydrostatic pressure. However, the safety of steroids and preservatives at epidural therapeutic doses has been demonstrated in both clinical and experimental studies (301-317). The major theoretical complications of corticosteroid administration include arachnoiditis, suppression of the pituitary-adrenal axis, hypocorticism, Cushing's syndrome, osteoporosis, avascular necrosis of bone, steroid myopathy, weight gain, fluid retention, and hyperglycemia (316, 317). Other potential complications include hypertension, hypokalemia, epidural lipomatosis, retinal hemorrhage, subcapsular cataract formation, insomnia, mood swings, psychosis, facial flushing, headache, GI disturbances, and menstrual disturbances. However, the use of corticosteroids repeatedly for days or even a few weeks does not lead to adrenal insufficiency upon cessation of treatment; but prolonged therapy with corticosteroids occasionally may result in the suppression of pituitary-adrenal function that can be slow in returning to normal. Rare hypothalamic-pituitary-adrenal suppression during corticosteroid administration with epidural injections and after its withdrawal has been reported (316-319). However, no such reports have implicated spinal endoscopy and administration of steroids. Manchikanti et al (320) evaluated the effect of neuraxial steroids on weight and bone mass density (BMD) prospectively. They studied 204 patients, with 123 patients completing the study. They divided the patients into two groups, with one group receiving neural blockade without any steroids and the second group receiving neuraxial steroids. The results of serial determination of weight and BMD showed no significant change at any interval or at the end of 1 year in all 123 patients with or without steroid administration. In addition, this study also showed some improvement in BMD, as well as weight reduction, indicating improvement in functional status. They concluded that low-dose administration of neuraxial steroids is safe in patients suffering with chronic pain who have failed to respond to conservative modalities of treatment with a favorable risk-benefit ratio, without any deleterious effects either on body weight or BMD.

TECHNICAL CONSIDERATIONS

Spinal endoscopy is best performed by a caudal approach based on anatomy, equipment, and experience with epidu-

ral adhesiolysis with spring guided catheter. The straight entry into the epidural space through the caudal approach is much easier and more practical rather than entry into the lumbar epidural space through a paramedian approach, even with a steep angle. This facilitates not only the easy passage of the fiberoptic endoscope but also reduces damage to the device.

Anatomy

The spinal canal extends from the foramen magnum to the sacrum, which is bounded posteriorly by the ligamentum flavum and periosteum and anteriorly by the posterior longitudinal ligament that lies over the dorsal aspects of the vertebral bodies and discs (120). The size of the spinal canal is variable, with its largest diameter in the cervical and lumbar regions, corresponding to enlargements in the spinal cord measuring 18 mm in the anterior, posterior dimension at C4 to 6, with a transverse diameter of 30 mm; measuring 17 mm in both anterior, posterior and transverse measurements in the thoracic region, and 23 mm in anterior posterior diameters and 18 mm in the transverse diameter in the lumbar region (120). However, the size of the spinal canal is approximately twice the size of the cord. The canal in cross section appears triangular in the lumbar region (120). While the spinal cord ends at L1, the dural sac continues to the spinal cord and conus, running down to the level of S2.

The dural sac rests on the floor of the vertebral canal (321). The anterior relations of the dural sac, therefore, are the backs of the vertebral bodies and the intervertebral discs, and covering these structures is the posterior longitudinal ligament (321). Thus, anterior spinal arteries and sinuvertebral nerves run across the floor of the vertebral canal and are located anterior to the dural sac. The dural sac, posteriorly is related to the roof of the vertebral canal, the laminae, and ligamentum flava (321).

The epidural space is the space intervening between the dural sac and the osseo-ligamentous boundaries of the vertebral canal, which is a narrow space. This is described as a potential space and the term *epidural region* has been advocated as an alternative description to avoid the connotation of a wide, empty space (322). The epidural space is principally filled by a thin layer of areolar connective tissue which varies from diaphanous to pseudomembranous in structure (322). This also has been described as an epidural membrane (323). The membrane surrounds the dural sac and lines the deep surface of the laminae and pedicles (321). Ventrally, opposite the vertebral bodies,

the membrane lines the back of the vertebral body and then passes medially deep to the posterior longitudinal ligament, where it detaches to the anterior surface of the deep portion of the ligament (323). However, the membrane does not cover the back of the anulus fibrosus; prevented from doing so by the posterior longitudinal ligament as it expands laterally over the back of the disc. Thus, the epidural membrane blends with the upper and lower borders of the anulus fibrosis, however, in a plane just anterior to that of the posterior longitudinal ligament. Further, the membrane is drawn laterally to form a circumneural sheath around the dural sleeve of the nerve roots and spinal nerve, opposite the intervertebral foramen (323). Anterior and posterior internal vertebral venous plexuses run within the areolar tissue of the epidural membrane (321). Epidural fat is not distributed uniformly throughout the epidural space, but is concentrated around the nerve roots in the intervertebral foramina and in collections wrapped in areolar tissue enlarged in the midline recesses between the ligamentum flavum at each segmental level (322). The size of the posterior epidural space, however, averages only 4 to 6 mm at the lumbar level, 3 to 5 mm at the thoracic level, and 2 mm at the cervical level (120). Thus, the contents of the epidural space include the vertebral venous plexus, the spinal branches of the segmental arteries, the lymphatics, and the dura arachnoid projections that surround the spinal nerve roots, along with abundant fat (120).

Technique

Prior to undergoing spinal endoscopy, outpatients must be assessed with a comprehensive physical and psychological evaluation. All less invasive and conservative modalities of treatment, including fluoroscopically directed epidural steroid injections and spring guided catheter lysis of adhesions, should be exhausted. In addition, appropriate laboratory studies should be considered to rule out bleeding disorders. Nonsteroidal anti-inflammatory drugs, aspirin, and anticoagulants should be discontinued prior to spinal canal endoscopy to avoid unusual bleeding.

Under the preoperative preparation, an antibacterial scrub with a shower the night before should be considered. In addition, the patient should have an empty stomach. No general anesthesia should be contemplated. The patient should understand all the implications of the procedure and sign an informed consent.

After the initial evaluation, the patient is transferred to the holding area, where appropriate preparation is carried out with preoperative evaluation, checking of vital signs and

establishment of IV access, as well as antibiotic administration.

Following this, the patient is taken to the operating room or a sterile procedure room where preparation is carried out with Betadine® prep. Draping is carried out to cover the entire patient, extending into the cervical region.

At this time, under appropriate monitoring with blood pressure and pulse oximetry, sedation is administered and continuous monitoring is performed.

The procedure is performed in a sterile operating room under appropriate sterile precautions using fluoroscopy. The fluoroscope is adjusted over the lumbosacral region to perform the procedure in the lumbosacral region for a lumbar or caudal procedure, both an anteroposterior and lateral views.

After appropriate positioning of fluoroscopy, a physician, scrubbed and with sterile gown and gloves, infiltrates the area for needle insertion with local anesthetic. Following this, an epidural needle is introduced into the epidural space using fluoroscopic visualization. Once the needle placement is confirmed to be in the epidural space, a lumbar epidurogram is carried out using approximately 2 to 5 cc of contrast. Finding the filling defects by examining the contrast flow into the nerve roots is the purpose of the epidurogram. Intravascular or subarachnoid placement of the needle or contrast is avoided; if such malpositioning occurs, the needle is repositioned.

A 0.9-mm guide wire is inserted through the needle, which is advanced under fluoroscopic guidance to the level of suspected pathology, followed by a small incision and advancement of a 2-mm x 17.8-cm dilator with catheter (sheath) over the guidewire. Once the catheter is advanced to the tip of the guidewire, the wire is removed. At this time, a 0.8-mm fiberoptic spinal endoscopy is introduced into the catheter through the valve and is advanced until the tip is positioned at the distal end of the catheter, as determined by video and fluoroscopic images. In conjunction with gentle irrigation using normal saline, the catheter and fiberoptic myeloscope are manipulated and rotated in multiple directions, with visualization of the nerve roots at various levels. Gentle irrigation may also be carried out by slow, controlled infusion. Adhesiolysis and decompression are carried out by distension of the epidural space with normal saline and by mechanical means using the fiberoptic endoscope. Figures. 1 to 4 illustrate the procedural considerations.

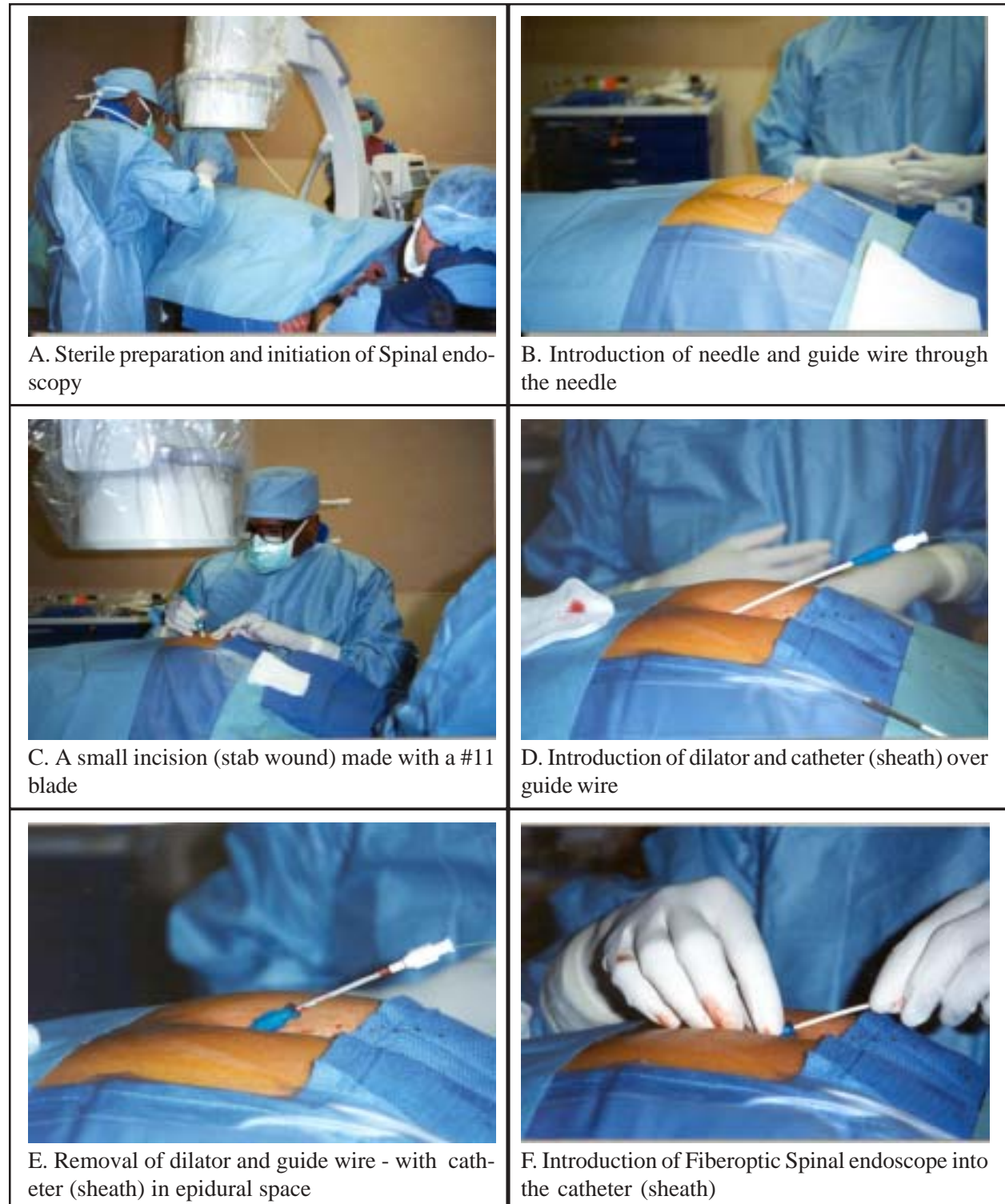


Fig. 1. Spinal endoscopy performed in a sterile operation room

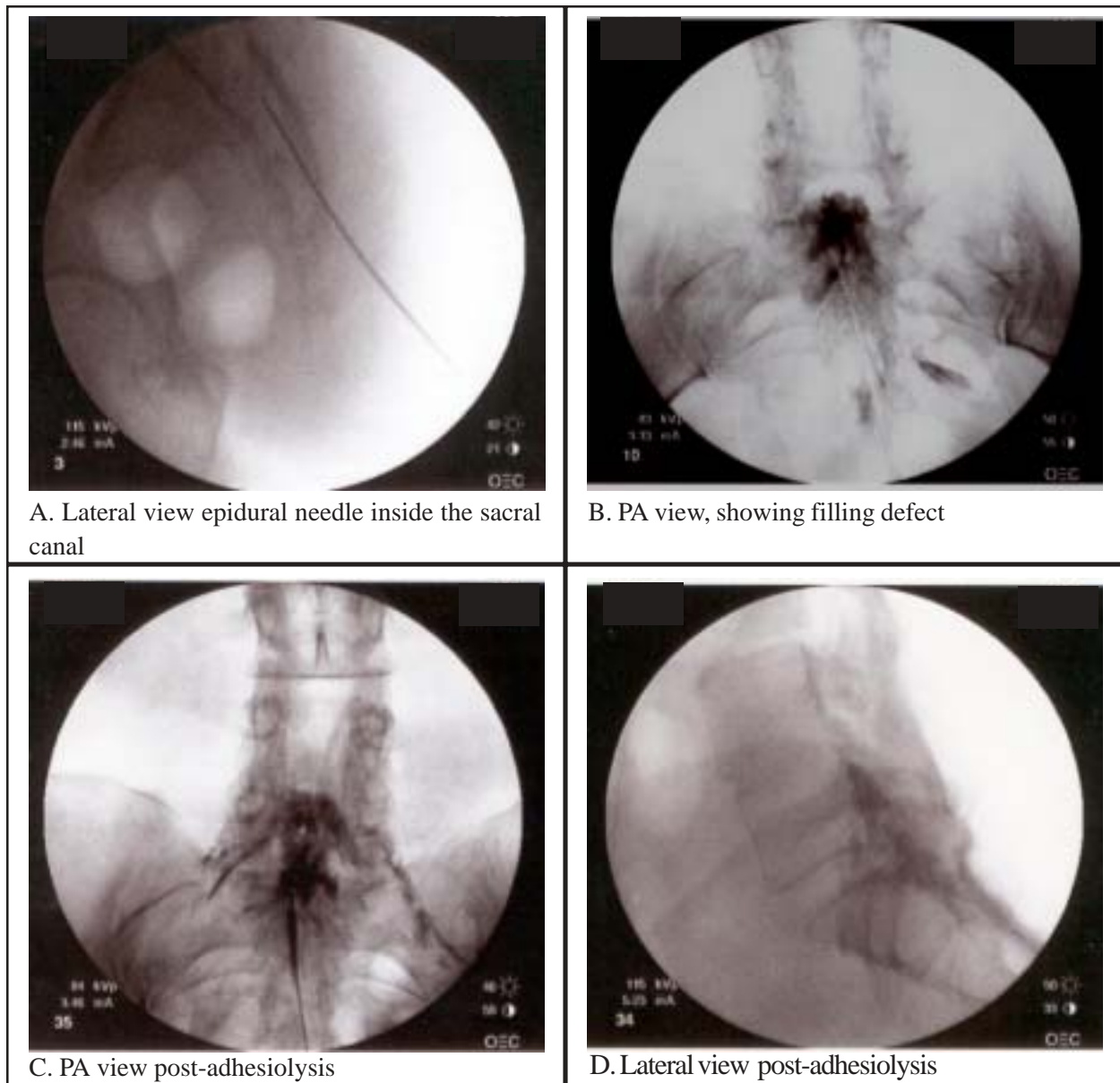


Fig 2. Fluoroscopic visualization of needle placement and lumbar epidurography

Confirmation is accomplished with injection of non-ionic contrast material. An epidurogram is performed on at least two occasions. Following completion of the procedure, generally, lidocaine 1%, preservative free, mixed with 6 to 12 mg of betamethasone acetate and phosphate mixture or methylprednisolone or triamcinolone is injected in each case after assuring that there is no evidence of subarachnoid leakage of contrast. If there is a question of subarachnoid leakage of the contrast, a Racz catheter may be

passed into the epidural space, and a mixture of local anesthetic injected very slowly in incremental doses, followed by injection of the steroid.

Following completion of the procedure, if necessary, self-absorbed sutures are applied, followed by sterile Bioclusive® dressing. Subsequently, the patient is turned to the supine position and transferred to the recovery room. In the recovery room, the patient is very closely monitored for any potential complications or side effects. If a patient

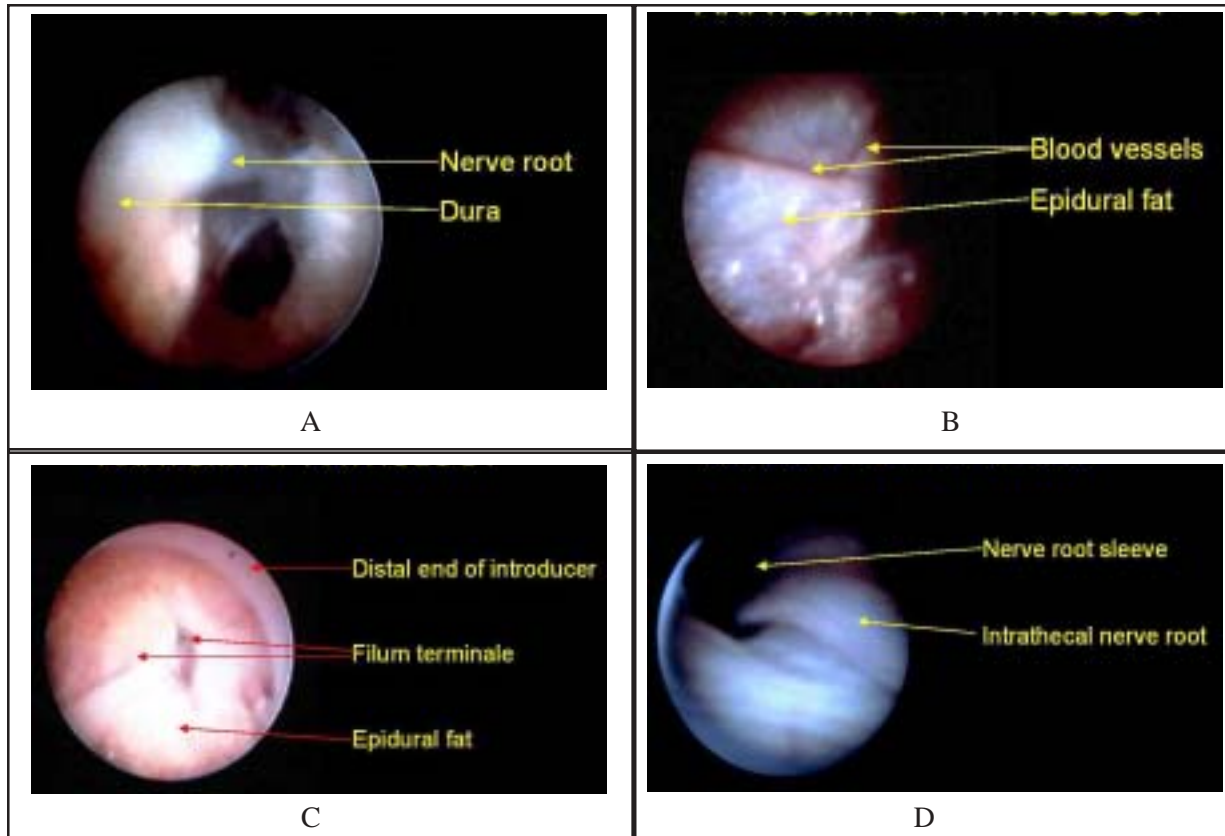


Fig. 3. Normal endoscopic anatomy of lumbar epidural space

Reproduction with permission from Visionary Biomedical (Mylotec), Inc.

has a catheter and no complications are observed and good pain relief is reported without any motor weakness, steroid is injected. At times, subsequent hypertonic saline neurolysis is also carried out with 10% sodium chloride solution.

Following this, the patient is re-evaluated, the catheter is flushed with normal saline and the catheter, if present, is removed and checked for intactness. The wound is also checked at this time, with or without the catheter. The patient is ambulated if all parameters are satisfactory and IV access is removed, and the patient is discharged home with appropriate instructions.

CONCLUSION

Chronic low back pain is a major health care and social problem. Much of the confusion surrounding endoscopic adhesiolysis in managing refractory low back pain results

from overemphasis on biopsychosocial problems and inappropriate selection of patients for this treatment modality. Considering the preliminary cumulative evidence available in the literature on endoscopic epidural adhesiolysis, the efficacy of this procedure is similar, if not superior, to various other modalities of treatments available in managing chronic low back pain, including surgical intervention.

While this is a very effective technique in managing chronic low back pain, caution must be exercised, as there are significant risks of complications of spinal cord trauma. While a pain practitioner needs to individualize the choice of treatment to each patient and personal experience, we recommend endoscopic epidural adhesiolysis, which has proven to be a valuable, safe, and cost-effective technique for relieving chronic, intractable pain nonresponsive to all other conservative modalities of treatment when performed in an outpatient setting, with reasonable and customary charges for the facility and physician services.

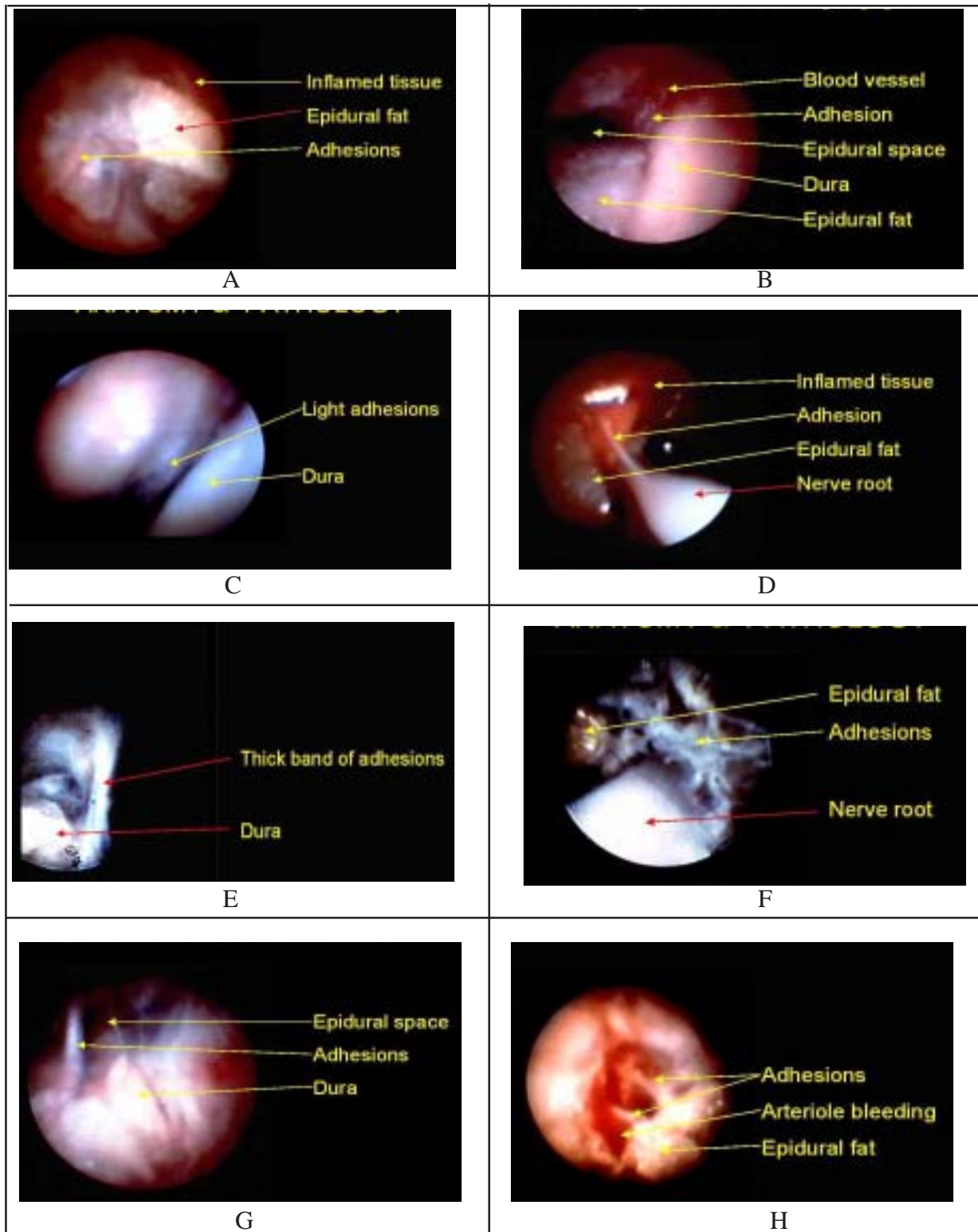


Fig. 4. Typical findings of endoscopic anatomy and adhesiolysis of lumbar epidural space
Reproduction with permission from Visionary Biomedical (Mylotec), Inc.

ACKNOWLEDGMENTS

The authors wish to thank Denise Pratt and Tonie Hatton for their dedication and patience in the preparation of this manuscript.

REFERENCES

1. Manchikanti L, Singh V, Kloth D et al. Interventional techniques in the management of chronic pain: Part 2.0. *Pain Physician* 2001; 4:24-96.
2. Manchikanti L. The role of neural blockade in the management of chronic low back pain. *Pain Digest* 1999; 9:166-181.
3. Wilkinson HA. Introduction: Etiology, diagnosis, and therapy. In *The Failed Back Syndrome. Etiology and Therapy*, Second Edition. Springer-Verlag, New York, 1992, pp 1-3.
4. Wilkinson HA. The role of improper surgery in the etiology of the failed back syndrome. In *The Failed Back Syndrome. Etiology and Therapy*, Second Edition. Springer-Verlag, New York, 1992, pp 4-12.
5. Nachemson AL. Failed back surgery syndrome is syndrome of failed back surgeons. *Pain Clinic* 1999; 11:271-284.
6. North RB. Management of the failed back surgery syndrome. *Adv Oper Ortho* 1993; 161-173.
7. Lawrence RC, Helmick CG, Arnett FC. Estimates of the prevalence of arthritis and selected musculoskeletal disorders in the United States. *Arthritis & Rheumatism* 1998; 41:778-799.
8. Manchikanti L. Chronic low back pain in the elderly: Part I. *Am J Pain Manage* 1997;7:104-117.
9. Cassidy D, Carroll L, Cote P: The Saskatchewan Health and Back Pain Survey. *Spine* 1998;23:1860-1867.
10. Van Den Hoogen HJM, Koes BW, Deville W et al. The prognosis of low back pain in general practice. *Spine* 1997;22:1515-1521.
11. Croft PR, Macfarlane GJ, Papageorgiou AC et al. Outcome of low back pain in general practice: A prospective study. *Brit Med J* 1998;316:1356-1359.
12. Andersson GBJ, Svensson HO. The intensity of work recovery in low back pain. *Spine* 1983; 8:880-887.
13. Davis H. Increasing rates of cervical and lumbar spine surgery in the United States, 1979-1990. *Spine* 1994;19:1117-1124.
14. Gureje O, Von Korff M, Simon GE et al. Persistent pain and well-being: A World Health Organization study in primary care. *JAMA* 1998;280:147-151.
15. Miedema HS, Chorus AMJ, Wevers CWJ et al. Chronicity of back problems during working life. *Spine* 1998; 18:2021-2029.
16. Carey TS, Garrett JM, Jackman A et al. Recurrence and care seeking after acute back pain: Results from a long-term follow-up study. *Medical Care* 1999; 2:157-164.

17. Hagen KB, Thune O. Work incapacity from low back pain in the general population. *Spine* 1998; 19:2091-2095.
18. Leigh JP, Markowitz SB, Fahs M et al. Occupational injury and illness in the United States: Estimates of costs, morbidity, and mortality. *Arch Intern Med* 1997; 157:1557-1568.
19. Turner JA, Ersek M, Herron L et al. Surgery for lumbar spinal stenosis, attempted meta-analysis of the literature. *Spine* 1992;17:1-7.
20. Waddell G, Kummel EG, Lotto WN et al. Failed lumbar disc surgery and repeat surgery following industrial injury. *J Bone Joint Surg (Am)* 1969;61:201-207.
21. Ross JS, Robertson JT, Frederickson RCA et al. Association between peridural scar and recurrent radicular pain after lumbar discectomy: Magnetic resonance evaluation. *Neurosurgery* 1996;38:855-863.
22. Fritsch EW, Heisel J, Rupp S. The failed back surgery syndrome. Reasons, intraoperative findings, and long-term results: A report of 182 operative treatments. *Spine* 1996;21:626-633.
23. Parke WW, Watanable R. Adhesions of the ventral lumbar dura. Adjunct source of discogenic pain? *Spine* 1990; 15:300-303.
24. Quiles M, Marchisello PJ, Tsairis P. Lumbar adhesive arachnoiditis: Etiological and pathological aspects. *Spine* 1978; 3:45-50.
25. Benoist M, Ficat C, Baraf P et al. Post operative lumbar epiduroarachnoiditis: Diagnostic and therapeutic aspects. *Spine* 1980; 5:432-436.
26. Fager CA, Freidberg SR. Analysis of failures and poor results of lumbar spine surgery. *Spine* 1980; 5:87-94.
27. Hanley EN, Shapiro DE. The development of low back pain after excision of a lumbar disc. *J Bone Joint Surg* 1989; 71A:719-721.
28. Frymoyer JW. Magnitude of the problem. In Weinstein J, Weisel SW (eds). *The Lumbar Spine*. Philadelphia, WB Saunders, 1990, pp 32-38.
29. LaRocca H. Failed lumbar surgery. Principles of management. In Weinstein J, Wiesel S (eds). *The Lumbar Spine*. WB Saunders Company, Philadelphia, 1990, pp 872-881.
30. Rutkow IM. Orthopaedic operations in the United States, 1979-1983. *J Bone Joint Surg* 1986; 68A: 716-719.
31. Hanley EN Jr. The cost of surgical intervention for lumbar disc herniation. In Weinstein JN (ed). *Clinical Efficacy and Outcome in the Diagnosis and Treatment of Low Back Pain*. Raven Press, New York, 1992, pp 125-133.
32. Burton CV. Causes of failure of surgery on the lumbar spine: Ten-year follow up. *Mt Sinai J Med* 1991; 58:183-187.
33. Burton CV, Kirkaldy-Nillis WH, Yong-Hing K et al. Causes of failure of surgery on the lumbar spine. *Clin Orthop* 1981; 157:191-199.

34. North RB, Campbell JN, James CS et al. Failed back surgery syndrome: 5 year follow-up in 102 patients undergoing repeated operation. *Neurosurgery* 1991; 28:685-691.
35. Katz JN, Lipson SJ, Larson MG. The outcome of decompressive laminectomy for degenerative lumbar spinal stenosis. *J Bone Joint Surg* 1991; 73:809-816.
36. Postacchini F. Results of surgery compared with conservative management for lumbar disc herniations. *Spine* 1996; 21:1383-1387.
37. Law JD, Lehman RAW, Kirch WM. Reoperation after lumbar intervertebral disc surgery. *J Neurosurg* 1978;48:259-263.
38. Waddell G, Gibson NA, Grant I. Surgical treatment of lumbar disc prolapse and degenerative lumbar disc disease. In Nachemson AL, Jönsson E (eds). *Neck and Back Pain*. Lippincott Williams & Wilkins, Philadelphia, 2000, pp 305-325.
39. Gibson JNA, Grant IC, Waddell G. The Cochrane review of surgery for lumbar disc prolapse and degenerative lumbar spondylosis. *Spine* 1999; 24:1820-1832.
40. Keskimäki I, Seitsalo S, Osterman H et al. Reoperations after lumbar disc surgery. A population-based study of regional and interspecialty variations. *Spine* 2000; 25:1500-1508.
41. Berger E, Davis JMB. Chronic pain following lumbar spinal surgery in 1000 patients. *Proceedings of 9th World Congress on Pain*, August 1999, pp181-182.
42. Elzayat, SG, Faanaos C, Elzayat IM. Failed back surgery: A prospective study. *J Neurol Orthop Med Surg* 1995; 16:165-166.
43. Cinotti G, David T, Postacchini F. Results of disc prosthesis after a minimum follow-up period of 2 years. *Spine* 1996; 21:995-1000.
44. Johnsson KE, Alfudén, Rosén I. The effect of decompression on the natural course of spinal stenosis. A comparison of surgically treated and untreated patients. *Spine* 1991; 16:615-619.
45. Horenstein S. Chronic low back pain and the failed low back syndrome. *Neurol Clin* 1989; 7:361-385.
46. Jönsson B, Strömqvist B. Clinical characteristics of recurrent sciatica after lumbar discectomy. *Spine* 1996; 21:500-505.
47. Taylor VM, Deyo RA, Ciol M et al. Patient-oriented outcomes from low back surgery. *Spine* 2000; 25:2445-2452.
48. Atlas SJ, Keller RB, Robson D et al. Surgical and nonsurgical management of lumbar spinal stenosis. Four-year outcomes from the Maine lumbar spine study. *Spine* 2000; 25:556-562.
49. Frocrain L, Duvauferrier R, Husson JL et al. Recurrent postoperative sciatica: Evaluation with MR imaging and enhanced CT. *Radiology* 1989; 170:531-533.
50. Fountas KN, Kapsalaki EZ, Johnston KW et al. Post-operative lumbar microdiscectomy pain. Minimization by irrigation and cooling. *Spine* 1999; 24:1958-1960.
51. Postacchini F. Lumbar disc herniation. A new equilibrium is needed between nonoperative and operative treatment. *Spine* 2001; 26:601.
52. Yorimitsu E, Chiba K, Toyama Y et al. Long-term outcomes of standard discectomy for lumbar disc herniation. A follow-up study of more than 10 years. *Spine* 2001; 26:652-657.
53. DeBerard MS, Masters KS, Colledge AL. Outcomes of posterolateral lumbar fusion in Utah patients receiving workers' compensation. A retrospective cohort study. *Spine* 2001; 26:738-747.
54. Kuslich SD, Danielson G, Dowdle JD et al. Four-year follow-up results of lumbar spine arthrodesis using the Bagby and Kuslich lumbar fusion cage. *Spine* 2000; 25:2656-2662.
55. Hu RW, Jaglal S, Axcell T et al. A population-based study of reoperations after back surgery. *Spine* 1997; 22:2265-2271.
56. Wetzel FT, LaRocca H. The failed posterior lumbar interbody fusion. *Spine* 1991; 16:839-845.
57. Katz J. Lumbar spinal fusion. Surgical rates, costs, and complications. *Spine* 1995; 20:78S-83S.
58. Suk KS, Lee HM, Moon SH et al. Recurrent lumbar disc herniation. Results of operative management. *Spine* 2001; 26:672-676.
59. Junge A, Fröhlich M, Ahrens S et al. Predictors of bad and good outcome of lumbar spine surgery. A prospective clinical study with 2 years' follow-up. *Spine* 1996; 21:1056-1065.
60. Katz J, Lipson S, Chang L et al. Seven- to 10-year outcome of decompressive surgery for degenerative lumbar spinal stenosis. *Spine* 1996; 21:92-98.
61. Biondi J, Greenberg BJ. Redecompression and fusion in failed back syndrome patients. *J Spinal Disord* 1990; 3:362-369.
62. Wetzel FT, Phillips FM, Aprill CN. Extradural sensory rhizotomy in the management of chronic lumbar radiculopathy. *Spine* 1997; 22:2283-2292.
63. Herno A, Airaksinen O, Saari T et al. Surgical results of lumbar spinal stenosis. A comparison of patients with or without previous back surgery. *Spine* 1995; 20:964-969.
64. Loupasis GA, Stams K, Katonis PG et al. Seven-to 20-year outcome of lumbar discectomy. *Spine* 1999; 24:2313-2317.
65. Crock HV. Observation on the management of failed spinal operations. *J Bone Joint Surg* 1976; 58:193-199.
66. Greenwood J, McGuire TH, Kimbell F. A study of the causes of failure in the herniated intervertebral disc operation: An analysis of sixty-seven reoperated cases. *J Neurosurg* 1952; 9:15-20.
67. Barrios C, Ahmed M, Arrotegui JI et al. Clinical factors predicting outcome after surgery for herniated lumbar disc: An epidemiological multivariate analysis. *J Spinal Disord* 1990; 3:205-209.

68. Matsui H, Terahata N, Tsuji H et al. Familial predisposition and clustering for juvenile lumbar disc herniation. *Spine* 1992; 17:1323-1328.
69. Pheasant HC. Sources of failure in laminectomies. *Orthop Clin North Am* 1975; 6:319-329.
70. Connolly ES. Surgery for recurrent lumbar disc herniation. *Clin Neurosurg* 1992; 39:211-216.
71. Fandino J, Botana C, Viladrich A et al. Reoperation after lumbar disc surgery: Results in 130 cases. *Acta Neurochir Wien* 1993; 122:102-104.
72. Jackson RK. The long-term effects of wide laminectomy for lumbar disc excision: A review of 130 patients. *J Bone Joint Surgery* 1971; 53:609-616.
73. Jönsson B, Stromqvist B. Repeat decompression of lumbar nerve roots: A prospective two-year evaluation. *J Bone Joint Surg* 1993; 75:894-897.
74. Thomalske G, Galow W, Ploke G. Critical comments on a comparison of two series (1000 patients each) of lumbar disc surgery. *Adv Neurosurg* 1977; 4:22-27.
75. Bernard TN. Repeat lumbar spine surgery: Factors influencing outcome. *Spine* 1993; 18:2196-2200.
76. Ebeling U, Kalbaryck H, Reulen HJ. Microsurgical reoperation following lumbar disc surgery: Timing, surgical findings, and outcomes in 92 patients. *J Neurosurg* 1989; 70:397-404.
77. Epstein JA, Lavine LS, Epstein BS. Recurrent herniation of the lumbar intervertebral disc. *Clin Orthop* 1967; 52:169-178.
78. O'Sullivan MG, Connolly AE, Buckley TF. Recurrent lumbar disc protrusion. *Br J Neurosurg* 1990; 4:319-325.
79. Barr JS, Kubik CS, Molloy MK et al. Evaluation of end results in treatment of ruptured lumbar intervertebral discs with protrusion of nucleus pulposus. *Surg Gynec and Obstet* 1967; 125:250-256.
80. Frymoyer JW, Hanley EN, Howe J et al. Disc excision and spine fusion in the management of lumbar disc disease. A minimum ten-year follow-up. *Spine* 1978; 3:1-6.
81. Mannismaki P, Vanharanta H, Puranen J. Disability 20-30 years after disc surgery. A follow-up of 162 patients. *Presented at the Annual Meeting of the International Society for the Study of the Lumbar Spine, Marseilles, June 15-19, 1993.*
82. Naylor A. Late results of laminectomy for lumbar disc prolapse. A review after ten to twenty-five years. *J Bone Joint Surg* 1974; 56:17-29.
83. Salenius P, Laurent LE. Results of operative treatment of lumbar disc herniation. A survey of 886 patients. *Acta Orthop Scand* 1977; 48:630-634.
84. Davis RA. A long-term outcome analysis of 984 surgically treated herniated lumbar discs. *J Neurosurg* 1994; 80:415-421.
85. Dvorak J, Gauchat MH, Valach L. The outcome of surgery for lumbar disc herniation. A 4 to 17-year follow-up with emphasis on somatic aspects. *Spine* 1988; 13:1418-1422.
86. Nashold BS Jr., Blaine S, Hrubec Z. *Lumbar Disc Disease. A Twenty-Year Clinical Follow-up Study.* C.V. Mosby Co., St. Louis, 1971.
87. O'Connell JEA. Protrusions of the lumbar intervertebral discs. A clinical review based on five hundred cases treated by excision of the protrusion. *J Bone Joint Surg* 1951; 33:8-30.
88. Shannon N, Paul EA. L4/5 and L5/S1 disc protrusions: Analysis of 323 cases operated on over 12 years. *J Neurol Neurosurg Psychiatry* 1979; 42:804-809.
89. Spangfort EV. The lumbar disc herniation: A computer aided analysis of 2,504 operations. *Acta Orthop Scand* 1972; 142(Suppl):1-95.
90. Waddell G, Reilly S, Torsney B et al. Assessment of the outcome of low back surgery. *J Bone Joint Surg* 1988; 70:723-727.
91. Weber H. Lumbar disc herniation. A controlled, prospective study with ten years of observation. *Spine* 1983; 8:131-140.
92. Deyo RA, Cherkin DC, Loeser JD et al. Morbidity and mortality in association with operations on the lumbar spine. *J Bone Joint Surg* 1992; 74A:536-544.
93. Rosenstein C, Hardy RW Jr. Repeat operations for lumbar disc. In Hardy RW Jr. (ed). *Lumbar Disc Disease*, Second edition. Raven Press, New York, 1993, pp 171-177.
94. Korres DS, Loupassis G, Stamos K. Results of lumbar discectomy: A study using 15 different evaluation methods. *Eur Spine J* 1992; 1:20-24.
95. Kelley JH, Voris DC, Svien HJ et al. Multiple operations for protruded intervertebral disc. *Proc Staff Meet Mayo Clin* 1954; 29:546-550.
96. Boccanera L, Davalli C, Laus M. Multiple operations on the lumbar spine: A study of 15 patients operated on 3 times or more for an initial diagnosis of prolapsed disc. *Ital J Orthop Traumatol* 1984; 10:321-331.
97. Finnegan WJ, Fenlin JM, Marvel JP et al. Results of surgical intervention in the symptomatic multiply-operated back patient. *J Bone Joint Surg* 1979; 61:1077-1082.
98. Lehmann TR, LaRocca HS. Repeat lumbar surgery: A review of patients with failure from previous lumbar surgery treated by spinal canal exploration and lumbar spinal fusion. *Spine* 1981; 6:615-619.
99. Stauffer RN, Coventry MB. A rational approach to failures of lumbar disc surgery: The orthopedist's approach. *Orthop Clin North Am* 1971; 2:533-542.
100. Weir BKA, Jacobs GA. Reoperation rate following lumbar discectomy: An analysis of 662 lumbar discectomies. *Spine* 1980; 5:366-370.
101. Herno A, Airaksinen O, Saari T. Long-term results of surgical treatment of lumbar spinal stenosis. *Spine* 1993; 11:1471-1474.
102. Pappas CT, Harrington T, Sonntag VK. Outcome analysis in 654 surgically treated lumbar disc herniations. *Neurosurgery* 1992; 30:862-866.

103. Anderson S. A rationale for the treatment algorithm of failed back surgery syndrome. *Curr Rev Pain* 2000; 4:395-406.
104. Pasquier NM, Leri D. Injection-intra-et extraudrales de cocaine a dose minime dans le traitement de la sciatique. *Bull Gen Ther* 1901; 142:196.
105. Caussade G, Queste P. Traitement de al neuralgia sciatique par la methode de Sicard. Resultats favorables même dans les cas chroniques par la cocaïne à doses élevées et répétées à intervalles rapprochés. *Bull Soc Med Hosp Paris* 1909; 28:865.
106. Sicard JA, Forestier J. Méthode radiographique d'exploration de la cavité épidurale par le Lipiodol. *Rev Neurol* 1921; 28:1264-1266.
107. Ombregt L, Ter Veer HJ. Treatment of the lumbar spine. In Ombregt L, Bisschop P, Ter Veer HJ et al (eds). *A System of Orthopaedic Medicine*. WB Saunders, London, 1995, pp 633-688.
108. Brown JH. Pressure caudal anesthesia and back manipulation. *Northwest Med* 1960; 59: 905-909.
109. Racz GB, Holubec JT. Lysis of adhesions in the epidural space. In Racz GB (ed). *Techniques of Neurolysis*. Kluwer Academic, Boston, 1989, pp 57-72.
110. Racz GB, Sabonghy M, Gintautas J et al. Intractable pain therapy using a new epidural catheter. *JAMA* 1982; 248: 579-581.
111. Racz GB, Haynsworth RF, Lipton S. Experiences with an improved epidural catheter. *Pain Clinic* 1986; 1:21-27.
112. Racz GB, Heavner JE, Raj PP. Percutaneous epidural neuroplasty. Prospective one-year follow up. *Pain Digest* 1999; 9:97-102.
113. Heavner JE, Racz GB, Raj P. Percutaneous epidural neuroplasty. Prospective evaluation of 0.9% NaCl versus 10% NaCl with or without hyaluronidase. *Reg Anesth Pain Med* 1999; 24:202-207.
114. Manchikanti L, Pakanati R, Bakhit CE et al. Role of adhesiolysis and hypertonic saline neurolysis in management of low back pain. Evaluation of modification of Racz protocol. *Pain Digest* 1999; 9:91-96.
115. Racz GB, Heavner JE, Raj PP. Epidural neuroplasty. *Seminars in Anesthesia* 1997; 302-312.
116. Manchikanti L, Bakhit CE. Percutaneous lysis of epidural adhesions. *Pain Physician* 2000; 3:46-64.
117. Manchikanti L, Pampati V, Fellows B et al. Role of one day epidural adhesiolysis in management of chronic low back pain: A randomized clinical trial. *Pain Physician* 2001; 4:153-166.
118. Lou L, Racz G, Heavner J. Percutaneous epidural neuroplasty. In Waldman SD (ed) *Interventional Pain Management*, Second Edition, W.B. Saunders Company, Philadelphia, 2000, pp 434-445.
119. Saberski L, Brull S. Spinal and epidural endoscopy: A historical review. *Yale J Bio Med* 1995; 68:7-15.
120. Saberski LR. Spinal endoscopy current concepts. In Waldman SD (ed) *Interventional Pain Management*, Second Edition, W.B. Saunders Company, Philadelphia, 2000, pp 143-161.
121. Burman MS. Myelography or the direct visualization of the spinal cord. *J Bone Joint Surg* 1931; 13:695-696.
122. Shimoji K, Fujoka H, Onodera M et al. Observation of spinal canal and cisternae with the newly developed small-diameter, flexible fiberscopes. *Anesthesiology* 1991; 75:341-344.
123. Stern EL. The spinascope: A new instrument for visualizing the spinal canal and its contents. *Medical Record* (NY) 1936; 143:31-32.
124. Pool JL. Direct visualization of dorsal nerve roots of the cauda equina by means of a myeloscope. *Arch Neurol* 1938; 39:1308-1312.
125. Pool JL. Myelography: Diagnostic inspection of the cauda equina by means of an endoscope. *Bull Neurol Inst*. 1938; 7:178-189.
126. Pool JL. Myelography: Intraspinous endoscopy. *Surgery* 1942; 11:169-182.
127. Ooi Y, Morisaki N. Intrathecal lumbar endoscope. *Clin Orthopedic Surgery* (Japan) 1969; 4:295-297.
128. Ooi Y, Satoh Y, Morisaki N. Myelography. *Igakuno Ayumi* (Japan) 1972; 81:209-212.
129. Ooi Y, Satoh Y, Morisaki N. Myelography. *Orthop Surg* (Japan) 1973; 24:181-186.
130. Ooi Y, Satoh Y, Morisaki N. Myelography: Possibility of observing lumbar intrathecal space by use of an endoscope. *Endoscopy* 1973; 5:91-96.
131. Ooi Y, Satoh Y, Morisaki N. Myelography: A preliminary report. *J. Japan. Orthop Assoc* 1973; 47:619-627.
132. Ooi Y, Satoh Y, Morisaki N. Myelography. *Int. Orthop* 1977; 1:107-111.
133. Ooi Y, Satoh Y, Hirose K et al. Myelography. *Acta Orthop Belg* 1978; 44:881-894.
134. Satoh Y, Hirose K, Ooi Y et al. Myelography in the diagnosis of low back pain syndrome. *Proceedings of Third Congress of International Rehabilitation Medicine Assoc*, Basel, Switzerland, July 2-9, 1978.
135. Ooi Y, Satoh Y, Inoue K et al. Myelography with special reference to blood flow changes in the cauda equina during Lasegue's test. *Int Orthop* 1981; 4:307-311.
136. Blomberg RG. A method of epiduroscopy and spinaloscopy: Presentation of preliminary results. *Acta Anaesthesiol Scand* 1985; 29:113-116.
137. Blomberg RG, Olsson SS. The lumbar epidural space in patients examined with epiduroscopy. *Anesth Analg* 1989; 68:157-160.
138. Blomberg RG. Technical advantages of the paramedian approach for lumbar epidural puncture and catheter introduction. A study using epiduroscopy in autopsy subjects. *Anaesthesia* 1988; 43:837-843.
139. Heavner JE, Cholkhavatia S, Kizelshteyn G. Percutaneous evaluation of the epidural and subarachnoid space with the flexible fiberscope. *Reg Anesth* 1991; 15S1:85.

140. Heavner J, Chokhavatia K, McDaniel K et al. Diagnostic and therapeutic maneuvers in the epidural space via a flexible endoscope (abstract 1534). In *Abstracts of the Seventh World Congress on Pain*, Paris (Raven Press), August 1993.
141. Saberski L, Kitahata L. Direct visualization of the lumbosacral epidural space through the sacral hiatus. *Anesth Analg* 1995; 80:839-840.
142. Saberski L, Kitahata L. Review of the clinical basis and protocol for epidural endoscopy. *Connecticut Medicine* 1996; 60:71-73.
143. Saberski L, Kitahata L. Persistent radiculopathy diagnosed and treated with epidural endoscopy. *J Anesth* 1996; 10:292-295.
144. Saberski L. A retrospective analysis of spinal canal endoscopy and laminectomy outcomes data. *Pain Physician* 2000; 3:193-196.
145. Manchikanti L, Pampati V, Bakhit CE et al. Non-endoscopic and endoscopic adhesiolysis in post lumbar laminectomy syndrome: A one-year outcome study and cost effective analysis. *Pain Physician* 1999; 2:52-58.
146. Manchikanti L. The value and safety of epidural endoscopic adhesiolysis. *Amer J Anesthesiol* 2000; 275-278.
147. Choi YK, Tan MH, Barbella JD et al. Epiduroscopic analysis of persistent back and leg pain and the efficacy of epiduroscopy in the treatment of failed back pain syndrome. *Reg Anesth Pain Med* 2001; 26:90.
148. Shutse G, Kurtse G, Grol O et al. Endoscopic method for the diagnosis and treatment of spinal pain syndromes. *Anesteziol Reanimatol* 1996; 4:62-64.
149. Witte H, Hellweg S, Witte B et al. Epiduroscopy with access via the sacral canal. Some constructional equipment requirements from the anatomic and biomechanical viewpoint. *Biomed Tech* 1997; 42:24-29.
150. Richardson J, McGurgan P, Cheema S et al. Spinal endoscopy in chronic low back pain with radiculopathy: A prospective case series. *Anaesthesia* 2001; 56:454-460.
151. LaRocca H, Macnab I. The laminectomy membrane: Studies in its evolution, characteristics, effects and prophylaxis in dogs. *J Bone Joint Surg* 1974; 56:545-550.
152. McCarron RF, Wimpee MW, Hudkins PG et al. The inflammatory effect of the nucleus pulposus. A possible element in the pathogenesis of low back pain. *Spine* 1987; 12:760-764.
153. McCarron RF. Epidural fibrosis: Experimental model and therapeutic alternatives. In Racz GB (ed). *Techniques of Neurolysis*. Kluwer Academic Publishers, Boston, 1989, pp 87-94.
154. Dahmen G. Rezidivoperationen nach Nucleotomie. Bericht über ein Kolloquium. In Schöllner D (ed). *Rezidive nach Lumbalen Bandscheibenoperationen: Ursachen, Diagnostik, Behandlung*. Medizinische Literarische Verlags Gesellschaft, Uelzen, Germany 1980, pp70-72.
155. Keyl W, Wirth CJ. Indikation, Technik und Ergebnisse der Operationen bei Nucleusrezidiven. In Schöllner D (ed). *Rezidive nach lumbalen Bandscheibenoperationen: Ursachen, Diagnostik, Behandlung*. Medizinische Literarische Verlags Gesellschaft, Uelzen, Germany 1980, pp 70-72.
156. Krämer J. *Bandscheibenbedingte Erkrankungen: Ursachen, Diagnose, Behandlung, Vorbeugung, Begutachtung*, Second edition. Stuttgart, Thieme, 1986.
157. Pawl RP. Arachnoiditis and epidural fibrosis: The relationship to chronic pain. *Curr Rev of Pain* 1998; 2:93-99.
158. Van Goethem JW, Van de Kelft E, Biltjes IG et al. MRI after successful lumbar discectomy. *Neuroradiology* 1996; 38:S90-96.
159. Grave P, Tullberg T, Rydberg J et al. Postoperative lumbar magnetic resonance imaging with contrast enhancement: Compression between symptomatic and asymptomatic patients. *Acta Radiol* 1996; 37:366-372.
160. Annertz M, Jönsson B, Stromquist B et al. No relationship between epidural fibrosis and sciatica in the lumbar postdiscectomy syndrome: A study with contrast-enhancement magnetic resonance imagery in symptomatic and asymptomatic patients. *Spine* 1995; 20:449-453.
161. Cervellini P, Curri D, Volpin L et al. Computed tomography of epidural fibrosis after discectomy. A comparison between symptomatic and asymptomatic patients. *Neurosurgery* 1988; 6:710-713.
162. Songer M, Ghosh L, Spencer D. Effects of sodium hyaluronate on peridural fibrosis after lumbar laminectomy and discectomy. *Spine* 1990; 15:550-554.
163. Cooper R, Freemont A, Hoyland J et al. Herniated intervertebral disc-associated periradicular fibrosis and vascular abnormalities occur without inflammatory cell infiltration. *Spine* 1995; 20:591-598.
164. Manchikanti L, Bakhit CE, Pampati V. Role of epidurography in caudal neuroplasty. *Pain Digest* 1998; 8:277-281.
165. Olmarker K, Rydevik B. Selective inhibition of tumor necrosis factor- α prevents nucleus pulposus-induced thrombus formation, intraneural edema, and reduction of nerve conduction velocity. *Spine* 2001; 26:863-869.
166. Olmarker K, Rydevik B, Holm B et al. Effects of experimental graded compression on blood flow in spinal nerve roots: A vital microscopic study on the porcine cauda equina. *J Orthop Res* 1989; 7:817-823.
167. Cook SD, Prewett AB, Dalton JE et al. Reduction in perineural scar formation after laminectomy with Polyactive[®] membrane sheets. *Spine* 1994; 19:1815-1825.
168. Manchikanti L. Transforaminal lumbar epidural steroid injections. *Pain Physician* 2000; 3:374-398.

169. Saal JS, Franson RC, Dobrow R et al. High levels of inflammatory phospholipase A2 activity in lumbar disc herniations. *Spine* 1990; 15:674-678.
170. Kayama S, Konno S, Olmarker K et al. Incision of the annulus fibrosus induces nerve root morphologic, vascular, and functional changes. *Spine* 1996;21:2539-2543.
171. Chaoyang C, Cavanaugh JM, Ozaktay C et al. Effects of phospholipase A₂ on lumbar nerve root structure and function. *Spine* 1997;22:1057-1064.
172. Bobechko WT, Hirsch C. Autoimmune response to nucleus pulposus in the rabbit. *J Bone Joint Surg* 1965; 47B:574-580.
173. Elves MW, Bucknill T, Sullivan MF. In vitro inhibition of leucocyte migration in patients with intervertebral disc lesions. *Orthop Clin North Am* 1975; 6:59-65.
174. Gertzbein SD. Degenerative disk disease of the lumbar spine: Immunological implications. *Clin Orthop* 1977; 129:68-71.
175. Gertzbein SD, Tait JH, Devlin SR. The stimulation of lymphocytes by nucleus pulposus in patients with degenerative disk disease of the lumbar spine. *Clin Orthop* 1977; 123:149-154.
176. Gertzbein SD, Tile M, Gross A. Autoimmunity in degenerative disc disease of the lumbar spine. *Orthop Clin North Am* 1975;6:67-73.
177. Olmarker K, Blomquist J, Stromberg J et al. Inflammatory properties of nucleus pulposus. *Spine* 1995; 20:665-669.
178. Cavanaugh JM, Ozaktay AC, Vaidyanathan S. Mechano- and chemosensitivity of lumbar dorsal roots and dorsal root ganglia: An in vitro study. *Trans Orthop Res Soc* 1994; 19:109.
179. Kawakami M, Weinstein JN, Tamaki, et al. The difference in nociceptive potential of the nucleus pulposus and the annulus fibrosus. In Weinstein JN, Gordon SL (eds). *Low Back Pain: A Scientific and Clinical Overview*. American Academy of Orthopaedic Surgeons, Rosemont, IL, 1996, pp 209-213.
180. Kawakami M, Tamaki T, Weinstein JN et al. Pathomechanism of pain-related behavior produced by allografts of intervertebral disc in the rat. *Spine* 1996; 21:2101-2107.
181. Kang JD, Georgescu HI, McIntyre-Larkin L et al. Herniated lumbar intervertebral discs spontaneously produce matrix metalloproteinases, nitric oxide, interleukin-6, and prostaglandin E2. *Spine* 1996; 21: 271-277.
182. Olmarker K, Rydevik B, Nordborg C. Autologous nucleus pulposus induces neurophysiologic and histologic changes in porcine cauda equina nerve roots. *Spine* 1993; 18:1425-1432.
183. Gronblad M, Virri J, Tolonen J et al. A controlled immunohistochemical study of inflammatory cells in disc herniation tissue. *Spine* 1994; 19:2744-2751.
184. Jaffray D, O'Brien JP. Isolated intervertebral disc resorption: A source of mechanical and inflammatory back pain? *Spine* 1986; 11:397-401.
185. Kawakami M, Tamaki T, Hashizume H et al. The role of phospholipase A2 and nitric oxide in pain-related behavior produced by an allograft of intervertebral disc material to the sciatic nerve of the rat. *Spine* 1997; 22:1074-1079.
186. Marshall LL, Trethewie ER, Curtain CC. Chemical radiculitis: A clinical, physiological and immunological study. *Clin Orthop* 1977; 129:61-67.
187. Murphy RW. Nerve roots and spinal nerves in degenerative disk diseases. *Clin Orthop* 1977; 129:46-60.
188. Nygaard OP, Mellgren SI, Osterud B. The inflammatory properties of contained and noncontained lumbar disc herniation. *Spine* 1997; 22:2484-2488.
189. Yabuki S, Kikuchi S, Olmarker K et al. Acute effects of nucleus pulposus on blood flow and endoneurial fluid pressure in rat dorsal root ganglia. *Spine* 1998; 23:2517-2523.
190. Yabuki S, Igarashi T, Kikuchi S. Application of nucleus pulposus to the nerve root simultaneously reduces blood flow in dorsal root ganglion and corresponding hindpaw in the rat. *Spine* 2000; 25:1471-1476.
191. Devor M. Pain arising from the nerve root and the dorsal root ganglia and chronically injured axons: A physiological basis for the radicular pain of nerve root compression. *Pain* 1977; 3:25-41.
192. Olmarker K, Rydevik B, Holm S. Edema formation in spinal nerve roots induced by experimental, graded compression: An experimental study on the pig cauda equina with special reference to differences in effects between rapid and slow onset of compression. *Spine* 1989; 14:569-573.
193. Yoshizawa H, Nakai S, Koboyashi S et al. Intraneurial edema formation as a basic factor in lumbar radiculopathy. In Weinstein JN, Gordon SL (eds). *Low Back Pain: A Scientific and Clinical Overview*. American Academy of Orthopaedic Surgeons, Rosemont, IL 1996, pp 235-246.
194. Yabuki S, Onda A, Kikuchi S et al. Prevention of compartment syndrome in dorsal root ganglia caused by exposure to nucleus pulposus. *Spine* 2001; 26:870-875.
195. Takebayashi T, Cavanaugh J, Ozaktay A et al. Effect of nucleus pulposus on the neural activity of dorsal root ganglion. *Spine* 2001; 26:940-945.
196. Olmarker K. Mechanical and biochemical injury of spinal nerve roots: An experimental perspective. In Weinstein JN, Gordon SL (eds). *Low Back Pain: A Scientific and Clinical Overview*. Rosemont, IL, American Academy of Orthopaedic Surgeons, 1996, pp 215-233.
197. Mixer WJ, Barr JS. Rupture of the intervertebral disc with involvement of the spinal cord. *N Engl J Med* 1934; 211:210-215.

198. Ford LT, Lam RL. The psychiatric aspects of low back pain. *J Bone Joint Surg* 1952; 38:931-932.
199. Barr JS. Low back pain and sciatic pain. *J Bone Joint Surg* 1951; 33:633-649.
200. Mixter WJ, Ayers JB. Herniation or rupture of the intervertebral disc into the spinal canal. *N Engl J Med* 1935; 213:385-395.
201. Barsa JE, Charlton JE. Diagnosis of epidural scarring and its possible contribution to chronic low back pain syndrome. *Pain* 1984; S4:376.
202. Manchikanti L, Pampati V, Baha AG et al. Contribution of facet joints to chronic low back pain in postlumbar laminectomy syndrome: A controlled comparative prevalence evaluation. *Pain Physician* 2001; 4:175-180.
203. Kuslich SD, Ulstrom CL, Michael CJ. The tissue origin of low back pain and sciatica. *Orthop Clin North Am* 1991; 22:181-187.
204. Key JA, Ford LT. Experimental intervertebral disc lesions. *J Bone Joint Surg* 1948; 30:621-630.
205. Imai S, Hukuda S, Maeda T. Dually innervating nociceptive networks in the rat lumbar posterior longitudinal ligaments. *Spine* 1995; 19:2086-2092.
206. Racz GB, Noe C, Heavner JE. Selective spinal injections for lower back pain. *Curr Rev Pain* 1999; 3:333-341.
207. Hatten HP Jr. Lumbar epidurography with metrizamide. *Radiology* 1980; 137:129-136.
208. Roberson GH, Hatten HP Jr, Hesselink JH. Epidurography. Selective catheter technique and review of 53 cases. *Am J Radiol* 1979; 132:787-793.
209. Stewart HD, Quinell RC, Dann N. Epidurography in the management of sciatica. *Br J Rheumatol* 1987; 26:424-429.
210. Devulder J, Lutgarde B, Castille F et al. Relevance of epidurography and epidural adhesiolysis in chronic failed back surgery patients. *Clin J Pain* 1995; 11:147-150.
211. Bogduk N, Christophidis N, Cherry D et al. *Epidural Use of Steroids in the Management of Back Pain. Report of Working Party on Epidural Use of Steroids in the Management of Back Pain.* National Health and Medical Research Council, Canberra, Commonwealth of Australia, 1994, pp 1-76.
212. Manchikanti L, Papanati RR, Pampati V. Comparison of three routes of epidural steroid injections in low back pain. *Pain Digest* 1999; 9:277-285.
213. Hammer M, Doleys D, Chung O. Transforaminal ventral epidural adhesiolysis. *Pain Physician* 2001; 4:273-279
214. Andrade S, Eckman E. Distribution of radiographic contrast media in the epidural space of normal volunteers using a midline transligamentum flavum vs a selective epidural nerve canal injection technique. *ISIS Newsletter* October, 1992; 6-8.
215. Riew KD, Yin Y, Gilula L et al. Can nerve root injection obviate the need for operative treatment of lumbar radicular pain? A prospective, randomized, controlled, double/blind study. *Proceedings of North American Spine Society* 16th Annual Meeting. Chicago, 1999, pp 94-95.
216. Shah R, Vad V, Lutz G et al. Transforaminal epidural injections in lumbar radiculopathy: Prospective randomized trial. *Proceedings of the North American Spine Society*, 15th Annual Meeting New Orleans, 2000, pp 44-45.
217. Krämer J, Ludwig J, Bickert U et al. Lumbar epidural perineural injection: A new technique. *Eur Spine J* 1997; 6:357-361.
218. Slipman CW. Diagnostic nerve root blocks. In Gonzalez EG, Materson RS (eds). *The Nonsurgical Management of Acute Low Back Pain.* Demos vermande, New York 1997; pp 115-122.
219. Concato J, Shah N, Horwitz RI. Randomized, controlled trials, observational studies, and the hierarchy of research designs. *N Engl J Med* 2000; 342:1887-1892.
220. Goossens MEJB, Evers SMAA, Vlaeyen JWS et al. Principles of economic evaluation for interventions of chronic musculoskeletal pain. *Eur J Pain* 1999; 3:343-353.
221. Ferraz MB, Maetzel A, Bombardier C. A summary of economic evaluations published in the field of rheumatology and related disciplines. *Arthritis Rheum* 1997; 40:1587-1593.
222. Goossens MEJB, Evers SMAA. Economic evaluation of back pain interventions. *J Occup Rehab* 1997; 7:15-32.
223. Maetzel A, Ferraz MB, Bombardier C. A review of cost effectiveness analyses in rheumatology and related disciplines. *Curr Opin Rheumatol* 1998; 10:136-140.
224. Ross Davies A, Doyle AT, Lansky D et al. Outcomes assessment in clinical settings: A consensus statement on principles and best practices in project management. *Joint Comm Quality Improvement* 1994; 20:6-16.
225. Malter AD, Larson EB, Urban N et al. Cost effectiveness of lumbar discectomy for the treatment of herniated intervertebral disc. *Spine* 1996; 21:1048-1055.
226. Mueller-Schwefe G, Hassenbusch SJ, Reig E. Cost effectiveness of intrathecal therapy for pain. *Neuromodulation* 1999; 2:77-84.
227. Kuntz K, Snider R, Weinstein J et al. Cost effectiveness of fusion with and without instrumentation for patients with degenerative spondylolisthesis and spinal stenosis. *Spine* 2000; 25: 1132-1139.
228. Guo HR, Tanaka S, Halperin WE et al. Back pain prevalence in US industry and estimates of lost work days. *Am J Public Health* 1999; 89:1029-1035.
229. Manchikanti L, Pampati V, Bakhit CE et al. Effectiveness of lumbar facet joint nerve blocks in chronic low back pain: A randomized clinical trial. *Pain Physician* 2001; 4: 101-117.

230. Hopwood M. Outcomes assessment in pain management. In Abram SE (ed). *Pain Management*. Churchill-Livingstone, Philadelphia, 1998, pp14.1-14.11.
231. Cicala RS, Wright H. Outpatient treatment of patients with chronic pain. Analysis of cost savings. *Clin J Pain* 1989; 5: 223-226.
232. Lave JR, Frank RG, Schulberg HC et al. Cost effectiveness of treatments for major depression in primary care practice. *Arch Gen Psychiatry* 1998; 55:645-651.
233. Chang RW, Pellissier JM, Hazen GB. A cost effectiveness analysis of total hip arthroplasty for osteoarthritis of the hip. *JAMA* 1996; 275:858-865.
234. Wong JB, Sonnenberg FA, Salem DN et al. Myocardial revascularization for chronic stable angina: Analysis of the role of percutaneous transluminal coronary angioplasty based on data available in 1989. *Ann Intern Med* 1990; 113:852-871.
235. Katz DA, Cronenwett JL. The cost effectiveness of early surgery versus watchful waiting in the management of small abdominal aortic aneurysms. *J Vasc Surg* 1994; 19:980-991.
236. Tabandeh H. Intraocular hemorrhages associated with endoscopic spinal surgery. *Am J Ophthalmol* 2000; 129:688-690.
237. Kushner FH, Olson JC. Retinal hemorrhage as a consequence of epidural steroid injection. *Arch Ophthalmol* 1995; 113:309-313.
238. Ling C, Atkinson PL, Munton CG. Bilateral retinal hemorrhages following epidural injection. *Br J Ophthalmol* 1993; 77:316-317.
239. Purdy EP, Ajimal GS. Vision loss after lumbar epidural steroid injection. *Anesth Analg* 1998; 86:119-122.
240. Victory RA, Hassett P, Morrison G. Transient blindness following epidural analgesia. *Anesthesia* 1991; 46:940-941.
241. Clark CJ, Whitwell J. Intraocular hemorrhage after epidural injection. *Brit Med J* 1961; 2:1612-1613.
242. Usubiaga JE, Wikinski JA, Usubiaga LE. Epidural pressure and its relation to spread of anesthetic solution in epidural space. *Anesth Analg* 1967; 46:440-446.
243. Morris DA, Henkind P. Relationship of intracranial, optic-nerve sheath, and retinal hemorrhage. *Am J Ophthalmol* 1967; 64:853-859.
244. Sampath P, Rigamonti D. Spinal epidural abscess: A review of epidemiology, diagnosis, and treatment. *J Spinal Disord* 1999; 12:89-93.
245. Wang LP, Haverberg J, Schmidt JF. Incidence of spinal epidural abscess after epidural analgesia. *Anesthesiology* 1999; 91:1928-1936.
246. Rathmell JP, Garahan MB, Alsofrom GF. Epidural abscess following epidural analgesia. *Reg. Anesth Pain Med* 2000; 25:79-82.
247. Martin RJ, Yuan HA. Neurosurgical care of spinal epidural, subdural, and intramedullary abscesses and arachnoiditis. *Orthop Clin North Am* 1996; 27:125-136.
248. Kuker W, Mull M, Mayfrank L, et al. Epidural spinal infection: Variability of clinical and magnetic resonance imaging findings. *Spine* 1997; 22:544-551.
249. Baker AS, Ojemann RG, Swartz MN et al. Spinal epidural abscess. *N Engl J Med* 1975; 293:463-468.
250. Knight JW, Cordingley JJ, Palazzo MGA. Epidural abscess following epidural steroid and local anaesthetic injection. *Anaesthesia* 1997; 52:576-585.
251. Sharif HS. Role of imaging in the management of spinal infections. *AJR* 1992; 158:1333-1345.
252. DuPen SL, Peterson DG, Williams A et al. Infection during chronic epidural catheterization: Diagnosis and treatment. *Anesthesiology* 1990; 73:905-909.
253. Donovan Post MJ, Sze G, Quencer RM et al. Gadolinium-enhanced MR in spinal infection. *J Computer Assist Tomogr* 1990; 14:721-729.
254. Brookman CA, Rutledge MLC. Epidural abscess: Case report and literature review. *Reg Anesth Pain Med* 2000; 25:428-431.
255. Hlavin ML, Kaminski HJ, Ross JS et al. Spinal epidural abscess: A ten year perspective. *Neurosurgery* 1990; 27:177-184.
256. Darouiche RO, Hamill RJ, Greenberg SB et al. Bacterial spinal epidural abscess. Review of 43 cases and literature survey. *Medicine* 1992; 71:369-385.
257. Mackenzie AR, Laing RBS, Smith CC et al. Spinal epidural abscess: The importance of early diagnosis and treatment. *J Neurol Neurosurg Psychiatry* 1998; 65:209-212.
258. Nussbaum ES, Rigamonti D, Standiford H et al. Spinal epidural abscess: A report of 40 cases and review. *Surg Neurol* 1992; 38:225-231.
259. Sarubbi FA, Vasquez JE. Spinal epidural abscess associated with the use of temporary epidural catheters: Report of two cases and review. *Clin Infec Dis* 1997; 25:1155-1158.
260. Yuste M, Canet J, Garcia M et al. An epidural abscess due to resistant *Staphylococcus aureus* following epidural catheterization. *Anaesthesia* 1997; 52:150-168.
261. Mamourian AC, Dickman CA, Drayer BP et al. Spinal epidural abscess: Three cases following spinal epidural injection demonstrated with magnetic resonance imaging. *Anesthesiology* 1993; 78:204.
262. Strong, WE. Epidural abscess associated with epidural catheterization: A rare event? Report of two cases with markedly delayed presentation. *Anesthesiology* 1991; 74:943.
263. Bromage PR. Spinal extradural abscess: Pursuit of vigilance. *Br J Anaesth* 1993; 70:471-473.
264. Yap KB, Finaly IG. Epidural infection associated with epidural catheterization in a cancer patient with back pain: Case report. *Palliat Med* 1994; 8:251-253.
265. Kaul S, Meena AK, Sundaram C et al. Spinal extradural abscess following local steroid injection. *Neurol*

- India 2000; 48:181-183.
266. Chan ST, Leung S. Spinal epidural abscess following steroid injection for sciatica: Case report. *Spine* 1989; 14:106-108.
267. Goucke CR, Graziotti P. Extradural abscess following local anaesthetic and steroid injection for chronic low back pain. *Brit J Anesth* 1990; 65:427-429.
268. Scott DB, Hibbard BM. Serious non-fatal complications associated with extradural block in obstetric practice. *Br J Anaesth* 1990; 64:537-541.
269. Burstal R, Wegener F, Hayes C et al. Epidural analgesia: Prospective audit of 1062 patients. *Anaesth Intensive Care* 1998; 26:165-172.
270. DeLeon-Casasola OA, Parker B, Lema M et al. Post-operative epidural bupivacaine-morphine therapy: Experience with 4227 surgical cancer patients. *Anesthesiology* 1994; 81:368-375.
271. Lund PC. Peridural anaesthesia -Review of 10,000 cases. *Acta Anaesthesiol Scand* 1962; 6:143-159.
272. Bryers K, Axelrod P, Michael S et al. Infections complicating tunnelled intraspinal catheter systems used to treat chronic pain. *Clin Infect Dis* 1995; 21:403-408.
273. Holt HM, Anderses SS, Andersen O et al. Infections following epidural catheterisation. *J Hosp Infect* 1995; 30:253-260.
274. Hunt JR, Rigor BM, Collins JR. The potential for contamination of continuous epidural catheters. *Anesth Analg* 1977; 56:222-225.
275. Pegues DA, Carr DB, Hopkins CC. Infectious complications associated with temporary epidural catheters. *Clin Infect Dis* 1994; 19:970-972.
276. Darchy B, Forceville X, Bavoux E et al. Clinical and bacteriologic survey of epidural analgesia in patients in the intensive care unit. *Anesthesiology* 1996; 85:988-998.
277. Jakobsen KB, Christensen M-K, Carlsson PS. Extradural anaesthesia for repeated surgical treatment in the presence of infection. *Br J Anaesth* 1995; 75:536-540.
278. Carson D, Wildsmith JAW. The risk of extradural abscess [editorial]. *Br J Anaesth* 1995; 75:520-521.
279. Maslen DR, Jones SR, Crislip MA et al. Spinal epidural abscess. Optimising patient care. *Arch Intern Med* 1993; 153:1713-1721.
280. Tacconi L, Johnston FG, Symon L. Spinal epidural abscess-review of 10 cases. *Acta Neurochir* 1996; 138:520-523.
281. Del Curling O, Gower DJ, McWhorter JM. Changing concepts in spinal epidural abscess: A report of 29 cases. *Neurosurgery* 1990; 27:185-192.
282. Heusner AP. Nontuberculous spinal epidural infections. *N Engl J Med* 1948; 239:845-854.
283. Hancock DO. A study of 49 patients with acute spinal extradural abscess. *Paraplegia* 1973; 10:285-288.
284. Danner RL, Hartman BJ. Update of spinal epidural abscess: 35 cases and review of the literature. *Rev Infect Dis* 1987; 9:265-274.
285. Bromage PR. Complications and contraindications. In Bromage PR (ed). *Epidural Analgesia*. WB Saunders, Philadelphia, 1978, pp 469-471.
286. Bromage PR, Benumof JL. Paraplegia following intracord injection during attempted epidural anaesthesia under general anaesthesia. *Reg Anesth Pain Med* 1998; 23:104-107.
287. Horlocker TT, Wedel DJ. Neurologic complications of spinal and epidural anaesthesia. *Reg Anesth Pain Med* 2000; 25:83-98.
288. Sandhu H, Morley-Fost P, Spadafora S. Epidural hematoma following epidural analgesia in a patient receiving unfractionated heparin for thromboprophylaxis. *Reg Anesth Pain Med* 2000; 25:72-75.
289. Osmani O, Afeiche N, Lakkis S. Paraplegia after epidural anaesthesia in a patient with peripheral vascular disease: Case report and review of the literature with a description of an original technique for hematoma evacuation. *J Spinal Disord* 2000; 13:85-87.
290. Tamburrelli F, Leone A, Pitta L. A rare cause of lumbar radiculopathy: Spinal gas collection. *J Spinal Disord* 2000; 13:451-454.
291. Katz JA, Lukin R, Bridenbaugh PO et al. Subdural intracranial air: An unusual cause of headache after epidural steroid injection. *Anesthesiology* 1991; 74:615.
292. Mateo E, Lopez-Alarcon MD, Moliner S et al. Epidural and subarachnoid pneumocephalus after epidural technique. *Eur J Anesthesiol* 1999; 16:413-17.
293. Demierre B, Ramadan A, Hauser H et al. Radicular compression due to lumbar intraspinal gas pseudocyst: case report. *Neurosurgery* 1988; 22:731-733.
294. Gebarski SS, Gebarski KS, Gabrielson TO et al. Gas as a mass: A symptomatic spinal canalicular collection. *J Computer Assist Tomogr* 1984; 8:145-146.
295. Kumber R, West CGH, Gillespie JE. Gas in a spinal extradural cyst. *J Neurosurg* 1989; 70:486-488.
296. Ricca GF, Robertson JT, Hines RS. Nerve root compression by herniated intradiscal gas. *J Neurosurg* 1990; 72:282-284.
297. Yoshida H, Shinomiya K, Nakai O et al. Lumbar nerve root compression caused by lumbar intraspinal gas. *Spine* 1997; 22:348-351.
298. Kane RE. Neurologic deficits following epidural or spinal anaesthesia. *Anesth Analg* 1981; 60:150-161.
299. Rigler ML, Drasner K, Krejcie TC et al. Cauda equina syndrome after continuous spinal anaesthesia. *Anesth Analg* 1991; 72:275-281.
300. Lisai P, Doria C, Crissantu L et al. Cauda equina syndrome secondary to idiopathic spinal epidural lipomatosis. *Spine* 2001; 26:307-309.
301. Olmarker K, Byrod G, Cornefjord M et al. Effects of methylprednisolone on nucleus pulposus-induced nerve root injury. *Spine* 1994; 19:1803-1808.
302. Hayashi N, Weinstein JN, Meller ST et al. The effect of epidural injection of betamethasone or bupivacaine

- in a rat model of lumbar radiculopathy. *Spine* 1998; 23:877-885.
303. Minamide A, Tamaki T, Hashizume H et al. Effects of steroids and lipopolysaccharide on spontaneous resorption of herniated intervertebral discs. An experience study in the rabbit. *Spine* 1998; 23:870-876.
304. Kingery WS, Castellote JM, Maze M. Methylprednisolone prevents the development of autotomy and neuropathic edema in rats, but has no effect on nociceptive thresholds. *Pain* 1999; 80:555-566.
305. Johansson A, Bennett GJ. Effect of local methylprednisolone on pain in a nerve injury model. A pilot study. *Reg Anesth* 1997; 22:59-65.
306. Kepes ER, Duncalf D. Treatment of backache with spinal injections of local anesthetics, spinal and systemic steroids. A review. *Pain* 1985; 22:33-47.
307. Tanner JA. Epidural injections. A new survey of complications and analysis of the literature. *J Orthop Med* 1996; 18:78-82.
308. Delaney TJ, Rowlingson JC, Carron H et al. Epidural steroid effects on nerves and meninges. *Anesth Analg* 1980; 58:610-614.
309. Cicala RS, Turner R, Moran E et al. Methylprednisolone acetate does not cause inflammatory changes in the epidural space. *Anesthesiology* 1990; 72:556-558.
310. MacKinnon SE, Hudson AR, Gentilli R et al. Peripheral nerve injection injury with steroid agents. *Plast Reconstr Surg* 1982; 69:482-489.
311. Chino N, Awad EA, Kottke FJ. Pathology of propylene glycol administered by perineural and intramuscular injection in rats. *Arch Phys Med Rehab* 1974; 55:33-38.
312. Benzon HT, Gissen AJ, Strichartz GR et al. The effect of polyethylene glycol on mammalian nerve impulses. *Anesth Analg* 1987; 66:553-559.
313. Abram SE, Marsala M, Yaksh TL. Analgesic and neurotoxic effects of intrathecal corticosteroids in rats. *Anesthesiology* 1994; 81:1198-1205.
314. Latham JM, Fraser RD, Moore RJ et al. The pathologic effects of intrathecal betamethasone. *Spine* 1997; 22:1558-1562.
315. Slucky AV, Sacks MS, Pallares VS et al. Effects of epidural steroids on lumbar dura material properties. *J Spinal Disord* 1999; 12:331-340.
316. Manchikanti L. The value and safety of steroids in neural blockade. Part I. *AJPM* 2000; 10:69-78.
317. Manchikanti L. The value and safety of steroids in neural blockade. Part II. *American Journal of Pain Management* 2000; 10:122-134.
318. Knight CL, Burnell JC. Systemic side-effects of extradural steroids. *Anesthesia* 1980; 35: 593-594.
319. Edmonds JC, Vance ML, Hughes JM. Morbidity from paraspinal depo corticosteroid injections for analgesia. Cushing's syndrome and adrenal suppression. *Anesth Analg* 1991; 72:820-822.
320. Manchikanti L, Pampati V, Beyer C et al. The effect of neuraxial steroids on weight and bone mass density: A prospective evaluation. *Pain Physician* 2000; 3:357-366.
321. Bogduk N.. Nerves of the lumbar spine. In *Clinical Anatomy of the Lumbar Spine and Sacrum*. Churchill Livingstone, New York, 1997, pp127-143.
322. Parkin IG, Harrison GR. The topographical anatomy of lumbar epidural space. *J Anat* 1985; 141:211-217.
323. Wiltse LL, Fonesca AS, Amster J et al. Relationship of the dura, Hoffman's ligaments, Batson's plexus, and a fibrovascular membrane lying on the posterior surface of the vertebral bodies and attaching to the deep layer of the posterior longitudinal ligament: An anatomical, radiologic, and clinical study. *Spine* 1993; 18:1030-1043.