

Comprehensive Review

Is Genicular Nerve Radiofrequency Ablation Safe? A Literature Review and Anatomical Study

Soo Yeon Kim, MD^{1,2}, Phuong Uyen Le, DO^{1,2}, Boleslav Kosharskyy, MD^{1,2}, Alan D. Kaye, MD, PhD³, Naum Shaparin, MD^{1,2}, and Sherry A. Downie, PhD²

From: ¹Montefiore Medical Center, Bronx, NY; ²Albert Einstein College of Medicine, Bronx, NY; ³Louisiana State University School of Medicine, New Orleans, LA

Address Correspondence:
Phuong Uyen Le, DO
Montefiore Medical Center
Physical Medicine and Rehabilitation
150 E 210th Street
2nd floor
Bronx, NY 10467
E-mail:
ple@montefiore.org

Disclaimer: There was no external funding in the preparation of this manuscript. Conflict of interest: Each author certifies that he or she, or a member of his or her immediate family, has no commercial association (i.e., consultancies, stock ownership, equity interest, patent/licensing arrangements, etc.) that might pose a conflict of interest in connection with the submitted manuscript.

Manuscript received: 09-19-2015
Revised manuscript received: 12-07-2015
Accepted for publication:
01-05-2016

Free full manuscript:
www.painphysicianjournal.com

Genicular nerve radiofrequency ablation (RFA) has recently gained popularity as an intervention for chronic knee pain in patients who have failed other conservative or surgical treatments. Long-term efficacy and adverse events are still largely unknown. Under fluoroscopic guidance, thermal RFA targets the lateral superior, medial superior, and medial inferior genicular nerves, which run in close proximity to the genicular arteries that play a crucial role in supplying the distal femur, knee joint, meniscus, and patella. RFA targets nerves by relying on bony landmarks, but fails to provide visualization of vascular structures. Although vascular injuries after genicular nerve RFA have not been reported, genicular vascular complications are well documented in the surgical literature. This article describes the anatomy, including detailed cadaveric dissections and schematic drawings, of the genicular neurovascular bundle. The present investigation also included a comprehensive literature review of genicular vascular injuries involving those arteries which lie near the targets of genicular nerve RFA. These adverse vascular events are documented in the literature as case reports. Of the 27 cases analyzed, 25.9% (7/27) involved the lateral superior genicular artery, 40.7% (11/27) involved the medial superior genicular artery, and 33.3% (9/27) involved the medial inferior genicular artery. Most often, these vascular injuries result in the formation of pseudoaneurysm, arteriovenous fistula (AVF), hemarthrosis, and/or osteonecrosis of the patella. Although rare, these complications carry significant morbidities. Based on the detailed dissections and review of the literature, our investigation suggests that vascular injury is a possible risk of genicular RFA. Lastly, recommendations are offered to minimize potential iatrogenic complications.

Key words: Genicular nerve, genicular artery, radiofrequency ablation, genicular vascular injury, knee osteoarthritis, patella injury

Pain Physician 2016; 19:E697-E705

In the elderly population, e.g., 60 years and older, approximately 13% of women and 10% of men experience symptomatic knee osteoarthritis (OA) (1). Conservative treatments include physical therapy, analgesic medications, and intra-articular injection of steroid and visco-supplementation. In 2011, Choi et al (2) introduced a novel technique to alleviate chronic pain resulting from knee OA. The procedure involves an ablation of the lateral superior, medial superior, and medial inferior genicular nerves utilizing radiofrequency

under fluoroscopic guidance. Significant improvement in pain and function was noted in all patients (N = 19) who received the treatment and no adverse events were reported (2).

Thermal radiofrequency ablation (RFA) targets nerves using bony landmarks (Fig. 1), but fails to provide visualization of vascular structures. Genicular nerves run in close proximity to genicular arteries that play a crucial role in supplying the distal femur, knee joint (3), meniscus (4), and patella (5). Even though no

complications of genicular nerve RFA have been reported in the literature, complications related to genicular vascular injury have been well described in surgical literature (6-33). Therefore, genicular nerve RFA may cause vascular injury, potentially resulting in pseudoaneurysm, arteriovenous fistula (AVF), hemarthrosis, and osteonecrosis of the patella.

METHODS

Cadaveric Dissections

Dissections were performed on 2 cadavers in residence at the Albert Einstein College of Medicine. These cadavers were intended for educational and research purposes.

Literature Review

The present investigation included a PubMed search using the following terms: knee geniculate artery, pseudoaneurysm knee, vascular injury of the patella. Twenty-seven case reports were identified which detail injury to the superior lateral, superior medial, and medial inferior arteries that were written in the English language. The year the cases were described, the patient's age, type of procedure, type of iatrogenic complication, time to identify the injury after the operation, and procedures necessary to prevent worsening of these complications were reported.

ANATOMY

Geniculate Nerve Anatomy

The nerve network supplying the knee joint is complex. Tributaries from tibial, common peroneal, femoral, and obturator nerves are found around the knee proper (34). The nerves of significance to RFA of the knee include the branches of the common peroneal and tibial nerves. Cadaveric dissections detailing the course of smaller branches of these nerves are scarce. According to Callaghan et al (35), the lateral superior genicular nerve originates from the common peroneal division of the sciatic nerve 8 – 10 cm superior to the joint line. It travels toward the superolateral aspect of the knee capsule deep to the biceps femoris muscle and the iliotibial band. The tibial nerve gives rise to 3 articular branches in the popliteal fossa, 2 of which are located on the medial aspect of the knee joint, and are targets of RFA: the medial superior and medial inferior genicular nerves (35). The lateral superior genicular nerve and the medial superior and medial inferior genicular nerves innervate the articular capsule of the knee joint (36). These nerves were demonstrated to be in close proximity to the lateral superior, medial superior, and medial inferior genicular arteries (Fig. 2). A recent anatomical study of 8 cadavers revealed that although the nerves show variable course proximally, all had a constant distal contact on the femur and tibia (37).

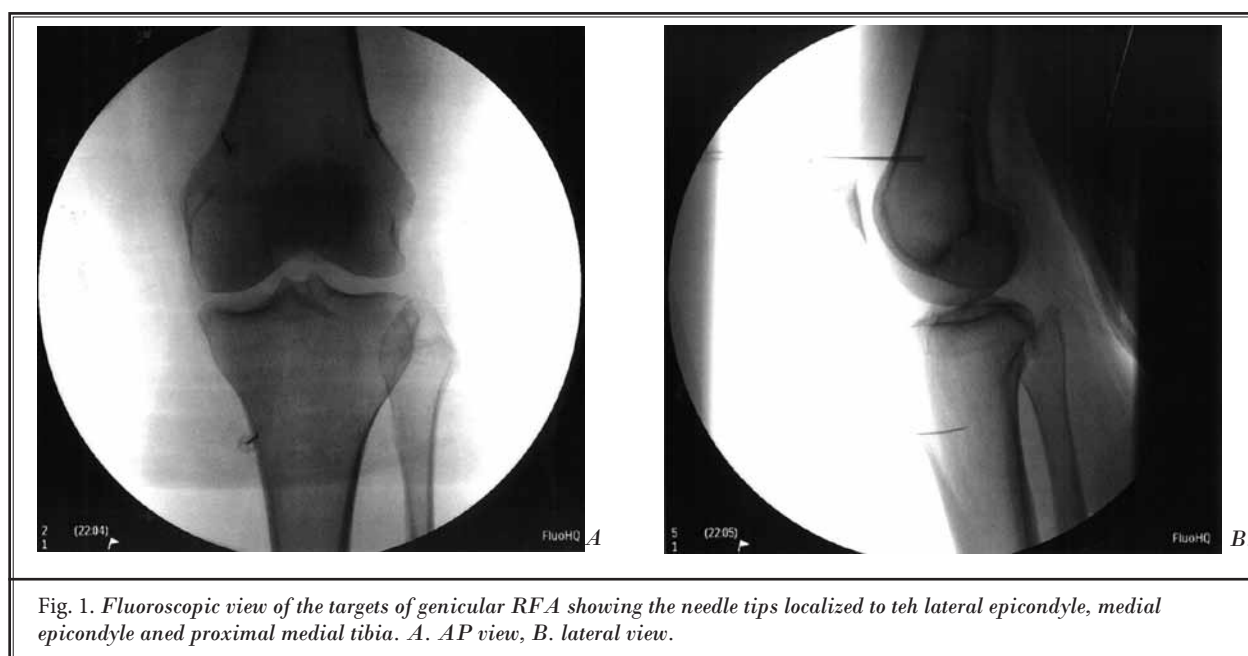


Fig. 1. Fluoroscopic view of the targets of genicular RFA showing the needle tips localized to the lateral epicondyle, medial epicondyle and proximal medial tibia. A. AP view, B. lateral view.

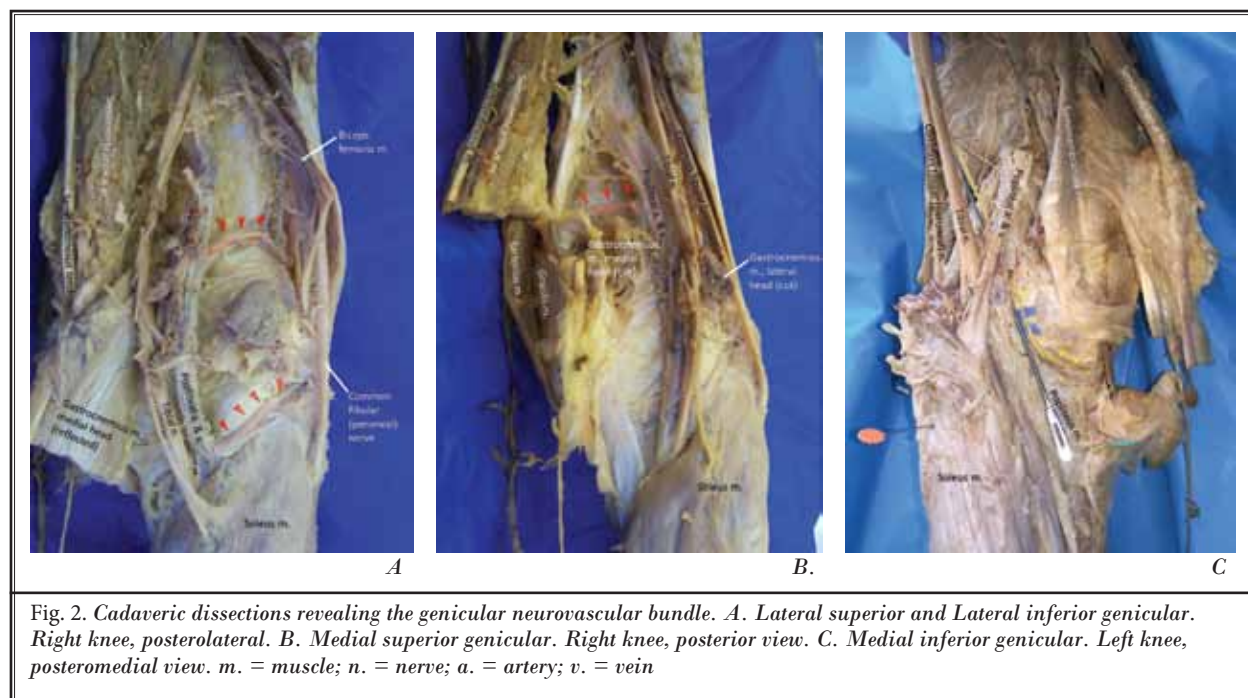


Fig. 2. Cadaveric dissections revealing the genicular neurovascular bundle. A. Lateral superior and Lateral inferior genicular. Right knee, posterolateral. B. Medial superior genicular. Right knee, posterior view. C. Medial inferior genicular. Left knee, posteromedial view. m. = muscle; n. = nerve; a. = artery; v. = vein

Geniculate Artery Anatomy

The arterial supply to the knee is diverse and includes many anatomical variations. At the popliteal fossa, the popliteal artery gives rise to the lateral superior genicular, the medial superior genicular, and the medial inferior genicular arteries (Fig. 3) (35). The lateral superior genicular artery arises proximal to the lateral condyle of the femur, deep to the tendon of the biceps femoris. It provides a superficial branch that supplies the vastus lateralis muscle and anastomoses with the lateral inferior genicular artery (35). Its anastomosis with the descending branch of the lateral circumflex femoral is inconsistent and often inadequate (38). The deep branch of the lateral superior genicular artery supplies the knee joint and anastomoses with the descending genicular and medial superior genicular arteries across the anterior aspect of the femur (35).

The medial superior genicular artery has 2 branches. One branch supplies the vastus medialis muscle and anastomoses with the descending genicular and medial inferior genicular arteries. The other branch supplies the knee joint and anastomoses with the lateral superior genicular artery (35).

The medial inferior genicular artery also gives 2 branches. The first courses along the upper border of the popliteus muscle. On the medial side of the knee, it anastomoses with the descending genicular and medial

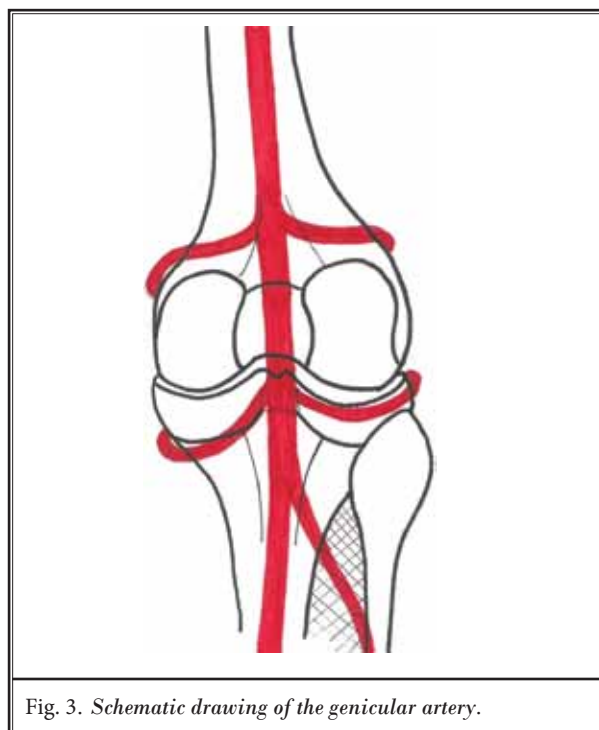


Fig. 3. Schematic drawing of the genicular artery.

superior genicular arteries. The second branch crosses the tibia under the patellar ligament to anastomose with the lateral inferior genicular and the anterior re-

current tibial arteries (35). The medial inferior genicular artery was found in close proximity to the posterior horn of the medial meniscus (7) and supplied the medial meniscus (3).

The patella also receives blood supply from genicular arteries targeted during RFA of the knee. The lateral superior, medial superior, and medial inferior genicular arteries provide significant contribution to the peripatellar ring. The medial superior genicular artery supplies the transverse suprapatella portion of the ring. The lateral transverse portion is partially supplied by the lateral superior genicular artery. The transverse infrapatellar portion of the ring receives partial perfusion from the medial inferior genicular artery (35).

Literature Review of Genicular Vascular Injury

Injuries involving the genicular arteries are uncommon but carry significant morbidities. These adverse vascular events are documented in the literature as case reports. Of the 27 cases analyzed in this investigation, 25.9% (7/27) have involved the lateral superior genicular artery, 40.7% (11/27) have involved the medial superior genicular artery, and 33.3% (9/27) have involved the medial inferior geniculate artery. Most often, these vascular injuries result in the formation of pseudoaneurysm, AVF, hemarthrosis, and/or osteonecrosis of the patella (Table 1, 2, and 3). Pseudoaneurysms are more likely to form from a partially damaged vessel. The blood dissects into the surrounding soft tissues, form-

ing an encapsulated hematoma, which undergoes subsequent organization and endothelialization (16). The pseudoaneurysm can increase in size with increase in systemic blood pressure potentially leading to compression of surrounding structures that can result in distal neurovascular deficit. In addition, rupture may result and this can produce swelling (6), calf pain, and ecchymosis mimicking deep vein thrombosis (12) or acute and recurrent hemarthrosis (11,14). Pseudoaneurysms have been reported to occur after open synovectomy, meniscectomy, arthroscopy, and total knee arthroplasty (TKA).

Lateral Superior Genicular Artery Injury

The present investigation revealed that injury to the superior lateral genicular artery has been reported (Table 1) in 7 cases (6,11,13,14,17,18,25). The injuries have occurred after primary TKA in 4 cases, after TKA revision in 2 cases, and after ligamentous and meniscal arthroscopic repair in one case. The majority of the injuries resulted in pseudoaneurysms; however, a few patients have suffered recurrent hemarthrosis, and one has suffered AVF. Those affected included both men and women with ages ranging from young athlete (age not specified) to 68 years. The time from operation until detection of the injury has ranged from immediate to 36 days. The majority of patients (71%) underwent percutaneous embolization of the lateral superior genicular artery. One patient required 3 operations to stop the bleeding, with the last being an open arthrotomy (14).

Table 1. Case reports of injury to the lateral superior genicular artery.

Year Reported	Age and gender	Procedure	Type(s) of Complication	Time to Identify the Injury Post-operation	Result
2002 (14)	65 M	TKA	Pseudoaneurysm and recurrent hemarthrosis	Immediate	Three operations performed with eventual arthrotomy to tie off the lateral geniculate arteries
2004 (11)	59 M	TKA Revision	Pseudoaneurysm and recurrent hemarthrosis	5 days	Initial evacuation of hemarthrosis followed by percutaneous embolization
2005 (6)	64 M	TKA	Pseudoaneurysm, hematoma and hemarthrosis	6 days	Percutaneous embolization and repeat arthroscopy to drain the hematoma and lavage the joint
2007 (13)	56 M	TKA Revision	Hematoma and pseudoaneurysm	1 week	Percutaneous embolization
2010 (25)	35 F	TKA	Pseudoaneurysm	36 days	Percutaneous embolization
2013 (18)	68 M	TKA	Pseudoaneurysm	4 days	Percutaneous embolization
2015 (17)	-- (young athlete)	Arthroscopic repair of ligament and meniscus	Pseudoaneurysm and AVF	Information not provided	Surgical resection of pseudoaneurysm and ligation of arteriovenous fistula

Table 2. Case reports of injury to the medial superior genicular artery.

Year Reported	Age and gender	Procedure	Type(s) of Complication	Time to Identify Injury Post-operation	Result
1990 (27)	49 M	Arthroscopic meniscectomy	Pseudoaneurysm	1 week	Ultrasound guided compression repair followed by coiled embolization
1995 (26)	19 F	Arthroscopy for excision of synovial plica and joint lavage	Pseudoaneurysm	10 weeks	Surgical resection
1999 (15)	29 F	Arthroscopic synovectomy	Hematoma and Pseudoaneurysm	12 hours	Percutaneous embolization
1997 (19)	32 M	Arthroscopic meniscectomy	Pseudoaneurysm	6 days	Percutaneous embolization
1999 (15)	54 M	TKA	Pseudoaneurysm	1 month	Percutaneous embolization
2007 (13)	63 F	TKA	Pseudoaneurysm	6 weeks	Compression dressing (spontaneous resolution), discontinuation of anticoagulation
2008 (28)	47 M	Arthroscopic synovectomy	Hemarthrosis and pseudoaneurysm	3 months	Selective angiographic embolization
2009 (29)	43 M	Arthroscopic meniscectomy	Pseudoaneurysm and hemarthrosis	8 days	Percutaneous embolization
2011 (30)	45 M	Partial meniscectomy	Hemarthrosis and pseudoaneurysm	3 days	Surgical exploration and excision of pseudoaneurysm and ligation of the medial superior genicular artery
2012 (12)	71 F	TKA	Hematoma and pseudoaneurysm	8 days	Evacuation and exploration and ligation of the medial superior genicular artery
2014 (10)	63 M	TKA	Pseudoaneurysm	2 weeks	Compression dressing (spontaneous resolution), and discontinuation of anticoagulation

Another patient required an initial evacuation of the hematoma followed by embolization (11). One patient had received a repeat arthroscopy and joint lavage in addition to embolization (6). The last patient underwent surgical resection of the pseudoaneurysm and had ligation of the AVF (17). All reported cases of lateral genicular artery injury showed eventual improvement of symptoms after appropriate interventions.

Medial Superior Genicular Artery Injury

The branch of the medial superior genicular artery that pierces the medial intramuscular septum to supply the vastus medialis muscle is easily injured (35). Eleven cases, including hematoma, hemarthrosis, and pseudoaneurysm (Table 2), have been reported in the literature. The procedures not only include TKA but also arthroscopic meniscectomy and arthroscopic synovectomy. Both men and women have been affected with ages ranging from 19 to 71 years. The time to identify

the injury has ranged from 12 hours to 10 weeks. Two cases resolved spontaneously after compression dressing and discontinuation of anticoagulation (10,13), while the other cases required percutaneous embolization (13,15,19,27,28), surgical resection (26,30), or evacuation and ligation of the offending artery (12,30).

Medial Inferior Genicular Artery Injury

Nine case reports have been documented (Table 3) involving the medial inferior genicular artery (7-9,20,21). Surgeries involved were TKA, medial meniscus repair, anterior cruciate ligament (ACL) repair, and intramedullary nailing of the tibia after spiral fracture. Again both men and women were affected with a wide age range (23 – 87 years). The time it required for detection can range from one hour to 2 months. Most cases led to pseudoaneurysm or aneurysm with 2 resulting in concomitant development of AVF. Both of these cases were treated with surgical excision of pseudoa-

Table 3. Case reports of injury to the medial inferior genicular artery.

Year Reported	Age and gender	Procedure	Type(s) of Complication	Time to Identify Injury Post-operation	Result
1987 (8)	73 F	TKA	Pseudoaneurysm and AVF	3 weeks	Surgical excision of pseudoaneurysm, disruption of the arteriovenous fistula and ligation of the medial inferior genicular artery
1987 (8)	67 M	TKA	Pseudoaneurysm and AVF	2 months	Surgical excision of pseudoaneurysm, disruption of the arteriovenous fistula and ligation of the medial inferior genicular artery
1989 (21)	58 F	TKA	Aneurysm	2 months	Percutaneous embolization
1994 (7)	57 F	Arthroscopic resection of posterior horn of medial meniscus	Pseudoaneurysm	1 week	Two operations: 1. Resection of hematoma 2. Removal of pseudoaneurysm and ligation of medial inferior genicular artery
2000 (9)	30 M	ACL repair	Pseudoaneurysm	5 weeks	Open exploration, resection of thrombus and ligation of medial inferior genicular artery
2005 (31)	87 F	TKA	3 recurrent hemorrhagic episodes eroding through the medial skin incision	4 weeks	Exploration and evacuation of the hematoma and ligation of the medial inferior genicular artery
2006 (32)	37 M	ACL reconstruction with hamstring tendon autograft	Pseudoaneurysm	1 hour	Hematoma evacuation and ligation of the medial inferior geniculate artery
2009 (20)	47 M	Closed intramedullary nailing of the tibia	Pseudoaneurysm	A few days	Percutaneous embolization
2011 (33)	23 M	ACL construction	Hemarthrosis and pseudoaneurysm	2 weeks	Percutaneous embolization

neurysm, disruption of the arteriovenous fistula, and ligation of the offending artery (8). Other cases have required percutaneous embolization (20,21,33) or open resection of the hematoma and ligation of the offending artery (7,9,31,32).

Patella Injury

The lateral superior, lateral inferior, and medial inferior genicular arteries provide a significant contribution to the blood supply of the patella. An *in vivo* study examination of patellar blood flow after TKA revealed that lateral release with sacrifice of the superior lateral genicular artery led to a reduction of 30.61% of blood flow to the patella. In this study, the patellar blood supply was also compromised if the medial superior and medial inferior genicular arteries were sacrificed (39). Other studies have shown an increase in patellar avas-

cularity after TKA using the lateral release approach (40,41). Disruption of the blood supply to the patella may lead to avascular necrosis of the patella with the potential consequence of patella fractures (22,42).

Injury to Neighboring Neurovascular Structures

It is important to take into consideration the nerves in close proximity to those targeted by thermal RFA. The saphenous nerve provides sensory innervation to the medial aspect of the leg. Damage to the infrapatellar branch can result in the development of painful neuroma and complex regional pain syndrome (43-45). Therefore, the course of the saphenous nerve, especially the infrapatellar branch of the saphenous nerve, should be considered when performing RFA of nerves in the medial aspect of the knee.

Targeting the lateral superior, medial superior, and medial inferior genicular nerves for RFA may be difficult. The path of the descending artery in the lateral thigh is unpredictable (3); it has at least 5 origins. Its anastomosis at the knee to the genicular arteries is not constant and oftentimes inadequate (38). Thirty-two cadaveric dissections revealed variations in the origin of the osteoarticular and saphenous branches of the femoral artery. In 24 specimens, the descending genicular artery gives rise to the osteoarticular and saphenous branches. In the remaining dissections, they arise directly from the femoral artery. More distally, 9 variations were found with regard to the number and origin of the muscular, musculoarticular, and saphenous branches (3). As arteries travel with nerves in a neurovascular bundle (2), it is likely that genicular nerves may also exhibit a number of anatomical variations around the knee, even though cadaveric studies are lacking. After surgical operations, the path that the nerves take might be unpredictable related to axonal misrouting and aberrant reinnervation (46). Because RFA has been proposed as a treatment for post-TKA knee pain, we need to take into consideration that the path taken by the genicular nerves might vary greatly from individual to individual (47). In addition, the path of the nerves and arteries across joints is often affected by the position of the joint (7). In Choi et al's procedure (2), the knee was positioned in slight flexion by placing a pillow underneath. Therefore, the trajectory of the nerves and arteries may change and targeting the nerves might be difficult. As arteries travel with nerves in a neurovascular bundle, ablating nerves using a bony landmark may not effectively target the nerves of interest and may lead to undesired vascular complications. Injuries to the arteries around the knees, including the descending genicular artery, are not uncommon (20,24).

Discussion

Although large randomized trials of genicular nerve RFA are not available, the procedure has gained popularity among interventionists. As it still is a relatively novel intervention, long-term efficacy and adverse events are still largely lacking at this time. This investigation has attempted to demonstrate the importance of the anatomical proximity of genicular arteries to genicular nerves, variations of the neurovascular bundle, and potential complications resulting from injuries to the genicular vessels. The consequences of injuring adjacent neural and vascular structures, albeit rare in open operations and arthroscopy of the knee,

are not insignificant. Related to the rarity of these conditions, delay in diagnosis may lead to worsening complications, which can contribute to increased morbidity and mortality. Therefore, the interventionist must exercise great care while performing RFA of genicular nerves in order to avoid inadvertently injuring nearby structures, especially vascular structures, leading to iatrogenic complications.

From our detailed dissections, review of the existing anatomical studies and surgical literature, the risk of injury to these vessels is a reasonable possibility. However, it is interesting that no reports have documented these vascular injuries in the literature. It is possible that geniculate vascular injuries do exist in patients receiving RFA but have not been reported at present as the procedure is relatively new. We should also consider the sink effect of blood vessels in proximity to the RFA targets. Due to constant blood flow, the temperature of the targeted area is attenuated (48). Perhaps, this reduction in temperature may lead to a better coagulation effect than if it were by direct needle trauma, and thus vascular injury can be avoided.

Conclusion

After appreciation of the potential risks associated with geniculate RFA, it is crucial to utilize appropriate safety measures to prevent arterial puncture during the procedure. In a case report, Protzman et al (46) performed RFA of genicular nerves under fluoroscopy and also used ultrasound with Doppler function to help identify genicular nerves and the accompanying arteries. This technique needs to be tested on a larger scale, including allowing for visualization of the vasculature and targeted nerves. However, the concurrent use of ultrasound and fluoroscopy may not always be practical. Another technique which may decrease the risk of vascular injury is pulsed RFA. In pulsed RFA, no tissue damage occurs as the temperature is set at a limit of 42 degree Celsius. Pulsed RFA has been described in the treatment of knee OA within the pericapsular nerve endings (49) and the sciatic nerve (50). Long-term efficacy of pulsed RFA of the saphenous nerve has been demonstrated in the treatment of chronic knee pain (51). Recently, pulsed RFA of the entire nerve supply of the knee showed improved functional outcome in patients with knee OA (52). However, pulsed RFA at the level of the lateral superior, medial superior, and medial inferior genicular nerves has not been studied and therefore warrants further evaluation.

REFERENCES

- Zhang Y, Jordan JM. Epidemiology of osteoarthritis. *Clin Geriatr Med* 2010; 26:355-369.
- Choi WJ, Hwang SJ, Song JG, Leem JG, Kang YU, Park PH, Shin JW. Radiofrequency treatment relieves chronic knee osteoarthritis pain: A double-blind randomized controlled trial. *Pain* 2011; 152:481-487.
- Scheibel MT, Schmidt W, Thomas M, von Salis-Sogliano G. A detailed anatomical description of the subvastus region and its clinical relevance for the subvastus approach in total knee arthroplasty. *Surg Radiol Anat* 2002; 24:6-12.
- Day B, Mackenzie WG, Shim SS, Leung G. The vascular and nerve supply of the human meniscus. *Arthroscopy* 1985; 1:58-62.
- Lazaro LE, Cross MB, Lorich DG. Vascular anatomy of the patella: Implications for total knee arthroplasty surgical approaches. *Knee* 2014; 21:655-660.
- Pritsch T, Parnes N, Menachem A. A bleeding pseudoaneurysm of the lateral genicular artery after total knee arthroplasty – a case report. *Acta Orthop* 2005; 76:138-140.
- Bernard M, Grothues-Spork M, Georgoulis A, Hertel P. Neural and vascular complications of arthroscopic meniscal surgery. *Knee Surg Sports Traumatol Arthrosc* 1994; 2:14-18.
- Dennis DA, Neumann RD, Toma P, Rosenberg G, Mallory TH. Arteriovenous fistula with false aneurysm of the inferior medial geniculate artery. A complication of total knee arthroplasty. *Clin Orthop Relat Res* 1987; 222:255-260.
- Evans JD, de Boer MT, Mayor P, Rees D, Guy AJ. Pseudoaneurysm of the medial inferior genicular artery following anterior cruciate ligament reconstruction. *Ann R Coll Surg Engl* 2000; 82:182-184.
- Gaheer RS, Chirputkar K, Sarungi M. Spontaneous resolution of superior medial geniculate artery pseudoaneurysm following total knee arthroplasty. *Knee* 2014; 21:586-588.
- Ibrahim M, Booth RE, Jr., Clark TW. Embolization of traumatic pseudoaneurysms after total knee arthroplasty. *J Arthroplasty* 2004; 19:123-128.
- Julien TP, Gravereaux E, Martin S. Superior medial geniculate artery pseudoaneurysm after primary total knee arthroplasty. *J Arthroplasty* 2012; 27:323.e313-e326.
- Law KY, Cheung KW, Chiu KH, Antonio GE. Pseudoaneurysm of the geniculate artery following total knee arthroplasty: A report of two cases. *J Orthop Surg (Hong Kong)* 2007; 15:386-389.
- Moran M, Hodgkinson J, Tait W. False aneurysm of the superior lateral geniculate artery following total knee replacement. *Knee* 2002; 9:349-351.
- Omary R, Stulberg SD, Vogelzang RL. Therapeutic embolization of false aneurysms of the superior medial genicular artery after operations on the knee. A report of two cases. *J Bone Joint Surg Am* 1991; 73:1257-1259.
- Pai VS. Traumatic aneurysm of the inferior lateral geniculate artery after total knee replacement. *J Arthroplasty* 1999; 14:633-634.
- Saboo SS, Juan YH, Belkin M, Sacks A, Khandelwal A, Steigner ML, Rybicki FJ. Multi-detector CT angiography in case of concomitant pseudoaneurysm and arteriovenous fistula of the lateral superior geniculate artery. *Postgrad Med J* 2014; 90:118-119.
- Saini P, Meena S, Malhotra R, Gamanagatti S, Kumar V, Jain V. Pseudoaneurysm of the superior lateral genicular artery: Case report of a rare complication after total knee arthroplasty. *Patient Saf Surg* 2013; 7:15.
- Sarroso EA, Ogilvie-Harris DJ. Pseudoaneurysm as a complication of knee arthroscopy. *Arthroscopy* 1997; 13:644-645.
- Shaw A, Stephen A, Lund J, Bungay P, Denunzio M. Geniculate arterial pseudoaneurysm formation following trauma and elective orthopaedic surgery to the knee: 2 case reports and a review of the literature. *J Radiol Case Rep* 2009; 3:12-16.
- Stanley D, Cumberland DC, Elson RA. Embolisation for aneurysm after knee replacement: Brief report. *J Bone Joint Surg Br* 1989; 71:138.
- Tria AJ, Jr., Harwood DA, Alicea JA, Cody RP. Patellar fractures in posterior stabilized knee arthroplasties. *Clin Orthop Relat Res* 1994; 229:131-138.
- Tsubosaka M, Matsushita T, Kuroda R, Matsumoto T, Kurosaka M. Pseudoaneurysm of the articular branch of the descending genicular artery following double-bundle anterior cruciate ligament reconstruction. *Knee Surg Sports Traumatol Arthrosc* 2015; 1-4.
- Vincent GM, Stanish WD. False aneurysm after arthroscopic meniscectomy. A report of two cases. *J Bone Joint Surg Am* 1990; 72:770-772.
- Park JJ, Slover JD, Stuchin SA. Recurrent hemarthrosis in a hemophilic patient after revision total knee arthroplasty. *Orthopedics* 2010; 33:771.
- Aldrich D, Anshuetz R, LoPresti C, Fumich M, Pitluk H, O'Brien W. Pseudoaneurysm complicating knee arthroscopy. *Arthroscopy* 1995; 11:229-230.
- Armato DP, Czamecki D. Geniculate artery pseudoaneurysm: A rare complication of arthroscopic surgery. *AJR Am J Roentgenol* 1990; 155:659.
- Becher C, Burger UL, Allenberg JR, Kaufmann GW, Thermann H. Delayed diagnosis of a pseudoaneurysm with recurrent hemarthrosis of the knee joint. *Knee Surg Sports Traumatol Arthrosc* 2008; 16:561-564.
- Lee KB, Song SY, Kwon DJ, Shin J, Paik SH. Pseudoaneurysm of the medial superior genicular artery after arthroscopic partial meniscectomy. *Clin Orthop Surg* 2009; 1:173-175.
- Muftu S, Jr., Smits P, Feyen J. Pseudoaneurysm of the superior medial genicular artery following knee arthroscopy. *Knee Surg Sports Traumatol Arthrosc* 2011; 19:1314-1315.
- Sharma H, Singh GK, Cavanagh SP, Kay D. Pseudoaneurysm of the inferior medial geniculate artery following primary total knee arthroplasty: Delayed presentation with recurrent haemorrhagic episodes. *Knee Surg Sports Traumatol Arthrosc* 2006; 14:153-155.
- Milankov M, Miljkovic N, Stankovic M. Pseudoaneurysm of the medial inferior genicular artery following anterior cruciate ligament reconstruction with hamstring tendon autograft. *Knee* 2006; 13:170-171.
- Mello W, de Brito WE, Migon EZ, Borges A. Pseudoaneurysm of the medial inferior genicular artery after anterior cruciate ligament reconstruction. *Arthroscopy* 2011; 27:442-445.
- Ikeuchi M, Ushida T, Izumi M, Tani T. Percutaneous radiofrequency treatment for refractory anteromedial pain of osteoarthritic knees. *Pain Med* 2011; 12:546-551.
- Callaghan JJ, Rosenberg AG, Rubash HE. Surgical Anatomy of the Knee. In: *The Adult Knee*. Ed: Wasielewski RC. Lippincott Williams & Wilkins, Philadelphia 2003, pp 77-78.

36. Hirasawa Y, Okajima S, Ohta M, Tokio-ka T. Nerve distribution to the human knee joint: Anatomical and immunohistochemical study. *Int Orthop* 2000; 24:1-4.
37. Franco CD, Buvanendran A, Petersohn JD, Menzies RD, Menzies LP. Innervation of the anterior capsule of the human knee: Implications for radiofrequency ablation. *Reg Anesth Pain Med* 2015; 40:363-368.
38. Sabalbal M, Johnson M, McAlister V. Absence of the genicular arterial anastomosis as generally depicted in textbooks. *Ann R Coll Surg Engl* 2013; 95:405-409.
39. Hughes SS, Cammarata A, Steinmann SP, Pellegrini VD, Jr. Effect of standard total knee arthroplasty surgical dissection on human patellar blood flow in vivo: An investigation using laser Doppler flowmetry. *J South Orthop Assoc* 1998; 7:198-204.
40. McMahon MS, Scuderi GR, Glashow JL, Scharf SC, Meltzer LP, Scott WN. Scintigraphic determination of patellar viability after excision of infrapatellar fat pad and/or lateral retinacular release in total knee arthroplasty. *Clin Orthop Relat Res* 1990; 260:10-16.
41. Scuderi G, Scharf SC, Meltzer LP, Scott WN. The relationship of lateral releases to patella viability in total knee arthroplasty. *J Arthroplasty* 1987; 2:209-214.
42. Wetzner SM, Bezreh JS, Scott RD, Bierbaum BE, Newberg AH. Bone scanning in the assessment of patellar viability following knee replacement. *Clin Orthop Relat Res* 1985; 199:215-219.
43. Horner G, Dellon AL. Innervation of the human knee joint and implications for surgery. *Clin Orthop Relat Res* 1994; 301:221-226.
44. Poehling GG, Pollock FE, Jr., Koman LA. Reflex sympathetic dystrophy of the knee after sensory nerve injury. *Arthroscopy* 1988; 4:31-35.
45. Liuzzi FJ, Tedeschi B. Peripheral nerve regeneration. *Neurosurg Clin N Am* 1991; 2:31-42.
46. Protzman NM, Gyi J, Malhotra AD, Kooch JE. Examining the feasibility of radiofrequency treatment for chronic knee pain after total knee arthroplasty. *PM R* 2014; 6:373-376.
47. Masala S, Fiori R, Raguso M, Morini M, Calabria E, Simonetti G. Pulse-dose radiofrequency for knee osteoarthritis. *Cardiovasc Intervent Radiol* 2014; 37:482-487.
48. Zorbas G, Samaras T. A study of the sink effect by blood vessels in radiofrequency ablation. *Comput Biol Med* 2015; 57:182-186.
49. Masala S, Fiori R, Raguso M, Morini M, Calabria E, Simonetti G. Pulse-dose radiofrequency for knee osteoarthritis. *Cardiovasc Intervent Radiol* 2014; 37:482-487.
50. Fucci Djibilian ER, Pascual-Ramirez J, Martinez-Marcos A, Valverde Mantecon JM, Ultrasound-guided sciatic nerve pulsed radiofrequency for chronic knee pain treatment: A novel approach. *J Anesth* 2013; 27:935-938.
51. Akbas, M, Luleci N, Dere K, Luleci E, Ozdemir U, Toman H. Efficacy of pulsed radiofrequency treatment on the saphenous nerve in patients with chronic knee pain. *J Back Musculoskelet Rehabil* 2011; 24:77-82.
52. Vas, L, Pai Renuka, Khandagale N, Pattnaik M. Pulsed radiofrequency of the composite nerve supply to the knee joint as a new technique for relieving osteoarthritic pain: A preliminary report. *Pain Physician* 2014; 17:493-506.

