

## Case Report

## Ultrasound-Guided Phrenic Nerve Block for Intractable Hiccups following Placement of Esophageal Stent for Esophageal Squamous Cell Carcinoma

David Arsanious, BS<sup>1</sup>, Spiro Khoury, MD<sup>2</sup>, Edgar Martinez, MD<sup>3</sup>, Ali Nawras, MD<sup>4</sup>, Gregory Filatoff, MD<sup>5</sup>, Hossam Ajabnoor, MBBS<sup>2</sup>, Umar Darr, MD<sup>3</sup>, and Joseph Atallah, MD<sup>2</sup>

From: <sup>1</sup>University of Vermont College of Medicine, Burlington, VT; <sup>2</sup>Division of Pain Management, University of Toledo, Toledo, OH; <sup>3</sup>Department of Internal Medicine, University of Toledo, Toledo, OH; <sup>4</sup>Division of Gastroenterology and Endoscopy, University of Toledo, Toledo, OH; <sup>5</sup>Department of Anesthesiology, University of Toledo, Toledo, OH.

Address Correspondence:  
David Arsanious, BS  
University of Vermont  
College of Medicine, Given #31  
89 Beaumont Ave  
Burlington, VT  
E-mail:  
david.arsanious@med.uvm.edu

Disclaimer: There was no external funding in the preparation of this manuscript. Conflict of interest: Each author certifies that he or she, or a member of his or her immediate family, has no commercial association (i.e., consultancies, stock ownership, equity interest, patent/licensing arrangements, etc.) that might pose a conflict of interest in connection with the submitted manuscript.

Manuscript received: 08-04-2015  
Revised manuscript received:  
09-20-2015  
Accepted for publication: 09-29-2015

Free full manuscript:  
www.painphysicianjournal.com

Hiccups are actions consisting of sudden contractions of the diaphragm and intercostals followed by a sudden inspiration and transient closure of the vocal cords. They are generally short lived and benign; however, in extreme and rare cases, such as esophageal carcinoma, they can become persistent or intractable, up to and involving significant pain, dramatically impacting the patient's quality of life.

This case involves a 60-year-old man with a known history of squamous cell carcinoma of the esophagus. He was considered to have high surgical risk, and therefore he received palliative care through the use of fully covered metallic esophageal self-expandable stents due to a spontaneous perforated esophagus, after which he developed intractable hiccups and associated mediastinal pain. Conservative treatment, including baclofen, chlorpromazine, metoclopramide, and omeprazole, provided no relief for his symptoms. The patient was referred to pain management from gastroenterology for consultation on pain control. He ultimately received an ultrasound-guided left phrenic nerve block with bupivacaine and depomedrol, and 3 days later underwent the identical procedure on the right phrenic nerve. This led to complete resolution of his hiccups and associated mediastinal pain. At follow-up, 2 and 4 weeks after the left phrenic nerve block, the patient was found to maintain complete alleviation of the hiccups.

Esophageal dilatation and/or phrenic or vagal afferent fiber irritation can be suspected in cases of intractable hiccups secondary to esophageal stenting. Regional anesthesia of the phrenic nerve through ultrasound guidance offers a long-term therapeutic option for intractable hiccups and associated mediastinal pain in selected patients with esophageal carcinoma after stent placement.

**Key words:** Esophageal stent, esophageal stenting, intractable hiccups, intractable singultus, phrenic nerve block, phrenic nerve, ultrasound, palliative care, esophageal carcinoma

**Pain Physician 2016; 19:E653-E656**

**S**ingultus, commonly referred to as hiccups, are a common and often transient involuntary, intermittent, and spasmodic contraction of the muscles of the diaphragm and intercostals, followed by a sudden inspiration with a closure of the glottis. The 3 categories of hiccups are based on duration: A bout is an episode lasting up to 48 hours, persistent

hiccups continue from 48 hours up to one month, and intractable hiccups continue for longer than one month and can cause anorexia, weight loss, sleep deprivation, and depression (1,2).

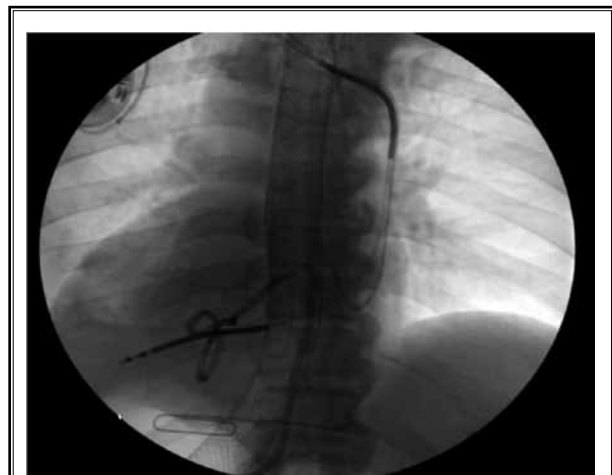
The phrenic nerve is an essential structure that is paramount to diaphragmatic function on each side. These arise from the ventral rami of the third, fourth,

and fifth cervical nerve roots, and course via the prevertebral fascia until they join anterior to the upper, lateral portion of the anterior scalene muscle, before descending through a gap between the sternocleidomastoid and omohyoid muscles then deep into the mediastinum to provide motor innervation to each hemidiaphragm (3,4). According to an ultrasound study of the phrenic nerve, it is oval, and its average diameter is  $0.6 \times 1.0$  mm (ranging from  $0.3 \times 0.6$  to  $0.8 \times 1.7$ ) whether left or right side. Moreover, there is no significant difference in this nerve between among genders and ages (5).

Pharmacologic treatments such as proton pump inhibitors, GABA receptor agonists/anticonvulsants, dopamine antagonists, and baclofen have been successfully used in some cases (6-8). Interventional regional anesthesia is also a viable therapeutic option. Ultrasound-guided phrenic nerve blocks have been shown to be effective for treatment of intractable hiccups (3,9). Here we present an interesting case where phrenic nerve block was successful in treating intractable hiccups in a patient who underwent esophageal stenting for spontaneous perforated esophagus caused by esophageal squamous cell carcinoma. To the best of our knowledge, this is the first report of phrenic nerve block in the setting of intractable hiccup that coincided with the placement of an esophageal stent for palliative care.

### Case Report

This patient was a 60-year-old gentleman who initially presented with a chief complaint of chest pain and



*Fig. 1. Wall Flex fully covered metallic self-expandable esophageal stent seen successfully placed in the distal esophagus on radiograph.*

was found to have spontaneous perforated esophagus of unknown etiology complicated by fluid collection in the mediastinum. Computed tomography (CT) scan showed a fluid collection within the posterior mediastinum. He was transferred to our institution for evaluation. He was initially seen by thoracic surgery and was considered to have a high surgical risk. He was then evaluated by gastroenterology for endoscopic treatment.

Upper endoscopy identified an esophageal mass in the distal segment. The patient received esophageal stenting, which has been historically used to palliate incurable esophageal malignancies that lead to dysphagia and/or tracheoesophageal fistulae (10). The patient had 2 WallFlex fully covered metallic self-expandable esophageal stents placed in at the site of the perforation (Fig. 1). On the following day, he reported pain and developed a case of severe hiccups. The patient was treated conservatively with muscle relaxant, baclofen, dopamine receptor antagonists, chlorpromazine and metoclopramide, and proton pump inhibitor with no relief of symptoms. Pain management was consulted for pain control and the option of phrenic nerve block was discussed with the patient.

Under ultrasound guidance, the anterior and middle scalene muscles were identified. Between the bellies of these 2 muscles is where the inter-scalene groove was revealed (Fig. 2). The probe was placed supero-lateral to this groove to the level of the fifth cervical nerve root and its course was followed until the right phrenic nerve was identified. A 22-gauge Stimuplex needle was introduced around phrenic nerve and a 4 mL solution of 0.25% bupivacaine followed by 40 mg of depomedrol was injected after negative aspirate. The patient tolerated the procedure well and reported 40% relief of his singultus. Three days later, the patient underwent identical left-sided phrenic nerve block with 4 mL 0.25% bupivacaine followed by 40 mg depomedrol that provided him with 100% relief from the hiccups and pain related to the hiccups.

At follow-up in the pain clinic 2 and 4 weeks later, the patient reported no relapse in his symptoms. Furthermore, the patient never again reported this as a complaint to any of the other services from whom he was receiving palliative care at our institution.

### DISCUSSION

Intractable hiccups should be carefully investigated due to their significant impact on quality of life. They are highly distressing, restrict day-to-day activities, and for patients undergoing palliative care, add even more

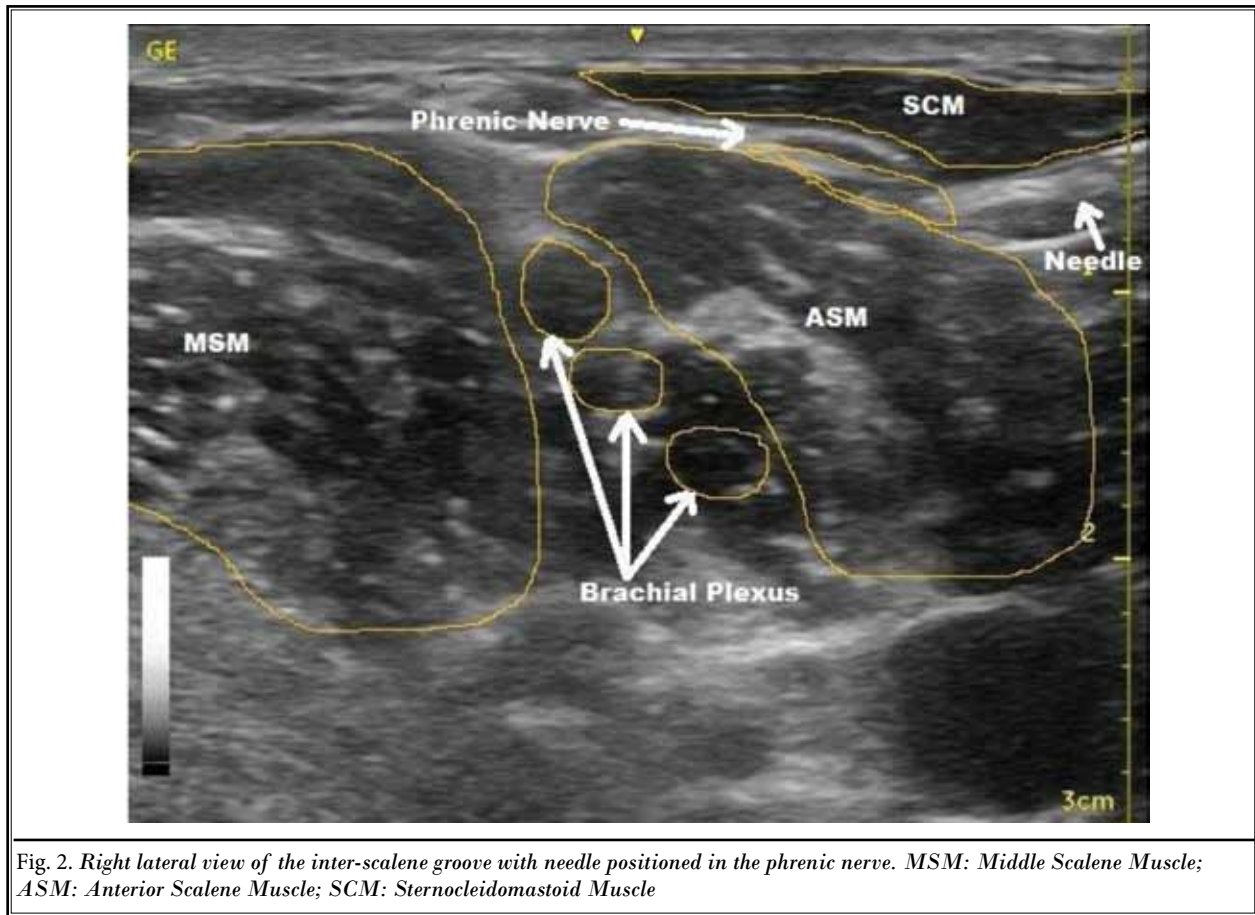


Fig. 2. Right lateral view of the inter-scalene groove with needle positioned in the phrenic nerve. MSM: Middle Scalene Muscle; ASM: Anterior Scalene Muscle; SCM: Sternocleidomastoid Muscle

discomfort to the end of life. More than 100 organic causes of persistent and intractable hiccups have been identified (11). Reports have been made that gastrointestinal carcinomas and their management have led to intractable hiccups as a complication (8,12,13). The pathophysiology of this is poorly understood, however may be related to irritation of the phrenic nerve from the primary tumor, irritation from tumor metastasis, or unintended side effect of therapeutic modalities such as stenting causing esophageal dilatation.

The relation of the phrenic nerve to hiccup was recognized at least as early as 1833 by Shortt who recommended blistering the surface of the neck over the origin and course of the phrenic nerves for intractable hiccup (14). A number of reports of freezing, transecting, crushing, and injecting lidocaine into the phrenic nerve to relieve intractable hiccups were published in the 1920s and 1930s (4).

The hiccup reflex arc consists of an afferent limb, made up by the phrenic and vagus nerves plus the sympathetic chain of T6-12. These axons are thought to ter-

minate on a spinal cord nucleus between C3 and C5 that is part of a network involving the brainstem and midbrain areas (respiratory center, phrenic nerve nuclei, medullary reticular formation, and hypothalamus). The efferent limb is made up by the phrenic nerve plus the motor neurons to the anterior scalene muscles (C5-7), external intercostal muscles (T1-11), and the recurrent laryngeal branch of the vagus nerve. Stimulation of any of the members of the hiccup reflex arc can result in hiccups (15,16). Often hiccups are caused by a multitude of factors including central nervous system disorders, vagus and phrenic nerve irritation, gastrointestinal diseases, thoracic abnormalities, cardiovascular disorders, toxic-metabolic abnormalities, post-op complications, medications, and/or psychogenic causes. Distention or inflammation of the esophagus, stomach, liver, or other organs can stimulate vagal afferents, and tumor or abscess may directly irritate the vagus or phrenic nerves, the diaphragm, or central nervous system (CNS) centers (15,17). Because the hiccups occurred in this patient after insertion of the esophageal stent,

we believe that the stent provoked mechanical irritation of the afferent limb of the hiccup reflex.

Although our patient did not show any signs of respiratory distress, phrenic nerve block may be contraindicated in patients with or at risk for severe pulmonary disorders. Furthermore, there are at least 2 reports where single shot phrenic nerve block provided only temporary relief. In one case, phrenic nerve block provided temporary relief and was then followed by ultrasound-guided pulsed radiofrequency lesioning and in the other a continuous bupivacaine infusion through a catheter for 3 days provided permanent relief (9,18).

Here we present an interesting case where phrenic nerve block was successful in treating intractable hiccups in a patient who underwent esophageal stenting for esophageal rupture caused by esophageal squamous cell carcinoma. The use of ultrasound provided optimal placement of the needle in close proximity to the target nerve. The phrenic nerve was easily identified by moving the probe in a cephalo-caudal direction in order to situate the needle without injury to any adjacent structures. We believe that adding steroids to the nerve block provided long-term relief for the patient and the use of ultrasound guidance provided us with confirmation that there was no intravascular injection. We chose to perform a block one side at a time to avoid respiratory distress to the patient by blocking both nerves in

the same setting. To the best of our knowledge, this is the first report of phrenic nerve block in the setting of intractable hiccups that coincided with the placement of an esophageal stent for palliative care.

## CONCLUSION

Singultus are diaphragmatic contractions against a closed glottis. They are often benign and transient, however if they become intractable, they can contribute to significant lifestyle impairment. Pharmacologic therapies are tailored to patient tolerance, and if response is not satisfactory, interventional modalities can be used for targeted long-term relief without side effects. Although there are a multitude of possible etiologies, gastrointestinal diseases such as esophageal carcinomas are known to have complications that we discussed in this case. Esophageal dilatation and thus nerve irritation from the lesion itself or through therapeutic means such as stenting could be reasons for development of such symptoms.

Intractable hiccups are a known complication of esophageal carcinoma and esophageal stenting, and ultrasound-guided phrenic nerve block offers a plausible treatment modality for symptomatic long-term relief. This case is unique because the intervention was done to treat mediastinal pain and intractable hiccups secondary to esophageal stenting.

## REFERENCES

1. Twycross R, Reginard, C. *Dysphagia, Dyspepsia, and Hiccup*. 2nd edition. Oxford University Press, Oxford, England, 1998.
2. Kolodzik PW, Eilers MA. Hiccups (singultus): Review and approach to management. *Ann Emerg Med* 1991; 20:565-573.
3. Calvo E, Fernandez-La Torre F, Brugarolas A. Cervical phrenic nerve block for intractable hiccups in cancer patients. *J Natl Cancer Inst* 2002; 94:1175-1176.
4. Noble EC. Hiccup. *Can Med Assoc J* 1934; 31:38-41.
5. Canella C, Demondion X, Delebarre A, Moraux A, Cotten H, Cotten A. Anatomical study of phrenic nerve using ultrasound. *European Radiology* 2010; 20:659-665.
6. Nishikawa T, Araki Y, Hayashi T. Intractable hiccups (singultus) abolished by risperidone, but not by haloperidol. *Annals of General Psychiatry* 2015; 14:13.
7. Matsuki Y, Mizogami M, Shigemitsu K. A case of intractable hiccups successfully treated with pregabalin. *Pain Physician* 2014; 17:E241-E242.
8. Turkyilmaz A, Eroglu A. Use of baclofen in the treatment of esophageal stent-related hiccups. *Ann of Thorac Surg* 2008; 85:328-330.
9. Renes SH, van Geffen GJ, Rettig HC, Gielen, MJ, Scheffer GJ. Ultrasound-guided continuous phrenic nerve block for persistent hiccups. *Regional Anesthesia and Pain Medicine* 2010; 35:455-457.
10. Hindy P, Hong J, Lam-Tsai Y, Gress, F. A comprehensive review of esophageal stents. *Gastroenterology & Hepatology* 2012; 8:526-534.
11. Moretto EN, Wee B, Wiffen PJ, Murchison AG. Interventions for treating persistent and intractable hiccups in adults. *Cochrane Database of Systematic Reviews* 2013; 1:CD008768.
12. McQuaid, K.R., Chapter 15. Gastrointestinal Disorders, in *CURRENT Medical Diagnosis & Treatment*. 2014, M.A. Papadakis and S.J. McPhee, Editors. 2014, The McGraw-Hill Companies: New York, NY.
13. Marinella MA. Diagnosis and management of hiccups in the patient with advanced cancer. *Journal of Supportive Oncology* 2009; 7:122-127, 130.
14. Shortt T. Hiccup, its causes and cure. *Edinb M & SJ* 1833; 39:305.
15. Krakauer EL, Zhu AX, Bounds BC, Sahani D, McDonald KR, Brachtel EF. Case records of the Massachusetts General Hospital. Weekly clinicopathological exercises. Case 6-2005. A 58-year-old man with esophageal cancer and nausea, vomiting, and intractable hiccups. *N Eng J Med* 2005; 352:817-825.
16. Friedman NL. Hiccups: A treatment review. *Pharmacotherapy* 1996; 16:986-995.
17. Smith HS, Busracamwongs A. Management of hiccups in the palliative care population. *American Journal of Hospice & Palliative Care* 2003; 20:149-154.
18. Kang KN, Park IK, Suh JH, Leem JG, Shin JW. Ultrasound-guided pulsed radiofrequency lesioning of the phrenic nerve in a patient with intractable hiccup. *Korean Journal of Pain* 2010; 23:198-201.