

## Retrospective Review

## Clinical Efficacy of Pulsed Radiofrequency Neuromodulation for Intractable Meralgia Paresthetica

Jae Jun Lee, MD, PhD<sup>1</sup>, Jong Hee Sohn, MD, PhD<sup>2</sup>, Hyuk Jai Choi, MD, PhD<sup>3</sup>,  
Jin Seo Yang, MD<sup>3</sup>, Kwang Ho Lee, MD, PhD<sup>4</sup>, Hye Jin Do, MD<sup>4</sup>, Sung Ho Lee, MD<sup>5</sup>,  
and Yong Jun Cho, MD, PhD<sup>3</sup>

From: Department of  
<sup>1</sup>Anesthesiology and Pain  
medicine, <sup>2</sup>Neurology, and  
<sup>3</sup>Neurosurgery, College of  
Medicine, Hallym University,  
Chuncheon, Korea; <sup>4</sup>Department  
of Anesthesiology and Pain  
medicine, Wonju Severance  
Christian Hospital, Yonsei  
University, Wonju, Korea;  
<sup>5</sup>Department of Neurosurgery,  
Kyung Hee Medical Center,  
Kyung Hee University, Seoul,  
Korea

Address Correspondence:  
Hyuk Jai Choi, MD  
Department of Neurosurgery,  
Chuncheon Sacred Heart  
Hospital, 77 Sakju-ro,  
Chuncheon, Kangwon-do, 200-  
704, Korea  
E-mail:  
neurosurgeon@hallym.or.kr

Disclaimer: Jae Jun Lee, MD,  
PhD and Jong Hee Sohn, MD,  
PhD, contributed equally to this  
work. This study was funded by  
Hallym University Research Fund  
(HURF-2014-07) and BioGreen  
21 (PJ01121401) of Rural  
Development Administration.  
Conflict of interest: Each author  
certifies that he or she, or a  
member of his or her immediate  
family, has no commercial  
association (i.e., consultancies,  
stock ownership, equity interest,  
patent/licensing arrangements,  
etc.) that might pose a conflict of  
interest in connection with the  
submitted manuscript.

Manuscript received: 02-16-2015  
Revised manuscript received:  
05-19-2015, 10-21-2015  
Accepted for publication:  
10-26-2015

Free full manuscript:  
www.painphysicianjournal.com

**Background:** Meralgia paresthetica (MP) is a neurologic disorder of the lateral femoral cutaneous nerve (LFCN), which is characterized by a localized area of paresthesia and numbness on the anterolateral aspect of the thigh. In most patients with MP, symptoms can be successfully managed with conservative treatment. However, in a small group of MP patients who are refractory to medical treatment, more aggressive low-risk treatment should be considered.

**Objective:** The objective of this study was to evaluate clinical outcomes of pulsed radiofrequency (PRF) neuromodulation of the LFCN in MP patients refractory to conservative treatment.

**Study Design:** Retrospective evaluation.

**Methods:** We retrospectively reviewed the clinical data of 11 patients with medically intractable MP who underwent PRF neuromodulation of the LFCN. These patients with MP underwent a diagnostic LFCN block using 2.0% lidocaine. Temporary pain relief > 50% was considered to be a positive response to the diagnostic nerve block. Following a positive response to the diagnostic nerve block, patients underwent PRF neuromodulation at 42° for 2 minutes. Patient pain was evaluated using a 10-cm visual analog scale (VAS). In MP patients who received PRF, we statistically evaluated VAS scores and the presence of any complications for 6 or more months after the procedure.

**Results:** The mean initial patient VAS score was  $6.4 \pm 0.97$  cm. This score was decreased to  $0.91 \pm 0.70$  cm,  $0.82 \pm 0.75$  cm, and  $0.63 \pm 0.90$  cm at the one-, 3-, and 6- month follow-ups, respectively ( $P < 0.001$ ). Sixty-three point six percent of patients achieved complete pain relief (pain-free) in the last follow-up, whereas 27.3% of patients achieved successful pain relief ( $\geq 50\%$  reduction in pain as determined by the VAS score). Furthermore, we did not observe any complications after the procedure.

**Conclusion:** PRF neuromodulation of the LFCN provides immediate and long-lasting pain relief without complications. Therefore, PRF of the LFCN can be used as an alternative treatment in patients with MP who are refractory to conservative medical treatment.

**Key words:** Diagnosis; lateral femoral cutaneous nerve, meralgia paresthetica, magnetic resonance imaging, neurosurgery, pain, intractable, pulsed radiofrequency, visual analog scale

**Pain Physician 2016; 19:173-179**

**M**eralgia paresthetica (MP) is a painful disorder of the lateral femoral cutaneous nerve (LFCN), which is characterized by complex symptoms, including pain, paresthesia, and numbness in the anterolateral thigh as a result of LFCN injury or compression (1). MP incidence is 4.3 per 10,000 persons and is more prevalent in patients experiencing carpal tunnel syndrome or pregnancy (2).

Conservative treatments, such as avoidance of tight-fitting clothes, physical therapy, weight loss in obese patients, anti-inflammatory medications, and local anesthetic injection with corticosteroids, are successful in relieving symptoms in the vast majority of patients (3). If conservative treatment fails, surgical treatment should be considered, and there are 2 surgical options: neurolysis or neurectomy (4). However, these surgical procedures have several disadvantages, such as the need for general anesthesia, risk of postsurgical infection, post surgical neurologic complications, and fear of surgery (1,5).

A few case studies recently reported a favorable outcome of pulsed radiofrequency (PRF) neuromodulation to the LFCN as an alternative treatment (6-8). In the current study, we present the clinical outcomes of 11 patients with MP treated using PRF neuromodulation.

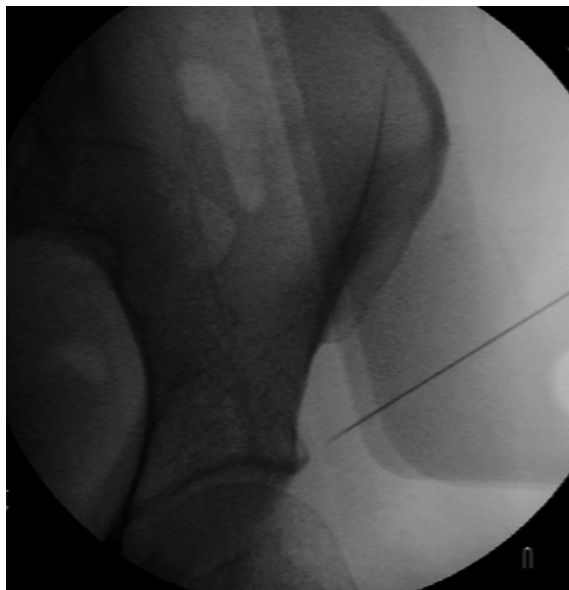

Fig. 1. A radiograph showing the entry point of the needle inserted into the LFCN approximately 1 cm medial to the anterior superior iliac spine (ASIS).  
AVG, average

## METHODS

### Patient Selection Criteria

This study received institutional review board approval (KMC IRB 1342-02); informed consent was not required because of the retrospective study design. This report represents a retrospective single-center review of 11 patients with medically intractable MP who were treated with PRF between September 2010 and March 2012. Our cases included 11 patients with MP of unknown origin (idiopathic).

MP was initially suspected in all the patients because of their clinical symptoms. We conducted neurophysiological evaluations, including a LFCN nerve conduction test, in all patients with suspected clinical symptoms of MP. The electrophysiological diagnosis of MP was established using sensory nerve action potentials (SNAP; < 10  $\mu$ V; latency, > 3.0 ms): decreased SNAP with side-to-side amplitude difference was indicative of MP. These patients underwent conservative treatment, including medication for 2 or more months. When conservative treatment was inadequate, we performed magnetic resonance imaging (MRI) scans or ultrasonography to rule out pain due to another cause. In patients with MP that was intractable to conservative treatment and had no other cause, we considered PRF of the LFCN. Diagnoses were confirmed by diagnostic LFCN block using 2.0% lidocaine (3 mL) administered twice over a one-week interval. Temporary pain relief of > 50% was considered to be a positive response to the diagnostic nerve block. These MP patients underwent PRF neuromodulation of the LFCN.

### PRF Procedure

PRF was performed in the operating room under fluoroscopy using a NeuroTherm NT1000 (NeuroTherm, Inc., Middleton, MA, USA) radiofrequency generator. In the operating room, the patient was placed in the supine position. The target site was prepped with betadine and draped aseptically, and then the anterior superior iliac spine (ASIS) was identified under C-arm fluoroscopy. In most cases, a disposable 20-gauge, 15-cm radiofrequency cannula (Model S-1505, NeuroTherm, Inc.) with a 5-mm active tip was inserted approximately 1 cm medial to the ASIS (quite variable: 2 cm lateral or 6 cm medial to the ASIS) (Fig. 1). The introducer needle was withdrawn, and the disposable RF electrode (Model RFDE-15, NeuroTherm, Inc.) was advanced. This was accomplished without bleeding. Selective stimulation of sensory fibers (50 Hz) showed concordant pain or dyesthesia below 0.3 V, which confirmed proper localiza-

tion of the PRF electrode. Motor stimulation was negative up to 1.5 V. The sensory stimulation results, which indicated that we were in the correct symptomatic area, were the most important findings used for target selection. After stimulation, PRF neuromodulation was performed for 2 minutes (45 V, 240 pulses). The pre-set maximum temperature was 42°).

### Outcome Measurements

In all patients, pain was assessed prior to the diagnostic block, as well as one, 3, 6, and ≥ 12 months following the PRF neuromodulation procedure. The pain intensity score, as measured on a visual analog scale (VAS; 0 cm: no pain, 10 cm: worst possible pain imaginable), was determined by the same blinded physician who performed the initial pain assessments.

### Statistical Analysis

Mean VAS scores for pain before the diagnostic block were compared with those obtained at the last follow-up after PRF neuromodulation using paired *t*-tests. Two-tailed *P*-values < 0.05 were considered to be statistically significant.

## RESULTS

### Patient Characteristics

The study included 11 patients (four men and seven women) aged 32 to 78 years (mean = 62.3 years). Mean symptom duration prior to PRF neuromodulation, the affected site (right or left), and number of pre-diagnostic blocks are summarized in Table 1.

### Clinical Outcomes

All VAS scores during the follow-up after PRF neuromodulation are shown in Table 2. The mean follow-up duration after the procedure was 14.6 months (range = 6 – 33 months). During the 6-month follow-up, all patients reported significant pain relief (VAS, ≥ 50% reduction in pain; *P* < 0.001). Two patients whose symptoms were completely relieved discontinued follow-up at 6 and 7 months after PRF, respectively. At the 12-month follow-up, one patient complained of symptom recurrence, with a VAS score of 4. In general, 7 patients (63.6%) achieved complete pain relief (pain-free) by the last follow-up, whereas 3 patients (27.2%) achieved successful pain relief (≥ 50% reduction in pain as determined by the VAS scores) (Table 2).

Changes in the mean VAS scores during the follow-ups are shown in Fig. 2. VAS scores at the one-, 3-, 6-, and 12-month follow-up assessments demonstrated significant improvements in pain compared with the pre-diagnostic block scores (*P* < 0.001). The mean pre-

Table 1. Characteristics of patients who underwent PRF neuromodulation for MP.

Characteristics	Value
Gender (M:F)	4:7
Mean age (range)	62.3 years (32 – 78)
Mean symptom duration before PRF (range)	5.8 months (2 – 12)
Affected side (right:left)	8:3
Number of diagnostic nerve blocks (range)	2.2 (2 – 3)

PRF, pulsed radiofrequency neuromodulation; M, male; F, female

Table 2. PRF treatment outcomes according to VAS scores.

	Age /Gender	Initial VAS	Post PRF	After 1 mo	After 3 mo	After 6 mo	After 12 mo	Last VAS	Follow-up duration	Remarks
1	61/M	6	0	0	0	0	0	0	33 mo	Pain-free
2	58/F	7	2	1	1	2	4	4	12 mo	Recurrence
3	58/F	7	1	1	0	0	0	0	12 mo	Pain-free
4	73/M	8	2	0	0	0	0	0	12 mo	Pain-free
5	48/M	5	2	2	2	2	2	2	12 mo	Pain relief
6	71/M	7	1	1	1	0	0	0	23 mo	Pain-free
7	34/F	5	1	0	0	0	0	0	12 mo	Pain-free
8	58/F	6	1	1	1	1	1	1	12 mo	Pain relief
9	73/F	7	2	1	1	0		0	7 mo	Pain-free
10	73/F	6	1	1	1	0		0	6 mo	Pain-free
11	78/F	6	1	2	2	2	2	2	20 mo	Pain relief

VAS, Visual Analog Scale; mo, month

diagnostic block VAS score of  $6.4 \pm 0.97$  cm decreased to  $0.91 \pm 0.70$  cm,  $0.82 \pm 0.75$  cm,  $0.63 \pm 0.90$  cm, and  $1.00 \pm 1.41$  cm at the one, 3, 6, and 12 months following the PRF procedure, respectively (Fig. 2).

### Safety

No adverse effects, such as sensory loss, numbness, wound infection, hematoma, or thermal injury, were found in any of the patients during the peri-procedural period. Further, no patients developed major or minor complications during the early or late follow-up periods.

### DISCUSSION

Conservative management of MP is effective in over 90% of patients, but patients with severe and persistent pain despite adequate conservative management should consider surgical treatment (i.e., either neurolysis or neurectomy of the LFCN) (9,10). However, these surgical options have both advantages and disadvantages. Some researchers suggest that neurolysis should be attempted prior to neurectomy because neurectomy results in permanent numbness in the nerve distribution (1). On the other hand, another study reported that the rate of symptom recurrence might be higher with neurolysis than with neurectomy (5). In previous studies, this invasive treatment of MP resulted in complete symptom relief with rates in the range of 30–100%. However, 4–40% of patients reported no

symptom relief and experienced several complications, such as mild sensory loss, numbness, wound infection, hematoma, and neuroma (Table 3) (1,5,11-17).

In the present study, a significant rate (91%; 10/11 patients) of symptom relief was achieved in patients with MP who were refractory to conventional management. This rate is comparable with those of previous surgical treatment studies on neurolysis (0–96%). In comparison with neurectomy, previous studies showed a 74–100% rate of symptom relief, which is superior to that with neurolysis; neurectomy may also result in poor outcomes or postoperative numbness (Table 3). Emamhadi (17) reported that neurectomy should be considered prior to neurolysis, and that it is more likely to result in complete relief. However, its complications (e.g., permanent anesthesia of the anterolateral thigh, probable motion restriction, postoperative local infection or bleeding, or worsening of the pain) should be considered, and the treated patient should undergo thorough neurologic examinations immediately after the procedure.

In addition to surgical treatment, potential MP treatment modalities include minimally invasive procedures, such as cryoneurolysis or radiofrequency lesioning of the LFCN, as well as additional treatment options, such as peripheral nerve stimulation or spinal cord stimulation (4,6,18-19). However, these procedures are unavailable to date due to a lack of published data or experience in managing MP. There are 2 types of radiofrequency lesioning: conventional radiofrequency (CRF) and PRF. During the application of CRF, a high temperature (80–82°C) is produced in the tissue surrounding the RF electrode tip, resulting in coagulative necrosis of the targeted tissue (20,21). Therefore, this is not conceptually different from other neurolytic procedures. In contrast, PRF neuromodulation results in rapid changes of strong electric fields and can lead to alteration of the pain signals and subsequent pain relief. Moreover, temperatures do not exceed 42°C during the procedure, and the target nerves and surrounding tissues are not damaged (22,23). While CRF thermal lesioning is effective due to nerve tissue destruction and subsequent blockade of pain transmission, the mechanism of PRF is still unknown. One theory of PRF suggests that it causes a neuromodulatory effect via changes in gene expression in pain-processing neurons (24-26). Another hypothesis based on ultrastructural analysis suggests that separation in the myelin configuration may result in blockage or interruption of the nerve signal

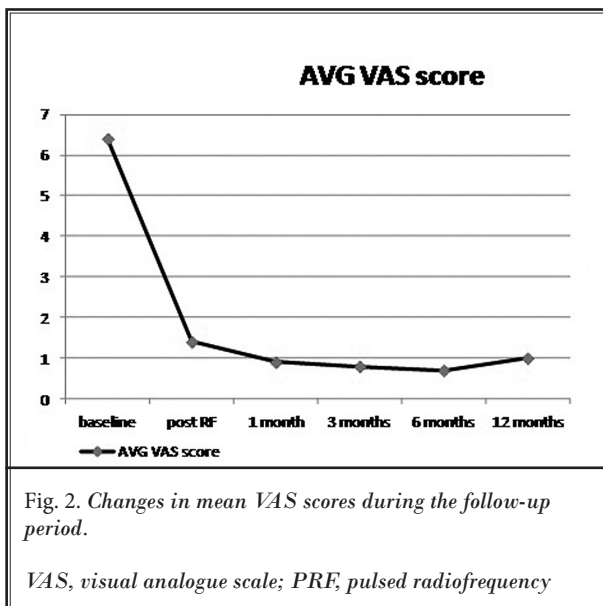


Table 3. Literature review on surgical management and our PRF neuromodulation results for MP.

First author, Year of publication	Number Intervention (No. of cases)	Pain-free (%)	Pain relief (%)	Remarks (Number of cases)
Macnicol, 1990 (11)	Neurolysis (25)	44	16	Mild sensory loss (7 of 11 patients with complete relief) No symptom relief (8)
Williams, 199 (11)	Neurectomy (24)		96	First-degree burn related to the anesthesia (1)
Edelson, 1994 (12)	Neurolysis (21)	67	24	Occasional pain but no limitation in activity (5) Pain interference with sports activities (2)
Nahabedian, 1995 (13)	Neurolysis (23)	78	18	Poor relief (1)
Van Eerten, 1995 (5)	Neurolysis (10)	30	30	Failure (4)
	Neurectomy (11)	82	18	Neuroma revealed by microscopic examination (1)
Siu, 2005 (14)	Neurolysis (45)	43	40	Short-term F/U (40): no pain relief (7), hematoma (3), wound infection (1)
		73	20	Long-term F/U (45): no pain relief (3)
Ducic, 2006 (15)	Neurolysis (29)		48	Poor outcome (5)
	Neurectomy (19)		29	Poor outcome (4)
de Ruiter, 2012 (16)	Neurolysis (10)	60		
	Neurectomy (8)	75	12.5	Bothered by numbness: sometimes (2), frequently (1)
Emamhadi, 2012 (17)	Neurolysis (5)	0		Recurrence (5)
	Neurectomy (9)	100		
Our results	PRF (11)	64	27	Recurrence (1)

F/U, follow up; PRF, pulsed radiofrequency neuromodulation

(27). Therefore, PRF may be used as a test method to help decide whether to create a permanent CRF lesion. Prolonged relief of the painful mononeuropathies following PRF has been reported on many occasions in the literature (28-30). Furthermore, a few case reports revealing its long-term effect in treating patients with MP were published (6-8). This is the first original article to demonstrate that this minimally invasive intervention can be used as an alternative option for MP refractory to conventional management. Further, the efficacy and complications of this technique are comparable to those of surgical options.

MP is typically diagnosed based on symptoms and signs in the LFCN distribution and on the absence of other neurological abnormalities in the lower extremities. The LFCN is a sensory nerve that originates from the first 3 lumbar nerve roots and runs through the pelvis along the lateral border of the psoas muscle crossing the iliacus muscle, toward and medial to the ASIS (31). It then passes above, below, or between the inguinal ligament, above the sartorius, and into the subcutaneous tissue of the femoral region. Ridder et al (32) reported possible anatomical variations of the LFCN in approximately 25% of the patient population. Also, the progression of 5 different types of LCFN, based on studies of cadavers, can be distinguished. Normally, the LFCN

passes 1 cm medial to the ASIS at the level of the inguinal ligament; however, there is considerable anatomical variation. The LFCN may cross over the iliac crest more than 2 cm away from the ASIS (33); another study described a case in which the LFCN crossed the ASIS at a distance < 5 mm superolateral of the anterior point of the ASIS (34). Due to these variations in anatomy, it may be difficult to accurately target the LFCN (35). According to reports of Bjurlin et al (36), the distance from the ASIS to the LCFN can vary from 0.3 – 6.5 cm. For these reasons, there have been many methods suggested for LCFN block. Thus, sensory stimulation less than 0.3 V during PRF for identifying the proper location of the target nerve and structural confirmation by fluoroscopy or ultrasonography are important for good outcomes. In addition, ultrasound allows the physician to maintain constant visualization of the needle (37). Therefore, future studies should determine whether ultrasound-guided PRF can be used to identify the LCFN and avoid potential complications.

Our study has several limitations. It was not a randomized, controlled study, but a retrospective case series involving a small sample. Hence, the outcomes of our study may not be generalizable. Additionally, our only outcome measure was determined using a pain assessment scale; however, LFCN neuropathy can influ-

ence the patient's functional status, including mobility. Future studies should also evaluate patients' global quality of life during the follow-up period. However, although our study was retrospective, it provides a promising view of the effectiveness and safety of PRF in patients with refractory MP. Future placebo-controlled, randomized, and double-blind studies may provide more objective information on the effectiveness of PRF in patients with MP.

In conclusion, surgical treatment should be considered for patients with intractable MP. PRF neuromodulation of the LFCN, an alternative treatment, can offer immediate and long-lasting pain relief of symptoms with low risk in MP patients refractory to conventional management. This minimally invasive, easily performed, and safe treatment modality should be considered for pain relief from intractable MP.

## ACKNOWLEDGMENT

### Author contribution

Study concept and design: Hyuk Jai Choi, Kwang Ho Lee. Acquisition of data: Hyuk Jai Choi. Analysis and interpretation of data: Hye Jin Do, Jin Seo Yang. Drafting of the manuscript: Jae Jun Lee, Jong Hee Sohn. Critical revision of the manuscript for important intellectual content: Sung Ho Lee, Yong Jun Cho. Statistical analysis: Jae Jun Lee, Jong Hee Sohn

### Conflict of interest

All authors have no conflicts of interest to report.

### Funding

This research was supported by Hallym University Research Fund (HURF-2014-13) and BioGreen 21 (PJ01121401) of Rural Development Administration.

## REFERENCES

- Grossman MG, Ducey SA, Nadler SS, Levy AS. Meralgia paresthetica: Diagnosis and treatment. *J Am Acad Orthop Surg* 2001; 9:336-344.
- van Slobbe AM, Bohnen AM, Bernsen RM, Koes BW, Bierma-Zeinstra SM. Incidence rates and determinants in meralgia paresthetica in general practice. *J Neurol* 2004; 251:294-297.
- Williams PH, Trzil KP. Management of meralgia paresthetica. *J Neurosurg* 1991; 74:76-80.
- Khalil N, Nicotra A, Rakowicz W. Treatment for meralgia paresthetica. *Cochrane Database Syst Rev* 2008; 12:CD004159.
- Van Eerten PV, Polder TW, Broere CA. Operative treatment of meralgia paresthetica: Resection versus neurolysis. *Neurosurgery* 1995; 37:63-65.
- Philip CN, Candido KD, Joseph NJ, Crystal GJ. Successful treatment of meralgia paresthetica with pulsed radiofrequency of the lateral femoral cutaneous nerve. *Pain Physician* 2009; 12:881-885.
- Choi HJ, Choi SK, Kim TS, Lim YJ. Pulsed radiofrequency neuromodulation treatment on the lateral femoral cutaneous nerve for the treatment of meralgia paresthetica. *Korean Neurosurg Soc* 2011; 50:151-153.
- Dalmau-Carola J. Treatment of meralgia paresthetica with pulsed radiofrequency of the lateral femoral cutaneous nerve. *Pain Physician* 2009; 12:1025-1026; author reply: 1026-1027.
- Erbay H. Meralgia paresthetica in differential diagnosis of low-back pain. *Clinical J of Pain* 2002; 18:132-135.
- Lee CH, Dellon AL. Surgical management of groin pain of neural origin. *J Am Coll Surg* 2000; 191:137-142.
- Macnicol MF, Thompson WJ. Idiopathic meralgia paresthetica. *Clin Orthop Relat Res* 1990; 254:270-274.
- Edelson R, Stevens P. Meralgia paresthetica in children. *J Bone Joint Surg Am* 1994; 76:993-999.
- Nahabedian MY, Dellon AL. Meralgia paresthetica: Etiology, diagnosis, and outcome of surgical decompression. *Ann Plast Surg* 1995; 35:590-594.
- Siu TL, Chandran KN. Neurolysis for meralgia paresthetica: An operative series of 45 cases. *Surg Neurol* 2005; 63:19-23; discussion 23.
- Ducic I, Dellon AL, Taylor N. Decompression of the lateral femoral cutaneous nerve in the treatment of meralgia paresthetica. *J Reconstr Microsurg* 2006; 22:113-118.
- de Ruiter GC, Wurzer JA, Kloet A. Decision making in the surgical treatment of meralgia paresthetica: Neurolysis versus neurectomy. *Acta Neurochir* 2012; 154:1765-1772.
- Emamhadi M. Surgery for meralgia paresthetica: Neurolysis versus nerve resection. *Turkish Neurosurgery* 2012; 22:758-762.
- Barna SA, Hu MM, Buxo C, Trella J, Cosgrove GR. Spinal cord stimulation for treatment of meralgia paresthetica. *Pain Physician* 2005; 8:315-318.
- Nouraei SA, Anand B, Spink G, O'Neil KS. A novel approach to the diagnosis and management of meralgia paresthetica. *Neurosurgery* 2007; 60:696-700.
- Sluijter ME. The role of radiofrequency in failed back surgery patients. *Curr Rev Pain* 2000; 4:49-53.
- Myers RR. *Neuropathology of Neurolytic Agents with Analysis of the Causes of Failed Neurolysis. Neural Blockade and Pain Management in Clinical Anesthesia and Management of Pain*. 3rd ed. Lippincott, Philadelphia, 1998, pp 985-1006.
- Rozen D, Parvez U. Pulsed radiofrequency of lumbar nerve roots for treatment of chronic inguinal hernia. *Pain Physician* 2006; 9:153-156.
- Son JH, Kim SD, Kim SH, Lim DJ, Park JY. The efficacy of repeated radiofrequency medial branch neurotomy for lumbar facet syndrome. *J Korean Neurosurg Soc* 2010; 48:240-243.
- Cahana A, Vutskits I, Muller D. Acute differential modulation of synaptic trans-

- mission and cell survival during exposure to pulsed and continuous radiofrequency energy. *J Pain* 2003; 4:197-202.
25. Cosman ER Jr, Cosman ER Sr. Electric and thermal field effects in tissue around radiofrequency electrode. *Pain Med* 2005; 6:405-424.
  26. Higuchi Y, Nashold BS Jr, Sluijter M, Cosman E, Pearlstein RD. Exposure of the dorsal root ganglion in rats to pulsed radiofrequency currents activated dorsal horn lamina I and II neurons. *Neurosurgery* 2002; 50:850-855; discussion 856.
  27. Tun K, Cemil B, Gurcay AG, Kaptanoglu E, Sargon MF, Tekdemir I, Comert A, Kanpolat Y. Ultrastructural evaluation of pulsed radiofrequency and conventional radiofrequency lesions in rat sciatic nerve. *Surgical Neurology* 2009; 72:496-500.
  28. Liliang PC, Lu K, Liang CL, Tsai YD, Hsieh CH, Chen HJ. Pulsed radiofrequency lesioning of the suprascapular nerve for chronic shoulder pain: A preliminary report. *Pain Med* 2009; 10:70-75.
  29. Navani A, Mahajan G, Kreis P, Fishman SM. A case of pulsed radiofrequency lesioning for occipital neuralgia. *Pain Med* 2006; 7:453-456
  30. Mitra R, Zeighami A, Mackey S. Pulsed radiofrequency for the management of chronic ilioinguinal neuropathy. *Hernia* 2007; 11:369-371.
  31. Haim A, Pritsch T, Ben-Galim P, Dekel S. A retrospective analysis of 79 patients evaluated and treated according to a standard algorithm. *Acta Orthopaedica* 2006; 77:482-486.
  32. de Ridder VA, de Lange S, Popta JV. Anatomical variations of the lateral femoral cutaneous nerve and the consequences for surgery. *J Orthop Trauma* 1999; 13:207-211.
  33. Murata Y, Takahashi K, Yamagata M, Shimada Y, Moriya H. The anatomy of the lateral femoral cutaneous nerve, with special reference to the harvesting of iliac bone graft. *J Bone Joint Surg Am* 2000; 82:746-747.
  34. Mischkowski RA, Selbach I, Neugebauer J, Koebeke J, Zöller JE. Lateral femoral cutaneous nerve and iliac crest bone grafts — anatomical and clinical considerations. *Int J Oral Maxillofac Surg* 2006; 35:366-372.
  35. Kosiyatrakul A, Nuansalee N, Luenam S, Koonchornboon T, Prachaporn S. The anatomical variation of the lateral femoral cutaneous nerve in relation to the anterior superior iliac spine and the iliac crest. *Musculoskeletal Surg* 2010; 94:17-20.
  36. Bjurlin MA, Davis KE, Allin EF, Ibrahim DT. Anatomical variations in the lateral femoral cutaneous nerve with respect to pediatric hip surgery. *Am J Orthop* 2007; 36:143-146.
  37. Fowler IM, Tucker AA, Mendez RJ. Treatment of meralgia paresthetica with ultrasound guided pulsed radiofrequency ablation of the lateral femoral cutaneous nerve. *Pain Pract* 2012; 12:394-398.

