

Randomized Trial

False Loss of Resistance in Cervical Epidural Injection: The Loss of Resistance Technique Compared with the Epidrum Guidance in Locating Epidural Space

Jin Young Lee, MD, PhD, Sangmin M. Lee, MD, PhD, Woo Seog Sim, MD, PhD, Hyun Joo Ahn, MD, PhD, Mi Hye Park, MD, Hyun Young Lim, MD, Soo Hee Lee, MD, Young Ri Kim, MD, Young Il Kim, MD, and Yu Jeong Bang, MD

From: Department of Anesthesiology and Pain Medicine, Samsung Medical Center, Sungkyunkwan University, School of Medicine, Seoul, Korea

Dr. Jin Young Lee is a clinical associate professor, Dr. Sangmin M. Lee and Dr. Woo Seok Sim are professors, Dr. Hyun Joo Ahn is an Associate Professor, Dr. Mi Hye Park, Dr. Hyun Young Lim, Dr. Soo Hee Lee, Dr. Young Ri Kim, and Dr. Young Il Kim are Fellows; and Dr. Yu Jeong Bang is a Resident, Department of Anesthesiology and Pain Medicine, Samsung Medical Center, Sungkyunkwan University, School of Medicine, Seoul, Korea.

Address Correspondence: Dr. Woo Seog Sim, MD, PhD, Department of Anesthesiology and Pain Medicine Samsung Medical Center Sungkyunkwan University, School of Medicine 81 Irwon-Ro, Gangnam-gu, Seoul, Korea 135-710 E-mail: anesthe@skku.edu

Disclaimer: The original work was performed in the Department of Anesthesiology and Pain Medicine, Samsung Medical Center, Sungkyunkwan University, School of Medicine, Seoul, Korea.

Manuscript received: 05-07-2015
Revised manuscript received: 07-02-2015, 08-27-2015
Accepted for publication: 09-23-2015

Free full manuscript: www.painphysicianjournal.com

Background: Epidural block failures can occur due to a misleading loss of resistance (LOR) signal.

Objective: This study was designed to evaluate the false LOR rate and to determine whether the Epidrum, which is an LOR device for identifying the epidural space, improves the ability to find the epidural space during cervical epidural injection compared the LOR technique.

Study Design: A randomized, single-blind trial.

Setting: Single academic medical center.

Methods: A total of 150 patients undergoing cervical interlaminar epidural injections at C7-T1 were randomized to receive either the LOR technique with a syringe (group C) or the Epidrum guidance (group E). Fluoroscopic images were used to confirm the accuracy of the needle placement within the epidural space. The rate of misleading epidural signals and adverse effects were recorded and analyzed.

Results: The false LOR rate was 74.7% for group C, 62.7% for group E, and 68.7% overall. The incidence of false LOR was not significantly different between the 2 groups. Also, the success rate and the rate of true epidural signals were similar between the 2 groups.

Limitations: The Epidrum cannot be used to confirm whether the needle has entered the vascular space without fluoroscopy.

Conclusions: In this study, we did not find any difference in accuracy between the Epidrum and the LOR technique with a syringe for detecting the cervical epidural space. The overall higher false LOR rate suggests that the combined use of fluoroscopy and LOR technique with a syringe or the Epidrum is necessary to increase the rate of finding the true cervical epidural space.

Clinical Trials registration: KCT0001333

Key words: Cervical epidural injection, epidural space, Epidrum, false positive, false negative, loss of resistance

Pain Physician 2016; 19:131-138

Cervical epidural steroid injection is an effective treatment strategy for the management of cervical radiculopathy. Although most cervical epidural injections are conducted safely with few side effects, serious morbidity has been reported (1,2). In addition, an accidental false epidural injection is not only a failed block, but also can lead to devastating life-threatening complications caused by an injury to the neural components. The accurate identification of the cervical epidural space is necessary to reduce side effects and improve the efficacy of the epidural injection. The ability to identify the epidural space depends largely on the skill of the physician. Traditionally, epidural injection has been performed using the loss of resistance (LOR) technique, which was first described in the 1930s and is based on a subjective feeling of negative pressure believed to be generated by penetration of the ligamentum flavum (3). The epidural space can be hard to distinguish, however, when an unclear LOR and epidural fluoroscopic pattern occur simultaneously (4). Physicians often become hesitant to advance the needle, which results in a difficult and more time-consuming procedure. Several methods to find the true epidural space have been suggested, including those that check the pressure and those that use a device to assist the procedure (5-10). The Epidrum (Exmoor Innovations Ltd, Taunton, UK) is a LOR device that connects to the epidural needle to facilitate the procedure. The diaphragm of the Epidrum, which is inflated with air, collapses when the needle tip reaches the resistanceless space such as the epidural space. The Epidrum can therefore be used to visually confirm the passage of the needle tip through the ligamentum flavum into the epidural space. This method has been used successfully in several studies of lumbar epidural anesthesia (5,6), but has not been tested at the cervical level. The purpose of this study was to determine the incidence of false LOR during cervical epidural injection and to evaluate the accuracy and safety of the Epidrum as a reliable method to access the successful entry into the cervical epidural space.

METHODS

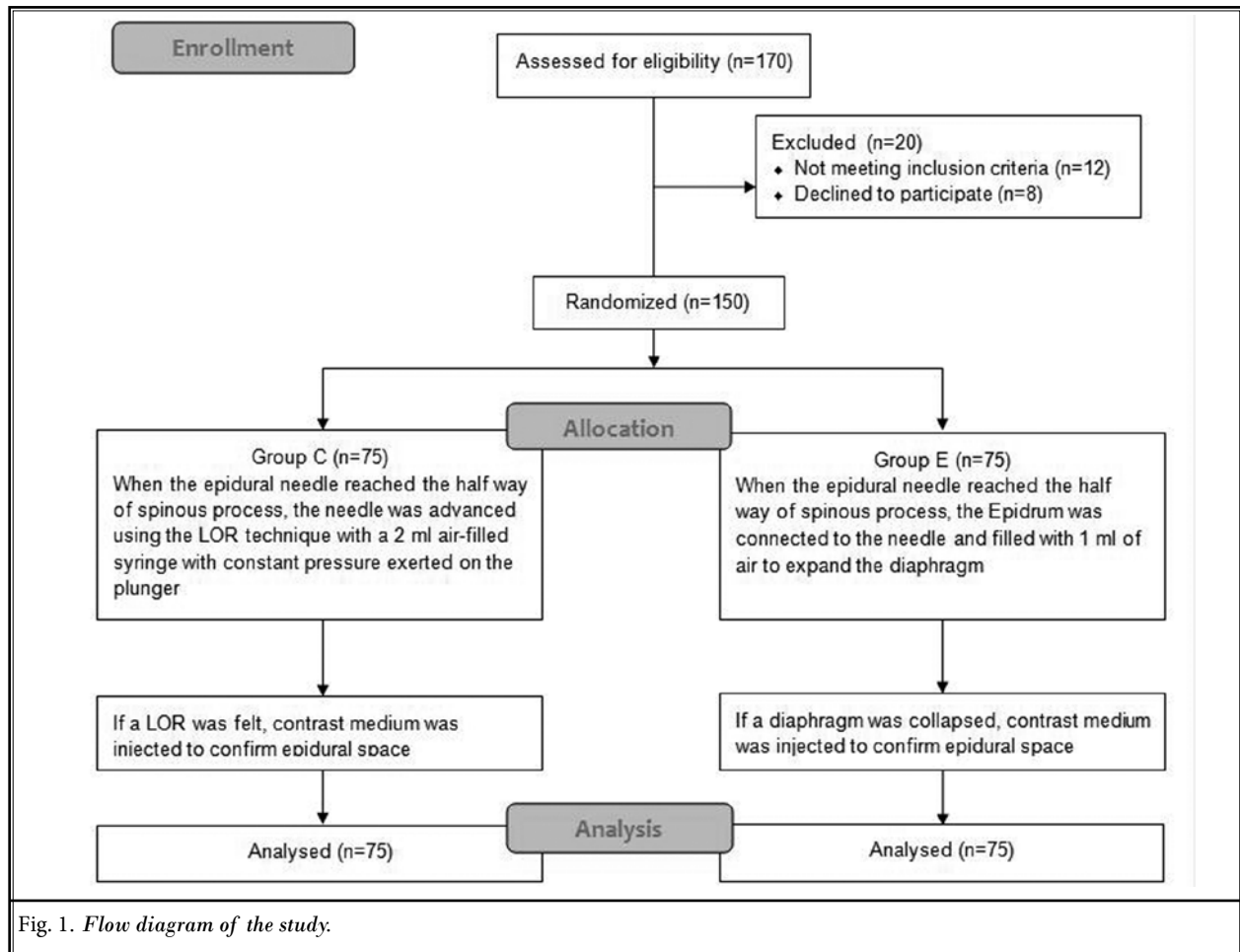
Patients

A total 150 patients between the ages of 20 and 80 years old who were undergoing cervical epidural injection were enrolled in the study. All patients had neck pain and/or cervical radiculopathy. The inclusion criteria were (a) a primary diagnosis of cervical radiculopathy;

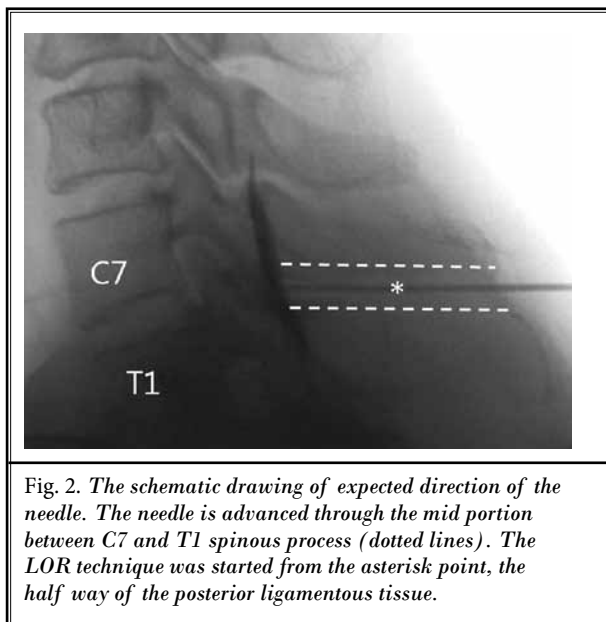
(b) no prior cervical epidural steroid injection; and (c) a cross-sectional imaging study (either computed tomography [CT] or magnetic resonance imaging [MRI]) of the cervical spine in patients with diagnoses of spinal stenosis, a herniated nucleus pulposus, ossification of posterior longitudinal ligament, and/or a degenerative spinal disorder. The exclusion criteria included any contraindications for cervical epidural injection, such as an unacceptable coagulation profile, prior neck surgery, a current infection, and/or an inability to flex or extend the neck. All patients were randomized into 2 groups: group C, who received the LOR technique with a syringe, and group E, who received the Epidrum guidance (Fig. 1). The randomization was performed by a computer program that generated random numbers (www.randomizer.org). This study was approved by our departmental ethics committee (2012-06-034) and registered with CRIS (Clinical Research Information Service, <http://cris.cdc.go.kr>, ref: KCT0001333, 2014.12.26). Written informed consent was obtained from all patients prior to their participation in this study.

Interventions

All procedures were performed under fluoroscopic guidance using the interlaminar midline approach at C7-T1 by the single pain physician with over 10 years of experience (WS Sim). The patients were placed in the prone position with their arms resting at their sides, and the neck was flexed using a pillow under the chest. An anteroposterior view was obtained with a C-arm (OEC series 9800, General Electronics, USA) to ensure midline of the C7-T1 interspace. At lateral view, when it was difficult to obtain an adequate clear image due to the patient's factor (short neck, elevated shoulder, and obesity), the patient was instructed to do a swimmer's view position by raising one arm forward to 180 degrees and resting the opposite arm on the downward side. Following an aseptic preparation and infiltration with 1% lidocaine, a 22-gauge Tuohy needle (Tae-Chang Industrial Co., Seoul, Republic of Korea) was inserted and advanced to the interspinous ligament. To compare the 2 groups in the same condition, we started the LOR technique when the needle reached the half way point of the spinous process aligning with the middle plane of posterior ligamentous tissue height under a lateral view (Fig. 2). For patients in group C, the needle was advanced with constant pressure exerted on the plunger of a 2 mL air-filled syringe. For patients in group E, the needle was connected to the Epidrum, inflated with 1 mL of air using the syringe (Fig. 3, Fig. 4A). After that,



the syringe was removed. The physician held the needle with both hands, and advanced the needle in a continuous forward direction toward the epidural space. If a LOR was felt (group C) or observed as the diaphragm collapsed (group E) (Fig. 4B), then the contrast medium (Omnipaque® 300) was injected to confirm whether the point was the epidural space or not under a lateral view. If the epidural pattern was not found, then the LOR was defined as a false positive LOR. If a LOR was not felt by the time that the needle reached the base of the spinous process, which was determined under a lateral view, the needle advancement was stopped and the contrast medium was injected to detect the location of the needle tip. If the contrast medium pattern was the epidural space, then the LOR was defined as a false negative LOR. The contrast medium was injected under real-time fluoroscopic guidance to confirm that the needle tip had reached the epidural space (Fig. 5). For both groups of patients, a mixture of 2 mL of



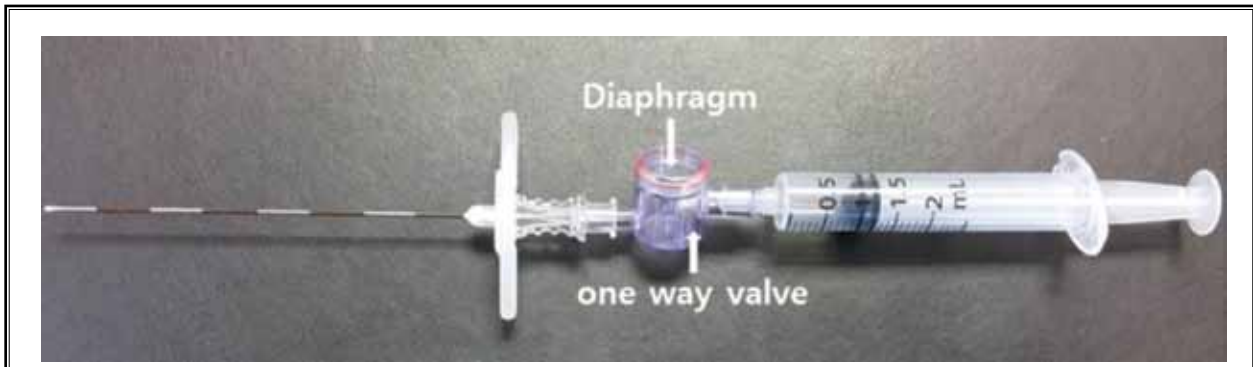


Fig. 3. The Epidrum is connected between the needle and the syringe.

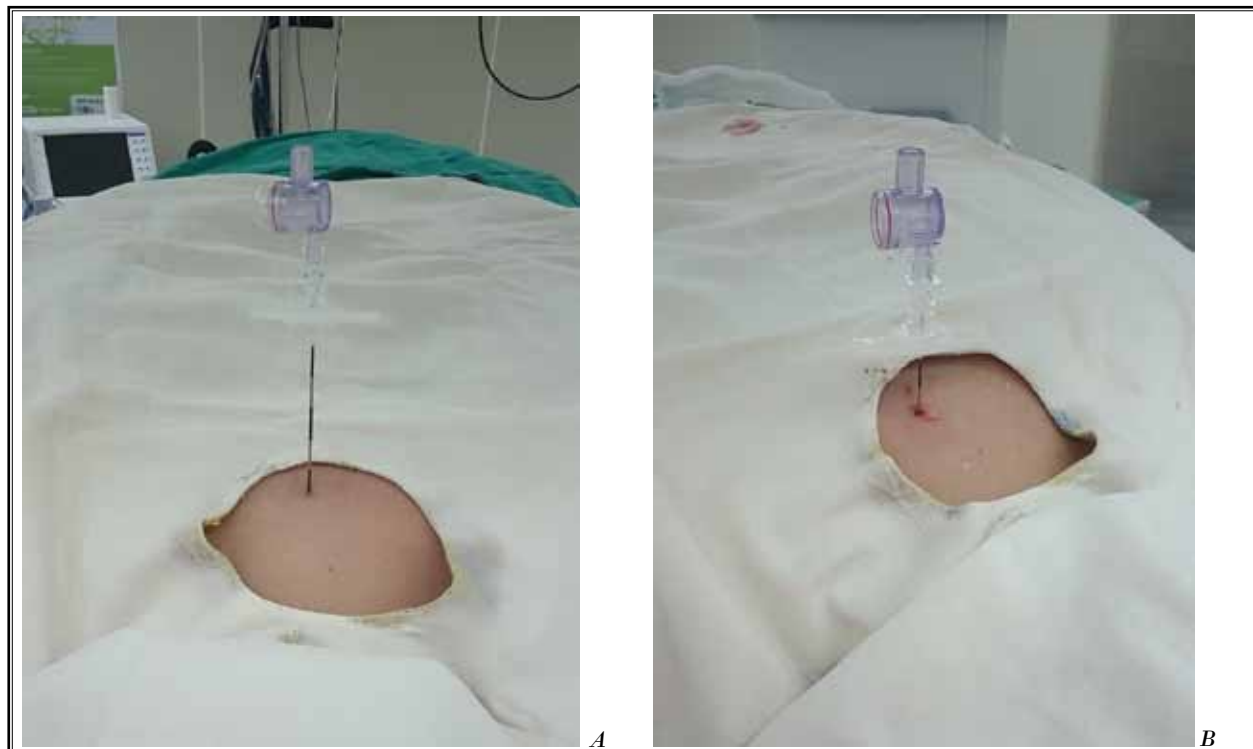


Fig. 4. A. The expanded diaphragm of the Epidrum when the needle tip is prior to entering the epidural space. B. The collapsed diaphragm of the Epidrum when the needle tip advances into the epidural space.

0.2% ropivacaine with 5 mg of dexamethasone was then slowly infused into the epidural space following negative aspiration. After the procedure, the patients were observed for any adverse effects. For each patient, the usefulness of the collapse signal (indicative or false LOR) and any observed complications were recorded.

Statistical Analysis

The sample size calculations were based on detecting a > 20 % difference in the false LOR rate between the 2 groups using initial estimates from our previous experience with the standard LOR and Epidrum techniques as well as previously published data. The α and β

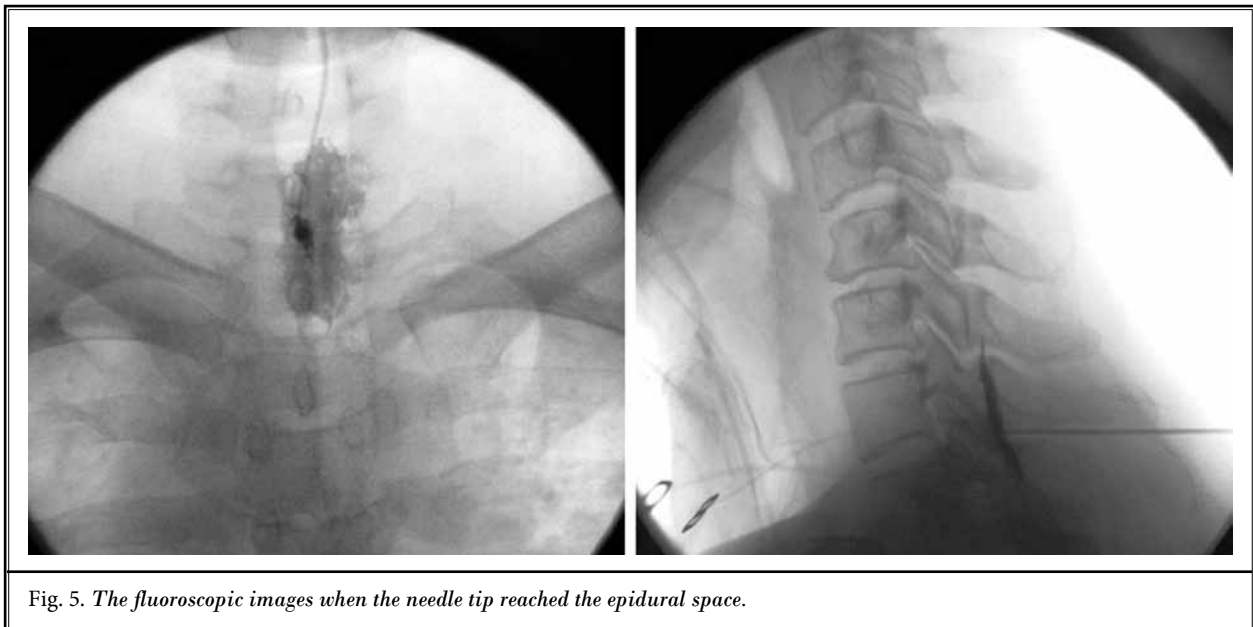


Fig. 5. The fluoroscopic images when the needle tip reached the epidural space.

errors were set at 0.05 and 0.2, accounting for the 10% drop rate, respectively, which resulted in 69 patients per group. The data were analyzed using SPSS 19.0 (Windows Software Package, SPSS, Chicago, IL, USA). The data are expressed as the mean \pm standard deviation (SD), median (range), or number (proportion). The demographic data for the 2 groups were compared using a t-test or Mann–Whitney U test. The number of patients was compared between the groups using the Pearson chi-square test. Differences at $P < 0.05$ were considered statistically significant.

RESULTS

Of the 170 patients assessed for eligibility, 20 were excluded due to not meeting inclusion criteria ($n = 12$) and declined to participate ($n = 8$). Thus, a total of 150 patients remained and were analyzed (Fig. 1). No statistically significant differences in the demographic data were observed between the 2 groups (Table 1). In 148 patients, the physician correctly detected the epidural space using either the LOR technique or the collapsing signal from the Epidrum, which was confirmed by fluoroscopy. The false LOR rate was 74.7% for group C, 62.7% for group E, and 68.7% overall (Table 2). No significant difference in the false LOR ratio was observed between the 2 groups (Table 2). There were 2 cases of accidental dural puncture in group C. Those patients had no unusual demographic characters and didn't show any symptoms, including headache, after puncture.

DISCUSSION

This study used the Epidrum as one such objective method that is used to confirm the LOR. The reported incidence of false LOR during epidural injection varies between 53% and 76.5% at the cervical level and between 25% and 30% at the thoracic and lumbar levels (11,12). In our study, the incidence of false LOR was 74.7% in the LOR technique group, 62.7% in the Epidrum guidance group, and 68.7% overall.

To determine which factors were associated with the false LOR in our study, we suspected the variability in the cervical anatomy, such as the different fiber structures, including thinness and midline gaps and directions of the posterior ligamentous tissue. To locate epidural space, the needle transverses 3 main ligamentous structures; the supraspinal and interspinous ligaments and the ligamentum flavum. The supraspinal and interspinous ligaments are composed of collagenous fibers, which may blunt the true LOR (13). Also, wide variations in fiber direction within these ligaments along the thoracic and lumbosacral spine provide different biomechanical response, explaining high proportion of stiffness in the lumbar interspinous ligaments. The interspinous ligaments are absent in the upper thoracic spine and are at least partially formed by the posterior layer in the lower thoracic spine (14). The ligamentum flavum is composed mainly of elastic fibers and is a crucial structure, as the LOR is elicited as the needle passes through it. The ligamentum flavum is

Table 1. *Patient demographics.*

	Group C (N = 75)	Group E (N = 75)	P-value
Age (yr)	51.9 ± 11.4	53.8 ± 9.2	0.264
Gender (M/F)	41/34	43/32	0.869
Height (cm)	163.5 (150.0 – 184.0)	165.0 (148.0 – 184.0)	0.911
Weight (kg)	65.5 (44.0 – 92.0)	65.5 (43.0 – 100.0)	0.765
Diagnosis			0.550
Cervical spinal stenosis	15 (20.0%)	20 (26.7%)	
Cervical HNP	53 (70.7%)	52 (69.3%)	
Others	7 (9.3%)	3 (4.0%)	

All data are presented as the mean ± SD, the number of patients (%) or median (range). M/F: male/female; HNP, herniated nucleus pulposus. Group C, patients who received the LOR technique with a syringe; Group E, patients who received the Epidrum guidance.

Table 2. *Comparison of Groups C and E.*

	Group C (N = 75)	Group E (N = 75)	P-value
Epidural signal			0.176
Indicative (true LOR)	22 (29.3%)	31 (41.3%)	
False LOR	56 (74.7%)	47 (62.7%)	
False positive LOR	48 (64.0%)	40 (53.3%)	
False negative LOR	8 (10.7%)	7 (9.3%)	

All data are presented as the number of patients (%). LOR, loss of resistance; Group C, patients who received the LOR technique with a syringe; Group E, patients who received the Epidrum guidance.

the thinnest at the cervical level and the thickest at the lumbar levels. The resistance to the needle advancement therefore decreases the more cephalic the puncture is performed (4). In addition, the incidences of a midline gap in the ligamentum flavum at the cervical level has been reported to be between 50% and 100% (4,15), which may contribute to a false LOR rate. It may increase the potential risk of spinal cord injury due to an accidental dural puncture. A midline gap is more commonly located in the caudal third of the ligamentum flavum than the middle or cephalic portion (15). In our study, we approached through the middle portion under a lateral fluoroscopic view. This approach might give us more chance to avoid accidental dural puncture at the midline gap. In addition to the variability in the cervical structure, we also considered patient characteristics, such as a distorted epidural space due to degenerative changes and/or obesity as possible factors associated with the false LOR rate. Fatty infiltration and fibrocartilaginous changes of the supraspinous ligament can affect LOR. Sharrock (16) documented that false positive LOR may be encountered by entering a hole or cyst in the interspinous ligament from degeneration of the interspinous ligament. Degenerative or hypertrophic changes in the ligamentum flavum can result in the transformation from elastic to a more collagenous structure, which is weaker in strength and results in the attenuation of the resistance. If the needle passes through the ligamentum flavum with a less perceptible feeling of resistance, then the perception of the

LOR may be weak or absent, which may result in excessive needle entries and catastrophic complications (17). In cervical injections for morbidly obese patients, the needle can penetrate unintended structures, such as the surrounding deep muscles or fat layers, prior to entering the true epidural space, which may lead to a false positive LOR. In this study, we started the LOR technique from the half way point of the posterior ligamentous tissue under a lateral view. This half way point might be an earlier location, which made a shallow injection and a false LOR at the cervical level due to specific characteristics of cervical ligamentous structures.

Several devices to assist epidural injections, including those that confirm correct needle placement based on the principle of negative pressure, have been developed (5-10). Lechner et al (8) described that epidural puncture assist device, which translates pressure change into corresponding acoustic and visual signals, is a reliable, safe, and simple procedure in needle handling, teaching, and confirming correct epidural catheter placement. Tielens et al (10) found the Epidrum syringe, which is a spring-loaded LOR syringe, provides a reliable identification of the epidural space. However, there are no clear additional values for widely using these techniques. The Epidrum is a device that provides visual confirmation of epidural space penetration via the collapse of the diaphragm (5-7). Sawada et al (5) reported that the Epidrum offers several advantages over conventional epidural space identifica-

tion techniques in terms of decreased time required for epidural detection, greater Tuohy needle control, and safer resident anesthesiologist training from removing operator subjectivity and variability. The Epidrum may be a valuable device for patients in whom a false LOR is more likely to occur or for patients in whom the conventional technique has failed due to an unclear LOR. When there was a false LOR with the Epidrum, it was visualized by a slow deflation of the diaphragm, so it was easier to identify epidural space than the tactile LOR technique, even though there was no significant difference between the groups.

Despite its value in confirming the epidural space, the Epidrum device has several limitations. The Epidrum cannot be used to confirm whether the needle has entered the vascular space without fluoroscopy. In addition, physicians cannot receive any tactile feedback within the different tissues during the needle location. Most false LOR failures occurred due to premature diaphragm deflation prior entering the epidural space. To reduce the false LOR rate, the manufacturer recommends attaching the Epidrum only after the needle has been advanced such that the tip is in the interspinous ligament. However, in real practice, it is not easy to find interspinous ligaments just from needle depth or subjective feeling, so, the C-arm is necessary to find the proper positing with safety and accuracy. Physicians must also consider the cost of the procedure with the

addition of the Epidrum device.

This study has several limitations. First, the physicians were not blinded to the group to which the patients were randomized because the physician knew when the Epidrum was used. Second, we did not estimate the peak force that was applied to the plunger of the syringe as an objective way to quantify the difference between true and false LOR. We suspect, however, that a higher force on the syringe plunger may increase the false LOR rate.

CONCLUSION

In conclusion, we investigated the false LOR rate during cervical epidural injections using the LOR technique compared with a device used to assist in finding the epidural space, the Epidrum. We did not find any difference in accuracy between the Epidrum and the LOR technique with a syringe for detecting the cervical epidural space. We also found that a false LOR occurred in over 60% of our cases, which suggests that the combined use of fluoroscopy and LOR technique with a syringe or the Epidrum is necessary to increase the rate of finding the true cervical epidural space.

Disclaimer

There was no external funding in the preparation of this manuscript.

REFERENCES

- Raj P, Lou L, Erdine S, Waldman S. Cervical epidural nerve block. In: Prithvi Raj P (ed). *Radiographic Imaging for Regional Anesthesia and Pain Management*. Churchill Livingstone, UK, 2003, pp 99-105.
- Manchikanti L, Malla Y, Wargo DO, Cash KA, Pampati V, Fellow B. A prospective evaluation of complications of 10,000 fluoroscopically directed epidural injections. *Pain Physician* 2012; 15:131-40.
- Zarzur E. Genesis of the 'true' negative pressure in the lumbar epidural space. A new hypothesis. *Anaesthesia* 1984; 39:1101-1104.
- Lirk P, Kolbitsch C, Putz G, Colvin J, Colvin HP, Lorenz I, Keller C, Kirchmair L, Rieder J, Moriggl B. Cervical and high thoracic ligamentum flavum frequently fails to fuse in the midline. *Anesthesiology* 2003; 99:1387-1390.
- Sawada A, Kii N, Yoshikawa Y, Yamakage M. Epidrum®: A new device to identify the epidural space with an epidural Tuohy needle. *J Anesth* 2012; 26:292-295.
- Kim SW, Kim YM, Kim SH, Chung MH, Choi YR, Choi EM. Comparison of loss of resistance technique between Epidrum® and conventional method for identifying the epidural space. *Korean J Anesthesiol* 2012; 62:322-326.
- Brinkmann S, Mitchell CH, Hocking G. Assessment of a single-operator real-time ultrasound-guided epidural technique in a porcine phantom. *Can J Anaesth* 2012; 59:323-324.
- Lechner TJ, van Wijk MG, Maas AJ, van Dorsten FR, Drost RA, Langenberg CJ, Teunissen LJ, Cornelissen PH, van Niekerk J. Clinical results with the acoustic puncture assist device, a new acoustic device to identify the epidural space. *Anesth Analg* 2003; 96:1183-1187.
- Paech MJ, Muchatuta NA, Griffiths JD, Bone E, Nathan EA. The Episire loss-of-resistance syringe. *Anaesth Intensive Care* 2011; 39:976.
- Tielens LK, Bruhn J, Vogt M, van Geffen GJ, Scheffer GJ. The Episire Autodetect syringe, a loss-of-resistance technique for locating the epidural space, used in pediatric patients. *Paediatr Anaesth* 2013; 23:747-750.
- Park MH, Lee WH, Ko YK, So SY, Kim HJ. Ultrasonographic measurement of the ligamentum flavum depth: Is it a reliable method to distinguish true and false loss of resistance? *Korean J Pain* 2012; 25:99-104.
- Stojanovic MP, Vu TN, Caneris O, Slezak

- J, Cohen SP, Sang CN. The role of fluoroscopy in cervical epidural steroid injections. *Spine (Phila Pa 1976)* 2002; 27:509-514.
13. Hogan QH. Epidural anatomy examined by cryomicrotome section. Influence of age, vertebral level, and disease. *Reg Anesth* 1996; 21:395-406.
14. Johnson GM, Zhang M. Regional differences within the human supraspinous and interspinous ligaments: A sheet plastination study. *Eur Spine J* 2002; 11:382-388.
15. Yoon SP, Kim HJ, Choi YS. Anatomic variations of cervical and high thoracic ligamentum flavum. *Korean J Pain* 2014; 27:321-325.
16. Sharrock NE. Recordings of, and an anatomical explanation for, false positive loss of resistance during lumbar extradural analgesia. *Br J Anaesth* 1979; 51:253-258.
17. Chen HC, Hsu PW, Lin CY, Tzaan WC. Symptomatic hematoma of cervical ligamentum flavum: Case report. *Spine (Phila Pa 1976)* 2005; 30:E489-E491.