

## Brief Commentary

## **e** Ultrasonographic Diagnosis of Calcifying Tenosynovitis of the Finger

Ming-Yen Hsiao, MD<sup>1</sup>, Hsin- I Wang, MD<sup>2</sup>, and Levent Özçakar, MD<sup>3</sup>

From: <sup>1</sup>National Taiwan University Hospital, Bei-Hu Branch; <sup>2</sup>National Taiwan University Hospital, Taipei, Taiwan; <sup>3</sup>Hacettepe University Medical School, Ankara, Turkey

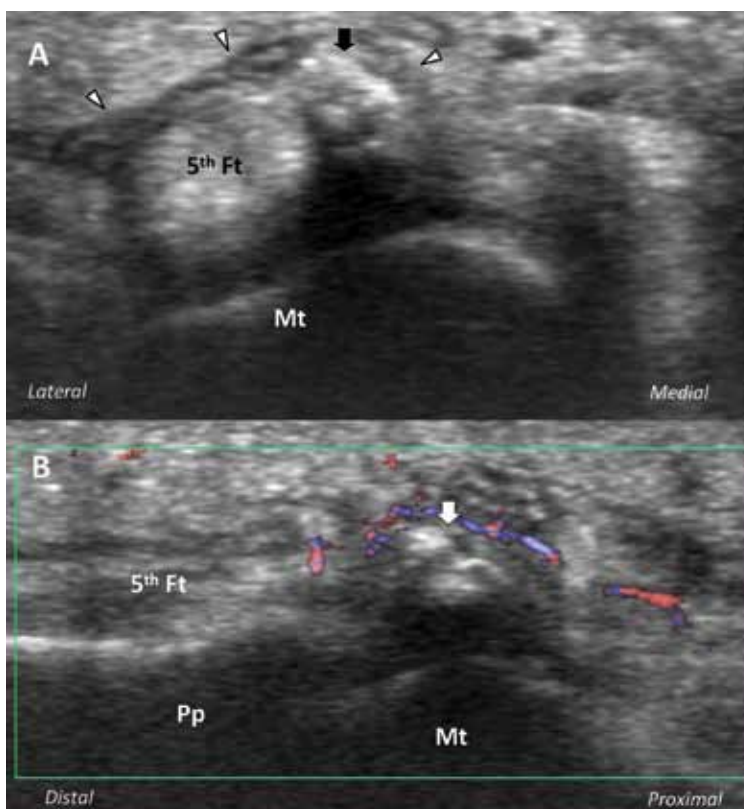
Address Correspondence:  
Ming-Yen Hsiao, M.D.  
Department of Physical Medicine  
and Rehabilitation  
National Taiwan University  
Hospital, BeiHu Branch  
No. 87, Neijiang St., Taipei 100,  
Taiwan  
E-mail: myferrant@gmail.com

Free full manuscript:  
[www.painphysicianjournal.com](http://www.painphysicianjournal.com)

**A** 39-year-old man was seen for severe pain and swelling at the base of his right fifth finger for the last 2 days. He had no history of inflammatory arthritis or hyperuricemia, and he also denied any antecedent injury or infection. On further questioning, he declared that he was a cook, frequently holding heavy pots with that hand.

Physical examination showed focal erythema, swelling, and marked tenderness on the volar side of the right fifth metacarpophalangeal joint. The active/passive joint motions were also limited and painful. Ultrasound (US) examination showed focal distension of the flexor tendon sheath, an irregular nodular calcification, and significant hypervascularity (Fig. 1). As the patient was diagnosed with calcifying flexor tenosy-

Fig. 1. US imaging of the flexor tendons of the right fifth digit (5th Ft). (A) Axial view at the level of metacarpal head (Mt) shows a focally distended tendon sheath (arrowheads) with an irregularly nodular calcification (arrow). (B) Longitudinal view over the metacarpophalangeal joint shows hypervascularity surrounding the calcification (arrow). Pp, proximal phalanx.



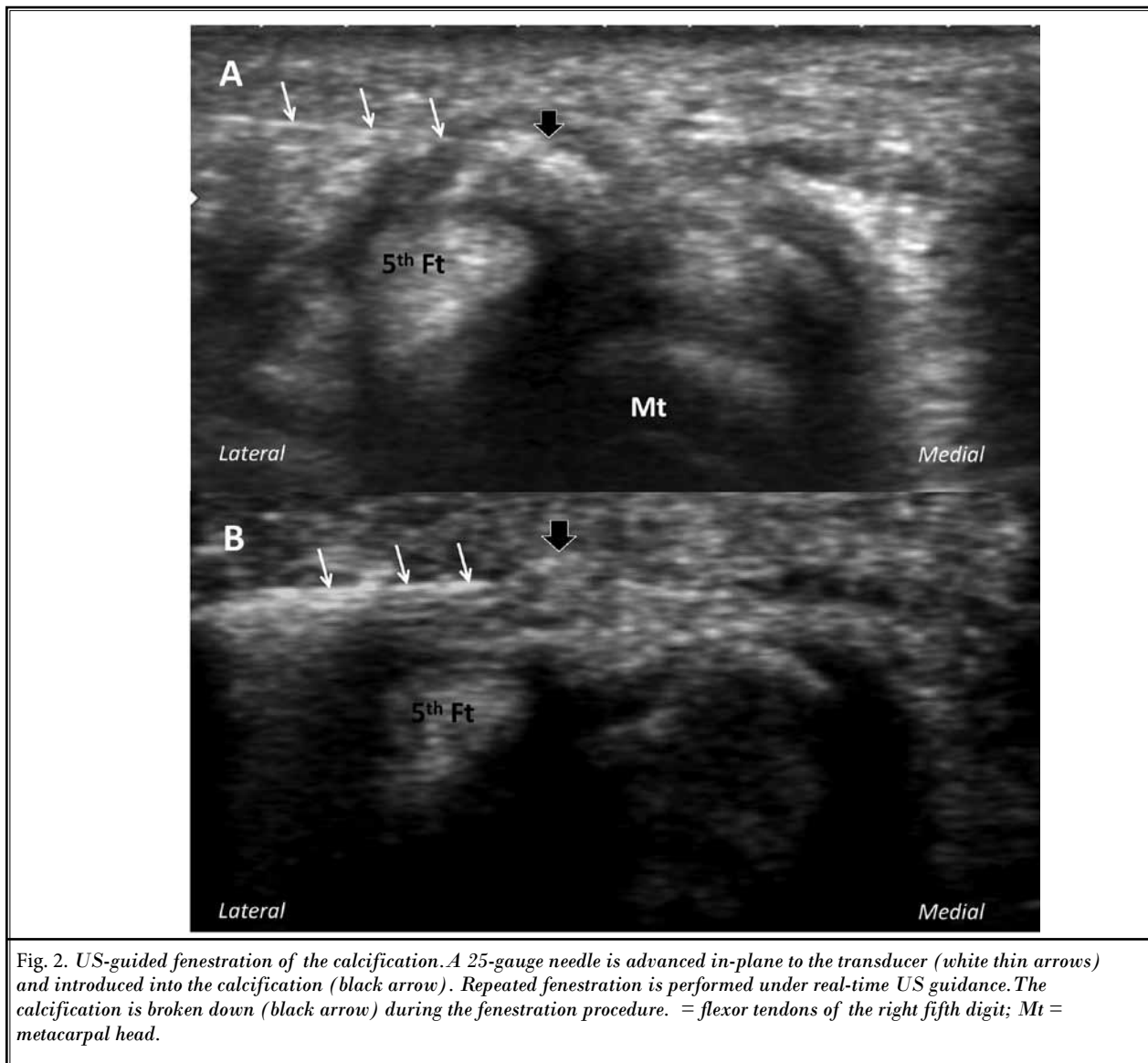


Fig. 2. US-guided fenestration of the calcification. A 25-gauge needle is advanced in-plane to the transducer (white thin arrows) and introduced into the calcification (black arrow). Repeated fenestration is performed under real-time US guidance. The calcification is broken down (black arrow) during the fenestration procedure. = flexor tendons of the right fifth digit; Mt = metacarpal head.

novitis. US-guided fenestration of the calcification and triamcinolone injection were performed (Fig. 2). On the first week follow-up, he had complete resolution of pain and recovery of range of motion.

Calcifying tendinitis is a debilitating painful condition caused by calcium hydroxyapatite deposition accompanied by acute inflammation. The condition is most commonly seen in the rotator cuff of the shoulder (1). When it occurs in the hands, which is rare, it frequently involves the insertion of the flexor carpi ulnaris tendon (in peri-menopausal women) (2,3). In our unusual case, the acute calcifying tenosynovitis of the fifth finger flexors ensued in a young man.

The clinical diagnosis of this condition can actually be quite challenging and easily confused with gout, cellulitis, septic arthritis, and acute fracture (2,4,5). Additionally, the calcifications may not be visible on radiographs several weeks in the early period. In this regard, US serves as a convenient and non-invasive imaging tool with superb resolution for soft tissues. It can detect tendon calcifications even in the early formative phase (6). Typical US presentation, as in the present case, includes a focal hyperechoic area with posterior acoustic shadowing, thickening and hypoecogenicity or focally distended tendon sheath, and hyperemia on Doppler imaging (6-8). Further, US is reported to be more sensi-

tive and accurate than magnetic resonance imaging in detecting tiny calcific depositions (6,9,10). The sensitivity and specificity of US in diagnosing calcifying tendonitis of the shoulder are 100% and > 90%, respectively (9,11); relevant literature about this condition in the finger is lacking. However, US could be a good tool in diagnosing calcifying tendonitis of the finger because

of the superficiality of flexor tendons, which makes it easily accessible by US. Last but not least, it also enables real-time imaging and guides therapeutic interventions thereafter. Overall, the present case once again highlights the critical role of US imaging in the differential diagnosis of acute inflammatory conditions and in the management of calcifying tendinitis of the hand.

---

## REFERENCES

1. Holt PD, Keats TE. Calcific tendinitis: A review of the usual and unusual. *Skeletal Radiol* 1993; 22:1-9.
2. Carroll RE, Sinton W, Garcia A. Acute calcium deposits in the hand. *J Am Med Assoc* 1955; 157:422-426.
3. Yosipovitch G, Yosipovitch Z. Acute calcific peri-arthritis of the hand and elbows in women. A study and review of the literature. *J Rheumatol* 1993; 20:1533-1538.
4. Moradi A, Kachooei AR, Mudgal CS. Acute calcium deposits in the hand and wrist. *J Hand Surg Am* 2014; 39:1854-1857.
5. Dilley DF, Tonkin MA. Acute calcific tendinitis in the hand and wrist. *J Hand Surg Br* 1991; 16:215-216.
6. Hodgson RJ, O'Connor PJ, Grainger AJ. Tendon and ligament imaging. *Br J Radiol* 2012; 85:1157-1172.
7. Farin PU, Jaroma H. Sonographic findings of rotator cuff calcifications. *J Ultrasound Med* 1995; 14:7-14.
8. Papatheodorou A, Ellinas P, Takis F, Tsanis A, Maris I, Batakis N. US of the shoulder: Rotator cuff and non-rotator cuff disorders. *Radiographics* 2006; 26:23.
9. Ottenheijm RP, Jansen MJ, Staal JB, Van Den Bruel A, Weijers RE, De Bie RA, Dinant GJ. Accuracy of diagnostic ultrasound in patients with suspected sub-acromial disorders: A systematic review and meta-analysis. *Arch Phys Med Rehabil* 2010; 91:1616-1625.
10. Zubler C, Mengiardi B, Schmid MR, Hodler J, Jost B, Pfirrmann CW. MR arthrography in calcific tendinitis of the shoulder: Diagnostic performance and pitfalls. *Eur Radiol* 2007; 17:1603-1610.
11. Kayser R, Hampf S, Pankow M, Seeber E, Heyde CE. Validity of ultrasound examinations of disorders of the shoulder joint. *Ultraschall Med* 2005; 26:291-298.

