

Brief Commentary

e "Bursitis De Novo": A Clinical Case of Ischiofemoral Impingement

Joan Dalmau-Carolà, MD

From: Girona, Spain

Address Correspondence:
Joan Dalmau-Carolà, MD
Bisbe Lorenzana, 39,3-3
Girona, Catalonia Spain
Email:
jdalmauc@acmcb.es

Disclaimer: There was
no external funding in
the preparation of this
manuscript.

Free full manuscript:
www.painphysicianjournal.
com

A 73-year-old woman with a 12-year history of seropositive rheumatoid arthritis and a 2-year history of established osteoporosis presented with persistent pain in the right gluteal area, thigh, and leg secondary to epileptic seizure one month prior. A compression hip screw and metal plate had been placed to treat a right femoral neck fracture 8 years earlier and removed after 4 years. On physical examination, right hip flexion was free and painless although internal-external rotations and the psoas test elicited pain; extension was blocked. Plain-film x-rays showed an unusually large lesser trochanter contacting the ischium (Fig. 1). Besides the total narrowing of the ischiofemoral space, magnetic resonance imaging (MRI) showed a small area of osteonecrosis in the posterior and internal aspect of the femoral head and iliopsoas tendonitis. Selective injection of 1 mL iohexol-40 on the lesser trochanter of the femur resulted in a contrast cap-like image depicting "bursitis de novo" over the lesser trochanter (Fig. 2). Finally, injecting 40 mg triamcinolone in 2.5 mL 0.25% bupivacaine brought about transient pain relief and increased mobility on hip extension. One month later, selective injection at the distal insertion of the psoas muscle on the lesser trochanter of the femur, as described elsewhere (1), achieved 30% pain relief on the visual analogue scale (VAS). The patient underwent physiotherapy without success; 8

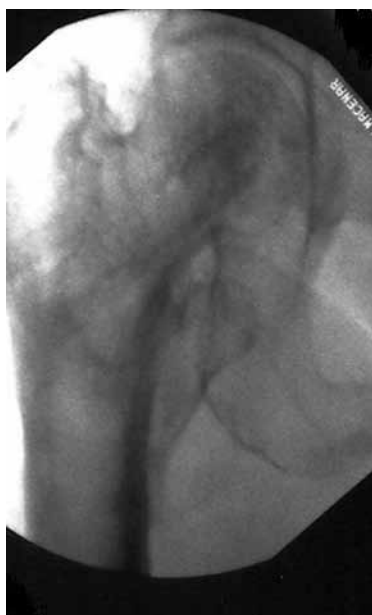

Fig. 1. Plain-film x-ray showing the larger-than-usual right lesser trochanter in contact with ischial bone.

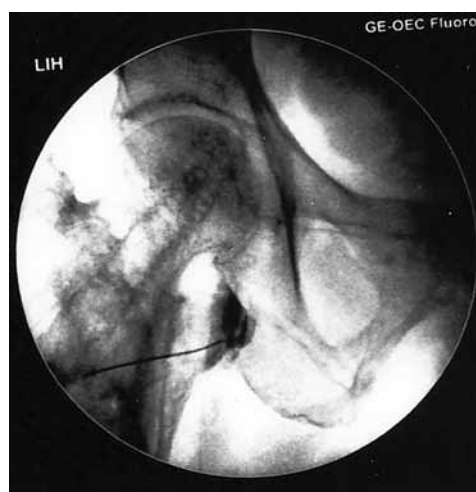


Fig. 2. A contrast cap-like image depicting "bursitis de novo" over the right lesser trochanter.

months later, total hip replacement at another center achieved 50% relief on VAS and increased mobility.

Comments

Ischiofemoral impingement was first described in 1977 by Johnson (2), who reported 3 patients with persistent pain after total hip replacement. Patti et al (3) reported a case with hip pain involving the quadratus femoris and no history of surgery. The unremitting pain, localized in the groin or buttock, can radiate distally. The symptoms may be reproduced by a combination of extension, adduction, and external rotation of the hip (4). The differential diagnosis includes iliopsoas impingement (1), hip adductor or rotator tears, neurological engagement, and related hip joint disorders (5). In a comprehensive radiological study, Torriani et al (6) reported that the ischiofemoral space (the smallest distance between the lateral cortex of the ischial tuberosity and medial cortex of the lesser trochanter) was reduced to 13 ± 5 mm in patients with ischiofemoral impingement compared to the normal value of 23 ± 8 mm; the quadratus femoris muscle, which occupies the space between the lesser trochanter and the ischium, may be compressed between these 2 bony structures. The quadratus femoris space (the smallest distance between superolateral surface of the hamstring tendons and posteromedial surface of the iliopsoas tendon or lesser trochanter) was reduced to 7 ± 3 mm compared to the normal value of 12 ± 4 . Nevertheless, the distance between the lesser trochanter and ischial bone in ischiofemoral impingement ranges from slightly below the normal range to zero, with permanent contact be-

tween bones (kissing bones). MRI is the most reliable diagnostic tool, particularly in subtle cases with normal radiological and ultrasound appearances. MRI can show edema, sclerosis, or cystic lesions of the lesser trochanter and ischium, as well as edema, tearing, fat infiltration, atrophy, or deformity of the quadratus femoris. In our unique case, imaging clearly demonstrated that the lesser trochanter was in permanent contact with the ischium. The lesser trochanter was larger than usual, probably because of abnormal bone remodeling after the previous hip fracture and the surgical osteosynthesis implant. It seems that the uncontrolled convulsions in the epileptic seizure were the precipitating event.

"Bursitis de novo" (7) occurring at anatomically predisposed locations, such as around hallux valgus, are well known. These lesions have no synovial lining; they result from fibrinoid necrosis of connective tissue in areas subject to chronic frictional irritation. Bursography (8), which involves the injection of contrast agent into a bursa, also enables the precise injection of diagnostic/therapeutic local anesthetic with/without corticosteroids, as in our case. The definitive treatment for ischiofemoral impingement is not yet clear. Radiologically or ultrasound-guided infiltration of a combination of local anesthetic and steroid into this space, prolotherapy, and physical therapy can be useful (9-11). Endoscopic decompression has an increasing role in treatment (12), and the excision of the lesser trochanter could be a last resort (3). In our case, total hip replacement gave a moderately satisfactory outcome.

REFERENCES

- Dalmau-Carolà J. Iliopsoas impingement: A report of 2 cases. *Pain Practice* 2014; 14:457-460.
- Johnson KA. Impingement of the lesser trochanter on the ischial ramus after total hip arthroplasty: Report of three cases. *J Bone Joint Surg [Am]* 1977; 59-A:268-269.
- Patti JW, Ouellette H, Bredella MA, Torriani M. Impingement of lesser trochanter on ischium as a potential cause for hip pain. *Skeletal Radiol* 2008; 37:939-941.
- Stafford GH, Villar RN. Ischiofemoral impingement. *J Bone Joint Surg Br* 2011; 93-B:1300-1302.
- Dalmau-Carolà J. Myofascial pain syndrome affecting the quadratus femoris. *Pain Practice* 2010; 10:257-260.
- Torriani M, Souto SC, Thomas BJ, Ouellette H, Bredella MA. Ischiofemoral impingement syndrome: An entity with hip pain and abnormalities of the quadratus femoris muscle. *AJR Am J Roentgenol* 2009; 193:186-190.
- Van Hoenaeker FM, Van Dyck P, Gielen J, De Schepper AM, Parizel PM. Musculoskeletal System In: Reimer P, Parizel PM, Meaney JFM, Stichnoth FA (eds). *Clinical MR Imaging: A Practical Approach*. 3rd ed. Springer-Verlag, Berlin Heidelberg, 2010, p 290.
- Resnick D, Niwayama G. *Diagnosis of Bone and Joint Disorders*. WB Saunders Company, Philadelphia, 1988, 328.
- Lee S, Kim I, Lee SM, Lee J. Ischiofemoral impingement syndrome. *Ann Rehabil Med* 2013; 37:143-146.
- Backer MW¹, Lee KS, Blankenbaker DG, Kijowski R, Keene JS. Correlation of ultrasound-guided corticosteroid injection of the quadratus femoris with MRI findings of ischiofemoral impingement. *AJR Am J Roentgenol* 2014; 203:589-593.
- Kim WJ¹, Shin HY, Koo GH, Park HG, Ha YC, Park YH. Ultrasound-guided prolotherapy with polydeoxyribonucleotide sodium in ischiofemoral impingement syndrome. *Pain Practice* 2014; 14:649-655.
- Safran M¹, Ryu J. Ischiofemoral impingement of the hip: A novel approach to treatment. *Knee Surg Sports Traumatol Arthrosc* 2014; 22:781-785.