

Observational Study

Radiologic Analysis and Clinical Study of the Upper One-third Joint Technique for Fluoroscopically Guided Sacroiliac Joint Injection

Junghyun Park, MD¹, Hue Jung Park, MD², Dong Eon Moon, MD³, Gye Jeol Sa, MD², and Young Hoon Kim, MD²

From: ¹Department of Anesthesiology and Pain Medicine, Incheon St. Mary's Hospital, College of Medicine, The Catholic University of Korea; ²Department of Anesthesiology and Pain Medicine, Seoul St. Mary's Hospital, College of Medicine, The Catholic University of Korea; ³M Pain Clinic, Seoul, Korea

Address Correspondence: Young Hoon Kim, MD
Department of Anesthesiology and Pain Medicine, Seoul St. Mary's Hospital, College of Medicine, The Catholic University of Korea, 222 Banpo-daero, Seocho-gu, Seoul 137-701, Republic of Korea
E-mail: anekyh@catholic.ac.kr

Disclaimer: There was no external funding in the preparation of this manuscript.
Conflict of interest: Each author certifies that he or she, or a member of his or her immediate family, has no commercial association (i.e., consultancies, stock ownership, equity interest, patent/licensing arrangements, etc.) that might pose a conflict of interest in connection with the submitted manuscript.

Manuscript received: 03+24-2015
Accepted for publication: 04-14-2015

Free full manuscript: www.painphysicianjournal.com

Background: Sacroiliac intraarticular injection by the traditional technique can be challenging to perform when the joint is covered with osteophytes or is extremely narrow.

Objective: To examine whether there is enough space for the needle to be advanced from the L5-S1 interspinous space to the upper one-third sacroiliac joint (SIJ) by magnetic resonance image (MRI) analysis as an alternative to fluoroscopically guided SIJ injection with the lower one-third joint technique, and to determine the feasibility of this novel technique in clinical practice.

Study Design: MRI analysis and observational study.

Setting: An interventional pain management practice at a university hospital.

Methods: We analyzed 200 axial T2-weighted MRIs between the L5 and S1 vertebrae of 100 consecutive patients. The following measurements were obtained on both sides: 1) the thickness of fat in the midline; 2) the distance between the midline (Point C) and the junction (Point A) of the skin and the imaginary line that connects the SIJ and the most medial cortex of the ilium; 3) the distance between the midline (Point C) and the junction (Point B) of the skin and the imaginary line that connects the SIJ and the L5 spinous process; 4) the distance between the SIJ and midline (Point C) on the skin, or between the SIJ and the midpoint (Point C') of the line from Point A to Point B; and 5) the angle between the sagittal line and the imaginary line that connects the SIJ and the midline on the skin. The upper one-third joint technique was performed to establish the feasibility of the alternative technique in 20 patients who had unsuccessful sacroiliac intraarticular injections using the lower one-third joint technique.

Results: The mean distances from the midline to Point A and to Point B were 21.9 ± 13.7 mm and 27.8 ± 13.6 mm, respectively. The mean distance between the SIJ and Point C (or Point C') was 81.0 ± 13.3 mm. The angle between the sagittal line and the imaginary line that connects the SIJ and the midline on the skin was $42.8 \pm 5.1^\circ$. The success rate of sacroiliac intraarticular injections with the upper one-third joint technique was 90% (18/20).

Limitations: This was an observational study and lacked a control group.

Conclusions: Sacroiliac intraarticular injections with the upper one-third joint technique are advisable when it is hard to perform them with the lower one-third joint technique.

Key words: Buttock pain, fluoroscopy, low back pain, sacroiliac joint, sacroiliac joint pain

Pain Physician 2015; 18:495-503

Sacroiliac joint (SIJ) dysfunction is a potential cause of low back pain and/or buttock pain with or without referred pain (1-7). Based on the results of local anesthetic block, the prevalence of SIJ pain ranges between 10% and 26.6% (3,8,9). Because of the inability to confirm the diagnosis of SIJ dysfunction with non-invasive tests, SIJ injection has been considered the evaluation of choice to confirm a diagnosis (1,10). Previous systematic reviews have described good evidence for the diagnosis of SIJ pain using controlled comparative local anesthetic blocks, fair evidence for provocative testing to diagnose SIJ pain, and limited evidence for the diagnostic accuracy of imaging (1,10).

Accurate placement of SIJ injections with a blind technique is only successful in 12 – 22% of cases (11,12). Although several studies have reported the feasibility of ultrasound-guided SIJ injections (13-17), a higher injection rate into the joint cavity was observed with fluoroscopically guided SIJ injection. Some studies reported that sacroiliac periarticular injections might be as effective as sacroiliac intraarticular injections for therapeutic purposes due to blockade of the ligaments and the neural supply (18-23). However, based on the scarcity of literature reports, sacroiliac periarticular injection was assessed as lacking in evidence (10,24). Thus, sacroiliac intraarticular injection with the lower one-third joint technique is the most commonly used method of treating and managing SIJ pain.

However, sacroiliac intraarticular injection by the traditional technique can be difficult to perform due to osteophytes covering the joint or an extremely narrow joint space (17,25,26). Thus, the present study was conducted to determine whether there is enough space for the needle to be advanced from the L5-S1 interspinous space to the SIJ by magnetic resonance image (MRI) analysis as an alternative to fluoroscopically guided SIJ injection with the lower one-third joint technique, and to determine the feasibility of this novel block technique in clinical practice.

METHODS

The study was approved by the Seoul St. Mary's Hospital, Catholic University Institutional Review Board (IRB No. KC13QISI0633). Written informed consent was obtained from all of the patients who were supposed to undergo the SIJ block.

MRI Findings and Measurements

In total, 200 lumbosacral MRIs of 100 consecutive

patients (male:female = 1:1) who visited the outpatient pain clinic with symptoms of low back pain and/or sciatica and who underwent lumbosacral MRI prior to August 1, 2013, were used. The exclusion criteria included age below 19 or above 90 years, and those with tumors in the lumbosacral region or with screw fixation in the sacrum.

Axial T2-weighted images between the L5 and S1 vertebrae were used. The following measurements on both sides (Fig. 1) were obtained: 1) the thickness of fat in the midline (a); 2) the distance between the midline (Point C) and the junction (Point A) of the skin and the imaginary line that connects the SIJ and the most medial cortex of the ilium (b); 3) the distance between the midline (Point C) and the junction (Point B) of the skin and the imaginary line that connects the SIJ and the L5 spinous process (c); 4) the distance between the SIJ and midline (Point C) on the skin, or between the SIJ and the midpoint (Point C') of the line from Point A to Point B (d); and 5) the angle between the sagittal line and the imaginary line that connects the SIJ and midline on the skin (e).

Provided that Point A (Fig. 1) is placed on the opposite side of the SIJ, the distance between the midline and the junction of the skin and the imaginary line that connects the SIJ and the most medial cortex of the ilium would be recorded as a negative value. Data such as age, gender, height, and weight were obtained from medical records.

Clinical Study

The upper one-third joint technique was performed to establish the feasibility of the alternative technique in 20 patients who had unsuccessful sacroiliac intraarticular injections using the lower one-third joint technique due to an extremely narrow joint space or osteophytes covering the joints (25). Patients who had lumbosacral transitional vertebrae, screw fixation in the sacrum, local infection, or a coagulopathy were excluded.

Procedural Technique

The patients were prepared in a prone position with a pillow under the abdomen. The procedure area was prepared and draped in the usual sterile fashion. All of the procedures were performed by a physician with more than 10 years' experience with SIJ injections. Before insertion of the needle, the subcutaneous tissue was infiltrated with 1% lidocaine in the midline of the L5-S1 interspinous space. A 10 cm long, 22-gauge

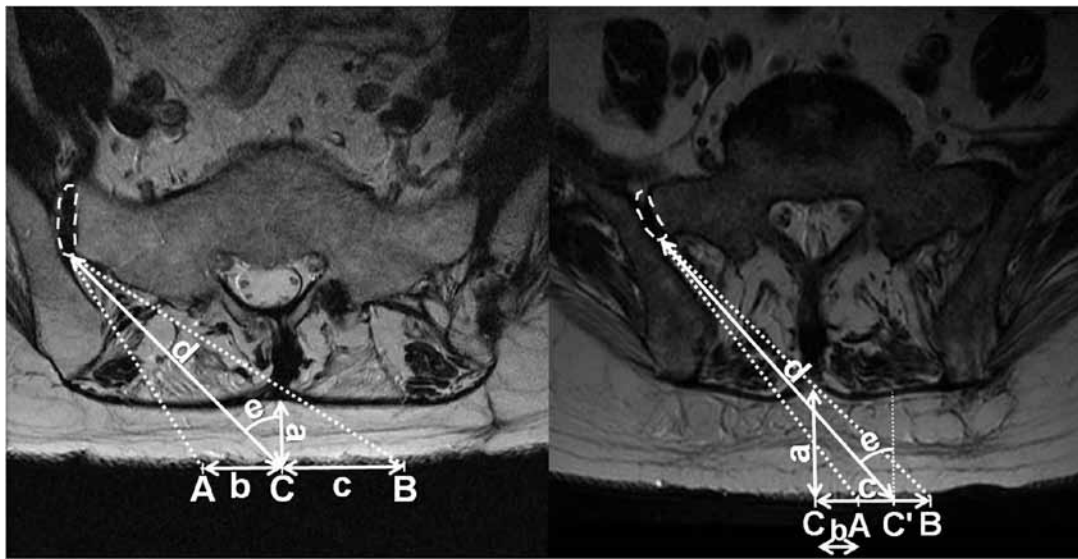


Fig. 1. Measured parameters (A, the junction of the skin and the imaginary line that connects the SIJ and the most medial cortex of the ilium; B, the junction of the skin and the imaginary line that connects the SIJ and the L5 spinous process; C, midline on the skin; C', the midpoint of the line from Point A to Point B; dashed area, SIJ; a, the thickness of fat in the midline; b, the distance between Point A and Point C; c, the distance between Point B and Point C; d, the distance between Point C and the SIJ; e, the angle between the sagittal line and the imaginary line that connects the SIJ and Point C). Point A is placed on the same side of the SIJ (left) and on the opposite side of the SIJ (right), respectively.

curved-tip spinal needle (Neurotic Nerve Block Needle, Hakko, Japan) was advanced into the skin and directed towards the upper one-third joint at about a 45° angle. As the needle hit a firm tissue on the silhouette of the iliac crest in the anteroposterior fluoroscopic view, we could distinguish between the sacrum and the iliac crest by rotating the curved needle. The curved-tip needle was advanced beyond the line of the iliac crest until the needle reached the joint with a pop sensation. The intraarticular position was confirmed by injecting 0.2 – 0.5 mL contrast material (Iobrix, 300 mgI/mL, Taejoon Pharm, Seoul, Korea) through the needle. The injected contrast material spread throughout the SIJ in a cephalocaudal fashion. After the contrast material outlined the SIJ without vascular runoff, a solution of steroid and local anesthetic (5 mg triamcinolone with 2 mL 0.4% lidocaine) was injected (Fig. 2). In the case of intravascular uptake, the same process was repeated after making a change in needle direction.

Clinical Data Collection

The following data were obtained: age, gender, height, weight, before and 30 minutes after the procedure numeric rating scales (NRS) for the assessment

of pain intensity, with a range of 0 (no pain) to 100 (worst pain imaginable), procedure time, grade of contrast spreading, occurrence of intravascular uptake or complications, and NRS for procedure-induced pain. Procedure time was defined as the interval between needle insertion and confirmation of contrast dispersion. Procedure failure was defined as a procedure where intraarticular injection was not confirmed or took longer than 300 seconds. Contrast spreading was graded as 1 = staying in the upper one-third of the joint, 2 = reaching the middle one-third of the joint, and 3 = reaching the lower one-third joint in fluoroscopic images.

Statistical Analyses

Student's t-test was used to analyze the measured parameters between the left and right sides. Simple linear regression analysis was used to analyze the correlations among age, body mass index (BMI), and measurements from MRIs. Age, BMI, before and 30 minutes after the procedure NRS for assessment of pain intensity, procedure time, and NRS for procedure-induced pain are presented as mean values with standard deviations (SDs). Before- and right after-procedural NRS

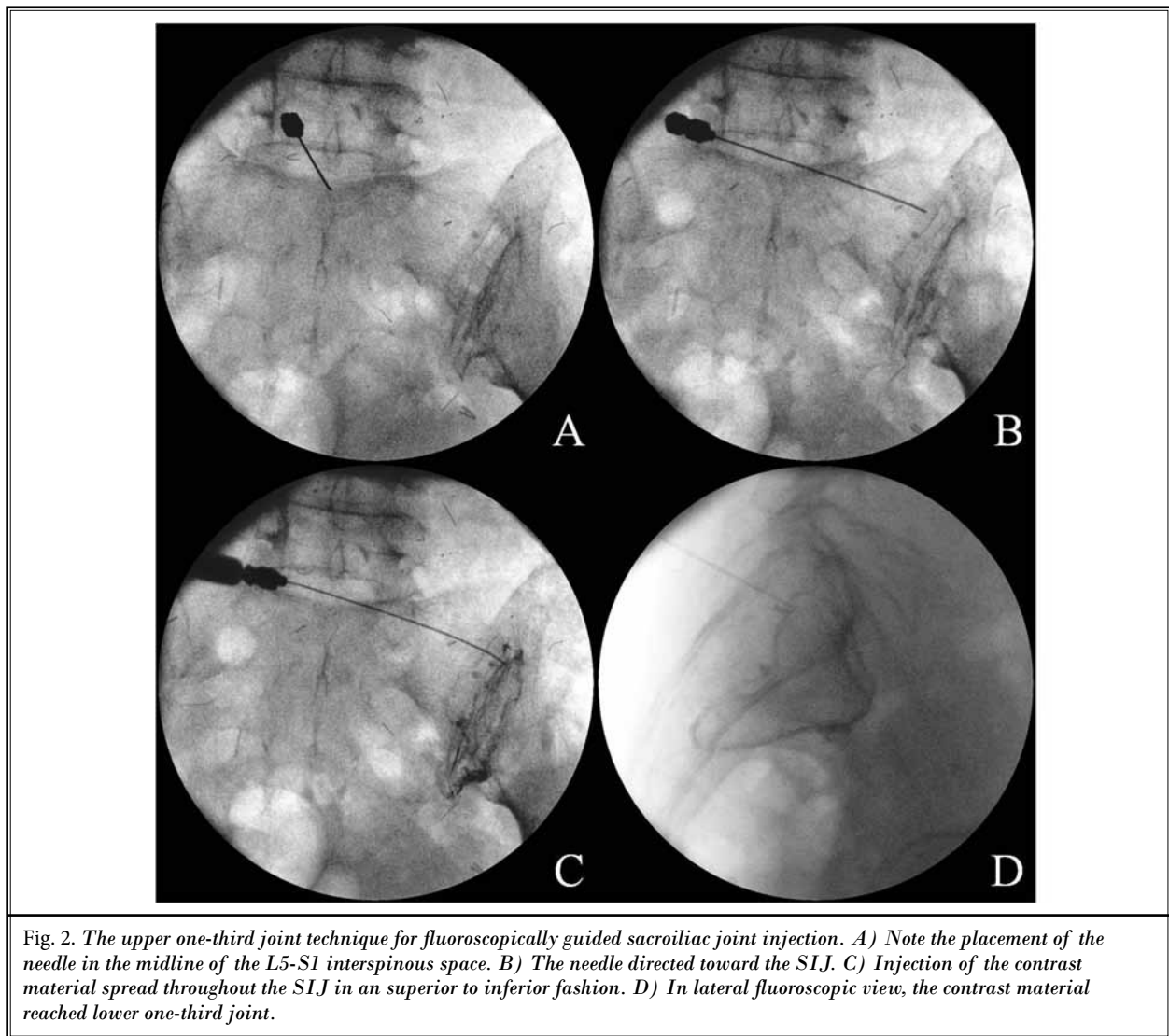


Table 1. Demographic data of patients whose MRIs were used in radiologic analysis.

Characteristics		
N		100
Gender (male/female)		50/50
Age (years)		58.4 (15.4)
Weight (kg)		61.8 (11.5)
Height (cm)		161.1 (9.7)
BMI (kg/m2)		23.7 (3.2)
Diagnosis	Herniated disc	39
	Spinal stenosis	57
	Post-spinal surgery syndrome	4

Values are presented as mean (SD) or count as appropriate. BMI = body mass index.

for pain were compared using a paired t-test. A *P* value < 0.05 was considered statistically significant. The SPSS software (ver. 18; SPSS, Inc., Chicago, IL) was used for statistical analyses.

RESULTS

Radiologic Study

Characteristics of patients whose MRIs were used in the radiologic analysis are shown in Table 1. Based on the measured parameters, the mean and SD were calculated. The results of the measurements are shown in Table 2; there were no significant differences between the left and right sides. Thus, all of the measurements

Table 2. Results of the measurements from MRIs.

Measurements	Left side (N = 100)	Right side (N = 100)	P	Combined (N = 200)
a (mm)	15.8 (8.6)	15.8 (8.6)	1.000	15.8 (8.6)
b (mm)	22.7 (14.3)	20.8 (13.9)	0.432	21.9 (13.7)
c (mm)	28.2 (14.3)	27.4 (12.9)	0.666	27.8 (13.6)
d (mm)	80.8 (12.9)	81.2 (13.7)	0.817	81.0 (13.3)
e (°)	42.9 (5.4)	42.7 (4.9)	0.745	42.8 (5.1)

Values are presented as mean (SD). a = the thickness of fat in the midline, b = the distance between the midline and the junction (Point A) of the skin and the imaginary line that connects the sacroiliac joint and the most medial cortex of the ilium, c = the distance between the midline and the junction (Point B) of the skin and the imaginary line that connects the sacroiliac joint and the L5 spinous process, d = the distance between the sacroiliac joint and midline on the skin, or between the sacroiliac joint and the midpoint of the line from Point A to Point B, e = the angle between the sagittal line and the imaginary line that connects the sacroiliac joint and midline on the skin, P values > 0.05 between the left and right sides.

were used in the analyses without distinguishing between the left and right sides. The mean thickness of fat in the midline was 15.8 ± 8.6 mm. The mean distances from the midline to Point A and Point B were 21.9 ± 13.7 mm and 27.8 ± 13.6 mm, respectively. The mean distance between the SIJ and Point C (or Point C') was 81.0 ± 13.3 mm. The angle between the sagittal line and the imaginary line that connects the SIJ and the midline on the skin was $42.8 \pm 5.1^\circ$.

The relationship between the thickness of fat and the distance between Point A and Point C was significant ($P < 0.001$; Fig. 3). The correlation coefficient, R, was 0.553. The R2 value indicated that 30.6% of variance in the distance between Points A and C could be explained by the thickness of fat ($R^2 = 0.306$; $F = 87.433$; $P < 0.001$). The regression results in Table 3 also showed that there was a negative relationship between the thickness of fat and the distance between Points A and C.

Of the 200 cases, 11 (5.5%) had negative values for the distance between Points A and C (Fig. 3, Table 4). In all of the 11 cases, the fat measured more than 30 mm in thickness. Their distances from Point C to Point A ranged from -4.1 to -27.5 mm. In the 14 (7%) cases whose fat measured more than 30 mm in thickness, the mean distance between the sacroiliac joint and the midline on the skin or between the sacroiliac joint and the midpoint of the line from Point A to Point B was 114.2 ± 13.7 mm.

Clinical Study

In a total of 20 patients, 20 fluoroscopically guided SIJ injections with the upper one-third joint technique

as an alternative method were performed to determine the feasibility of this novel block technique. Baseline characteristics and pre- and post-procedural data are shown in Table 5. The success rate of the procedure was 90% (18/20). The mean pre-procedural and post-procedural NRS for pain were 7.1 ± 1.1 and 1.1 ± 1.2 , respectively. The mean procedural time was 69.1 ± 50.4 seconds. In 2 cases, contrast material stayed in the upper one-third of the joint. In the rest of the cases, except the failed cases, contrast material reached the lower one-third of the joint.

DISCUSSION

The present study showed that there is enough space for the needle to be advanced from the L5-S1 interspinous space to the SIJ, and that the upper one-third joint technique may be an alternative option for SIJ injection. It can be challenging to successfully perform sacroiliac intraarticular injection with the conventional technique in cases where osteophytes cover the joint, the joint space is sinuous and narrow, or there is complex natural variation in individual anatomy (17,25,26). A few studies have reported unsuccessful sacroiliac intraarticular injection under fluoroscopic guidance; the failure rate was reported to be 3.3% (5/150) by Liliang et al (25) and 1.8% (1/50) by Jee et al (17). Several studies have suggested that periarticular injections might be as effective as intraarticular injections for therapeutic purposes (18-23). This means that sacroiliac regional pain might not only come from intraarticular structures, but rather, may come from periarticular structures, such as the posterior ligamentous tissue. However, sacroiliac

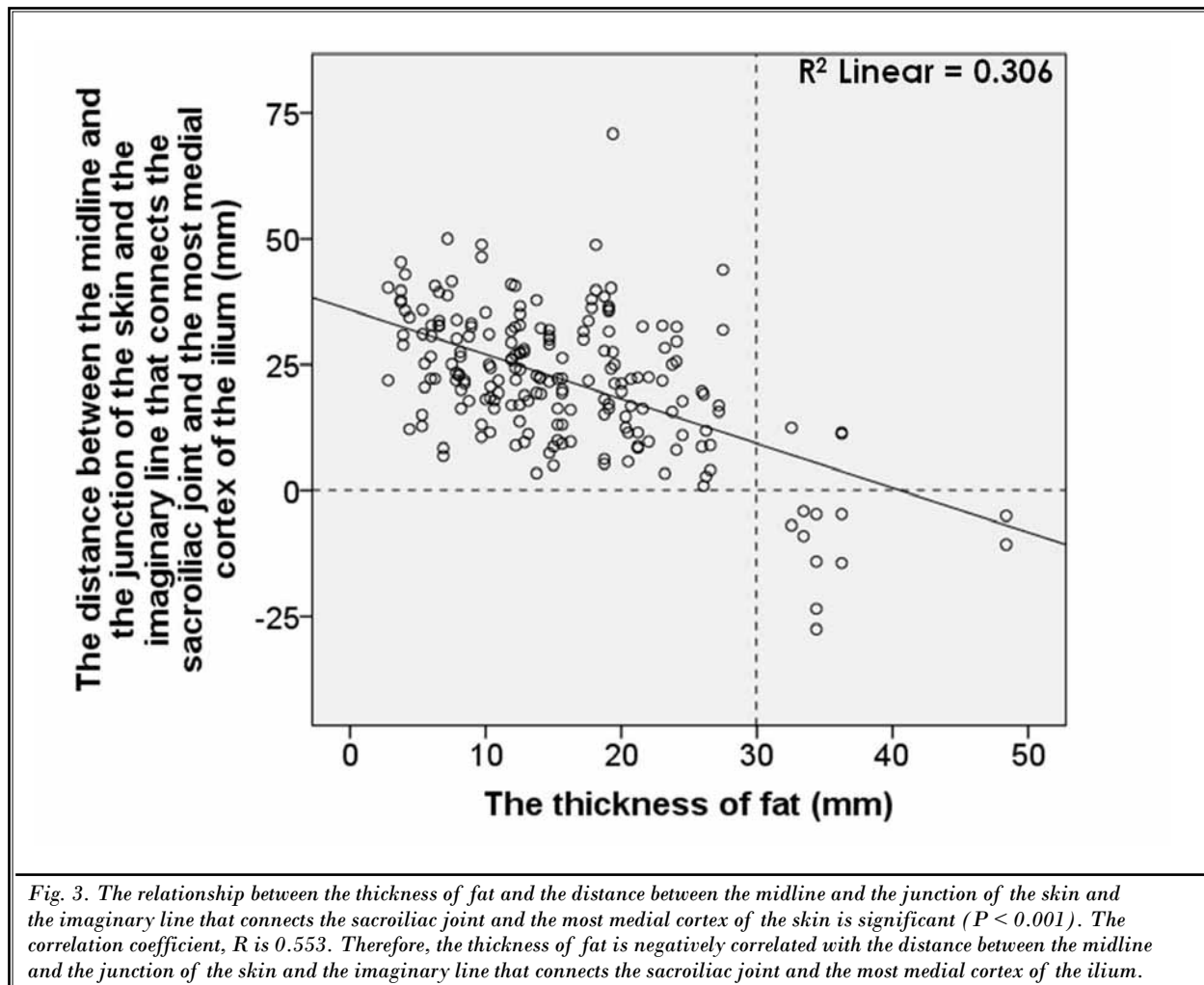


Table 3. Simple regression analysis: The relationship between the thickness of fat and the distance between Point A and Point C.

Independent Variable	Value
The thickness of fat	-0.553*
F value	87.433
R2	0.306
Adjusted R2	0.303

Point A = the junction of the skin and the imaginary line that connects the sacroiliac joint and the most medial cortex of the ilium, Point C = midline on the skin, R = correlation coefficient, * P value < 0.001 .

intraarticular injections are recommended when indications are satisfied with a suspicion of SIJ pain, because the evidence for diagnostic sacroiliac intraarticular injection is good (10). Sacroiliac intraarticular injection is necessary when there is a ventral outflow of painful material from the SIJ, which irrigates the neighboring lumbosacral plexus (27).

In the current radiologic study, Point C was located between Points A and B in 189 (94.5%) of 200 cases. This means that Point C can lead to the SIJ without obstruction in the majority of cases. The needle can be inserted obliquely, forming an approximate 45° angle with the skin surface. A 10 cm long spinal needle would be appropriate for the injection, because the mean distance between the SIJ and Point C (or Point C') was 81.0 ± 13.3 mm. Of the 200 cases, 14 (7%) cases had a thicker layer of fat, more than 30 mm thick. In 11 (5.5%) cases, Point

Table 4. Patients whose midline entry might be impossible.

	The thickness of fat (mm)	Point C to Point A (mm)	Point C to Point B (mm)
Case 1	33.4	-4.1	63.3
Case 2	34.4	-4.7	47.5
Case 3	36.3	-4.7	45.0
Case 4	48.4	-5.0	78.6
Case 5	32.6	-6.9	22.5
Case 6	33.4	-9.1	51.9
Case 7	48.4	-10.7	75.4
Case 8	34.4	-14.1	51.9
Case 9	36.3	-14.4	53.2
Case 10	34.4	-23.4	64.4
Case 11	34.4	-27.5	71.9

Point A = the junction of the skin and the imaginary line that connects the sacroiliac joint and the most medial cortex of the ilium, Point B = the junction of the skin and the imaginary line that connects the sacroiliac joint and the L5 spinous process, Point C = midline on the skin

A was located on the opposite side of the intended SIJ (Fig. 3, Table 4). This signifies that the needle insertion should not be started at the median line, but at the point approximately 20 – 30 mm off the median line in most patients with fat thickness of more than 30 mm. In these cases, however, a needle longer than 10 cm must be used. Given that the patients had lumbosacral MRIs, these would be helpful in finding a more elaborate needle pathway.

In the present clinical study, 18 of 20 (90%) patients showed successful sacroiliac intraarticular injection with the upper one-third joint technique. This indicates that this technique is feasible as an alternative injection, although the sample size was small. In 2 failed cases, we could neither estimate the thickness of the fat nor the proper location of the needle insertion because they had no lumbosacral MRI. The success rate of 90% is higher than the 80% reported in the study by Klausner et al (14) with ultrasound-guided SIJ injection at the level of the posterior sacral foramen 1 and 2. This difference in success rates might result from bony interference. At the level of the S1 and S2 foramen, the iliac crest protruded medially, forming the posterior superior iliac spine, which might restrict needle access to the joint (28,29). The level of the L5-S1 interspinous space used in our study directs the needle in a relatively caudal direction, and provides more space for the needle to be advanced compared to the level of the S1 and S2 foramen.

Due to unfamiliarity with the technique, the upper one-third joint technique was expected to cause more procedure-induced pain, longer procedure times, increased occurrence of intravascular uptakes, and a

Table 5. Baseline characteristics and pre- and post-procedural data.

Characteristics	
N	20
Gender (male/female)	4/16
Age (year)	53.8 (12.0)
Weight (kg)	61.9 (11.5)
Height (cm)	159.7 (9.7)
BMI (kg/m ²)	24.1 (2.7)
Before the procedure NRS for pain	7.1 (1.1)
30 min after the procedure NRS for pain	1.1* (1.2)
Procedure time (s)	69.1 (50.4)
Success rate of procedure (%)	90
Grade of contrast spreading	2.8 (0.7)
Occurrence of intravascular uptake	1
Occurrence of complications	0
NRS for procedure-induced pain	1.8 (1.6)

Values are presented as mean (SD) or count as appropriate.

* Indicates significant difference from Before the procedure NRS for pain ($P < 0.001$). BMI = body mass index, NRS = numeric rating scale.

lower grade of contrast spreading than the conventional technique. However, the procedural data for this alternative technique in Table 5 did not seem to differ from those of the conventional technique.

The present study had several limitations. First, this was an observational study lacking a control group. However, this study may provide a framework to move forward with a comparative study between the upper one-third joint technique and the lower one-third joint

technique. Second, the axial images of MRI used in this study were obtained in a supine position. There may be some numerical errors between the actual value during procedure and the measured value from the axial T2-weighted images because the SIJ injection was performed in a prone position.

CONCLUSION

In conclusion, sacroiliac intra-articular injections with the upper one-third joint technique are advisable

when it is difficult to perform sacroiliac intraarticular injections with the lower one-third joint technique.

Funding

The funding was solely from institutional and departmental sources.

Conflicts of interest

The authors have no conflicts of interest.

REFERENCES

1. Simopoulos TT, Manchikanti L, Singh V, Gupta S, Hameed H, Diwan S, Cohen SP. A systematic evaluation of prevalence and diagnostic accuracy of sacroiliac joint interventions. *Pain Physician* 2012; 15:E305-E344.
2. Bogduk N. The sacroiliac joint. In: *Clinical Anatomy of Lumbar Spine and Sacrum*. 4th ed. Churchill Livingstone, New York, 2005, pp 173-181.
3. Manchikanti L, Singh V, Pampati V, Damron KS, Barnhill RC, Beyer C, Cash KA. Evaluation of the relative contributions of various structures in chronic low back pain. *Pain Physician* 2001; 4:308-316.
4. Kennedy DJ, Shokat M, Visco CJ. Sacroiliac joint and lumbar zygapophysial joint corticosteroid injections. *Phys Med Rehabil Clin N Am* 2010; 21:835-842.
5. Fortin JD, Dwyer AP, West S, Pier J. Sacroiliac joint: Pain referral maps upon applying a new injection/arthrography technique. Part I: Asymptomatic volunteers. *Spine (Phila Pa 1976)* 1994; 19:1475-1482.
6. Schwarzer AC, Aprill CN, Bogduk N. The sacroiliac joint in chronic low back pain. *Spine (Phila Pa 1976)* 1995; 20:31-37.
7. Siddiq MA, Hasan SA, Das G, Khan AU. Interventional pain management in rheumatological diseases - a three years physiatric experience in a tertiary medical college hospital in Bangladesh. *Korean J Pain* 2011; 24:205-215.
8. Irwin RW, Watson T, Minick RP, Ambrosius WT. Age, body mass index, and gender differences in sacroiliac joint pathology. *Am J Phys Med Rehabil* 2007; 86:37-44.
9. Maigne JY, Aivaliklis A, Pfefer F. Results of sacroiliac joint double block and value of sacroiliac pain provocation tests in 54 patients with low back pain. *Spine (Phila Pa 1976)* 1996; 21:1889-1892.
10. Manchikanti L, Abdi S, Atluri S, Benjamin RM, Boswell MV, Buenaventura RM, Bryce DA, Burks PA, Caraway DL, Calodney AK, Cash KA, Christo PJ, Cohen SP, Colson J, Conn A, Corder H, Coubarous S, Datta S, Deer TR, Diwan S, Falco FJ, Fellows B, Geffert S, Grider JS, Gupta S, Hameed H, Hameed M, Hansen H, Helm S, 2nd, Janata JW, Justiz R, Kaye AD, Lee M, Manchikanti KN, McManus CD, Onyewu O, Parr AT, Patel VB, Racz GB, Sehgal N, Sharma ML, Simopoulos TT, Singh V, Smith HS, Snook LT, Swicegood JR, Vallejo R, Ward SP, Wargo BW, Zhu J, Hirsch JA. An update of comprehensive evidence-based guidelines for interventional techniques in chronic spinal pain. Part II: Guidance and recommendations. *Pain Physician* 2013; 16:S49-S283.
11. Rosenberg JM, Quint TJ, de Rosayro AM. Computerized tomographic localization of clinically-guided sacroiliac joint injections. *Clin J Pain* 2000; 16:18-21.
12. Hansen HC. Is fluoroscopy necessary for sacroiliac joint injections? *Pain Physician* 2003; 6:155-158.
13. Pekkafehli MZ, Kiralp MZ, Basekim CC, Silit E, Mutlu H, Ozturk E, Kizilkaya E, Dursun H. Sacroiliac joint injections performed with sonographic guidance. *J Ultrasound Med* 2003; 22:553-559.
14. Klauser A, De Zordo T, Feuchtner G, Sogner P, Schirmer M, Gruber J, Sepp N, Moriggl B. Feasibility of ultrasound-guided sacroiliac joint injection considering sonoanatomic landmarks at two different levels in cadavers and patients. *Arthritis Rheum* 2008; 59:1618-1624.
15. Klauser AS, De Zordo T, Feuchtner GM, Djedovic G, Weiler RB, Faschingbauer R, Schirmer M, Moriggl B. Fusion of real-time US with CT images to guide sacroiliac joint injection in vitro and in vivo. *Radiology* 2010; 256:547-553.
16. Chang WH, Lew HL, Chen CP. Ultrasound-guided sacroiliac joint injection technique. *Am J Phys Med Rehabil* 2013; 92:278-279.
17. Jee H, Lee JH, Park KD, Ahn J, Park Y. Ultrasound-guided versus fluoroscopy-guided sacroiliac joint intra-articular injections in the noninflammatory sacroiliac joint dysfunction: A prospective, randomized, single-blinded study. *Arch Phys Med Rehabil* 2014; 95:330-337.
18. Lee JH, Lee SH, Song SH. Clinical effectiveness of botulinum toxin A compared to a mixture of steroid and local anesthetics as a treatment for sacroiliac joint pain. *Pain Med* 2010; 11:692-700.
19. Luukkainen RK, Wennerstrand PV, Kautiainen HH, Sanila MT, Asikainen EL. Efficacy of periarticular corticosteroid treatment of the sacroiliac joint in non-spondylarthropathic patients with chronic low back pain in the region of the sacroiliac joint. *Clin Exp Rheumatol* 2002; 20:52-54.
20. Luukkainen R, Nissila M, Asikainen E, Sanila M, Lehtinen K, Alanaatu A, Kautiainen H. Periarticular corticosteroid treatment of the sacroiliac joint in patients with seronegative spondylarthropathy. *Clin Exp Rheumatol* 1999; 17:88-90.
21. Borowsky CD, Fagen G. Sources of sacroiliac region pain: Insights gained from a study comparing standard intra-articular injection with a technique combining intra- and peri-articular in-

- jection. *Arch Phys Med Rehabil* 2008; 89:2048-2056.
22. Murakami E, Tanaka Y, Aizawa T, Ishizuka M, Kokubun S. Effect of periarticular and intraarticular lidocaine injections for sacroiliac joint pain: Prospective comparative study. *J Orthop Sci* 2007; 12:274-280.
 23. Hartung W, Ross CJ, Straub R, Feuerbach S, Scholmerich J, Fleck M, Herold T. Ultrasound-guided sacroiliac joint injection in patients with established sacroiliitis: Precise IA injection verified by MRI scanning does not predict clinical outcome. *Rheumatology (Oxford)* 2010; 49:1479-1482.
 24. Hansen H, Manchikanti L, Simopoulos TT, Christo PJ, Gupta S, Smith HS, Hameed H, Cohen SP. A systematic evaluation of the therapeutic effectiveness of sacroiliac joint interventions. *Pain Physician* 2012; 15:E247-E278.
 25. Liliang PC, Lu K, Weng HC, Liang CL, Tsai YD, Chen HJ. The therapeutic efficacy of sacroiliac joint blocks with triamcinolone acetonide in the treatment of sacroiliac joint dysfunction without spondyloarthropathy. *Spine (Phila Pa 1976)* 2009; 34:896-900.
 26. Gupta S. Double needle technique: An alternative method for performing difficult sacroiliac joint injections. *Pain Physician* 2011; 14:281-284.
 27. Fortin JD, Washington WJ, Falco FJ. Three pathways between the sacroiliac joint and neural structures. *AJNR Am J Neuroradiol* 1999; 20:1429-1434.
 28. Chakraverty R, Pynsent P, Isaacs K. Which spinal levels are identified by palpation of the iliac crests and the posterior superior iliac spines? *J Anat* 2007; 210:232-236.
 29. Atlihan D, Bozkurt M, Turanli S, Dogan M, Tekdemir I, Elhan A. Anatomy of the posterior iliac crest as a reference to sacral bar insertion. *Clin Orthop Relat Res* 2004;141-145.

