

Case Series

Human Serum Modifies Aggregation Properties of Commonly Used Epidural Steroids

Sayed E. Wahezi, MD, Andrew Lederman, MD, Jeffrey Algra, MD, Soo Yeon Kim, MD, and Rani Sellers, PhD

From: Montefiore Medical Center, Bronx, NY

Address Correspondence:
Sayed E Wahez, MD
Montefiore Medical Center
Multidisciplinary Pain Program
3329 Bainbridge Ave
Bronx, NY 10467
E-mail:
swahezi@montefiore.org

Disclaimer: There was no external funding in the preparation of this manuscript.
Conflict of interest: Each author certifies that he or she, or a member of his or her immediate family, has no commercial association (i.e., consultancies, stock ownership, equity interest, patent/licensing arrangements, etc.) that might pose a conflict of interest in connection with the submitted manuscript.

Manuscript received: 12-31-2014
Revised manuscript received:
04-17-2015
Accepted for publication:
05-06-2015

Free full manuscript:
www.painphysicianjournal.com

Background: Case reports of catastrophic neurological sequelae during ESIs have questioned the safety of this procedure. A proposed mechanism is particulate steroid embolization resulting in neural ischemia. Previous reports have described steroid clumping in common epidural injection mixtures. We demonstrate that physiologic medium can also modify aggregation.

Objective: To inspect and compare aggregative properties of steroid preparations with and without human serum.

Setting: Academic tertiary care center.

Hypothesis: Particulate steroids display different aggregation characteristics in serum compared to non-physiologic solutions.

Design: Solutions were inspected under light microscopy: betamethasone sodium phosphate/betamethasone acetate, methylprednisolone, and dexamethasone were each mixed in lidocaine 1%, bupivacaine 0.5%, or sterile water in a 1:1 ratio. All preparations were inspected under light microscopy with 100x and 400x magnifications by a pathologist blinded to our expectations and hypothesis. Five random viewing fields were selected within each slide and the number of aggregates per field and the number of particles per aggregate was evaluated.

Results: The addition of serum had a significant effect on steroid particle aggregation and number of particles per aggregate.

Limitations: This study was limited by sample size as only 2 sets of human serum samples were tested with each preparation against one non-serum control. Additionally, as steroid preparations were evaluated under light microscopy, the ex vivo setting must be considered in the interpretation of results. Finally, mixing preparations with human serum as opposed to whole blood was necessary to allow for improved visibility on light microscopy despite the fact that whole blood may be necessary to more closely emulate in vivo coagulation setting.

Conclusions: Overall, the presence of serum resulted in fewer large steroid particle aggregates when compared to non-serum control samples. Amongst particulate steroids, betamethasone with bupivacaine 0.5% demonstrated the fewest and smallest particle aggregates, suggesting that preparation may reduce the risk of embolic infarction. Methylprednisolone formed significantly larger particles in bupivacaine 0.5% with serum compared to non-serum controls.

Key words: Corticosteroid, particulate aggregate, epidural injection, embolic infarction, serum

Pain Physician 2015; 18:E1131-E1138

An epidural steroid injection (ESI) is a common treatment to relieve radicular back pain. In recent years, much research has been dedicated to evaluating the true efficacy of this

intervention. Additionally, several case reports of significant morbidity have been published which have prompted new lines of questioning into the procedure's safety. As a result of these cases, in April

2014 the United States Food and Drug Association (FDA) issued a "warning that injection of corticosteroids into the epidural space of the spine may result in rare but serious adverse events, including loss of vision, stroke, paralysis, and death"(1).

Reported complications of ESIs have been described in the literature; they include vasodepressor syncope, headache, dural puncture, epidural hematoma, epidural abscess, and bacterial meningitis (2). One such complication gaining increasing attention is the introduction of steroid into arterial structures, resulting in embolic infarction of tissue. This is most likely when performing transforaminal injections, but it may also occur during other spinal procedures. Intravascular introduction of particulate steroid mixtures during a spinal injection can lead to spinal cord or cerebral infarction with devastating morbidity (3-7). The mechanism of injury, particularly pertaining to cervical transforaminal ESIs (CTFESI), may also be due to vasospasm of the anterior spinal artery causing anterior spinal cord syndrome or direct cord infarction (8-10).

Previous studies examined the size and aggregation of steroid crystals in native solutions or diluted with local anesthetic by light microscopy (11-13). Although examination of these mixtures may elucidate the behavior of these particles in vitro, they do not necessarily predict the behavior of steroid particulates in the intravascular space. While particle size may not be expected to change, its propensity to aggregate in human serum versus in its native preparation may be different. This study evaluates steroid particle behavior in an environment that resembles physiologic conditions more closely than what has been described. In this study, we examined the effect of human serum on steroid crystal aggregation.

METHODS

Betamethasone sodium phosphate/betamethasone acetate (celestone 6mg/mL), methylprednisolone (depo-medrol 40mg/mL), or dexamethasone (10mg/mL) were mixed in a 1:1 ratio with either lidocaine 1%, or bupivacaine 0.5% to make a steroid/anesthetic (SA) solution, or mixed 1:1 with sterile water to generate 9 total steroid solutions. The baseline steroid particle and aggregate sizes were determined by mixing these solutions at a 1:1 ratio in sterile water followed by immediate evaluation (within 30 seconds of mixing) by light microscopy using the 10X and 40X objectives (approximating 100- and 400-fold magnification, respectively).

Serum for these studies was obtained from 2 healthy

human subjects. Fresh whole blood was drawn into red top Vacutainer® tubes (no additives) and centrifuged at 10,000 rpm for 15 minutes. After centrifugation, the serum was collected (no hemolysis or lipemia was evident) and maintained at 37°C in a water bath. Each SA solution mixed in a 1:1 ratio with human serum and an aliquot was pipetted onto a glass slide and evaluated in the same manner as were the baseline steroid solution samples. Samples were evaluated within 30 seconds of mixing the steroid solution with the serum. The appearance of the particles and particle aggregates did not change as over 5 minutes. The pathologist was blinded to the study expectations and hypothesis.

Measurements of particle and aggregate size were done by taking photomicrographs of 5 randomly selected microscopic fields containing particles. Each field was photographed for analysis at 100- and 400-fold magnification. The histologist then described and counted the total number of particulate steroid aggregates as well as the number of particles forming each aggregate (single [1], double [2], triple [3], quadruple [4], and quadruple+ [4+] crystals). The particle and aggregate sizes were also measured (μm) in each field. The ratio of quadruple to total aggregates (RQT) and quadruple with quadruple+ to total aggregates (RQ+T) was calculated. We compared these ratios in the steroid solutions with serum to steroid solutions with sterile water. Comparison and statistical significance was evaluated using a 2-sided Mann-Whitney U-test resulting in Z scores and associated *P*-values.

RESULTS

Dexamethasone crystals, regardless of anesthetic choice, were not visible at 100-fold and 400-fold magnification and therefore no data on particle aggregates were included for this steroid solution. Dilution of all betamethasone solutions (water, lidocaine 1%, and bupivacaine 0.5%) 1:1 in human serum showed a decrease in both RQT and RQ+T compared to the native SA solution (Table 1). Betamethasone/water in serum and betamethasone/bupivacaine 0.5% in serum had RTQ and RTQ+ that were statistically different from their native solutions ($P < 0.01$). While betamethasone/lidocaine 1% in serum demonstrated a decrease in RQT and RQ+T compared to the native SA solution, this was not significant ($P > 0.05$) (Table 1). In the native solutions, single betamethasone particles ranged from 5 to 20 μm and large particles ranged from 40 to 100 μm . Large aggregations seen in the betamethasone/lidocaine 1% group measured from 60 to 120 μm . However, the larg-

est aggregates in the serum samples measured between 30 and 60 μm , indicating an overall decrease in the size of the large aggregate formation (Table 2).

The methylprednisolone/water solution failed to show a significant change in aggregation after mixing in serum. The methylprednisolone/lidocaine 1% solution mixed with serum demonstrated a significant decrease in RQT when combining all serum groups ($P < 0.05$). Methylprednisolone/bupivacaine 0.5% solution mixed with serum displayed a significant increase ($P < 0.05$) in RQT (Fig. 1).

Our results demonstrate that, *ex vivo*, serum decreases the size of betamethasone particle aggregates whether prepared in water, lidocaine 1%, or bupivacaine 0.5%. While serum does significantly reduce the percentage of large steroid aggregates in methylprednisolone/lidocaine 1%, the combination of methylprednisolone and bupivacaine 0.5% with serum resulted in increased steroid particle aggregate size.

Discussion

In 2011 an estimated 2.2 million epidurals were performed; this was approximately a 172% increase since the 800,000 performed in 2000 (14). The rapid growth of ESIs for back pain, in conjunction with an increase in reported associated major complications, has led to much attention directed at both the safety and efficacy of this interventional spine procedure. While devastating complications of spinal injections are exceedingly rare, understanding the magnitude of this complication is important to evaluate and optimize the safety of these injections. There is no data that quantifies the serious complications associated with spinal injections. However, published case reports and physician surveys have produced qualitative data regarding complications. In 2007, Scanlon et al (15), via a survey of 278 physicians, reported 30 major complications between 1990 and 2004 which included 12 cervical spinal cord infarcts, 16 vertebralbasilar brain infarcts, and 2 combined brain spinal/cord infarcts. In 2014, Engel and King (16), reviewed the literature, and in addition to those mentioned by Scanlon, noted 63 additional complications, 10 of which were fatal. These reports suggest that cervical transforaminal injections have the highest risk of serious side effects, followed by thoracic then lumbar transforaminals; though there is a risk of clinically significant steroid infarction with other steroid spinal injections such as interlaminar injections, the incidence is not as high. This is likely because most spinal neural foramen house a radicular artery. Interlaminar spaces

Table 1. RQT and RQ+TZ scores for each particulate steroid preparation.

PREP	RQT		RQ+T	
	Z-score	P-Value	Z-score	P-Value
Beta/W	-2.8	0.00512	-2.9333	0.00338
Beta/L1%	-1.6	0.1096	-0.8	0.42372
Beta/B0.5%	-3.0006	0.0027	-2.8782	0.00398
MP/W	-0.6736	0.50286		
MP/L1%	-2.1433	0.03236	-1.286	0.19706
MP/B0.5%	2.3883	0.01684	1.6534	0.09894

Beta – betamethasone; MP – methylprednisolone; L1% – lidocaine 1%; B0.5% – bupivacaine 0.5%

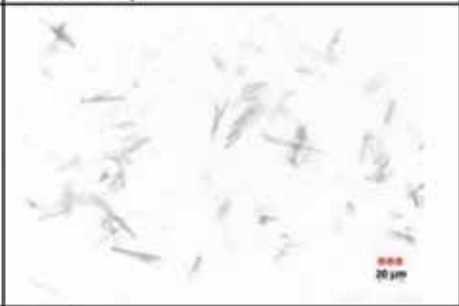





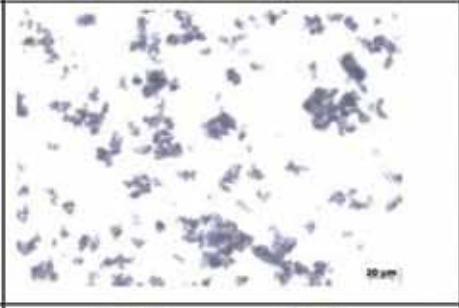


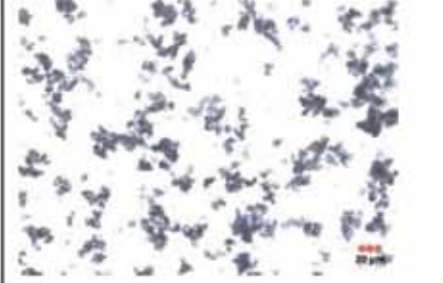
mostly contain small venous vasculature so infarction may not produce symptoms. Though complication rates may not be inferred from these publications, it does highlight complications encountered by physicians in the field.

Though exact complication rates remain unknown, many have directed efforts towards postulating possible mechanisms for these neurologic complications. One such mechanism, particularly specific to CTFESIs, is the occlusion of the vertebral artery or segmental artery accompanying the nerve root via embolization of the particulate steroid (14). Real time vascular injection studies suggest that intravascular injections are more common than previously reported (17). This has prompted several studies that have evaluated the microscopic appearance and behavior of various SA preparations. Under this assumption, it is believed that larger steroid particles and aggregates may increase the likelihood of embolic infarction. Conversely, it may be inferred that smaller particles and those with a lesser propensity to aggregate may decrease the risk of infarction.

Of the complications published in the literature, some identify the exact steroid preparation used. Scanlon et al (15) reported that of the 28 complications reported with known steroid preparations, methylprednisolone acetate was used in 21, betamethasone sodium phosphate, and sodium acetate in 3, triamcinolone acetonide in 3, methylprednisolone sodium succinate in 3, and dexamethasone sodium phosphate in 0 cases.

In an attempt to compare steroid safety, Benzon et al (12) evaluated the size of various steroid particles and the effect of various dilutions in saline and lido-

Table 2. 100x images of betamethasone (Beta) and methylprednisolone (MP) in all 3 preparations comparing native dilutant against human serum. 20 µm legend demonstrates relative size of red blood cells to particle size.

Injectate	Native Prep	Serum
Beta + Water		
Beta + Lidocaine1%		
Beta + Bupivacaine 0.5%		
MP + Lidocaine1%		
MP + Bupivacaine 0.5%		

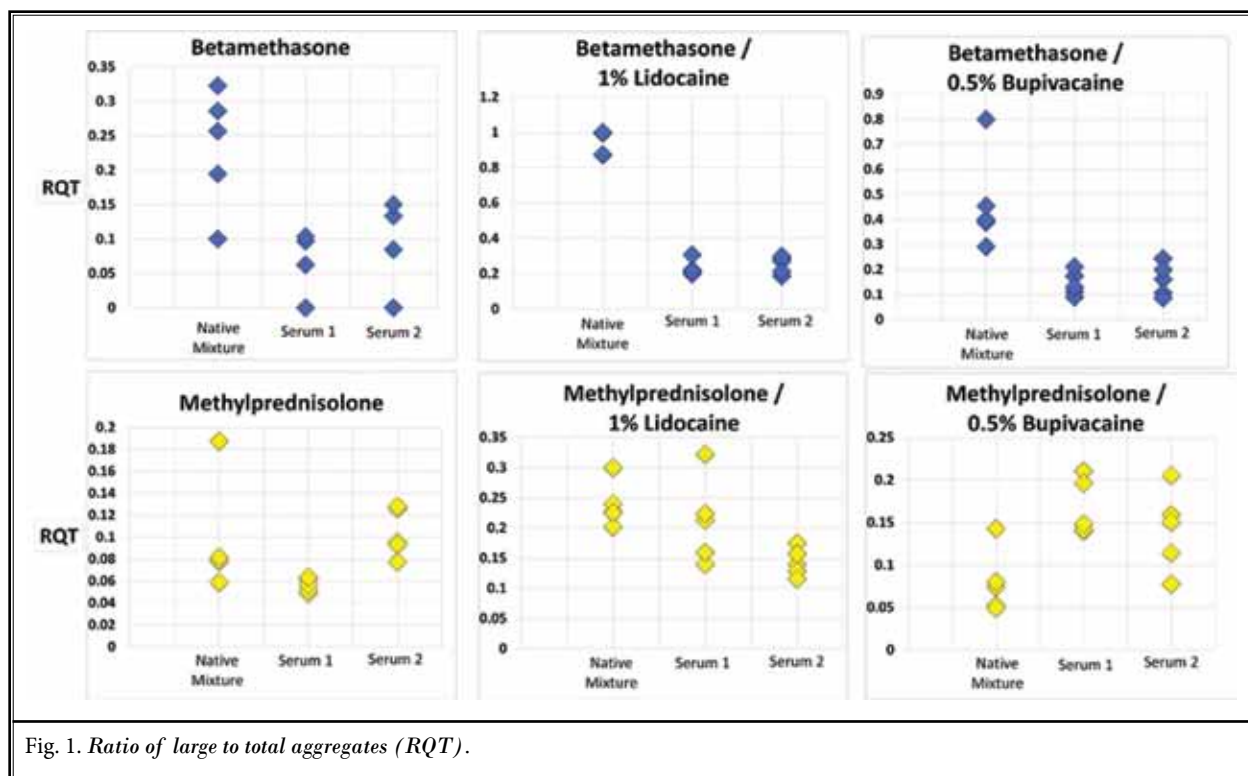


Fig. 1. Ratio of large to total aggregates (RQT).

caine 1%. Compounded betamethasone was found to have the smallest particle size of the particulate steroids and thus was recommended for strong consideration for CTFESIs when a particulate steroid was desired by the physician.

In 2008, Derby et al (11) similarly evaluated particle size using light microscopy, but also assessed each steroid's propensity to aggregate in lidocaine 1% with and without the addition of contrast dye. They found that dexamethasone had the smallest particle size, less than the size of one red blood cell, and had no particle aggregation. Of the particulate steroids, triamcinolone and compounded betamethasone formed more extensive aggregates than methylprednisolone preparations regardless of dye inclusion (11). Our results support Derby et al's methylprednisolone finding. We did not include triamcinolone in our study.

Both the Benzon et al (12) and Derby et al (11) studies reveal information about steroid particle behavior under the microscope that may guide physicians in both steroid selection and preparation with the goal to reduce the risk and morbidity of ischemia due to particulate embolism. Our study is the first study we are aware of to assess particulate steroid aggregation in serum. Methylprednisolone, betamethasone, and dexametha-

sone were chosen because they are commonly used steroids for spinal injections and the aforementioned investigators used these in their landmark publications. Lidocaine and bupivacaine were used for the same reason. The triamcinolone was not chosen because the FDA recently discouraged the use of this medication for intraspinal use. Accordingly, though there are no large studies that describe epidural injection preparations, the authors believe that the steroid and local anesthetic solutions mentioned in this manuscript are reflective of what is mostly used in epidural spinal injection preparations. The particulate sizes in this study were in accordance with sizes seen in previous studies. However, the addition of serum resulted in a notable change in the microscopic appearance of the steroid particles, and particle aggregation was different than reported by Derby et al (11). Derby et al (11) found that aggregation of methylprednisolone was greater than betamethasone. However this study revealed that in human serum, betamethasone, when combined with bupivacaine 0.5%, had less particle aggregation than without serum. From this, one may infer that amongst particulate steroids, the mixture of betamethasone and 0.5% bupivacaine may have the lowest risk of neurologic complications from particulate embolism.

Table 3. Published cases of infarctions following spinal injections.

Adverse Event	Fatal	Corticosteroid	Local Anesthetic	Procedure	Reference
Cervical spinal cord infarct	yes	Triamcinolone	Bupivacaine	CTFESI	Brouwers et al(18)
Cervical spinal cord infarct	no	Triamcinolone	Lidocaine	CTFESI	Brouwers et al(19)
Cortical blindness	no	None	None	CTFESI	McMillan & Crumpton (7)
Uncal and cerebellar herniation	yes	Methylprednisolone	Bupivacaine	CTFESI	Rozin et al(20)
Cervical cord and cerebellar infarct	no	Betamethasone	Lidocaine	CTFESI	Windsor et al(21)
Cerebellar and occipital lobe infarct	yes	Triamcinolone	Bupivacaine	CTFESI	Tiso et al(6)
Cervical spinal cord infarct	no	Triamcinolone	Bupivacaine	CTFESI	Ludwig and Burns(22)
Cervical spinal cord infarct	yes	Cortisone	Lidocaine	CTFESI	Meyer et al(23)
Spinal cord infarct	no	Betamethasone	Bupivacaine	LTFESI	Kennedy et al (24)
cerebellar herniation	no	Methylpredisolone	Lidocaine	CTFESI	Beckman et al (25)
Spinal cord infarct	no	Triamcinolone	Bupivacaine	LTFESI	Somayaji et al (26)
Cerebellar and brainstem infarct	no	Triamcinolone	None	CTFESI	Suresh et al (27)
Transverse Myelitis	no	Betamethasone	Bupivacaine/ epinephrine	LTFESI	Deshpande et al (28)
Transverse Myelitis	no	Triamcinolone	Bupivacaine	LTFESI	Lyders et al (29)
Spinal cord infarct	no	Methylpredisolone	None	CTFESI	Popescu et al (30)
Paraplegia	No	Triamcinolone	Bupivacaine	TIL	Tripathy et al (31)
Quadraplegia	No	Methylpredisolone	None	CIL	Bose et al (32)
Stroke	Yes	Triamcinolone	None	CF	Edlow et al (33)
Stroke	Yes	Methylpredisolone	None	CIL	Ziai et al (34)

TIL: Thoracic interlaminar; CIL: Cervical interlaminar; CF: Cervical facet

Additionally, this study showed an increase in large aggregate formation when the SA mixture of methylprednisolone and bupivacaine 0.5% was combined with serum. One may infer that this SA mixture may have an increased risk of particle embolism potentially having neurologic sequelae.

There are several published cases of adverse events resulting in brain or spinal cord ischemia following spinal injections (Table 3). Table 3 includes the SA mixtures that were used. Triamcinolone was used in half of the listed adverse events. Two of the cases represent SA preparations that were tested in our study and both support our findings. In our study, the combination of methylprednisolone and bupivacaine (20) showed a significant increase in crystal aggregation when mixed in serum. Additionally, the betamethasone and lidocaine mixture (21) failed to show a significant decrease in crystal aggregation when mixed in serum. This table suggests that there may be a link between a SA mixture's propensity to aggregate in physiologic conditions which may affect the risk of brain or spinal cord ischemia.

One limitation of this study was its ex-vivo interpretation of in-vivo activity. Additionally, evaluating SA preparations in human serum may render results dif-

ferent than those obtained when mixing with whole blood. Evaluating steroid behavior in whole blood, while scientifically optimal, is not practical as red blood cells fill the microscopic field and do not allow for clear viewing of steroid particles.

Data samples were limited to 2 healthy human serum samples. This study did not control for variability of blood composition such as pH or osmolality which may impact particulate behavior. Triamcinolone was not evaluated as previous investigators demonstrated that even a sentinel particle can occlude a medium sized vessel (8,11). Our study was designed to assess a possible change in embolization properties by modifying aggregation, thus mitigating the value of assessing triamcinolone here. Finally, the exact mechanism of brain or spinal cord damage as a complication from spinal injections remains unclear and this study is focused on the particle size as a component of morbidity.

Further research is needed to demonstrate the clinical value of this ex vivo study.

CONCLUSION

Particulate SA mixtures behaved differently when combined with serum as compared to previous studies presented in the literature. Betamethasone and bupiva-

caine 0.5% in serum showed the least amount of large crystal aggregates. Methylprednisolone in bupivacaine 0.5% demonstrated increased formation of large crystal aggregates in serum compared to sterile water. This study reveals information that may increase safety and influence anesthetic and steroid choice if a particulate steroid is desired for transforaminal epidural injection.

Comparing steroid preparations with dexamethasone in its native preparation versus in human serum proved to be of low clinical significance due to the small size particles and absence of large aggregate formations under the microscopic settings used.

We demonstrated a significant decrease in large betamethasone crystal aggregates when mixed with water or local anesthetic and human serum. Macroscopic evidence of precipitation such as that seen with triamcinolone and microscopic evidence of aggregate formation of betamethasone and lidocaine 1% may influence physicians to choose bupivacaine 0.5% as anesthetic diluent; this displayed smaller size aggregates as well as a significant decrease in large steroid particle formation.

The only methylprednisolone group that demonstrated a significant decrease in aggregation when mixed with human serum was the lidocaine 1% group. We suggest using betamethasone over methylprednisolone, but if methylprednisolone is preferred, we suggest using lidocaine 1% as anesthetic dilute.

Both betamethasone and methylprednisolone steroids formed large crystal aggregations ranging from 40 to 100 μm in size. The betamethasone mixtures displayed a decrease in size of the large aggregates when mixed with human serum.

In a clinical setting where a particulate steroid and local anesthetic is desired for intraspinal or paraspinal use, our ex vivo study suggests that betamethasone and 0.5% bupivacaine may produce the least end-artery clotting; therefore, in anatomical locations where arterial injection is considered a high risk (cervical>thoracic>lumbar transforaminals) this should be considered.

Here, we analyzed the effect of particulate steroids in physiologic medium and suggest that some preparations may be safer than others.

REFERENCES

1. FDA Drug Safety Communication: FDA requires label changes to warn of rare but serious neurologic problems after epidural corticosteroid injections for pain. March 2014. www.fda.gov/Drugs/DrugSafety/ucm394280.htm
2. McGrath J, Schaefer M, Malkamaki D. Incidence and characteristics of complications from epidural steroid injections. *Pain Medicine* 2011; 12:726-731.
3. Baker R, Dreyfuss P, Mercer S, Bogduk N. Cervical transforaminal injection of corticosteroids into a radicular artery: A possible mechanism for spinal cord injury. *Pain* 2003; 103:211-215.
4. Rathmell JP, Aprill C, Bogduk N. Cervical transforaminal injection of steroids. *Anesthesiology* 2004; 100:1595-1600.
5. Huntoon MA, Martin DP. Paralysis after transforaminal epidural injection and previous spinal surgery. *Regional Anesthesia and Pain Medicine* 2004; 29:494-495.
6. Tiso RL, Cutler T, Catania JA, Whalen K. Adverse central nervous system sequelae after selective transforaminal block: The role of corticosteroids. *Spine Journal* 2004; 4:468-474.
7. McMillan MR, Crumpton C. Cortical blindness and neurologic injury complicating cervical transforaminal injection for cervical radiculopathy. *Anesthesiology* 2003; 99:509-511.
8. Derby R, Lee S-H, Kim B-J, Chen Y, Seo KS. Complications following cervical epidural steroid injections by expert interventionalists in 2003. *Pain Physician* 2004; 7:445-449.
9. Huntoon MA. Anatomy of the cervical intervertebral foramina: Vulnerable arteries and ischemic neurologic injuries after transforaminal epidural injections. *Pain* 2005; 117:104-111.
10. Suh DC, Kim SJ, Jung SM, Park MS, Lee JH, Rhim SC. MRI in presumed cervical anterior spinal artery territory infarcts. *Neuroradiology*. 1996; 38:56-58.
11. Derby R, Lee SH, Date ES, Lee JH, Lee CH. Size and aggregation of corticosteroids used for epidural injections. *Pain Medicine* 2008; 9:227-234.
12. Benzon HT, Chew TL, McCarthy RJ, Benzon HA, Walega DR. Comparison of particle sizes of different steroids and the effect of dilution: A review of the relative neurotoxicities of the steroids. *Anesthesiology* 2007; 106:331-338.
13. Gazelka HM, Burgher AH, Huntoon MA, Mantilla CB, Hoelzer BC. Determination of the particulate size and aggregation of clonidine and corticosteroids for epidural steroid injection. *Pain Physician* 2012; 15:87-93.
14. Manchikanti L, Pampati V, Boswell MV, Smith HS, Hirsch JA. Analysis of the growth of epidural injections and costs in the Medicare population: A comparative evaluation of 1997, 2002, and 2006 data. *Pain Physician* 2010; 13:199-212.
15. Scanlon G, Moeller-Bertram T, Romanowsky S, Wallace M. Cervical transforaminal epidural steroid injections. *Spine* 2007; 32:1249-1256
16. Engel A, King A. The effectiveness and risks of fluoroscopically guided cervical transforaminal injections of steroids: A systematic review with comprehensive analysis of the published data. *Pain Medicine* 2014; 15:386-402.
17. Sae Young Kim, Yun Young Kim, Ae Ra Kim. Incidence of intravascular insertion in thoracic epidural catheterization by using real time fluoroscopy. *Korean Journal of Anesthesiology* 2012; 62:251-255.
18. Brouwers PJ, Kottink EJ, Simon MA, Prevo RL. A cervical anterior spinal artery syndrome after diagnostic blockade of the right C6-nerve root. *Pain* 2001; 91:397-399.

19. Brouwers PJ, Kottink EJ, Simon MA, Prevo RL. Reply to Dr Nash. *Pain* 2002; 96:218-219.
20. Rozin L, Rozin R, Koehler SA, Shakir A, Ladham S, Barmada M, Dominick J, Wecht CH. Death during transforaminal epidural steroid nerve root block (C7) due to perforation of the left vertebral artery. *American Journal of Forensic Medicine and Pathology* 2003; 24:351-355.
21. Windsor RE, Storm S, Sugar R, Nagula D. Cervical transforaminal injection: Review of the literature, complications, and a suggested technique. *Pain Physician* 2003; 6:457-465.
22. Ludwig MA, Burns SP. Spinal cord infarction following cervical transforaminal epidural injection: A case report. *Spine* 2005; 30:E266-E268.
23. Meyer HJ, Monticelli F, Kiesslich J. Fatal embolism of the anterior spinal artery after local cervical infiltration. *Forensic Science International* 2005; 149:115-119.
24. Kennedy DJ, Dreyfuss P, Aprill CN, Bogduk N. Paraplegia following image guided transforaminal lumbar spine epidural steroid injection: Two case reports. *Pain Med* 2009; 10:1389-1394.
25. Beckman WA, Mendez RJ, Paine GF, Mazzilli MA. Cerebellar herniation after cervical transforaminal epidural injection. *Reg Anesth Pain Med* 2006; 31:282-285.
26. Somayaji HS, Saifuddin A, Casey AT, Briggs TW. Spinal cord infarction following therapeutic computed tomography-guided left L2 nerve root injection. *Spine (Phila Pa 1976)* 2005; 30:E106-E108.
27. Suresh S, Berman J, Connell DA. Cerebellar and brainstem infarction as a complication of CT-guided transforaminal cervical nerve root block. *Skeletal Radiol* 2007; 36:449-452.
28. Deshpande DM, Krishnan C, Kerr DA. Transverse myelitis after lumbar steroid injection in a patient with Behcet's disease. *Spinal Cord* 2005; 43:735-737.
29. Lyders EM, Morris PP. A case of spinal cord infarction following lumbar transforaminal epidural steroid injection: MR imaging and angiographic findings. *AJNR* 2009; 30:1691-1693.
30. Popescu A, Gardner K. An unusual mechanism for spinal cord infarction – case report. *Ann Neurol* 2007; 62:S32.
31. Tripathi M, Nath SS, Gupta RK. Paraplegia after intracord injection during attempted epidural steroid injection in an awake-patient. *Anesth Analg* 2005; 101:1209-1011, table of contents.
32. Bose B. Quadriplegia following cervical epidural steroid injections: Case report and review of the literature. *Spine J* 2005; 5:558-563.
33. Edlow BL, Wainger BJ, Frosch MP, Copen WA, Rathmell JP, Rost NS. Posterior circulation stroke after C1-C2 intraarticular facet steroid injection: Evidence for diffuse microvascular injury. *Anesthesiology* 2010; 112:1532-1535.
34. Ziai WC, Ardelt AA, Llinas RH. Brainstem stroke following uncomplicated cervical epidural steroid injection. *Arch Neurol* 2006; 63:1643-1646.