

## Randomized Trial

# Intravenous Parecoxib and Continuous Femoral Block for Postoperative Analgesia after Total Knee Arthroplasty. A Randomized, Double-Blind, Prospective Trial

Despoina G Sarridou, MD<sup>1,2,3</sup>, Georgia Chalmouki, MD<sup>1</sup>, Maria Braoudaki, PhD<sup>4</sup>, Anna Koutsoupaki, MD<sup>1</sup>, Argiro Mela, MD, PhD<sup>1</sup>, and Athina Vadalouka, MD, PhD<sup>5</sup>

From: <sup>1</sup>Department of Anaesthesia and Management, Asklepeion Voulas General Hospital, Athens; <sup>2</sup>Department of Anaesthesia Critical Care and Pain Management, The Royal Brompton and Harefield NHS Trust, Harefield Hospital, London, UK; <sup>3</sup>Anaesthesia Cancer and Surgery Division, Imperial College London, UK; <sup>4</sup>University Research Institute for the Study and Treatment of Childhood Genetic and Malignant Diseases, University of Athens, Aghia Sophia Children's Hospital, Athens, Greece; <sup>5</sup>A' Anesthesia Clinic and Pain and Palliative Care Centre, University of Athens, Aretaieion University Hospital, Athens

Address Correspondence:  
Dr Despoina Sarridou, MD  
Senior Clinical Fellow  
Department of Anaesthesia Critical Care and Pain Management  
The Royal Brompton and Harefield NHS Trust  
Harefield Hospital, London, UK  
Critical Research Fellow  
Anaesthesia Cancer and Surgery Division,  
Imperial College London, UK  
25 Kenmore Close  
Kent Road, Richmond Surrey UK  
TW9 3JG  
E-mail: dodasarri@yahoo.gr

Disclaimer: There was no external funding in the preparation of this manuscript. Conflict of interest: Each author certifies that he or she, or a member of his or her immediate family, has no commercial association (i.e., consultancies, stock ownership, equity interest, patent/licensing arrangements, etc.) that might pose a conflict of interest in connection with the submitted manuscript.

Manuscript received: 10-02-2014  
Revised manuscript received:  
12-02-2014, 02-24-2015  
Accepted for publication: 02-26-2015

Free full manuscript:  
[www.painphysicianjournal.com](http://www.painphysicianjournal.com)

**Background:** Up until now, the optimal strategy for postoperative pain management after total knee arthroplasty (TKA) remains to be elucidated.

**Objective:** The current investigation aimed to examine the analgesic efficacy and the opioid sparing effects of intravenous parecoxib in combination with continuous femoral blockade.

**Study Design:** Randomized, double-blind, prospective trial.

**Setting:** University hospital in the United Kingdom.

**Methods:** In total, 90 patients underwent TKA under subarachnoid anesthesia and received continuous femoral block initially as a bolus with 20 mL of ropivacaine 0.75%. Infusion of 0.2% on 10 mL/h followed. Patients were randomized into 2 groups. Group D and Group P received parecoxib and placebo, respectively at 12 hour time intervals. Visual analog scale (VAS) pain scores were obtained at different time intervals including 4, 8, 12, 24 and 36 hours. The pain scores were measured with patients in a resting position. Morphine could also be administered with a patient controlled analgesia (PCA) pump if the specified analgesia was deemed inadequate (VAS > 5).

**Results:** None of the patients were withdrawn from the study. Parecoxib provided greater relief than placebo following TKA. The VAS pain scores measured at rest were statistically significantly lower in parecoxib-treated patients compared to the placebo group ( $P = 0.007$ ) at 4 ( $P = 0.044$ ), 12 ( $P = 0.001$ ), and 24 hours ( $P = 0.012$ ), postoperatively. Patients receiving parecoxib consumed less morphine at all time intervals than patients receiving placebo, with borderline statistical significance ( $P = 0.054$ ). In each time period, all patients receiving continuous femoral block irrespectively of the treatment group, required low morphine doses.

**Limitations:** Current protocol did not answer question as to functional recovery.

**Conclusion:** According to our findings intravenous parecoxib in combination with continuous femoral block provided superior analgesic efficacy and opioid sparing effects in patients undergoing TKA.

**Key words:** Anesthesia, TKA, morphine, opioids, VAS scores, continuous femoral block

**Pain Physician 2015; 18:267-276**

Currently, regardless of the advances in understanding the mechanisms underlying pain and the introduction of novel strategies, the ideal management of postoperative pain following total knee arthroplasty (TKA) remains to be elucidated. TKA is typically associated with moderate to severe postoperative pain (1,2), due to the rich innervation of the knee joint and the femoral, obturator, and sciatic nerves (3), delaying convalescence (4), prolonging hospitalization (5) and increasing patient discomfort, (6) or risks of postoperative complications (7,8). Failure to provide adequate analgesia impedes aggressive physiotherapy and rehabilitation (9).

Peripheral nerve blockade of one or more major nerves supplying the lower limb could theoretically provide effective analgesia (10). Unambiguously, continuous peripheral nerve blocks have been shown to be more efficient in postoperative analgesia and patient satisfaction, while offering few side effects and accelerated functional recovery (11,12). Within this context, continuous femoral nerve block is frequently and efficiently used to provide postoperative analgesia and related advantages concerning final outcome following surgical procedures (13-15). Several reports suggested that an ultrasound (US)-guided single-injection femoral nerve block improved patient satisfaction and reduced consumption of morphine during the first 48 hours (16), prolonged surgical anesthesia and postoperative analgesia (17,18), reduced rates of mechanical nerve injury (19), and resulted in low frequencies of neurological complications (20). However, according to Gandhi et al (21) catheter insertion without US monitoring might be more common due to its simplicity and the fact that it can be performed by a single operator. Alternatively, classic nerve stimulator guided peripheral nerve block has a very high efficiency, thus whether US-guided blocks will ever replace neurostimulation techniques remains debatable especially when regional anesthesia is performed by specialists in the field (11,17). In order to minimize motor block in the postoperative period and maintain postoperative pain management, low concentrations of long-acting anesthetic solutions including ropivacaine are mostly used (1,22), although the optimal concentration to maximize analgesia and minimize motor block remains unknown (1,23). Previous studies have confirmed that the effective postoperative pain management of this strategy is equivalent to continuous epidural analgesia and continuous lumbar plexus block following TKA, with even fewer side effects (12). However, posterior knee pain frequently requires ad-

ditional forms of analgesia (23).

Intravenous infusion of cyclooxygenase 2 (COX-2) antagonists could provide pain relief (24). The analgesic effects of parecoxib administered preoperatively or during interventional techniques have been well established (25). Based on clinical trials, the first perceptible analgesic effect of parecoxib occurs within 7 to 13 minutes, with clinically meaningful analgesia demonstrated within 23 – 39 minutes and a peak within 2 hours following administration of 40 mg intravenously (26).

However, to our knowledge, the optimal strategy to provide paramount postoperative pain relief with minimal adverse effects following TKA remains controversial. Subsequently, the current study was undertaken to investigate the analgesic efficacy and the opioid sparing effects of intravenous parecoxib in combination with continuous femoral block as a possible approach for superior TKA pain management.

## **METHODS**

### **Ethics Statement**

Informed written consent was given by all the patients prior to enrollment in the study. The study was also reviewed and approved by the Institutional Review Board and the Local Ethics Committee on human research and human studies at Aretaieion University Hospital with reference code S-138/15-06-10. Each patient was assigned a code and all data were analyzed anonymously.

### **Patients**

A total of 90 patients were included in the study, all of whom underwent TKA under spinal anesthesia. Prior to this, all patients received continuous femoral nerve block under neurostimulation guidance. Patients were randomized in 2 groups: Group D consisted of 45 patients who received the drug parecoxib intravenously in addition to femoral nerve block, and Group P consisted of 45 patients who received a placebo drug (N/S 0.9%) intravenously instead of parecoxib.

The randomization process was performed on the morning of surgery, where patients were randomized to one of the 2 aforementioned groups using computer-generated tables and sealed drawing-coded opaque envelopes. All drug solutions were prepared under aseptic conditions. All persons involved in the clinical care (surgeons, anaesthesiologists, and nurses) and all the patients remained blinded to the substance and the

treatment group assignment.

Exclusion criteria for both groups included age younger than 40 years old or older than 80 years old; ASA > III, obesity (> 140 kg body weight); allergy to local anesthetics, history of dependence on opioids, contraindications for subarachnoid anesthesia or femoral block (coagulopathy, local infection, pre-existing neurological problems, patient refusal); contraindications to the administration of parecoxib, severe hepatic or renal disease (serum creatinine  $\geq$  1.7 mg/dl), insulin dependent diabetes mellitus, heart failure NY II-III classification, angina, ischemic heart disease, gastrointestinal disorders, ulcers, or side effect(s) to parecoxib.

### **Pain and Anxiety Visual Analog Scales**

Prior to continuous femoral nerve block, all patients were introduced to using a 10-cm visual analog scale (VAS) for procedural pain (0 = no pain at all to 10 = worst pain imaginable). VAS pain scores at rest were obtained at different time intervals including 4, 8, 12, 24, and 36 hours. The pain scores were measured with patients in a resting position. Pain was assessed both at rest and on a flexion of the knee by 60 degrees.

### **Continuous Femoral Nerve Block under Neurostimulation Guidance**

The local anesthetic agent lidocaine 1% (0.5 mg/kg) was used to achieve generous skin and subcutaneous tissue infiltration before the needle was inserted just inferior to the inguinal crease, aiming at approximately 45 degrees cephalad. Simultaneously, sedation with intravenous midazolam 0.05 mg/kg was administered. By palpating the femoral artery, 1.5 cm to the outside and down, the femoral nerve was detected with current intensity 0.5 – 1.5 mA and a frequency of 2 Hz. At the same time, the nerve stimulator was clipped to the proximal bare area of the needle and the needle was pushed further to penetrate the overlying tissues; the latter was done to ensure that the anesthetic agent would cross the tissues and reach the femoral nerve with the guidance of the nerve stimulator (muscle twitches). The neurostimulated catheter was advanced further in, while the intensity was decreased from 0.5 to 0.2 mA, ensuring that there was still motor response at that point and also minimizing the risk of nerve damage due to accidental intraneural infiltration. This is characteristic of the contraction of the quadriceps muscle and the movement of the patella “dancing patella” sign. The catheter was then introduced into the needle until the muscle twitches were resumed, at which point the

catheter was gradually advanced beyond the tip of the needle, for a distance of approximately 3 – 5 cm, and secured subcutaneously using a 16 G cannula. Twenty mL of ropivacaine 0.75% were injected as a bolus single shot. Later, in recovery following TKA, a 200 mL pump would be connected to facilitate an infusion of 0.2% ropivacaine at 10 mL/h. The pump was connected when the level of sensory blockade had descended from the T12 level. The level of bilateral sensory and motor block was also checked with a pin-prick test. Criteria for withdrawal included catheter tip misplacement or moving, nonfunctional catheter, unpredictable occurrence of allergy, and occurrence of any illness which could potentially endanger the patient’s life.

### **Hemodynamics**

Assessment of blood pressure, pulse rate, oxygen saturation, and numerical rating scale (NRS) were periodically taken every 15 minutes intraoperatively and at 15 minutes following the administration of parecoxib and at 4, 8, 12, 24, and 36 hour intervals following the surgical procedure. Morphine could also be administered with a patient controlled analgesia (PCA) pump if the specified analgesia was deemed inadequate (VAS > 50). Side effects were also evaluated at the specified time intervals by asking the patients if they had any unwanted symptoms.

### **Statistical Analysis**

Repeated ANOVA measures were performed for all time intervals at which VAS pain scores were obtained, i.e., at 4, 8, 12, 24, and 36 hours, using the Statistics program (IBM Corp. Released 2010. IBM SPSS Statistics for Windows, Version 19.0. Armonk, NY: IBM Corp.). Similarly, repeated ANOVA measures were carried out at the same time intervals to assess possible differences in the consumption of morphine between the 2 differently treated groups. Non-parametric Mann-Whitney test was performed to verify statistically significant differences between the 2 groups at time points 4, 12, and 24 hours post-operatively.

## **RESULTS**

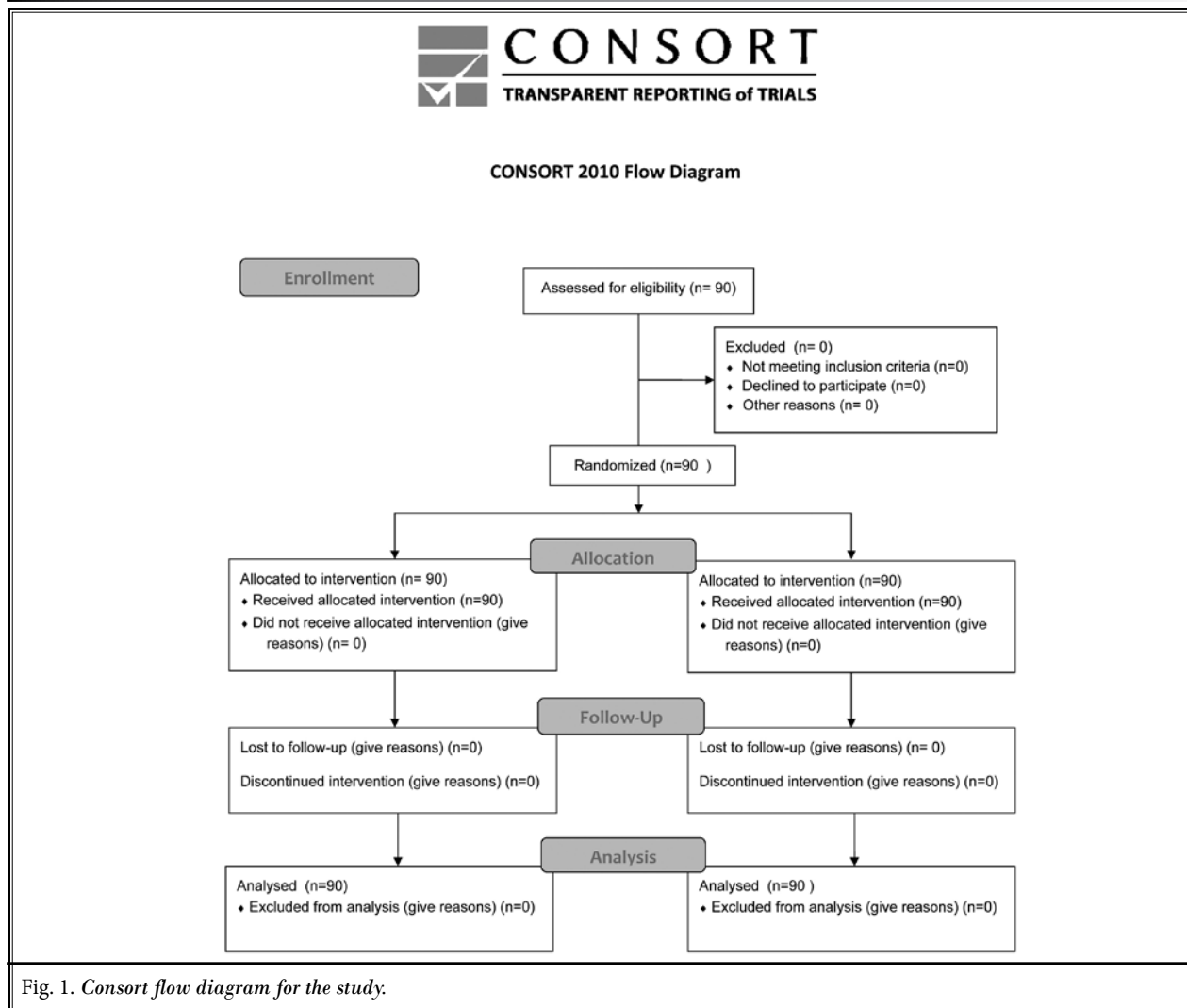
---

### **Patients**

A total of 90 patients were randomized to placebo (n = 45) and parecoxib (n = 45). None of the patients were withdrawn from the study. The physical characteristics of the study groups were comparable; most patients were female (83.3%) and all were Caucasians

Table 1. Patient characteristics and surgical data.

		Age (yr)	Weight (Kg)	Duration of anesthesia (min)
Parecoxib Group	Maximum	80	103	243
	N	45	45	45
	Mean	70.31	81.40	136.29
Placebo Group	Maximum	89	117	215
	N	45	45	45
	Mean	70.73	84.20	139.56
Statistic		t = 0.293	t = 1.14	z = 0.46
P-value		0.77	0.259	0.645



(100%). There were no significant statistical differences between treatment groups regarding either the hemodynamic variables perioperatively and postoperatively or the surgical procedure (surgery on right or left knee)

and the duration of anesthesia. Patient clinical and surgical data are summarized in Table 1. A consort flow diagram for the study can be seen in Fig. 1.

**Pain Intensity**

In general, parecoxib provided greater relief than placebo following TKA. The VAS pain scores measured at rest were statistically significantly lower in parecoxib-treated patients compared to the placebo group ( $P = 0.007$ ) at 4 ( $P = 0.044$ ), 12 ( $P = 0.001$ ), and 24 hours ( $P = 0.012$ ), postoperatively (Table 2, Fig. 2). At 8 and 36 hours, no statistical differences were observed;  $P = 0.202$  and  $P = 0.060$ , respectively. Of note, according to our data, at rest, the VAS scores were low at 4 hours, whereas they were at peak between 8 and 12 hours, postoperatively. Following 12 hours, the pain intensity gradually decreased.

**Morphine Consumption**

Analysis of the morphine consumption demonstrated that patients receiving parecoxib consumed less morphine at all time intervals than patients receiving placebo, with borderline statistical significance ( $P = 0.054$ ) (Fig. 3). Additionally, in each time period, all patients receiving continuous femoral block, irrespective of the treatment group, required low morphine doses. The incidence of morphine-

related complications was similar between the 2 groups. In total, related side effects were observed in 6/90 (6.67%) patients who received morphine. Patients experienced dizziness ( $n = 1$ ), drowsiness ( $n = 1$ ), and itchiness ( $n = 4$ ). No patient showed clinical evidence of local anesthetic toxicity or long-term complications associated with the nerve blocks.

**DISCUSSION**

Inadequate postoperative pain management following TKA is of principal concern (1,23) with immediate implications for patients' recovery (4-6) and rehabilitation (7-

Table 2. Statistical analysis of VAS pain scores at different time intervals.

	VAS 4	VAS 8	VAS 12	VAS 24	VAS 36
Mann-Whitney U	778,000	859,500	603,000	729,000	803,000
Wilcoxon W	1813,000	1894,500	1638,000	1764,000	1838,000
Z	-2.016	-1.275	-3.425	-2.507	-1.882
Asymp. Sig. (2-tailed)	0.044*	0.202	0.001*	0.012*	0.060

\*  $P < 0.05$

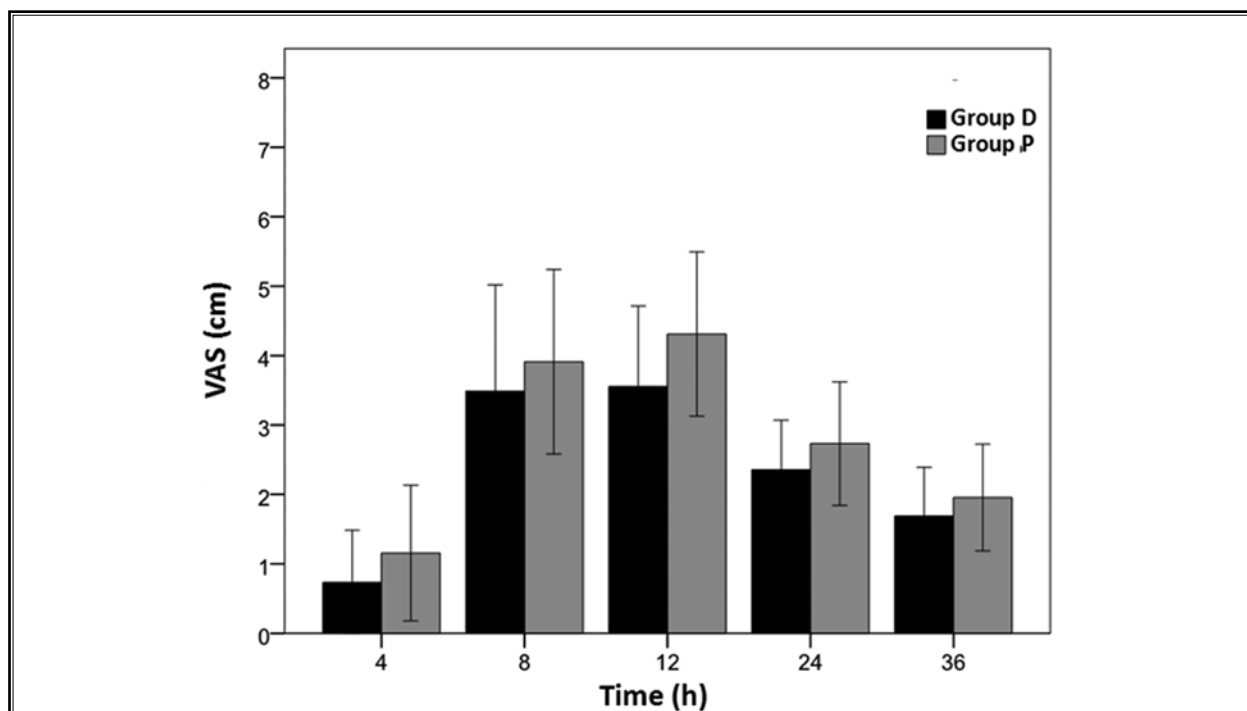
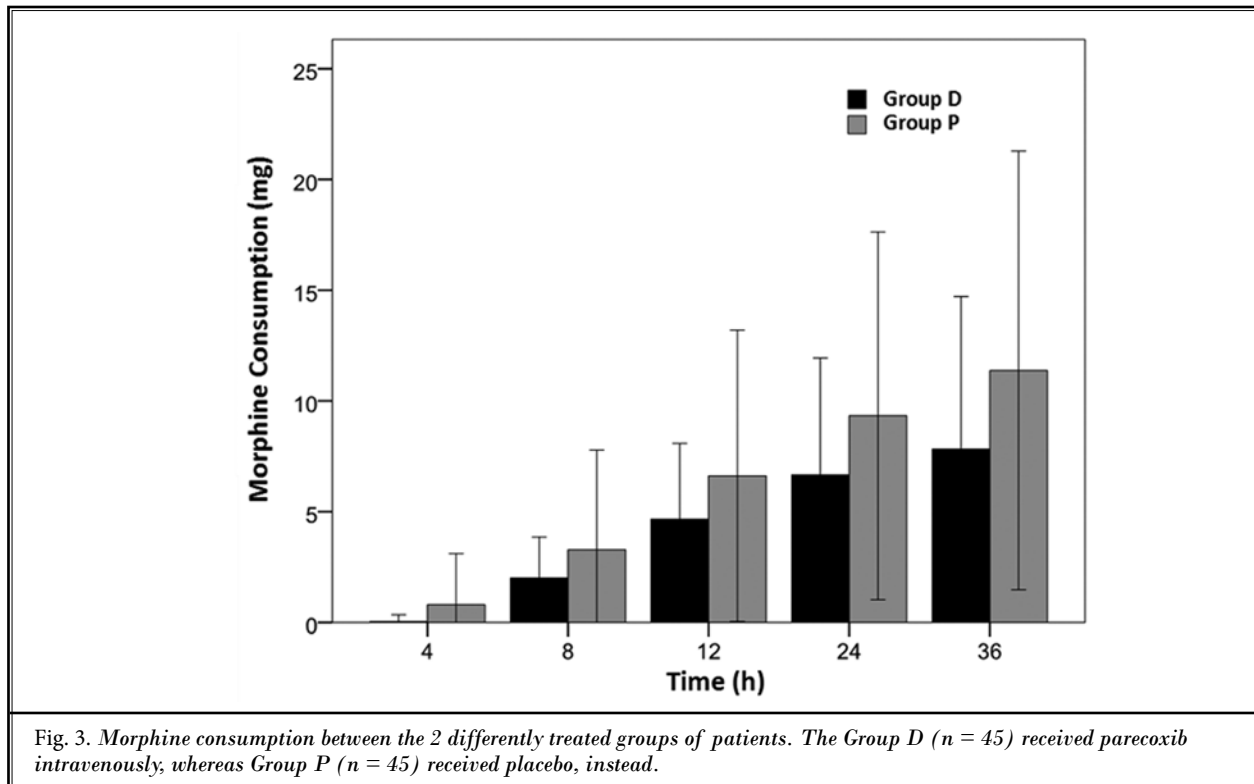


Fig. 2. Degree of pain measured at rest using a 10-cm VAS. The Group D ( $n = 45$ ) received parecoxib intravenously, whereas Group P ( $n = 45$ ) received placebo, instead.



9,27). Subsequently, interventions that can accelerate rehabilitation might have a tremendous impact on the quality of life. Thus far, among the numerous analgesic approaches, the optimal techniques remain controversial. It appears that the best way to assure a high success rate for postoperative analgesia is multimodal therapy (23,28-30).

Multimodal therapy seems to decrease narcotic usage, improve pain scores, increase patient satisfaction, and enhance early recovery (31). It basically refers to the administration, via the same route or by different routes, of combination and often multiple analgesics at various time points during the perioperative period to provide superior analgesia and limit side effects and adverse events (27,32-34). Multimodal analgesia modalities include the synchronous administration of NSAIDs; acetaminophen; opioids via oral, IV, or spinal routes; and local anesthetics at the wound site via peripheral nerve or epidural blocks, intraperitoneally, or at the wound site as indicated by the extension of the surgical procedure (23,29,35). Recent clinical evidence has highlighted the potential benefits of infiltrating high volumes of local anesthetics around the soft tissues of replaced hip and knee joints (36). The technique can be used alone or in combination with other regional

techniques and/or analgesic modalities as an important opioid-sparing component of multimodal strategy for treating postoperative pain (37). However, according to Banerjee and Rogers (38), although better pain relief in the immediate postoperative period with wound infiltration was succeeded following TKA, there was no definite evidence that this led to a reduction in opiate consumption or in hospital stay. This is also in line with Merritt et al (39) who recently suggested that wound infiltration affords a promising yet under-investigated method of postoperative pain control.

Regional anesthesia, and specifically the use of peripheral nerve blocks, represents valuable options for controlling perioperative pain of patients undergoing TKA (39,40). Early mobilization and rehabilitation, improved patient satisfaction, and reduced length of stay have been accomplished by using regional anesthesia and therefore peripheral nerve blocks are becoming ever more popular (40). According to Venditoli et al (41) continuous peripheral nerve blocks and low dose intrathecal opioids afford the cornerstone of multimodal analgesia; nonetheless, overuse of opioids can be associated with troublesome complications including depression, hemodynamic instability, nausea, vomiting, prolonged sedation, respiratory depression,



and ileus among others (25,42-44). In addition, opioids may not be ideal for patients requiring physical therapy because excessive sedation may impede therapy (27). Selective COX-2 inhibitors are of proven analgesic efficacy in postoperative pain control (24,26) and their opioid-sparing role might lead to significant lessening of opioid-related side effects (45).

Accordingly, well-coordinated perioperative pain management has been shown to increase patient satisfaction with surgical procedures, to improve postoperative quality of life, to decrease pain-related morbidity and hospital stays, as well as consequent medical costs related to surgery (46). Different modes of perioperative analgesia have been described. In the current study, implementation of the aforementioned multimodal perioperative protocol, analgesic combination therapy with continuous femoral block with ropivacaine 0.2% and parecoxib intravenously and morphine by PCA as rescue therapy, achieved improved pain control and accomplished therapy goals with less narcotic consumption and side effects following TKA and subsequently, led to better rehabilitation, increased range of motion and pain scores on mobilization (data not presented) and health-related quality of life, greater patient satisfaction (data not presented), as well as less postoperative pain. Of note, whether the current protocol led to functional recovery remains unanswered, since such measurements were not performed and subsequently this could be considered as a potential limitation of our study.

In the same context, the intensity of postoperative pain was assessed using the VAS pain scale. At rest, significantly higher VAS scores were recorded in patients belonging to the placebo group as compared to patients belonging to the parecoxib group at 4, 12, and 24 hour time intervals. The latter observation might be a result of a placebo group patients' attempt to avoid morphine-related side effects, and this is the reason why they did not increase their morphine dose by PCA.

The VAS pain scores obtained between 4 and 8 hours did not exhibit any significant disparities; however, this is somewhat anticipated, since it has been previously shown that patients who receive peripheral nerve blocks have significantly lower pain scores during the initial 8 hours following surgery (47). Placement of a femoral nerve catheter allows prolonged site-specific regional anesthesia (48) and favorable functional outcome (12). In the present study, the use of ropivacaine, which is considered an amide-type local anesthetic (22), might have provided our patients with improved pain

relief. The latter is in agreement with Leone et al (49), who confirmed that ropivacaine delivers long-lasting blocks.

Parecoxib affords the first COX-2 available for parenteral administration, which may be given either intravenously or intramuscularly providing potential advantages over oral medication both in perioperative and postoperative settings (50,51). It is thought to be the only parenterally administered selective COX-2 inhibitor which has the most supportive data for its beneficial effects (52). It has also been previously shown to be effective for the treatment of postoperative pain in various surgical operations (25,26), without increasing bleeding (53) or gastrointestinal toxicity (54,55). However, it has been reported to increase the risk of cardiotoxic sequelae and atherothrombotic complications (56,57). In the current report, no evidence of bleeding, gastrointestinal, cardiovascular, or thromboembolic events were noted in any of the treatment groups following administration of parecoxib, as previously reported (53-57). In addition, no influence on the intraostial remodelling and bleeding affecting surgical outcomes post TKA were observed judging from the hemoglobin concentrations, postoperative transfusion requirements, radiology follow-up, and rehabilitation progression. These observations validate the safe usage of parecoxib.

Previous reports also demonstrated that parecoxib administration following TKA resulted in a reduction in narcotic administration (8,58). We also attempted to ascertain whether parecoxib could reduce opioid consumption and related side effects. For this reason, we endeavored to investigate the potential differences in morphine consumption between the parecoxib-treated and the placebo-treated groups. According to our findings all patients received low morphine doses, irrespective of which treatment group they belonged to. Subsequently, it seems likely that continuous femoral block with 0.2% ropivacaine infusions provided patients with a clinically relevant advantage, reducing postoperative morphine consumption with limited relevant side effects. This is in line with previous studies that have associated continuous femoral nerve blockade, not only with improved postoperative pain relief (59), but also with significantly reduced postoperative consumption of morphine (59-61) and subsequently with less morphine-related complications following TKA (60) and better recovery (61). In addition, the fact that patients receiving parecoxib consumed less morphine than patients receiving placebo corroborated our observations

that intravenous parecoxib offered improved postoperative analgesia.

## CONCLUSION

In summary, the current study seems to provide significant insights into the potential use of intravenous parecoxib in combination with continuous femoral block with 0.2% ropivacaine for pain management and to offer additional data for developing optimal analgesic strategies following TKA. Generally, there was good evidence that intravenous parecoxib in combination with continuous femoral block provided superior analgesic efficacy and opioid sparing effects in patients

undergoing TKA.

## Authors' Contributions:

DGS participated in the design of the study, performed all experiments, collected and evaluated patients' clinical data, and drafted the manuscript. GC and AK assisted in the performance of experiments. MB performed data analyses and interpretation, and assisted in drafting the manuscript. AM participated in the design and coordination of the study and revised the manuscript draft. AV conceived, designed, and coordinated the study and revised the manuscript draft.

## REFERENCES

- Casati A, Vinciguerra F, Cappelleri G, Vinciguerra F, Cappelleri G, Aldegheri G, Fanelli G, Putzu M, Chelly JE. Adding clonidine to the induction bolus and postoperative infusion during continuous femoral nerve block delays recovery of motor function after total knee arthroplasty. *Anesth Analg* 2005; 100:866-872, table of contents.
- Paul JE, Arya A, Hurlburt L, Cheng J, Thabane L, Tidy A, Murthy Y. Femoral nerve block improves analgesia outcomes after total knee arthroplasty: A meta-analysis of randomized controlled trials. *Anesthesiology* 2010; 113:1144-1162.
- Ganapathy S, Wasserman RA, Watson JT, Bennett J, Armstrong KP, Stockall CA, Chess DG, MacDonald C. Modified continuous femoral three-in-one block for postoperative pain after total knee arthroplasty. *Anesth Analg* 1999; 89:1197-1202.
- Wylde V, Rooker J, Halliday L, Blom A. Acute postoperative pain at rest after hip and knee arthroplasty: Severity, sensory qualities and impact on sleep. *Orthop Traumatol Surg Res* 2011; 97:139-144.
- Essving P, Axelsson K, Åberg E, Spännar H, Gupta A, Lundin A. Local infiltration analgesia versus intrathecal morphine for postoperative pain management after total knee arthroplasty: A randomized controlled trial. *Anesth Analg* 2011; 113:926-933.
- Pagnano MW, Hebl J, Horlocker T. Assuring a painless total hip arthroplasty: A multimodal approach emphasizing peripheral nerve blocks. *J Arthroplasty* 2006; 21:80-84.
- Znojek-Tymborowska J, Keska R, Paradowski PT, Wito ski D. Relevance of infiltration analgesia in pain relief after total knee arthroplasty. *Acta Orthop Bras* 2013; 21:262-265.
- Zhu Y, Wang S, Wu H, Wu Y. Effect of perioperative parecoxib on postoperative pain and local inflammation factors PGE2 and IL-6 for total knee arthroplasty: A randomized, double-blind, placebo-controlled study. *Eur J Orthop Surg Ttraumatol* 2014; 24:395-401.
- Cibils LA, Ringler GE. Evaluation of mid-forceps delivery as an alternative. *J Perinat Med* 1990; 18:5-11.
- Fowler SJ, Symons J, Sabato S, Myles PS. Epidural analgesia compared with peripheral nerve blockade after major knee surgery: A systematic review and meta-analysis of randomized trials. *Br J Anaesth* 2008; 100:154-164.
- Capdevila X, Biboulet P, Morau D, Bernard N, Deschodt J, Lopez S, d'Athis F. Continuous three-in-one block for postoperative pain after lower limb orthopedic surgery: Where do the catheters go? *Anesth Analg* 2002; 94:1001-1006, table of contents.
- Morin AM, Kratz CD, Eberhart LH, Dinges G, Heider E, Schwarz N, Eisenhardt G, Geldner G, Wulf H. Postoperative analgesia and functional recovery after total-knee replacement: Comparison of a continuous posterior lumbar plexus (psoas compartment) block, a continuous femoral nerve block, and the combination of a continuous femoral and sciatic nerve block. *Reg Anesth Pain Med* 2005; 30:434-445.
- Casati A, Fanelli G, Beccaria P, Magistris L, Albertin A, Torri G. The effects of single or multiple injections on the volume of 0.5% ropivacaine required for femoral nerve blockade. *Anesth Analg* 2001; 93:183-186.
- Aguirre J, Del Moral A, Cobo I, Borgeat A, Blumenthal S. The role of continuous peripheral nerve blocks. *Anesthesiol Res Pract* 2012; 2012:560879.
- Chan EY, Fransen M, Parker DA, Assam PN, Chua N. Femoral nerve blocks for acute postoperative pain after knee replacement surgery. *Cochrane Database Syst Rev*. 2014; 5:CD009941.
- Sahin L, Korkmaz HF, Sahin M, Atalan G. Ultrasound-guided single-injection femoral nerve block provides effective analgesia after total knee arthroplasty up to 48 hours. *Agri*. 2014; 26:113-118.
- Wang, F, Liu L-W, Hu Z, Peng Y, Zhang X-Q, Li Q. Ultrasound and nerve stimulator guided continuous femoral nerve block analgesia after total knee arthroplasty: A multicenter randomized controlled study. *Rev Bras Anesthesiol* 2014; 65:14-20.
- Oberndorfer U, Marhofer P, Bosenberg A, Willschke H, Felfernig M, Weintraud M, Kapral S, Kettner SC. Ultrasonographic guidance for sciatic and femoral nerve blocks in children. *Br J Anaesth* 2007; 98:797-801.
- Bernards CM, Hadzic A, Suresh S, Neal JM. Regional anesthesia in anesthetized or heavily sedated patients. *Reg Anesth*



- Pain Med* 2008; 33:449-460.
20. Fredrickson MJ, Kilfoyle DH. Neurological complication analysis of 1000 ultrasound guided peripheral nerve blocks for elective orthopaedic surgery: A prospective study. *Anaesthesia* 2009; 64:836-844.
  21. Gandhi K, Lindenmuth DM, Hadzic A, Xu D, Patel VS, Maliakal TJ, Gadsden JC. The effect of stimulating versus conventional perineural catheters on postoperative analgesia following ultrasound-guided femoral nerve localization. *J Clin Anesth* 2011; 23:626-631.
  22. Fedder C, Beck-Schimmer B, Aguirre J, Hasler M, Roth-Z'graggen B, Urner M, Kalberer S, Schlicker A, Votta-Velis G, Bonvini JM, Graetz K, Borgeat A. In vitro exposure of human fibroblasts to local anaesthetics impairs cell growth. *Clin Exp Immunol* 2010; 162:280-288.
  23. Grant CRK, Checketts MR. Analgesia for primary hip and knee arthroplasty: The role of regional anaesthesia. *Contin Educ Anaesth Crit Care Pain* 2008; 8:56-61.
  24. Simon LS. Role and regulation of cyclooxygenase-2 during inflammation. *Am J Med* 1999; 106:37S-42S.
  25. Vadalouca A, Moka E, Chatzidimitriou A, Siafaka I, Sikioti P, Argyra E. A randomized, double-blind, placebo-controlled study of preemptively administered intravenous parecoxib: Effect on anxiety levels and procedural pain during epidural catheter placement for surgical operations or for chronic pain therapy. *Pain Pract* 2009; 9:181-194.
  26. Baharuddin KA, Rahman NH, Wahab SF, Halim NA, Ahmad R. Intravenous parecoxib sodium as an analgesic alternative to morphine in acute trauma pain in the emergency department. *Int J Emerg Med* 2014; 7:2.
  27. Baratta JL, Gandhi K, Viscusi ER. Perioperative pain management for total knee arthroplasty. *J Surg Orthop Adv* 2014; 23:22-36.
  28. Lewis C, Gunta K, Mitchell K, Bobay K. Effectiveness of multimodal pain management protocol in total knee arthroplasty patients. *Orthop Nurs* 2012; 31:153-159.
  29. de Leon-Casasola O. A review of the literature on multiple factors involved in postoperative pain course and duration. *Postgrad Med* 2014; 126:42-52.
  30. McCartney CJ, Nelligan K. Postoperative pain management after total knee arthroplasty in elderly patients: Treatment options. *Drugs Aging* 2014; 31:83-91.
  31. Lamplot JD, Wagner ER, Manning DW. Multimodal pain management in total knee arthroplasty: A prospective randomized controlled trial. *J Arthroplasty* 2014; 29:329-334.
  32. Gandhi K, Viscusi ER. Multimodal pain management techniques in hip and knee arthroplasty. *J NY School Reg Anesth* 2009; 13:1-10.
  33. Mariano ER, Perlas A. Adductor canal block for total knee arthroplasty: The perfect recipe or just one ingredient? *Anesthesiology* 2014; 120:530-532.
  34. Rosero EB, Joshi GP. Preemptive, preventive, multimodal analgesia: What do they really mean? *Plast Reconstr Surg* 2014; 134:85S-93S.
  35. American Society of Anesthesiologists Task Force on Acute Pain Management. Practice guidelines for acute pain management in the perioperative setting: an updated report by the American Society of Anesthesiologists Task Force on Acute Pain Management. *Anesthesiology* 2012; 116:248-173.
  36. Mahadevan D, Walter RP, Minto G, Gale TC, McAllen CJ, Oldman M. Combined femoral and sciatic nerve block vs combined femoral and periarticular infiltration in total knee arthroplasty: A randomized controlled trial. *J Arthroplasty* 2012; 27:1806-1811.
  37. Rawal N. Local infiltration analgesia and other multicomponent techniques to improve postoperative — outcome — are we comparing oranges and apples? *Reg Anesth Pain Med* 2011; 36:417-420.
  38. Banerjee P, Rogers BA. Systematic review of high-volume multimodal wound infiltration in total knee arthroplasty. *Orthopedics* 2014; 37:403-412.
  39. Merritt CK, Mariano ER, Kaye AD, Lissauer J, Mancuso K, Prabhakar A, Urman RD. Peripheral nerve catheters and local anesthetic infiltration in perioperative analgesia. *Best Pract Res Clin Anaesthesiol* 2014; 28:41-57.
  40. Danninger T, Opperer M, Memtsoudis SG. Perioperative pain control after total knee arthroplasty: An evidence based review of the role of peripheral nerve blocks. *World J Orthop* 2014; 5:225-232.
  41. Vendittoli PA, Makinen P, Drolet P, Lavigne M, Fallaha M, Guertin MC, Varin F. A multimodal analgesia protocol for total knee arthroplasty. A randomized, controlled study. *J Bone Joint Surg Am* 2006; 88:282-289.
  42. Gan TJ, Joshi GP, Zhao SZ, Hanna DB, Cheung RY, Chen C. Presurgical intravenous parecoxib sodium and follow-up oral valdecoxib for pain management after laparoscopic cholecystectomy surgery reduces opioid requirements and opioid-related adverse effects. *Acta Anaesthesiol Scand* 2004; 48:1194-1207.
  43. Busch CA, Shore BJ, Bhandari R, Ganapathy S, MacDonald SJ, Bourne RB, Rorabeck CH, McCalden RW. Efficacy of periarticular multimodal drug injection in total knee arthroplasty. A randomized trial. *J Bone Joint Surg Am* 2006; 88:959-963.
  44. Anastase DM, Cionac Florescu S, Munteanu A, Ursu T, Stoica C. Analgesic techniques in hip and knee arthroplasty: From the daily practice to evidence-based medicine. *Anesthesiol Res Pract* 2014; 2014:1-8.
  45. Langford RM, Mehta V. Selective cyclooxygenase inhibition: Its role in pain and anaesthesia. *Biomed Pharmacother* 2006; 60:323-328.
  46. Lee BH, Park JO, Suk KS, Kim TH, Lee HM, Park MS, Lee SH, Park S, Lee JY, Ko SK, Moon SH. Pre-emptive and multimodal perioperative pain management may improve quality of life in patients undergoing spinal surgery. *Pain Physician* 2013; 16:E217-E226.
  47. Feibel RJ, Dervin GF, Kim PR, Beaulé PE. Major complications associated with femoral nerve catheters for knee arthroplasty: A word of caution. *J Arthroplast* 2009; 24:132-137.
  48. Salinas FV, Liu SS, Mulroy MF. The effect of single-injection femoral nerve block versus continuous femoral nerve block after total knee arthroplasty on hospital length of stay and long-term functional recovery within an established clinical pathway. *Anesth Analg* 2006; 102:1234-1239.
  49. Leone S, Di Cianni S, Casati A, Fanelli G. Pharmacology, toxicology, and clinical use of new long acting local anesthetics, ropivacaine and levobupivacaine. *Acta Biomed* 2008; 79:92-105.
  50. Lloyd R, Derry S, Moore RA, McQuay HJ. Intravenous or intramuscular parecoxib for acute postoperative pain in adults. *Cochrane Database Syst Rev* 2009; 2:CD004771.
  51. Atkinson TJ, Fudin J, Jahn HL, Kubotera N, Rennick AL, Rhorer M. What's new in NSAID pharmacotherapy: Oral agents to injectables. *Pain Med* 2013; 14:S11-S17.
  52. Abdulla S, Eckhardt R, Netter U, Abdulla W. Randomized, double-blind, placebo-controlled study to assess the efficacy of nonopioid analgesics on pain follow-

- ing arthroscopic knee surgery. *Pain Res Treat* 2012; 2012:305821.
53. Martinez V, Belbachir A, Jaber A, Cherif K, Jamal A, Ozier Y, Sessler DI, Chauvin M, Fletcher D. The influence of timing of administration on the analgesic efficacy of parecoxib in orthopedic surgery. *Anesth Analg* 2007; 104:1521-1527, table of contents.
  54. Lazzaroni M, Bianchi Porro G. Gastrointestinal side-effects of traditional non-steroidal anti-inflammatory drugs and new formulations. *Aliment Pharmacol Ther* 2004; 20:48-58.
  55. Moodley I. Review of the cardiovascular safety of COXIBs compared to NSAIDS. *Cardiovasc J Afr* 2008; 19:102-107.
  56. Cox B, Durieux ME, Marcus MA. Toxicity of local anaesthetics. *Best Pract Res Clin Anaesthesiol* 2003; 17:111-136.
  57. Krotz F, Schiele TM, Klaus V, Sohn HY. Selective COX-2 inhibitors and risk of myocardial infarction. *J Vasc Res* 2005; 42:312-324.
  58. Tanavalee A, Thiengwittayaporn S. Multimodal pain management following minimally invasive total knee arthroplasty: An experience in 3-dose parecoxib. *J Med Assoc Thai* 2009; 92:S11-S18.
  59. Hunt KJ, Bourne MH, Mariani EM. Single-injection femoral and sciatic nerve blocks for pain control after total knee arthroplasty. *J Arthroplast* 2009; 24:533-538.
  60. Kadic L, Boonstra MC, DE Waal Malefijt MC, Lako SJ, VAN Egmond J, Driessen JJ. Continuous femoral nerve block after total knee arthroplasty? *Acta Anaesthesiol Scand* 2009; 53:914-920.
  61. Carli F, Clemente A, Asenjo JF, Kim DJ, Mistraretti G, Gomarasca M, Morabito A, Tanzer M. Analgesia and functional outcome after total knee arthroplasty: Periarticular infiltration vs continuous femoral nerve block. *Br J Anaesth* 2010; 105:185-195.