

## Case Study

## Intrathecal Baclofen in Spinal Spasticity: Frequency and Severity of Withdrawal Syndrome

Ivana Stetkarova, MD, PhD<sup>1</sup>, Karel Brabec, MD<sup>1</sup>, Peter Vasko, MD<sup>1</sup>, and Libor Mencil, MD<sup>2</sup>

From: <sup>1</sup>Department of Neurology, Third School of Medicine, Hospital Kralovske Vinohrady, Charles University, Prague, Czech Republic; <sup>2</sup>Department of Neurosurgery, Third School of Medicine, Hospital Kralovske Vinohrady, Charles University, Prague, Czech Republic.

Address Correspondence:  
Ivana Stetkarova, MD, PhD  
Department of Neurology  
Third Faculty of Medicine, Hospital  
Kralovske Vinohrady,  
Charles University, Prague  
Ruska 87, Prague 10, Czech Republic,  
100 00  
E-mail: ivana.stetkarova@fnkv.cz

Disclaimer: Supported by Research Project of Charles University PRVOUK P34, Czech Republic, Grant Project of Czech Ministry of Health NT12282. Conflict of interest: Dr. Stetkarova is a consultant for Medronic. Each author certifies that he or she, or a member of his or her immediate family, has no commercial association (i.e., consultancies, stock ownership, equity interest, patent/licensing arrangements, etc.) that might pose a conflict of interest in connection with the submitted manuscript.

Manuscript received: 11-05-2014  
Revised manuscript received:  
01-21-2015  
Accepted for publication:  
03-16-2015

Free full manuscript:  
[www.painphysicianjournal.com](http://www.painphysicianjournal.com)

**Background:** Intrathecal baclofen (ITB) delivered by programmable pump devices represents an important modality for long-term treatment of severe spinal spasticity.

**Objective:** One of the serious adverse events is a withdrawal syndrome after sudden interruption of ITB delivery. In this study, we analyzed the frequency and severity of this complication. Treatment recommendations follow.

**Study Design:** Case study

**Setting:** Academic medical center.

**Methods:** A total of 54 ITB pumps were successfully implanted in 39 patients with severe intractable spasticity (24 with spinal cord injury, 15 with multiple sclerosis, 24 men, age range 21 – 59 years).

**Results:** Eight patients developed a withdrawal syndrome on total a daily dose of ITB between 90 – 420 µg/day. Seven patients had catheter-related complications. In one patient, pump failure was observed due to its corrosion. Within the group, baclofen withdrawal syndrome occurred once in 20.1 pump-years counted out of 160.4 pump-years of ITB treatment.

**Limitations:** Small sample size.

**Conclusions:** ITB withdrawal syndrome is a rare but life-threatening event and prompt diagnosis before treatment initiation is critical. The reported events were mostly mild due to the acute treatment regime and probably due to a lower dose of ITB. A prerequisite for successful ITB treatment is a deep knowledge of complications and their prompt management in the hands of a multidisciplinary team in specialized centers.

**Key words:** Spasticity, intrathecal baclofen, pump systems, complications, withdrawal syndrome

**Pain Physician 2015; 18:E633-E641**

In severe spasticity with resistance to oral drugs and/or their severe side effects, intrathecal baclofen (ITB) has been used for clinical management of muscle hypertonia of spinal and supraspinal origin (1-4). Despite generally favorable outcomes and the relative safety of this method (5-7), complications associated with ITB may occur during the testing period, pump

implantation, and follow-up with the pump refill (8-9). Possible ITB complications can be divided into drug side effects (drug-related complications, e.g., overdose, excessive weakness, drowsiness, withdrawal) and complications resulting from implantation and failure of the system (procedure- and device-related complications) (10-11).

Any complication resulting in sudden interruption of ITB delivery may result in a severe baclofen withdrawal syndrome (12-14). This serious adverse event can be life threatening and its recognition is an important part of the ITB delivery management (15). Baclofen withdrawal syndrome is usually characterized by a sudden increase of spasticity, pruritus, hyperthermia, autonomic dysregulation, epileptic seizures, coma, rhabdomyolysis, disseminated intravascular coagulation, and multisystem organ failure (Table 1). Appropriate diagnosis before treatment initiation is critical as therapies utilized to manage complications associated with acute baclofen withdrawal may require institution of mechanical ventilation and additional neurocritical care expertise.

The aim of this study is to provide an overview of ITB withdrawal syndrome analyzing the frequency and severity of this complication and its course with the diagnostic process and treatment.

## METHODS

From 2003 until now, in the Department of Neurology, Third School of Medicine at Charles University, we have been testing a group of 54 patients (32 men, age range 18 – 56 years) with severe generalized spasticity of different etiology who did not respond sufficiently to physiotherapy and oral medication. Twenty-three patients suffered from multiple sclerosis (MS) and 31 patients had chronic spinal cord injury (SCI). All patients were familiar with the risks of intrathecal baclofen delivery during the testing period, pump implantation, and follow-up with pump refill. All of them signed an informed consent. This study was approved by the IRB at our institution.

Spasticity was evaluated clinically by commonly used clinical scales such as the Modified Ashworth scale. A single bolus of 50 – 75 – 100 µg of baclofen (Lioresal Intrathecal, Novartis, sterile dilution of 100 µg in 1 mL)

according to the clinical efficacy was applied through lumbar puncture at the L3-5 vertebral level mostly in SCI and MS patients who were wheelchair-bound. A single bolus always had an interval of 24 hours from the next administration. In MS patients with Expanded Disability Status Scale (EDSS) less than 7 and in ambulatory SCI patients, continuous intrathecal delivery through a spinal catheter was used, starting with an initial baclofen dose of 2 – 3 µg/hour. This method allowed for better assessment of the patient response to a short-term continuous delivery of baclofen. At the time of testing no one had acute infections or other serious internal disease, and no pressure ulcers. Patients with at least 2 points decrease on the Modified Ashworth scale after the test dose were accepted for treatment with the ITB pump delivery system.

An intrathecal catheter and pump were implanted by a neurosurgeon. The catheter was positioned between T8 and T10 as recommended in spinal spasticity (16). Implantation technique was guided by skillful neurosurgeon in an operating room. Under general anesthesia, baclofen pump system was implanted below the skin on one side of the lower abdomen. The pump was connected to the catheter which was tunneled beneath the skin into the intrathecal space. Top of the spinal catheter was usually positioned around the T8-10 vertebra level. The final position was confirmed by x-ray skiascopy in the operating room. Patients spent a few days in the hospital in order to establish the clinically effective dose of baclofen. Baclofen was gradually increased by about 10 to 20% for 24 hours to achieve an optimum dose (16). Most patients had stitches removed after 7 – 10 days. Patients were subsequently regularly followed up for clinical evaluation and refilling of the pump according to baclofen dosage. All patients receiving ITB therapy and their caregivers were advised of the importance of keeping scheduled refilling visits and were educated on the early symptoms of baclofen withdrawal.

Patients with suspicion of acute baclofen withdrawal (sudden increase of spasticity, pruritus, agitation, fever) were immediately investigated at the emergency room or hospitalized in the intensive care unit after the first onset of symptoms. Appropriate diagnosis of sudden interruption of ITB delivery due to catheter or pump complications was proved by intrathecal baclofen bolus dose, x-ray, computed tomography (CT), rotor test, and/or neurophysiologic assessment (H-reflex study) (Table 2). The H-reflex was obtained after the stimulation of the tibial nerve at the fossa poplitea with surface electrodes attached over the soleus muscle.

Table 1. *The main symptoms of acute baclofen withdrawal syndrome.*

Return of spasticity
Agitation, disorientation, hallucinations, confusion, memory impairment
Pruritus without any rash, paresthesia, autonomic dysfunction
Dizziness, nausea, tremor, anxiety, psychosis, mania
Seizure, delirium, insomnia, fluctuation of consciousness
Hypotension, tachycardia, hyperpyrexia
Rarely rhabdomyolysis with multiple organ failure and death

Table 2. Recommendations for diagnostics of acute baclofen withdrawal syndrome.

History and careful clinical examination (spasticity due to MAS)
Vital signs (temperature, heart rate, blood pressure, respiratory rate)
Empty the reservoir and check the aspirated volume with pump pre-programming
Program a single bolus of 50 ug of baclofen
H-reflex (before and one hour after single baclofen bolus)
Plain radiography of the whole pump system (including rotor test for pump function)
Empty the catheter via the side access port and add contrast liquid under fluoroscopy
CT scan and CT with contrast liquid for better visualization
Radionuclide scintigraphy with serial sequential scanning after 24 h, 48 h, 72 h
Magnetic resonance imaging up to 3 Tesla

Table 3. Complications in group of 54 ITB pumps.

Catheter problems	14
Pump explantation	2
CSF leakage	2
Seroma	1
Infection	4
Skin dehiscence above the pump	1
<b>Total</b>	<b>24</b>

## RESULTS

A total of 54 ITB pump systems have been implanted in 39 patients (24 men, age range 21 – 56 years, 5x Synchronmed EL and 49x Synchronmed II, Medtronic Inc; Minnesota, MN, USA), representing 160.4 pump-years. Mean follow-up time was 39 months (range 6 – 121 months). The total number of complications was 24 out of 54 ITB pumps (44%), mostly connected with catheter complications (26%) (Table 3).

Eight patients developed baclofen withdrawal syndrome on a total daily dose of ITB in the range of 90 – 420 µg/day (average of 189 µg/day) (Table 4) In this group of patients, baclofen withdrawal syndrome occurred once in a total of 20.1 years of ITB treatment.

The degree of spasticity in the lower limbs increased up to 3 or 4 according to Modified Ashworth Scale (MAS) in all patients but one, when suspicion of baclofen withdrawal was aroused. Only one patient (patient 4) developed muscle hypertonia of MAS 2. The symptoms started between 18 – 48 hours after sudden interruption of baclofen delivery. The time delay between the onset of withdrawal symptoms and being seen by a physician at the emergency room was in a wide range: immediately after the onset (patients 5, 7), 6 – 8 hours (patients 1 – 3, 6), and 5 – 7 days (patients 4, 8). The diagnosis of ITB withdrawal was confirmed as soon as possible, usually on the day of admission or in the next 2 days.

Patients developed mostly mild symptoms of ITB withdrawal syndrome which started up to 18 – 48 hours after sudden baclofen interruption and lasted for 36 – 48 hours. All patients suffered from a severe increase of spasticity or muscle spasms. Three of them were agitated and had pruritus without any rash. All patients were continuously monitored for vital functions at an intensive care unit and immediately received oral ba-

clofen with 10 to 25 mg of oral baclofen 4 times daily, up to the maximum baclofen dose of 150 mg/day, and/or parenteral diazepam with 5 mg 4 times daily or continuously as 1 – 2 mg/hour. Patient 7 received a single bolus of baclofen of 100 ug at the beginning of withdrawal symptoms by pump programming. All patients were treated without any mechanical ventilation support. All of them completely recovered up to 3 days after the onset of baclofen withdrawal syndrome.

The diagnosis of baclofen withdrawal syndrome was proved immediately after plain radiography (Fig. 1) in patients 1, 4, 6, and 8 and clinically after a human error in patient 7. In the others, the diagnosis was proved within the next 2 days. In patient 3 the pump failure was proved after rotor test using x-ray. In patient 2 we put contrast liquid into the access side port of the ITB pump and visualized an abnormal leak in the spinal segment by fluoroscopy and CT scanning (Fig. 2). Six patients had catheter-related complications (disconnection, malposition, and breaking), 4 of them proved by plain radiography and in one case by CT scan (see Table 4). When baclofen has been delivered intrathecally, H-reflex has disappeared (17). In 5 patients, H-reflex was again recordable from the soleus muscle as a marker of ITB absence into the cerebrospinal fluid.

In 2 patients baclofen withdrawal syndrome was identified only clinically. In patient 7 the content of the catheter was accidentally not emptied during the pump reimplantation due to end of the battery life where it is recommended to aspirate at least 2 mL of cerebrospinal fluid. In the other one (patient 5), the symptoms of withdrawal syndrome developed after the pump reimplantation. During the surgical revision a kink in the catheter of the pump segment was identified because of too tight stitching around the catheter. All patients but one received surgical treatment when the

Table 4. Characteristics of baclofen withdrawal syndrome (ITB-WSy) in group of our patients treated by ITB pump system.

No.	Age	Gender	Diagnosis	Type of pump	ITB-WSy dose (µg/day)	Time after pump implantation	Signs of ITB-WSy	Diagnosis of ITB-WSy	Cause of ITB-WSy	Surgery after ITB-WSy
1	45	M	CDMS	EL	110	26 months	spasticity, pruritus, agitation	x-ray, H-reflex	catheter cut	spinal catheter replacement
2	53	F	CDMS	EL	90	42 months	spasticity, agitation, fever	side port, CT, H-reflex	catheter leak	spinal catheter replacement
3	42	F	CDMS	S II	150	65 months	spasticity, pruritus, agitation, fever	rotor test, H-reflex	pump corrosion	pump reimplantation
4	37	F	NMO	S II	150	21 months	spasticity, pruritus	x-ray	malposition of spinal catheter under the skin	spinal catheter replacement
5	32	M	SCI, C3-C4	S II	420	during reimplantation	spasticity, agitation	clinically, H-reflex	after reimplantation, a kink at catheter pump segment	pump catheter deliberation
6	33	M	SCI, T4	S II	125	1 month	spasticity	x-ray	malposition of spinal catheter under the skin	spinal catheter replacement
7	35	M	SCI, C4-C5	S II	260	during reimplantation	spasticity, agitation	clinically, H-reflex	during the pump reimplantation no aspiration of catheter content	no surgery
8	21	M	SCI T9	S II	210	2 months	spasticity, sweating	x-ray	malposition of spinal catheter under the skin	spinal catheter replacement

Note: CDMS, clinically definite multiple sclerosis; SCI, spinal cord injury; NMO, neuromyelitis optica

withdrawal syndrome was resolved. Spasticity was again managed by oral medications and rehabilitation as in the time before the first pump implant. Usually, catheter replacement was scheduled up to 2 – 3 weeks after baclofen withdrawal syndrome. In patient 5, revision was carried out on the fifth day after pump implantation. Patient 3 underwent an acute pump reimplantation 48 hours after baclofen withdrawal syndrome and, subsequently, the broken pump was sent to Medtronic for their expertise and they identified the pump corrosion (Fig. 3).

### DISCUSSION

One of the serious adverse events of continuous 24-hour intrathecal baclofen administration is the withdrawal syndrome after sudden interruption of ITB delivery. This event is a life-threatening complication in patients who are long-term dependent on ITB for spasticity control. In this study, the reported events were less frequent and mostly mild due to the acute treatment regime and relatively low daily dose of ITB.

ITB therapy has been shown to be efficacious by numerous studies; however, a variety of complications and side effects connected with ITB treatment may occur (10,11,18,19). Approximately 20 – 40% of patients with implanted pumps experience different types of complications (5,17). The most frequent complications are catheter malfunctions, infections and CSF leaks (5, 11,17-18). In MS and SCI, an ITB complication rate of 1% per month has been reported mainly due to catheter-related problems (9).

Patients treated by ITB pump delivery had higher cerebrospinal fluid concentrations following intrathecal administration and abrupt cessation of ITB administration (e.g., pump malfunction, infected hardware, etc.)

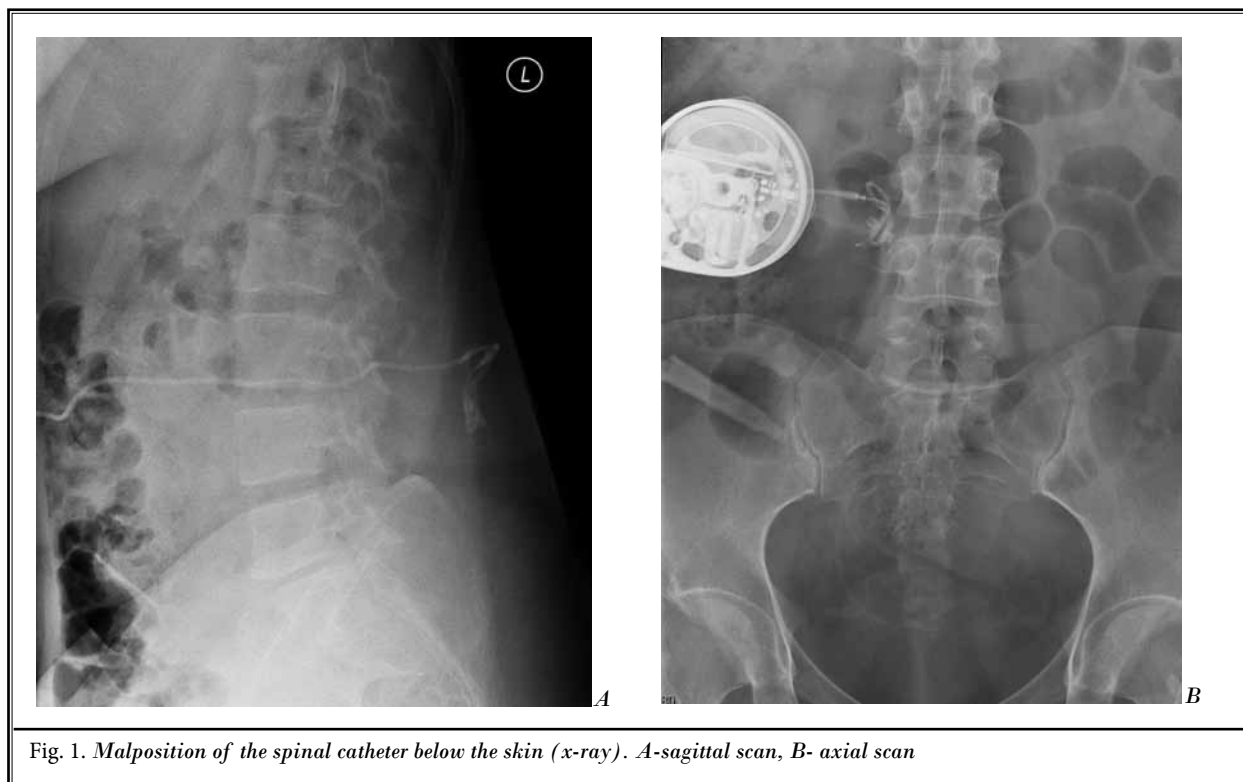


Fig. 1. Malposition of the spinal catheter below the skin (x-ray). A-sagittal scan, B- axial scan

can result in a rapid onset of acute baclofen withdrawal syndrome (20-23). More of them often occur after human error (defective filling of the pump, bad program settings, inappropriate change in baclofen concentration), catheter problem (occlusion, disconnection, kink, break, or catheter dislocation out of the intrathecal space), or pump failure (insufficient or no dosage) (16,18). Occasionally, as a human error, it can occur during pump refilling when baclofen is accidentally filled into the pump pocket and not in the pump reservoir and normal programming is set but the reservoir runs empty.

Baclofen withdrawal syndrome may begin immediately within the first 2 days, initially presenting with severe rebound of spasticity and pruritic symptoms as we observed in all of our patients. The main symptoms of baclofen withdrawal syndrome are sudden increase in spasticity, itching without any rash (pruritus), hyperthermia, headache, agitation, disorientation, hallucinations, autonomic dysregulation, epileptic seizures, coma, and rhabdomyolysis (Table 2). In severe cases the rhabdomyolysis with disseminated intravascular coagulation and multisystem organ failure can lead to death (13). These symptoms are likely due to a sudden removal of baclofen-mediated GABA-B inhibition of the central

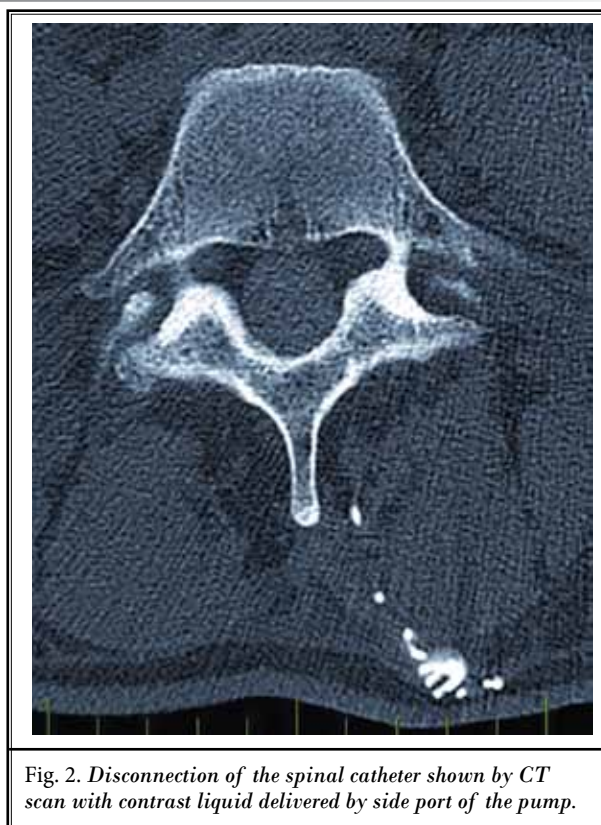


Fig. 2. Disconnection of the spinal catheter shown by CT scan with contrast liquid delivered by side port of the pump.




Fig. 3. Pump corrosion (A, B).

nervous system. Severe baclofen withdrawal syndrome may present with broader, systemic symptoms mimicking other syndromes such as autonomic dysreflexia, sepsis (24), serotonergic and neuroleptic malignant syndromes (25), and malignant hyperthermia. Clinical symptoms in our patients were mostly typical for baclofen withdrawal syndrome and we had no problem with differential diagnosis. The acute management of severe ITB withdrawal syndrome always requires hospitalization in the intensive care unit with monitoring of vital signs. ITB withdrawal syndrome usually lasts less than 2 – 3 days; however, in rare situations symptoms can persist for several weeks (26-27).

The main treatment goal is the quickest delivery of baclofen to the patient. In less severe ITB withdrawal syndrome, oral baclofen supplementum has been the most widely used method for treating withdrawal (15,20,21). If possible, it is prudent to use an external intrathecal catheter to provide bolus doses or an infusion until the implanted pump can be repaired or replaced (28). A commonly used intrathecal bolus dose is 50 µg. The most common adjuvant therapy for baclofen withdrawal is treatment with benzodiazepines. Other agents have varying degrees of success in the prevention and treatment of baclofen withdrawal symptoms including propofol, cyproheptadine, and dantrolene (29). In mild symptoms of baclofen withdrawal syndrome (e.g., increased spasticity and itching) we recommend symptomatic therapy with immediate admission to the hospital for observation in an intensive care unit until the symptoms disappear, as we practiced in

our patients. The treatment should start immediately after the established diagnosis of baclofen withdrawal syndrome. The dosage of oral baclofen depends on ITB dosage, and usually starts with 10 to 25 mg of baclofen 4 times daily, up to the maximum baclofen dose of 150 mg/day. Diazepam parenteral can be added as 1 – 2 mg/hour continuously. Our patients with acute baclofen withdrawal syndrome were treated successfully by this scheme with oral baclofen and parenteral benzodiazepines. The symptoms in our patients were mild and none of the patients required any mechanical ventilation support. When severe symptoms of baclofen withdrawal occur, an acute admission to the intensive care unit is necessary for assessment of vital function support with monitoring of liver and kidney functions to avoid multiorgan failure. When rhabdomyolysis is observed, dantrolene could be used to inhibit increased muscle tone and hypermetabolic status.

Different techniques are used to diagnose the presence and/or cause of an ITB system malfunction (30,31). We recommend a sequence of diagnostic steps to find the cause of discontinuation of ITB therapy (Table 2). Complications associated with the catheter are the most common, up to 74%, as a dislocation, break, occlusion, or disconnection (9,11,18,31-33). Obvious disconnection, malposition, migration, or breakage of the catheter is typically visible on plain radiographs. To determine where a catheter problem is located, a contrast liquid is applied through the entrance into the side port of the pump system under the skiascopy. Before such procedure, the catheter content must be emptied by at

least 2 mL of cerebrospinal fluid to prevent baclofen overdose. Then the contrast liquid is inserted and the integrity of the whole system is checked by x-ray. CT and CT myelography are helpful for better visualization. Magnetic resonance imaging (MRI) is important when a granuloma at the end of the catheter is suspected (34); however, in ITB treatment it is unlikely to be present (35,36). Radionuclide (Indium, Technetium) scintigraphy of ITB in the pump reservoir and subsequent tracing through the catheter system into the cerebrospinal fluid may be useful in revealing catheter obstruction (37). Indium has a longer half-life and could be injected into the running pump. During that time, Indium is spread in the cerebrospinal fluid along the length of the spinal cord to the basal cistern of the brain. Scans are done every day for 3 days to assess the leakage from the catheter. More sensitive neurophysiological techniques, such as H-reflex measurement, appear promising as an adjunctive diagnostic technique (38). It is especially useful for the establishment of an early diagnosis of a catheter-related problem such as incomplete system disruption or microfracture. Sometimes no catheter problem can be documented by imaging techniques, but catheter replacement may still rectify the problem. When pump failure is suspected, the rotor test with a single bolus of baclofen is recommended at the smallest size within the shortest period of application. To examine the position of the rotor, a plain radiograph of the pump rotor before the starting bolus and at the end of the bolus is necessary. Normal function of the rotor is ¼ turn of the pump. Possible causes of ITB delivery failure due to pump problems are connected to a low drug level in the reservoir or empty reservoir, rotor stall or computer error, mechanical damage, and battery failure (16). Rarely, repeated MRI can induce pump memory error (39). When the drug has lasted in the pump reservoir longer than permitted use of the drug (for Synchromed II more than 180 days), a pump corrosion may occur, which leads to malfunction of the system. It is recommended to use only one drug in the reservoir; however, a good experience with baclofen and morphine has been reported for treatment of pain and spasticity without any pump complication (40). Battery life of the pump is estimated to be up to 6 – 7 years, and then it must be replaced. Unfortunately, in our patient, pump corrosion was observed after 5 years and 3 months without any problem with refills before.

Except for baclofen withdrawal syndrome, a baclofen overdose belongs to another drug-related complications connected to ITB administration (22). Acute

baclofen overdose usually arises after human mistake during baclofen filling into the pump reservoir. The overdose may happen after a high dose of the drug, the change in concentration, the error in programming the pump, improper bridging dose of the drug. Symptoms of overdose include excessive weakness of muscles beginning in the lower limbs, fatigue, hypotension, sedation, sleepiness, dizziness, nausea and vomiting, seizures or coma requiring intensive care and assisted ventilation. Acute ITB overdose is managed with immediate cessation of baclofen delivery through the system, reducing the baclofen load by cerebrospinal fluid aspiration and by providing supportive treatment in an intensive care setting. It is also recommended to use physostigmine, which regulates breathing difficulties and somnolence (37). There is no specific antidote for reversing overdose symptoms.

The most common complications during surgical implantation of a pump system include local bleeding, local tissue damage, leakage of cerebrospinal fluid and infection (38-40). The subcutaneous pocket around the pump leads sometimes to a fluid collection (seroma), which is usually absorbed within 1 – 2 weeks. If it persists longer a surgical revision is recommended. Another serious complication of ITB delivery is an infection which may occur after the pump implantation in any place of the implanted system. Severe infections could lead to removal of the whole pump system (38). There is a risk of sepsis, meningitis or meningencephalitis; however, these events are rare (41). Quick identification of infectious agents is recommended, followed by a high dose of microbe-specific antibiotics. The preventive measures include sterile technique of pump system implantation and preventive intraoperative administration of antibiotics. Technical problems with puncture of intrathecal space can lead to leakage of cerebrospinal fluid. Blood patch of 15 – 20 mL of autologous blood in the epidural space to replace epidural perforation is recommended (39). Prevention of this complication is paramedian puncture approach and meticulous suture around the catheter to fix it up.

The most common complications with a pump are its overflow, twisting, damage and battery failure. Foreign-body reaction has been reported as a very rare complication (42). Rarely, repeated MRI can induce pump memory error (43). Overloading of the pump may cause damage of the reservoir and overdose the patient. When a failure of the pump is suspected the rotor test with x-ray before and after baclofen bolus is performed to detect proper rotation of the pump rotor.

When fixation of the pump is inappropriate or patient increases his weight, the pump may roll over with increased pressure on the catheter attached to the pump. For sterile filling of the reservoir pump an original package with antibacterial filter is recommended to prevent the infection into the intrathecal space.

## CONCLUSION

ITB withdrawal syndrome is a life-threatening event and prompt appropriate diagnosis before treat-

ment initiation is critical. Acute ITB withdrawal is managed by restoring the delivery of ITB, providing supportive care in an intensive care setting, and using drugs such as benzodiazepines or a low dose of propofol in selected cases.

Prerequisites for the successful application and follow-up of intrathecal pump systems are comprehensive professional training, knowledge of complications, and safe administration in the hands of a multidisciplinary team in the specialized centers.

## REFERENCES

- Albright AL, Gilmartin R, Swift D, Krach LE, Ivanhoses CB, McLaughlin JF. Long-term baclofen therapy for severe spasticity of cerebral origin. *J Neurosurg* 2003; 98:291-295.
- Azouvi P, Mane M, Thiebaut J-B, Denys P, Remy-Neris O, Bussel B. Intrathecal baclofen administration of severe spinal spasticity: Functional improvement and long-term follow-up. *Arch Phys Med Rehabil* 1996; 77:36-39.
- Avellino AM, Loeser JD. Intrathecal baclofen for treatment of intractable spasticity of spine or brain etiology. *Neuromodulation* 2000; 2:75-81.
- Boviatsis EJ, Kouyialis AT, Korfiatis S, Sakas DE. Functional outcome of intrathecal baclofen administration for severe spasticity. *Clin Neurol Neurosurg* 2005; 107:289-295.
- Zahavi A, Geertzen JHB, Staal M, Rietman JS. Long term effect (more than five years) of intrathecal baclofen on impairment, disability and quality of life in patients with severe spasticity of spinal origin. *J Neurol Neurosurg Psychiatry* 2004; 75:1553-1557.
- Campbell WM, Ferrel A, McLaughlin JF, Grant GA, Loeser JD, Graubert C, Bjornson K. Long-term safety and efficacy of continuous intrathecal baclofen. *Development Medicine and Child Neurology* 2002; 44:660-665.
- Rekand T, Grønning M. Treatment of spasticity related to multiple sclerosis with intrathecal baclofen: A long-term follow-up. *J Rehabil Med* 2011; 43:511-514.
- Dario A, Tomei G. A benefit-risk assessment of baclofen in severe spinal spasticity. *Drug Saf* 2004; 27:799-818.
- Draulans N, Vermeersch K, Degraeuwe B, Meurrens T, Peers K, Nuttin B, Kiekens C. Intrathecal baclofen in multiple sclerosis and spinal cord injury: Complications and long-term dosage evolution. *Clin Rehabil* 2013; 27:1137-1143.
- Vender JR, Hester S, Waller JL, Rekito A, Lee MR. Identification and management of intrathecal baclofen pump complications: A comparison of pediatric and adult patients. *J Neurosurg* 2006; 104:9-15.
- Stetkarova I, Yablom SA, Kofler M, Stokic DS. Procedure- and device-related complications of intrathecal baclofen administration for management of adult muscle hypertonias: A review. *Neurorehabil Neural Repair* 2010; 24:609-619.
- Siegfried RN, Jacobson L, Chabal C. Development of an acute withdrawal syndrome following the cessation of intrathecal baclofen in a patient with spasticity. *Anesthesiology* 1992; 77:1048-1050.
- Mohammed I, Hussain A. Intrathecal baclofen withdrawal syndrome - a life-threatening complication of baclofen pump: A case report. *BMC Clin Pharmacol* 2004; 4:6.
- Greenberg MI, Hendrickson RG. Baclofen withdrawal following removal of an intrathecal baclofen pump despite oral baclofen replacement. *J Toxicol Clin Toxicol* 2003; 41:83-85.
- Coffey RJ, Edgar TS, Francisco GE, Graziani V, Meythaler JM, Ridgely PM, Sadiq SA, Turner MS. Abrupt withdrawal from intrathecal baclofen: Recognition and management of a potentially life-threatening syndrome. *Arch Phys Med Rehabil* 2002; 83:735-741.
- Saulino M, Yablom S, Moberg-Wolff E, Chow JW, Stokic DS. Intrathecal baclofen for spasticity. In: *Spasticity: Diagnosis and Management* (Brashear A, Elovic E eds). Demos Medical Publishing, LLC, New York, NY, 2011. pp 229-242.
- Kumru H, Stetkarova I, Schindler C, Vidal J, Kofler M. Neurophysiological evidence for muscle tone reduction by intrathecal baclofen at the brainstem level. *Clin Neurophysiol* 2011; 122:1229-1237.
- Motta F, Antonello CE. Analysis of complications in 430 consecutive pediatric patients treated with intrathecal baclofen therapy: 14-year experience. *J Neurosurg Pediatr* 2014; 13:301-306.
- Dario A, Scamoni C, Picano M, Fortini G, Cuffari S, Tomei G. The infection risk of intrathecal drug infusion pumps after multiple refill procedures. *Neuromodulation* 2005; 8:36-39.
- Zuckerbraun NS, Ferson SS, Albright AL, Vogeley E. Intrathecal baclofen withdrawal: Emergent recognition and management. *Pediatr Emerg Care* 2004; 20:759-764.
- Ross JC, Cook AM, Stewart GL, Fahy BG. Acute intrathecal baclofen withdrawal: A brief review of treatment options. *Neurocrit Care* 2011; 14:103-108.
- Alden TD, Lytle RA, Park TS, Noetzel MJ, Ojemann JG. Intrathecal baclofen withdrawal: A case report and review of the literature. *Childs Nerv Syst* 2002; 18:522-525.
- Watve SV, Sivan M, Raza WA, Jamil FF. Management of acute overdose or withdrawal state in intrathecal baclofen therapy. *Spinal Cord* 2012; 50:107-111.
- Kao LW, Amin Y, Kirk MA, Turner MS. Intrathecal baclofen withdrawal mimicking sepsis. *J Emerg Med* 2003; 24:423-427.
- Salazar ML, Eiland LS. Intrathecal baclofen withdrawal resembling serotonin syndrome in an adolescent boy with cerebral palsy. *Pediatr Emerg Care* 2008; 24:691-693.



26. Hansen CR, Gooch JL, Such-Neibar T. Prolonged, severe intrathecal baclofen withdrawal syndrome: A case report. *Arch Phys Med Rehabil* 2007; 88:1468-1471.
27. Douglas AF, Weiner HL, Schwartz DR. Prolonged intrathecal baclofen withdrawal syndrome. Case report and discussion of current therapeutic management. *J Neurosurg* 2005; 102:1133-1336.
28. Bellingher A, Siriwetcharak R, Rosenquist R, Greenlee JD. Prevention of intrathecal baclofen withdrawal syndrome: Successful use of a temporary intrathecal catheter. *Reg Anesth Pain Med* 2009; 34:600-602.
29. Meythaler JM, Roper JF, Brunner RC. Cyproheptadine for intrathecal baclofen withdrawal. *Arch Phys Med Rehabil* 2003; 84:638-642.
30. Miracle AC, Fox MA, Ayyangar RN, Vyas A, Mukherji SK, Quint DJ. Imaging evaluation of intrathecal baclofen pump catheter systems. *AJNR Am J Neuroradiol* 2011; 32:1158-1164.
31. Awaad Y, Rizk T, Siddiqui I, Roosen N, McIntosh K, Waines GM. Complications of intrathecal baclofen pump: Prevention and cure. *ISRN Neurol* 2012; 2012:575168.
32. Dardashti S, Chang EY, Kim RB, Alsharif KI, Hata JT, Perret DM. False positive radiographical evidence of pump catheter migration into the spinal cord. *Pain Physician* 2013; 16:E627-E630.
33. Krames ES, Chapple I. Reliability a clinical utility of an implanted intraspinal catheter used in the treatment of spasticity and pain. *Neuromodulation* 2000; 3:7-14.
34. Stetkarova I, Vrba I, Tomas R, Kofler M. Does a narrow spinal canal facilitate intrathecal granuloma formation? A case report. *Cesk Slov Neurol N* 2013; 76:110-112.
35. Deer TR, Raso LJ, Garten TG. Inflammatory mass of an intrathecal catheter in patients receiving baclofen as a sole agent: A report of two cases and a review of the identification and treatment of the complication. *Pain Med* 2007; 8:259-262.
36. Deer TR, Raso LJ, Coffey RJ, Allen JW. Intrathecal baclofen and catheter tip inflammatory mass lesions (granulomas): A reevaluation of case reports and imaging findings in light of experimental, clinicopathological, and radiological evidence. *Pain Med* 2008; 9:391-395.
37. Frémondrière F, Saoût V, Lacœuille F, Ferrapie AL, Menei P, Couturier O, Richard I, Dinomais M. Isotopic scintigraphy combined with computed tomography: A useful method for investigating inefficiency of intrathecal baclofen. *J Rehabil Med* 2014; 46:712-714.
38. Stokic DS, Yablon SA, Hayes A. Comparison of clinical and neurophysiologic responses to intrathecal baclofen bolus administration in moderate-to-severe spasticity after acquired brain injury. *Arch Physiol Med Rehab* 2005; 86:1801-1806.
39. Kosturakis A, Gebhardt R. SynchroMed II intrathecal pump memory errors due to repeated magnetic resonance imaging. *Pain Physician* 2012; 15:475-477.
40. Saulino M. Simultaneous treatment of intractable pain and spasticity: Observations of combined intrathecal baclofen-morphine therapy over a 10-year clinical experience. *Eur J Phys Rehabil Med* 2012; 48:39-45.
41. Mueller-Schwefe G, Penn RD. Physostigmine in the treatment of intrathecal baclofen overdose. Report of three cases. *J Neurosurg* 1989;71:273-275.
42. Follet KA, Burchiel K, Deer T, DuPen S, Prager J, Turner MS, Coffey RJ. Prevention of intrathecal drug delivery catheter-related complications. *Neuromodulation* 2003;6:32-41.
43. Dominguez E, Latif O, Rozen D, Sahinler B, Orbegozo M, Edmunds A, Lou L, Day M, Racz G, Raj P. Subdural blood patch for the treatment of persistent CSF leak after permanent intrathecal catheter implantation: A report of two cases. *Pain Pract* 2001;1:344-353.
44. Follet KA, Boortz-Marx RL, Drake JM, DuPen S, Schneider SJ, Turner MS, Coffey RJ. Prevention and management of intrathecal drug delivery and spinal cord stimulation system infections. *Anesthesiology* 2004;6:1582-1594.
45. Wunderlich C, Krach LE. Gram-negative meningitis and infections in individuals treated with intrathecal baclofen for spasticity: A retrospective study. *Developmental Medicine and Child Neurology* 2006;48:450-455.
46. Bernuz B, Assier H, Bissierex H, Thiebaut JB, Rech C, Schnitzler A. Intrathecal baclofen pump: A foreign-body reaction case report and its solution. *J Rehabil Med* 2012; 44:184-185.

