

## Brief Commentary

## Lumbar Disc Herniation with Contralateral Radiculopathy: Do We Neglect the Epidural Fat?

Jun-Song Yang, MD, Dong-Jie Zhang, MS, and Ding-Jun Hao, MD, PhD

From: Department of Spinal Surgery, Hong-Hui Hospital Medical College of Xi'an Jiaotong University, Xi'an, 710054, China

Address Correspondence: Ding-Jun Hao, MD, PhD  
Department of Spinal Surgery  
Hong-Hui Hospital Medical College of Xi'an  
Jiaotong University Xi'an,  
710054, China  
E-mail: dingjun.hao@qq.com

Free full manuscript:  
[www.painphysicianjournal.com](http://www.painphysicianjournal.com)

Lumbar disc herniation (LDH) is the most common cause of radiculopathy, whose pathological entity underlying nerve root compression is usually on the same side as the symptoms. However, LDH causing contralateral radiculopathy are sometimes encountered by pain physicians. There have been tremendous developments in the treatment options for LDH; the situation of LDH causing contralateral radiculopathy is indeed a dilemma for some pain physicians. We will report a case of a patient with a L4-5 disc herniation whose left herniated disc caused radiculopathy on the right side. After a percutaneous lumbar endoscopic discectomy via the side ipsilateral to the symptomatic side, this case obtained a significant symptom remission. The migrated epidural fat is discussed as a cause of associated contralateral neurological deficit. Only via a surgical approach ipsilateral to the herniated side, could there be a clinical improvement postoperatively.

**Key words:** Contralateral symptoms, lumbar disc herniation, radiculopathy, epidural fat

**Pain Physician 2015; 18:E253-E256**

Lumbar disc herniation (LDH) is the most common cause of radiculopathy, with a pathological entity underlying nerve root compression, usually on the same side as the symptoms. However, LDH causing contralateral radiculopathy is sometimes encountered by pain physicians. Even though the treatments for LDH have shown tremendous developments; the situation of LDH causing contralateral radiculopathy is indeed a dilemma for some pain physicians. We will report a case of L4-L5 disc herniation with a left herniated disc which caused radiculopathy on the right side. After a percutaneous lumbar endoscopic discectomy via the side ipsilateral to the symptomatic side, this patient obtained significant symptom remission. The migrated epidural fat is discussed as a cause of associated contralateral neurological deficit. Only via a surgical approach ipsilateral to the herniated side, could a clinical improvement be obtained postoperatively.

A 50-year-old male patient, who complained about a 6-month history of aggravating lumbar pain accompanied by a radiated pain on his right leg, was referred to our hospital. Neurological examination revealed hy-

paesthesia on the lateral side of the right shank. However, the motor strength and sensation of the other portions of his lower extremities were normal. Straight leg rising test was also negative bilaterally. Magnetic resonance imaging (MRI) demonstrated a left paramedian herniation at L4-L5 disc (Fig. 1A). Although the patient underwent 2 months of physical therapy, the therapeutic efficiency was temporary and unsatisfactory. As the side of the neurological deficit was inconsistent with the herniated side, a selective diagnostic nerve block was performed in the L4-L5 foramen on his symptomatic side, in which a temporary symptom remission was obtained.

A percutaneous lumbar endoscopic exploration approached from the side ipsilateral to the symptomatic side was performed. Percutaneous entry was established at the right L4-L5 foramen entering through the skin approximately 12 cm lateral to the midline. With anteroposterior (AP) and lateral fluoroscopy, an 18-gauge puncture needle was placed in the L4-L5 disc through right Kambin's triangle. When the depth of the tip of the guide wire, which replaced the puncture

needle, was verified using lateral fluoroscopic imaging, a combined dilator-sheath system of suitable size was bluntly inserted. After a sequential dilation, the oval operation sheath was laid diagonally toward the right L4-L5 foramen. When insertion of the endoscope was complete, the operation was performed under the continuous irrigation of 0.9% saline solution. During the operation, it was observed that there was prominent venous engorgement and congestion in the epidural space. Venous structures and a part of epidural fat were cauterized with a trigger-flex bipolar radiofrequency. Thus, the embedded right L5 nerve root was gradually exposed. Meanwhile, it was noticed that, even though there was notable congestion, the L5 nerve root was not eroded by the protruded disc fragment. Immediately after releasing the L5 nerve root, partial remission of the radiating pain of the right leg was obtained. To avoid recurrence, a discectomy was performed via the right foramen to shrink the left protruded disc, in which the intradiscal pressure was reduced via decreasing the total volume inside the nucleus pulposus.

The patient's postoperative course was notable, in which the visual analogue scale of leg pain was decreased from 7 preoperatively to 2 immediately after the operation. The pain was finally eliminated in one week. In the further 6-month follow-up, no operation-related complications or recurrence were reported. A postoperative axial MRI was obtained at the 3-month follow-up (Fig. 1B).

After reviewing all published literature, the factors responsible for contralateral radiculopathy are listed as follows. Hunt et al (1) has reported a patient with contralateral radiculopathy after transforaminal lum-

bar interbody fusion (TLIF), in which the unequal operational distraction wedged the foramen and the disc space, and thus caused the asymptomatic stenosis on the non-operative side. In the clinical and morphometric study conducted by Karabekir et al (2), the asymmetrically hypertrophied ligamentum flava is deemed to be an etiology of contralateral sciatica among disc herniated patients. Kalemci et al (3) have reported a case of a contralateral neurological deficit, in which venous congestion was regarded as the cause. In the clinical series of Sucu and Gelal (4), a possible main mechanism of the contralateral symptom was that the varied traction forces to the spinal cord caused by the different projections of the herniations could result in stretching and trapping of the contralateral side of the nerve root, rather than direct compression. In addition, the unusual excessive dural attachments anchored on the posterior longitudinal ligament could be another reason.

Besides the aforementioned pathogenesis, based on the pain mechanism of spinal epidural lipomatosis, in which the excessive proliferation of the epidural adipose tissue could cause progressive neurological deficit (5-7), we believe that the migrated epidural fat is related to the contralateral neurological deficit. As we know, the spinal canal and its constituents (epidural fat, blood, cerebrospinal fluid, surrounding ligaments, and spinal cord) create a state of volume equilibrium (Fig. 2A). When the volume or the distribution of the constituents is altered, the volume equilibrium within the spinal canal could be changed. As the supporting framework within the spinal canal, the epidural fat supports and separates the other constituents within this comparable closed spinal canal. Once the disc is

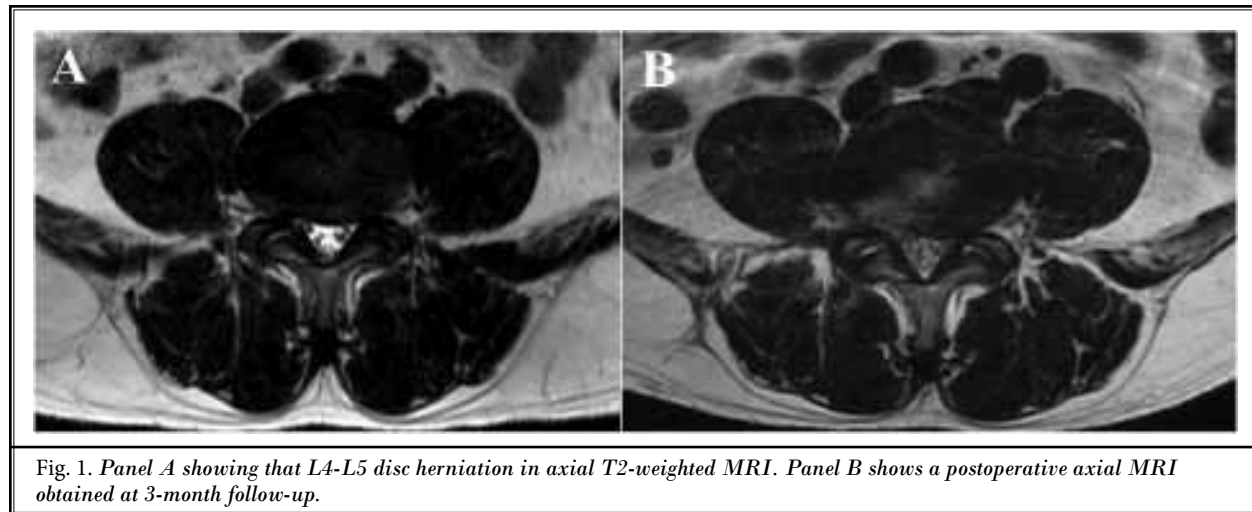


Fig. 1. Panel A showing that L4-L5 disc herniation in axial T2-weighted MRI. Panel B shows a postoperative axial MRI obtained at 3-month follow-up.

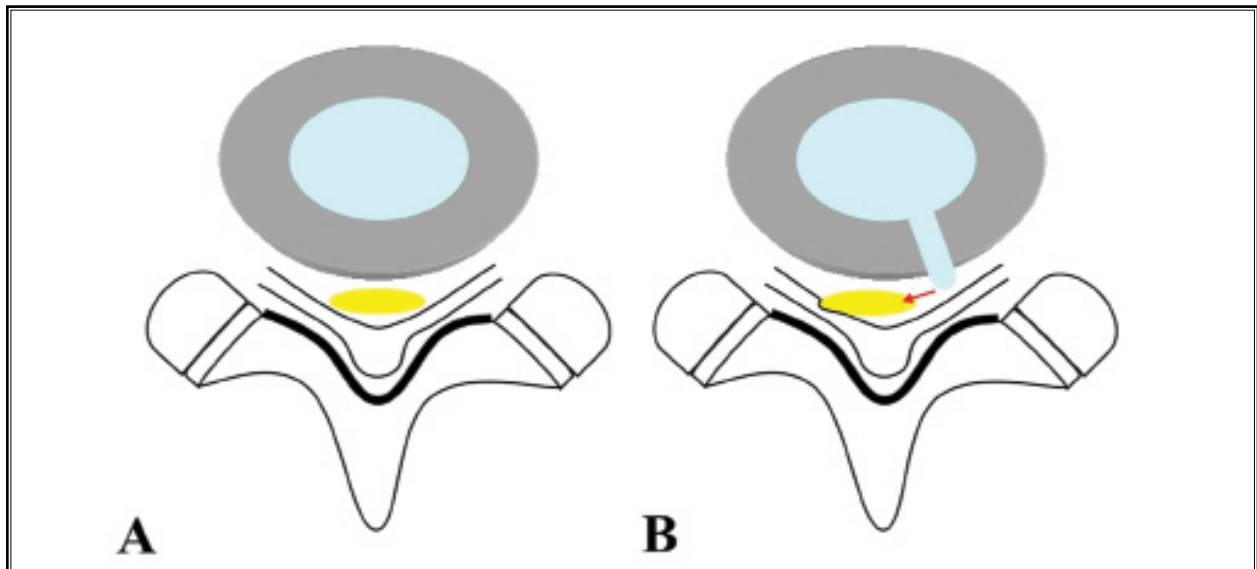


Fig. 2. Schematic drawings (Panel A and B) showing that dominance of the contralateral findings may be related to the migrated epidural fat in some patients.

herniated, as a main compensatory area, the epidural fat is first pushed away. Thus, the migrated epidural fat could generate encroachment to the contralateral neural contents (Fig. 2B). Additionally, it could lead to the venous engorgement and congestion in the epidural space and the nerve root, further exacerbating the neurological symptom. That also explains why a prominent venous congestion was observed in the L5 nerve root of our case, even without the direct compression from the contralateral herniated disc.

In the literature on surgical approaches for LDH with contralateral symptoms, both a unilateral approach only on the side of the herniated side (3,5,8,9) and bilateral exploration (10-12) have been described. Different from the aforementioned approaches, we obtained a significant symptom remission via an approach

on the symptomatic side. We believe that this approach is also efficacious. A satisfactory neural decompression is aimed at achieving a thorough neurolysis and exposing the neural content, in which the surrounding epidural fat is partially removed. Thus, the postoperative inner pressure within the spinal canal is actually reduced. That could explain that whatever the ipsilateral or contralateral approach you choose, a clinical improvement could be obtained postoperatively.

The migrated epidural fat plays a significant role in the pain mechanism of LDH with contralateral radiculopathy. Only via a surgical approach ipsilateral to the herniated side, could clinical improvement be obtained postoperatively. Because this is only one case, this conclusion needs to be verified in further comparative studies.

**REFERENCES**

1. Hunt T, Shen FH, Shaffrey CI, Arlet, V. Contralateral radiculopathy after transforaminal lumbar interbody fusion. *Eur Spine J* 2007;16:315.
2. Karabekir HS, Yildizhan A, Atar EK, Gocmen-Mas N, Yazici C. Effect of ligamenta flava hypertrophy on lumbar disc herniation with contralateral symptoms and signs: A clinical and morphometric study. *Arch Med Sci* 2010; 6:617-622.
3. Kalemci O, Kizmazoglu C, Ozer E, Arda MN. Lumbar disc herniation associated with contralateral neurological deficit: Can venous congestion be the cause? *Asian Spine J* 2013; 7:60-62.
4. Sucu HK, Gelal F. Lumbar disk herniation with contralateral symptoms. *Eur Spine J* 2006; 15:570-574.
5. Hooten WM, Hogan MS, Sanemann TC, Maus TJ. Acute spinal pain during an attempted lumbar epidural blood patch in congenital lumbar spinal stenosis and epidural lipomatosis. *Pain Physician* 2008; 11:87-90.
6. Vince GH, Brucker C, Langmann P, Herbold C, Solymosi L, Roosen K. Epidural spinal lipomatosis with acute onset of paraplegia in an HIV-positive patient treated with corticosteroids and protease inhibitor: Case report. *Spine (Phila Pa 1976)* 2005; 30:E524-E527.
7. Venkatanarasimha N, Parrish RW. Case 148: Thoracic epidural lipomatosis. *Radiology* 2009; 252:618-622.
8. Lee DY, Lee SH. Recurrent lumbar disc herniation with contralateral symptoms treated by percutaneous endoscopic discectomy. *Kor J Spine* 2007; 4:41-43.
9. Akdeniz T, Kaner T, Tutkan I, Ozer AF. Unilateral surgical approach for lumbar disc herniation with contralateral symptoms. *J Neurosurg Spine* 2012; 17:124-127.
10. Choudhury AR, Taylor JC, Worthington BS, Whitaker R. Lumbar radiculopathy contralateral to upper lumbar disc herniation: Report of 3 cases. *Br J Surg* 1978; 65:842-844.
11. Kornberg M. Sciatica contralateral to lumbar disk herniation. *Orthopedics* 1994; 17:362-364.
12. Mirovsky Y, Halperin N. Eccentric compression of the spinal canal causing dominantly contralateral-side symptoms. *J Spinal Disord* 2000; 13:174-177.