

Retrospective Study

## Transforaminal Endoscopic Treatment of Lumbar Radiculopathy after Instrumented Lumbar Spine Fusion

Albert E. Telfeian, MD, PhD<sup>1</sup>, Gabriele P. Jasper, MD<sup>2</sup>, and Gina M. Francisco, BSc<sup>2</sup>

From: <sup>1</sup>Brown University, Dept. of Neurosurgery, <sup>2</sup>Center for Pain Control, Brick, NJ

Address Correspondence: Albert E. Telfeian, MD, PhD  
Brown University  
Dept. of Neurosurgery  
593 Eddy Street  
Rhode Island Hospital  
Providence, RI 02903  
E-mail: albert.telfeian@nts-online.net

Disclaimer: There was no external funding in the preparation of this manuscript. Conflict of interest: Each author certifies that he or she, or a member of his or her immediate family, has no commercial association (i.e., consultancies, stock ownership, equity interest, patent/licensing arrangements, etc.) that might pose a conflict of interest in connection with the submitted manuscript.

Manuscript received: 09-29-2014  
Revised manuscript received: 11-24-2014  
Accepted for publication: 12-19-2014

Free full manuscript: [www.painphysicianjournal.com](http://www.painphysicianjournal.com)

**Background:** Transforaminal endoscopic discectomy and foraminotomy is a well-described minimally invasive technique for surgically treating lumbar radiculopathy caused by a herniated disc and foraminal narrowing.

**Objective:** To describe the technique and feasibility of transforaminal foraminoplasty for the treatment of lumbar radiculopathy in patients who have already undergone instrumented spinal fusion.

**Study Design:** Retrospective study.

**Setting:** Hospital and ambulatory surgery center

**Methods:** After Institutional Review Board approval, charts from 18 consecutive patients with lumbar radiculopathy and instrumented spinal fusions who underwent endoscopic procedures between 2008 and 2013 were reviewed.

**Results:** The average pain relief one year postoperatively was reported to be 67.0%, good results as defined by MacNab. The average preoperative VAS score was 9.14, indicated in our questionnaire as severe and constant pain. The average one year postoperative VAS score was 3.00, indicated in our questionnaire as mild and intermittent pain.

**Limitations:** This is a retrospective study and only offers one year follow-up data for patients with instrumented fusions who have undergone endoscopic spine surgery.

**Conclusion:** Transforaminal endoscopic discectomy and foraminotomy could be used as a safe, yet, minimally invasive and innovative technique for the treatment of lumbar radiculopathy in the setting of previous instrumented lumbar fusion.

**IRB approval:** Meridian Health: IRB Study # 201206071J

**Key words:** Endoscopic discectomy, minimally-invasive, transforaminal, fusion

**Pain Physician 2015; 18:179-184**

**T**echnological advances in spine interventions have seen a boom in the past 2 decades, and in the most recent decade, secondary to more minimally invasive surgical options. Incisions may be getting smaller, but the number of surgeries is not. According to a report by the Agency for Healthcare

Research and Quality (AHRQ), approximately 488,000 spinal fusions were performed during U.S. hospital stays in 2011, which accounted for a 70 percent growth in procedures from 2001 (1-2).

As these new less invasive techniques are applied in clinical practice, we must be ready with new solu-

tions to the complications that subsequently arise. One difficulty with any minimally invasive fusion approach is performing an extensive enough discectomy and bilateral foraminal decompression when restricted by a narrow minimally invasive incision or retractor system. For patients with continued or recurrent radicular pain after surgery, the options presented may include life-long interventional pain management, dorsal column stimulation, and or chronic oral or intrathecal narcotic usage. Transforaminal endoscopic discectomy and foraminotomy is described here as an ultra-minimally invasive solution to the problem of lumbar radiculopathy in the setting of a previous instrumented spinal fusion.

## METHODS

### Patients

After Institutional Review Board Approval, charts from 18 consecutive patients (mean age 64.0, 6 women [33%] and 12 men [67%]) with lumbar radiculopathy

and instrumented spinal fusions who underwent endoscopic procedures between 2008 and 2013 were reviewed. Tables 1 and 2 show the patient demographic data and clinical results for patients undergoing single level and multi-level endoscopic treatment. Data on patients receiving endoscopic treatment at the levels of arthrodesis is presented primarily. The only data included that represents disease adjacent to a fused level is included in Table 2: a 64-year-old man who presented with an L3-5 fusion and underwent endoscopic treatment at L3-4, L4-5, and L5-S1.

### Operative Technique

Patients were selected for treatment based on the results of their magnetic resonance imaging (MRI), computed tomography (CT), physical exam, dermatomal pain pattern, and favorable response to transforaminal injection. All patients considered for endoscopic surgical treatment had already exhausted more conservative treatments which included, but

Table 1. Results of single level transforaminal endoscopic discectomy and foraminotomy after instrumented lumbar fusion.

Age	Gender	Fusion	Endo	Levels	Side	Pre-op VAS	1 year VAS	% Improved
40	M	L5-S1	L5-S1	1	Right	100	20	80
40	M	L4-5	L4-5	1	Left	100	0	100
45	M	L5-S1	L5-S1	1	Left	95	0	100
59	F	L3-4	L3-4	1	Left	80	40	50
61	M	L4-5	L4-5	1	Left	100	10	90
65	F	L5-S1	L5-S1	1	Left	80	10	87.5
72	M	L2-3	L2-3	1	Left	100	0	100
73	M	L3-4	L3-4	1	Left	100	50	50
84	M	L4-5	L4-5	1	Left	90	0	100

Table 2. Results of multi-level transforaminal endoscopic discectomy and foraminotomy after instrumented lumbar fusion.

Age	Gender	Fusion	Endo	Levels	Side	Pre-op VAS	1 year VAS	% Improved
53	M	L4-S1	L4-S1	2	Right	100	75	25
53	M	L3-S1	L3-S1	3	Right	100	70	30
64	M	L3-5	L3-S1	3	Left	90	5	94
65	M	L2-3	L2-4	2	Bilat.	70	20	71
67	F	L3-5	L3-5	2	Right	80	60	25
67	F	L3-S1	L3-S1	3	Left	100	25	75
68	F	L3-5	L3-5	2	Right	80	65	18.75
77	F	L2-4	L2-4	2	Right	100	90	10
81	M	L4-S1	L4-S1	2	Right	80	0	100

were not limited to, physical therapy and epidural steroid injections.

Patients were positioned prone on the Wilson frame or in the lateral decubitus position with the operating room table reversed and the flank over the break in the table. A roll was placed under the flank and the table flexed to open the disc space when the lateral position was used.

The procedure was done under local and intravenous sedation; the level of anesthetic was titrated so the patient was able to communicate with the surgeon throughout the procedure. The Joimax TESSYS (Joimax, Germany) endoscopic system was used for the procedure. Percutaneous entry was established entering through the skin 10 – 16 cm lateral to the midline. Using intermittent fluoroscopic guidance, alternating between lateral and anterior-posterior (AP) view, or using tunnel or bull's-eye technique, a 25 cm 18 gauge needle was advanced and placed in the disc space through Kambin's triangle, between the exiting and traversing nerves. An AP fluoroscopic view was used so the disc space was not entered before the needle was past medial border of the pedicle.

Sequential reamers were used to enlarge the neural foramen by removing the ventral aspect of the superior facet. Three technical innovations were utilized to expand the neural foramen (foraminoplasty): 1) "joystick" reaming, 2) endoscopic drilling, and 3) endoscopic chiseling. "Joystick" reaming was performed by inserting a large caliber reamer over

a smaller caliber dilator. The free room between the larger reamer and smaller dilator allowed the reamer to be toggled posteriorly to over-ream the superior articulating process and enlarge the foramen and better decompress the exiting nerve (Fig. 1). Endoscopic drilling was often performed at an oblique angle targeting the junction of the superior articulating process and the pedicle to unroof the traversing nerve (Fig. 1). The endoscopic chisel was used to unroof the exiting (Fig. 1) and traversing nerve roots after reaming and endoscopic drilling.

Discectomy was performed with straight, up going, and bendable graspers (Fig. 2). After foraminoplasty techniques, the semi-bendable grasper could be observed reaching under the exiting nerve root in the epidural space with endoscopic and fluoroscopic visualization (Fig. 2). By rotating the beveled canula working channel and endoscope, a 360 degree visualization of the annulus and exiting and traversing nerve roots was possible. The technical success of the foraminotomy procedure was determined by the visualization of the exiting and traversing nerve root and visualizing the ball probed dilator passing freely under the nerve and over the inferior pedicle (Fig. 3). After adequate discectomy and foraminotomy, the patient was asked prior to terminating the procedure the status of his or her radicular symptoms. The working channel and scope were removed, pressure was held on the 5 mm incision for 5 minutes, and the wound was closed with a single interrupted suture and a band aid.

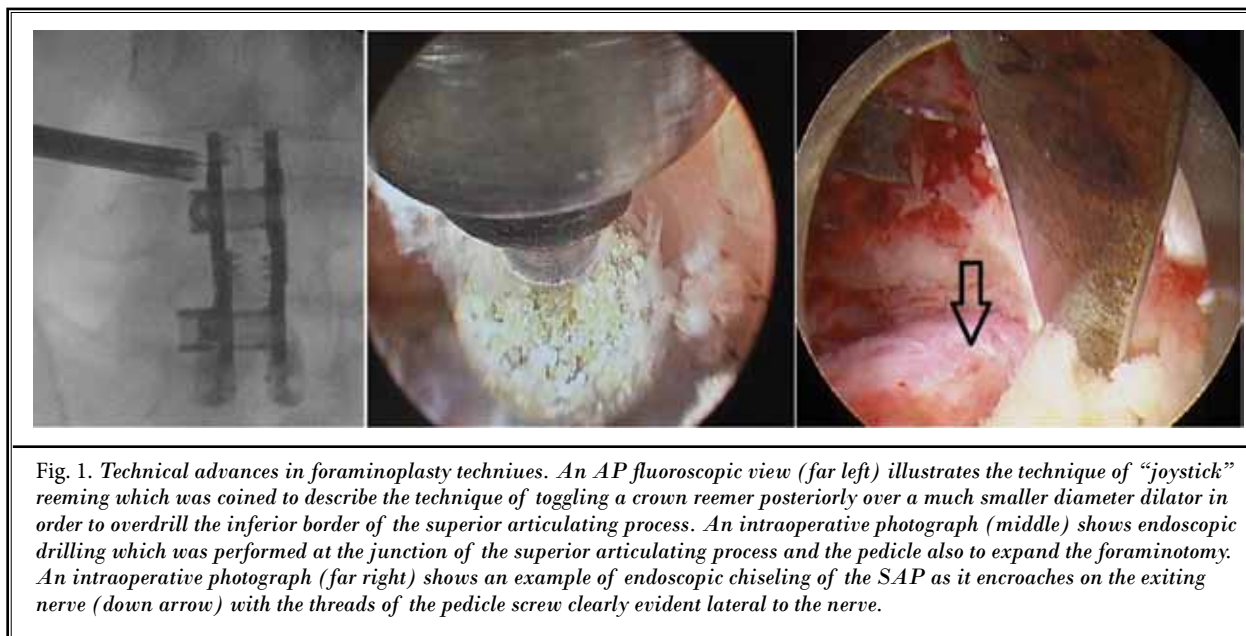
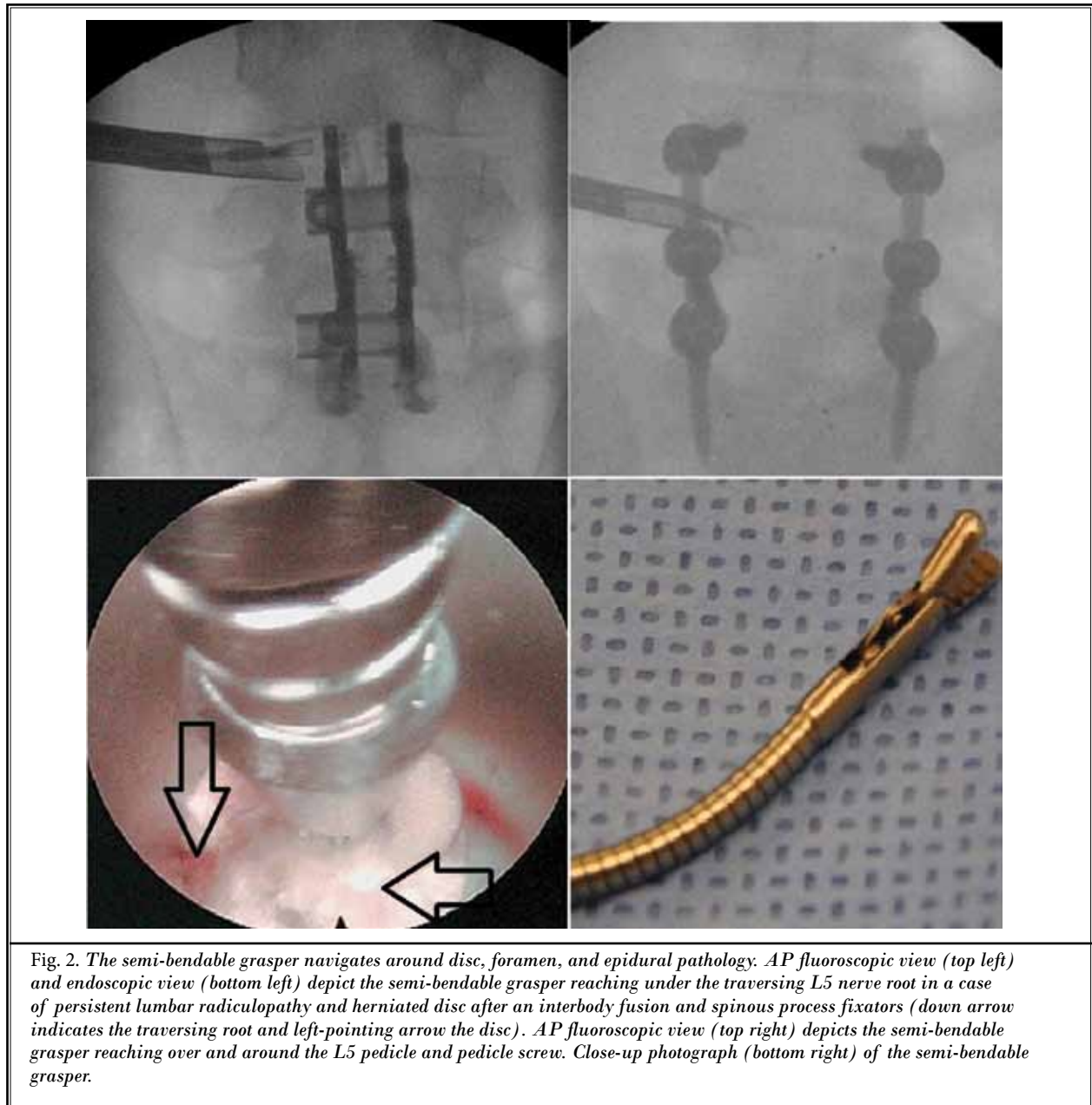


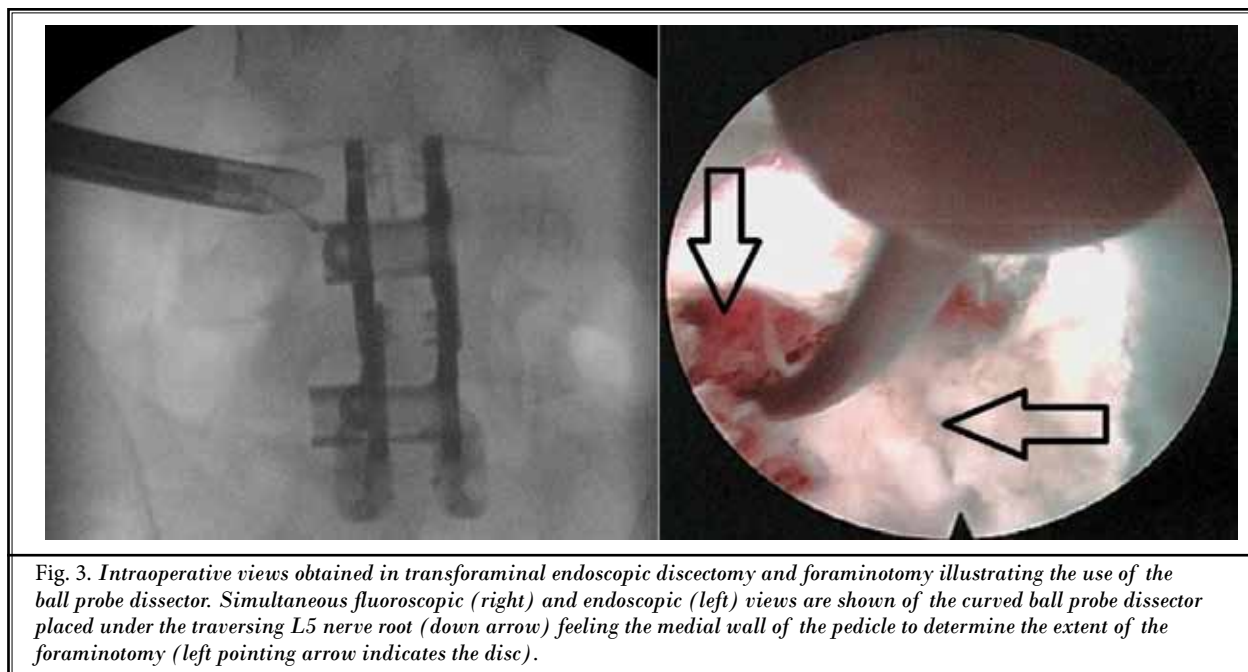
Fig. 1. Technical advances in foraminoplasty techniques. An AP fluoroscopic view (far left) illustrates the technique of "joystick" reaming which was coined to describe the technique of toggling a crown reamer posteriorly over a much smaller diameter dilator in order to overdrill the inferior border of the superior articulating process. An intraoperative photograph (middle) shows endoscopic drilling which was performed at the junction of the superior articulating process and the pedicle also to expand the foraminotomy. An intraoperative photograph (far right) shows an example of endoscopic chiseling of the SAP as it encroaches on the exiting nerve (down arrow) with the threads of the pedicle screw clearly evident lateral to the nerve.



## RESULTS

Eighteen patients underwent discectomy and foraminotomy at 30 spine levels, 8 on the right side, 9 on the left side, and one bilaterally. There were 9 single level, 6 two level, and 3 three level endoscopic treatments performed. The 18 patients treated had a total of 28 levels fused: 10 one level, 6 two level, and 2 three level instrumented fusions. The average

pain relief one year postoperatively was reported to be 67.0%, good results as defined by MacNab. The average preoperative VAS score was 9.14, indicated in our questionnaire as severe and constant pain. The average one year postoperative VAS score was 3.00, indicated in our questionnaire as mild and intermittent pain. For the 9 single level cases, the average pain relief one year postoperatively was reported to be 84.2%, excellent results as defined by MacNab. The



average preoperative VAS score was 9.39. The average one year post-operative VAS score was 1.44, indicated in our questionnaire as mild and intermittent pain. For the 9 multi-level cases, the average pain relief one year postoperatively was reported to be 49.9%, fair results as defined by MacNab. The average preoperative VAS score was 8.89. The average one year postoperative VAS score was 4.56, indicated in our questionnaire as mild to moderate pain.

## Discussion

Since the development of screw fixation by Michele and Krueger in 1949 (3) and metallic rod stabilization by Harrington in 1953 (4), arthrodesis of the lumbar spine has seen an ever-increasing number of new technologies to enhance fusion rates and with these technologies more minimally invasive approaches that might spare tissue damage but might also be limited in their effectiveness in achieving nerve root decompression or complete discectomy. There is very little literature available regarding recurrent radiculopathy after instrumented lumbar fusion procedures. Possible causes for lumbar radiculopathy post-instrumented fusion include pseudoarthrosis (5), incomplete disc removal (6), and inadequate contralateral decompression after transforaminal lumbar interbody fusion (7).

In our series of patients, not surprisingly, patients who needed only single level endoscopic foraminal

decompression did better than those who needed multi-level endoscopic foraminal decompression. Considering the other treatment options available to patients with residual or recurrent radicular symptoms after instrumented spinal fusions, the significant improvements seen after endoscopic foraminal decompression were somewhat surprising: on average between 49% and 84% improvement after one year.

Other studies have shown that endoscopic spine surgery is an effective procedure for treating multiple pathologies in the lumbar spine including lateral, paracentral, central, extruded, and even contralateral herniated discs as well as lateral recess stenosis (8-11). In this series, transforaminal endoscopic discectomy and foraminotomy is proposed as a novel "rescue" technique in the setting of lumbar disc reherniation and foraminal stenosis after instrumented lumbar fusion. Posterior hardware such as interspinous fixators, large pedicle screw heads, and crosslinks between rod fixators pose a strategic challenge to offering patients minimally invasive posterior surgeries to repair unintended complications of instrumented fusion procedures. Here a transforaminal approach that avoids a repeat posterior approach, is truly minimally invasive, and does not require general anesthesia is suggested as a helpful addition in the minimally invasive spine internationalist's armamentarium.

## CONCLUSION

Endoscopic spine surgery is a burgeoning subfield in minimally invasive spine surgery. A Medline search for "endoscopic discectomy" revealed only 12 references for the years 1990 through 1993, but 72 references for the years 2000 through 2003 and 160 references

for the years 2010 through 2013. Current prospective studies on endoscopic spine techniques are being performed by spine specialists throughout the world. This study represents only a retrospective clinical investigation on a small cohort of patients and is presented only as preliminary data on what is now being studied in a prospective manner.

## REFERENCES

- Weiss AJ, Elixhauser A, Andrews RM. Characteristics of operating room procedures in U.S. hospitals, 2011. *HCUP Statistical Brief #170*. Agency for Healthcare Research and Quality, Rockville, MD, 2014.
- Weiss AJ, Elixhauser A. Trends in operating room procedures in U.S. hospitals, 2001-2011. *HCUP Statistical Brief #171*. Agency for Healthcare Research and Quality, Rockville, MD, 2014.
- Albert TJ, Jones AM, Balderston RA. Spinal instrumentation. In: Rothman RH, Simeone FA (eds). *The Spine*. 3rd ed. WB Saunders. Philadelphia, 1992, pp 1777-1796.
- Harrington PR. Treatment of scoliosis: Correction and internal fixation by spine instrumentation. *J Bone Joint Surg Am* 2002; 84-A:316.
- Faundez AA1, Schwender JD, Safriel Y, Gilbert TJ, Mehbod AA, Denis F, Transfeldt EE, Wroblewski JM. Clinical and radiological outcome of anterior-posterior fusion versus transforaminal lumbar interbody fusion for symptomatic disc degeneration: A retrospective comparative study of 133 patients. *Eur Spine J* 2009; 18:203-211.
- Gertzbein SD1, Hollopeter MR. Disc herniation after lumbar fusion. *Spine* 2002; 27:E373-376.
- Hunt T, Shen FH, Shaffrey CI, Arlet V. Contralateral radiculopathy after transforaminal lumbar interbody fusion. *Eur Spine J* 2007; 16:311-314.
- Choi G, Lee SH, Lokhande P, Kong BJ, Shim CS, Jung B, Kim JS. Percutaneous endoscopic approach for highly migrated intracanal disc herniations by foraminal technique using rigid working channel endoscope. *Spine* 2008; 1:E508-515.
- Ruetten S, Komp M, Merk H, Godolias G. Full-endoscopic interlaminar and transforaminal lumbar discectomy versus conventional microsurgical technique: A prospective, randomized, controlled study. *Spine* 2008; 33:931-939.
- Ruetten S, Komp M, Merk H, Godolias G. Surgical treatment for lumbar lateral recess stenosis with the full-endoscopic interlaminar approach versus conventional microsurgical technique: A prospective, randomized, controlled study. *J Neurosurg Spine* 2009; 10:476-485.
- Yeom KS, Choi YS. Full endoscopic contralateral transforaminal discectomy for distally migrated lumbar disc herniation. *J Orthop Sci* 2011; 16:263-269.