

Case Report

Successful Treatment of Post Thrombotic Syndrome with Sequential Lumbar Sympathetic Block

Anita Gupta, DO, PharmD, Brittany Portonova, DPM, and Cyrus Dadachanji, MD

From: Drexel University College of Medicine, Philadelphia, PA

Address Correspondence:
Anita Gupta, DO, PharmD
Vice Chair/Associate Professor
Drexel University College of
Medicine
Dept. of Anesthesiology and
Perioperative Medicine
245 N. 15th Street MS #310
Philadelphia, PA
E-mail:
anita.gupta@drexelmed.edu

Disclaimer: There was no external funding in the preparation of this manuscript.

Conflict of interest: Each author certifies that he or she, or a member of his or her immediate family, has no commercial association (i.e., consultancies, stock ownership, equity interest, patent/licensing arrangements, etc.) that might pose a conflict of interest in connection with the submitted manuscript.

Manuscript received: 05-05-2014
Revised manuscript received:
09-08-2014
Accepted for publication:
09-22-2014

Free full manuscript:
www.painphysicianjournal.com

An underappreciated sequelae of deep venous thrombosis (DVT) is the pain associated with the blood clot in the peripheral extremity. Although most frequently acute in nature, DVT occasionally presents with chronic pain in the affected limb. Furthermore, many individuals suffering from prothrombotic states often have recurring pain from DVT. Thus far there has been a paucity in the medical literature in how to treat post thrombotic pain. Post thrombotic syndrome (PTS) can cause a significant decrease in quality of life in individuals who have had a history of a DVT. Symptoms will typically include edema, pain, heaviness of the affected limb, skin changes, ulcers, varicosities, and gait abnormality. An underappreciated approach to treating PTS is the utilization of lumbar sympathetic blocks (LSB). A 68-year-old male who had a history of recurrent right lower extremity deep venous thrombosis presented with complaints of excruciating pain, discomfort, and erythema in his right lower extremity, which was negatively affecting his quality of life and prohibiting him from mobility. The patient attributed his lack of mobility secondary to the thrombotic pain. Compression boot/stocking therapy was not combating the discomfort associated with the PTS, often increasing the severity of the patient's pain. Sequential right lumbar sympathetic blocks were performed, which nearly completely resolved the patient's symptoms and improved the patient's ambulatory status and ability to perform activities of daily living. Sympathetic nerve blocks should be considered as a treatment option for patients who suffer with pain from PTS.

Key words: Pain, edema, lumbar, sympathetic, thrombosis, venous

Pain Physician 2015; 18:E65-E69

Lower extremity edema is often a painful and debilitating disease process that causes patients pain and limits their ability to perform activities of daily living. Lower extremity edema etiologies are numerous and can be both systemic and/or local in nature including but not limited to cardiac failure, renal and hepatic disease, venous/lymphatic disorders, trauma, and infection (1). One common etiology, which especially presents as unilateral, is a deep venous thrombosis, which can lead to chronic changes in the

affected limb. These chronic, debilitating changes are collectively called post thrombotic syndrome (PTS) (2).

Patients who suffer from PTS will present with edema, pain, heaviness, gait abnormalities, localized skin discoloration, ulcers, and varicosities, and many report a decrease in their quality of life. Treatment options are often limited and usually focus on compression therapy and topical treatments for skin changes (3). Sympathetic nerve blocks, however, may help to reduce pain and edema and increase quality of life for patient with PTS.

Lumbar sympathetic blocks (LSB) are commonly utilized by physicians to treat pain associated with lower extremity pathology such as phantom limb, complex regional pain syndrome, neuropathy, and a variety of vascular conditions (4). They are indicated in treating such conditions that present with symptoms of altered sympathetic tone, which include pain, erythema, edema, abnormal skin temperature, and dystrophic changes to the limb (5). You can expect to see vasodilation, increased skin temperature, decreased edema, reduction in erythema, and a decrease in pain as potential effects of a LSB. The goal of a LSB is to stop the pain cascade and optimize blood flow through the extremity (4,5).

Overview of Post Thrombotic Syndrome

A deep venous thrombosis (DVT) is commonly recognized as only an acute emergency that requires timely treatment to prevent any serious complications. While this is true, the chronic consequences of DVTs are not as commonly considered. Between 20% – 50% of patients who have a DVT will go on to develop PTS (6). There are predictive factors which are considered to be highly correlated with the development of PTS including continued symptoms of initial DVT after one month of onset, recurrent ipsilateral DVT, extensive DVT, obesity, and old age (7).

Symptoms of PTS include intractable leg edema, achy discomfort, heaviness of affected limb, itching, tingling, varicosities, telangiectasia, localized erythema or hyperpigmented skin changes, induration of skin, and leg ulcers (1,6,7). Patients will often express that their physical abilities are severely limited because of the pain and discomfort associated with PTS. As a result, PTS has been shown to have a significant affect on quality of life and health care costs (2,8).

Prevention of PTS, following acute onset of a DVT, has been shown to be difficult and inconsistent. Some studies have shown that there is significant benefit in wearing compression stockings for a 2-year period following onset of DVT, while others have demonstrated that this evidence is not fully supported (8,9). Local thrombolysis of the DVT in the acute phase has shown in preliminary trials to prevent the onset of PTS, but is typically reserved for more extensive DVTs because of risks associated with the procedure. Early thrombolysis may help to preserve the venous structure and prevent chronic change to the vessel; however, its efficacy and benefit is still being investigated (7).

Treatment of PTS has also proven to be difficult and frustrating for patients. Compression stockings

are considered a primary form of treatment but with higher-grade compression stockings, compliance is an important factor to be considered. High-grade compression stockings, 30 – 40 mmHg, are preferred but pose great difficulty for patients who have to apply them on their own. Even when worn consistently, pain, swelling, and skin changes often do not resolve, leaving the patient with limited treatment options. Venoactive medications and endovascular procedures are often implemented as treatment options but do not consistently provide long-term relief for patients (7-12).

Case Presentation

A 68-year-old man presented to the University Pain Institute at Hahnemann as a referral from a neurosurgeon for complaints of chronic back pain, as well as painful right lower extremity edema and erythema. At this time his referring physician had attributed his symptoms to complex regional pain syndrome and they were interested in management of this condition. He described the pain in his right lower extremity to be sharp and achy with occasional spasms. The swelling also affected his gait pattern and has been getting progressively worse over the past 2 years. He was wearing compression stockings to bilateral lower extremities at this time but they were not helping to manage his right lower extremity edema and pain. The patient had a history of mild chronic bilateral lower leg edema due to his cardiac illness.

At this time the patient reported a sharp decline in his quality of life. Prior to visiting our office, the patient had seen another outside physician who performed a sympathetic nerve block that offered him 100% relief of his symptoms, but they had since returned.

His past medical history was significant for hypertension, hypothyroid, ischemic cardiomyopathy with orthotopic heart transplant in 2003, sleep apnea, obesity, gastric polyp, history of multiple hernia repairs, L4-L5 Laminectomy and fusion in 2010, and L3-L5 laminectomy and fusion in 2013. Consequently, around the time of his spinal surgeries, he also had a DVT in his right calf in 2010 and again in 2013. Ultrasound studies did show that he only had partial resolution of his initial DVT, with new onset DVT in the same region; right femoral and popliteal veins. The patient was placed on anticoagulation therapy with coumadin for 6 months following each DVT. While the patient was admitted for his DVT, a hematology/oncology team was consulted to rule out a hypercoagulable disease process.

Physical examination revealed bilateral lower ex-

tremity 2+ pitting edema with the right significantly worse than the left. Erythema was present from the level of the right ankle malleoli to the tibial tuberosity with absence of warmth. There were no open lesions or evidence of infection. Gross sensation and reflexes were intact and within normal limits to the bilateral lower extremities. The patient had an antalgic gait with diffuse discomfort upon palpation of the right distal lower extremity.

At this time, we proposed treatment with a right lumbar sympathetic nerve block. Current literature does support the use of LSB for patients with complex regional pain syndrome but nothing has been reported for patients with PTS. We were attempting to treat the patient based upon the underlying physiology that if LSB can reduce pain and erythema and optimize blood flow in complex regional pain syndrome patients that it will prove to have similar affects in a patient with PTS.

Management and Outcomes

Prior to any treatment planning, the patient was referred to a vascular surgeon to rule out any acute vascular conditions that could explain his symptoms. The patient's referring neurosurgeon also indicated that other than clinical suspicion for complex regional pain syndrome, there were no other neurological concerns currently. Given the patient's physical exam findings and previous success with his sympathetic nerve block, it was decided to perform a lumbar sympathetic nerve block and concomitantly continue use of his compression stockings for therapy. His symptoms and clinical exam were more consistent with that of PTS rather than complex regional pain syndrome as outlined in Table 1.

METHODS

A series of 3 right lumbar sympathetic blocks was done under intravenous conscious sedation over the course of one year. The procedure was performed in the

prone position utilizing fluoroscopic guidance. After the patient was sterilely prepped with cholraprep and draped, the L2-L3 interspace was identified. Using 1% lidocaine, a subcutaneous skin wheal was created 3 inches ipsilateral to the interspinous space on the right side. A 22g 5-inch spinal needle was inserted at approximately a 45 degree angle. After the needle touched the anterolateral border of the upper vertebral body at about 2 inches, it was walked off anteriorly until bony contact was lost. The needle aspirated negative for blood and cerebrospinal fluid. Subsequently, 1 mL of intravenous contrast was injected and a longitudinal spread was visualized. A single injection of 15 mL of 0.25% bupivacaine was used for the nerve block.

Following the patients first nerve block, he reported 80% reduction of his pain and improvement in his right lower extremity edema and erythema. His pain scale ranking at this time was 5/10 (Fig. 1).

A second LSB was performed 2 months later. Following the second nerve block, the patient's erythema was almost completely resolved and his right lower extremity edema was reduced and now considered to be equal when compared to his contralateral limb. He reported a 2/10 rating on the pain scale along with a significant improvement in his ability to perform daily activities. At this point in time he was satisfied with the clinical progress that was made. The patient continued to wear his compression stockings to control residual bilateral edema. A third LSB was performed 5 months later for residual pain; the patient still has to complete his post procedure follow-up. Results are outlined in Fig. 2.

DISCUSSION

PTS can cause a significant decrease in quality of life in individuals who have had a history of a DVT. Treatment options are limited and patients are often left struggling with debilitating symptoms including

Table 1. Symptoms of PTS versus complex regional pain syndrome.

| | Post Thrombotic Syndrome | Complex Regional Pain Syndrome |
|--------------------|----------------------------------|--|
| Onset/Etiology | History of DVT | History of trauma |
| Pain/Discomfort | Achy, heavy, itching | Burning |
| Skin color | Red, brown-hyperpigmentation | Blotchy, red, purple, pale |
| Skin texture | -Late - in duration | -Early - Excessive sweating Late - Atrophic, thin skin |
| Ulcers | May be present | Typically not present |
| Mechanism of Edema | Increased capillary permeability | Neurogenically mediated increased capillary permeability |

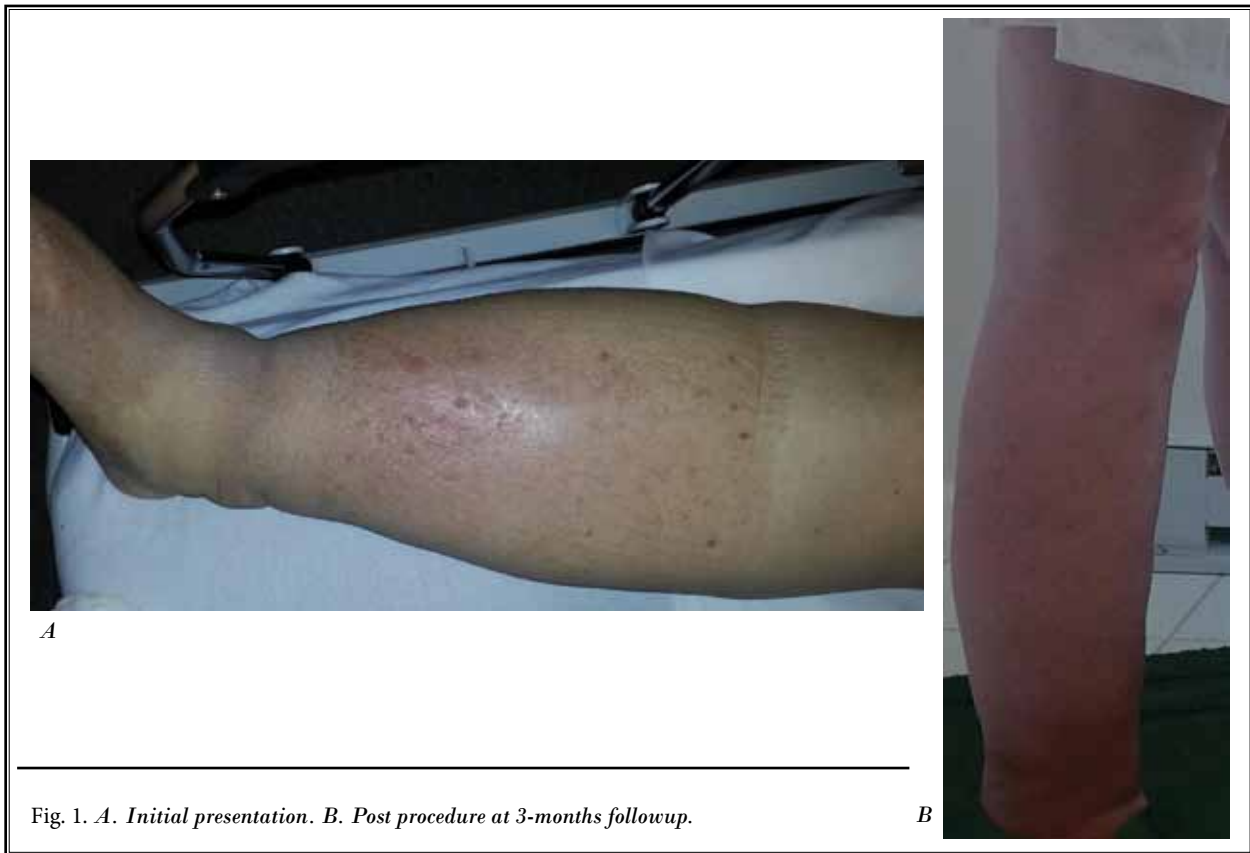

Fig. 1. *A. Initial presentation. B. Post procedure at 3-months followup.*

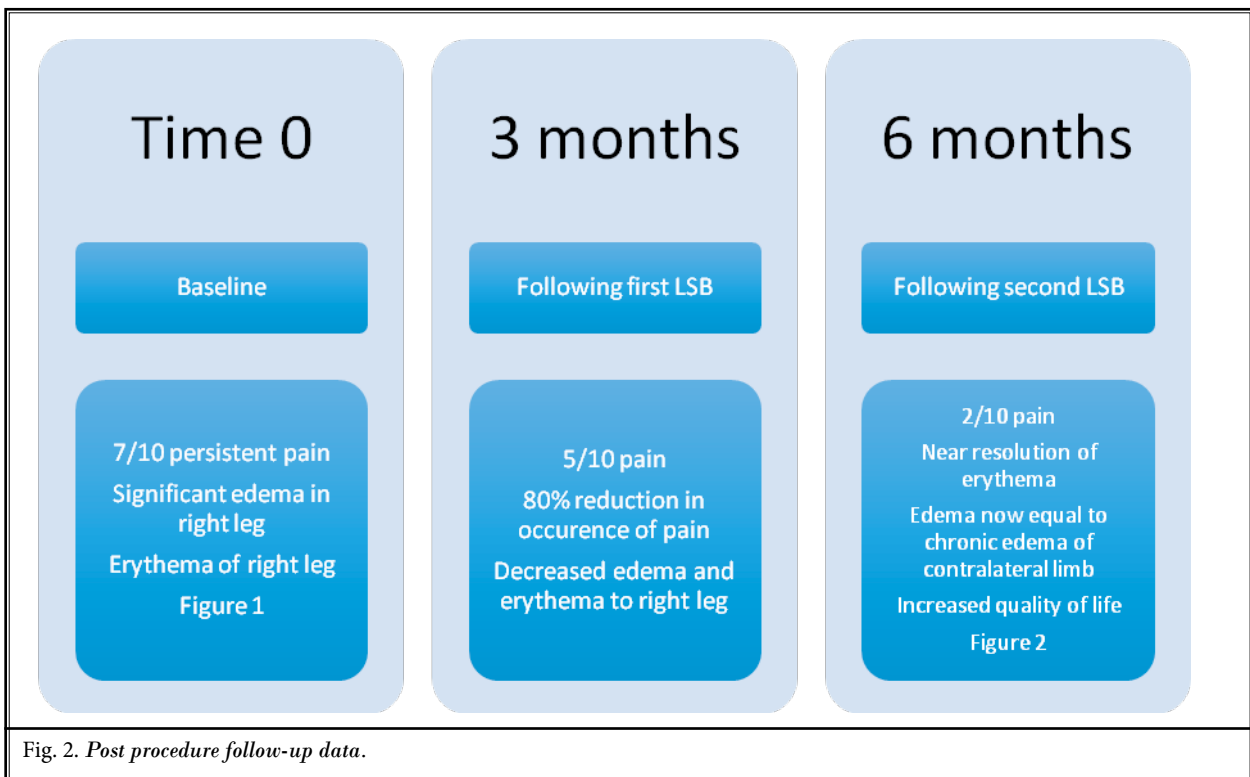


Fig. 2. *Post procedure follow-up data.*

severe achy pain, heaviness of limb, chronic irritated skin, gait abnormalities, and decreased quality of life.

When considering the pathophysiology that occurs in development of PTS, residual obstruction of the venous structures with unresolved thrombosis, as well as venous reflux and venous hypertension are regarded as the typical the aggravating factors. These pathologic changes to the vessels and increased capillary permeability lead to an increase in venous pooling and extravasation of fluid from the vessels. With chronic edema, skin changes occur including hemosiderin deposits, thickening of the skin, break down, and ulceration (1).

The sympathetic nervous system plays an important role in the mediation of peripheral blood flow. When the sympathetic response is activated, there is vasoconstriction of the venous structures, which then increases the venous pressure, decreases dilation of the vein, and increases return of blood to the heart (2,10). A LSB may provide the optimization of peripheral blood flow, as it

does in patients with complex regional pain syndrome, which can enhance circulation in the limb of PTS patients. Also reduction of venous pressures in vessels that are partially obscured by an old thrombosis may provide benefit to reducing extravasation of fluid to interstitial tissue (2). The pain relief provided by the sympathetic nerve block could also permit the patient to increase his amount and frequency of ambulation comfortably and simply allow for the natural muscular pumps in the calf to drive the residual edema out of the lower extremity.

In this case presentation, the patient found significant relief from a series of LSBs, which permitted him to return to nearly all of his previous daily activities. Though compression stocking therapy is considered the best current treatment and means of preventing PTS, other treatment options need to be investigated. A LSB has been shown to relieve the pain and associated edema and erythema with PTS and should be further studied in this patient population.

REFERENCES

1. Traves KP, Studdiford JS, Pickle S, Tully AS. Edema: Diagnosis and management. *American Family Physician* 2013; 88:1102-110B.
2. Phillips LJ, Sarkar R. Molecular characterization of post-thrombotic syndrome. *Journal of Vascular Surgery* 2007; 45:A116-A122.
3. Kahn SR. How I treat postthrombotic syndrome. *Blood* 2009; 114:4624-4631.
4. Steven D. Waldman. Chapter 164. *Pain Management*. Second Edition, Saunders, Philadelphia, PA, 2001, 1230-1236.
5. Lennard TA, Walkowski S, Singla AK, Vivian DG. *Pain Procedures in Clinical Practice*. Third Ed. Saunders, Philadelphia, PA 2011, 507-519.
6. Bouman AC, Smits JJ, Ten Cate H, Ten Cate-Hoek AJ. Markers of coagulation, fibrinolysis and inflammation in relation to post-thrombotic syndrome. *Journal of Thrombosis and Hemostasis* 2012; 10:1532-1538.
7. Kahn SR, Shapiro S, Wells PS, Rodger MA, Kovacs MJ, Anderson DR, Tagalakakis V, Houweling AH, Ducruet T, Holcroft C, Johri M, Solymoss S, Miron MJ, Yeo E, Smith R, Schulman S, Kassis J, Keaton C, Chagnon I, Wong T, Demers C, Hanmiah R, Kaatz S, Selby R, Rathbun S, Desmarais S, Opatryny L, Ortel TL, Ginsberg JS. Compression stockings to prevent post-thrombotic syndrome: A randomized placebo-controlled trial. *Lancet* 2014; 383:880-888.
8. Kolbach DN, Sandbrink MW, Hamulyak K, Neumann HA, Prins MH. Non-pharmaceutical measures for prevention of post-thrombotic syndrome. *Cochrane Database Syst Rev* 2004; CD004174.
9. Morling JR, Yeoh SE, Kolbach DN. Rutosides for treatment of post-thrombotic syndrome. *Cochrane Database Syst Rev* 2013; CD005625.
10. Breidhardt T, Irfan A, Klima T, Drexler B, Balmelli C, Arenja N, Socrates T, Ringger R, Heinisch C, Ziller R, Schifferli J, Meune C, Mueller C. Clinical summary pathophysiology of lower extremity edema in acute heart failure revisited. *The American Journal of Medicine* 2012; 125:1124.e1-1124.e8.
11. Borchers AT, Gershwin ME. Complex regional pain syndrome: A comprehensive and critical review. *Autoimmunity Reviews* 2014; 13:242-265.
12. Wilfrid Jänig. Sympathetic nervous system and inflammation: A conceptual view. In: *Autonomic Neuroscience: Basic and Clinical* Volume 182. Elsevier, Philadelphia, PA 2014, pp. 4-14.

