

Retrospective Study

Treatment of Metastatic Spinal Lesions with a Navigational Bipolar Radiofrequency Ablation Device: A Multicenter Retrospective Study

Praveen R. Anchala, MD¹, Winston D. Irving, MD¹, Travis J. Hillen, MD¹, Michael V. Friedman, MD¹, Bassem A. Georgy, MD², Douglass M. Coldwell, MD, PhD³, Nam D. Tran, MD⁴, PhD, Frank D. Vrionis, MD, PhD⁴, Allan Brook, MD⁵, and Jack W. Jennings, MD, PhD¹

From: ¹Department of Musculoskeletal Interventional Radiology Mallinckrodt Institute of Radiology, St. Louis, MO; ²Department of Musculoskeletal Interventional Radiology, University of California in San Diego, San Diego, CA; ³Department of Radiology, University of Louisville, Louisville, KY; ⁴Department of Neuro-Oncology, Moffitt Cancer Center, Tampa, FL; ⁵Neuroradiology, Montefiore Medical Center, New York, NY

Address Correspondence: Jack W Jennings, MD, PhD
Mallinckrodt Institute of Radiology
Washington University School of Medicine in St. Louis
510 South Kingshighway Blvd.
St. Louis, MO 63108
E-mail: jenningsj@mir.wustl.edu

Disclaimer: There was no external funding in the preparation of this manuscript. Conflict of interest: Dr. Jennings is on a speaker panel and a consultant for DFINE, INC. Dr. Hillen is a Lab instructor with DFINE, INC. Each author certifies that he or she, or a member of his or her immediate family, has no commercial association (i.e., consultancies, stock ownership, equity interest, patent/licensing arrangements, etc.) that might pose a conflict of interest in connection with the submitted manuscript.

Manuscript received: 09-26-2013
Revised manuscript received: 11-08-2013
Accepted for publication: 02-24-2014

Free full manuscript: www.painphysicianjournal.com

Background: Spinal metastatic lesions are a common occurrence among oncology patients and contribute to significant morbidity. Treatment options have been limited in their effectiveness and scope to this point.

Objective: This study aims to report the safety and efficacy of radiofrequency ablation (RFA) of malignant spinal lesions using a novel RFA bipolar tumor ablation system which includes a navigational electrode containing 2 active thermocouples.

Study Design: IRB approved multicenter retrospective review of patients receiving RFA as a treatment of metastatic osseous lesions between March 2012 and March 2013.

Setting: This study consists of patients from 5 large academic centers.

Method: One hundred twenty-eight metastatic lesions were identified in 92 patients who underwent a total of 96 procedures. Cement augmentation was performed when the vertebral body was at risk or had a pathological fracture. Visual analogue scale (VAS) scores were obtained preoperatively as well as postoperatively at the one week, one month, and 6 month time points. Interval change in the patients' pain medications was recorded. Postoperative imaging was used to assess tumor burden at the treated level when available.

Results: RFA was technically successful in all of the lesions without complication or thermal injury. Our study demonstrated significant ($P < 0.01$) decreases in the VAS scores at one week, one month, and 6 months postoperatively. In our largest center, 54% of our patients experienced a decrease and 30% had no change in their pain medications postoperatively. Sixty-two percent of the spinal lesions in this largest institution were located in the posterior vertebral body. Post-ablation imaging confirmed size of ablation zones consistent with that measured by the thermocouples.

Limitations: The main limitations of this study are the heterogeneous patient population, data set, and potential confounding variable of concurrent cement augmentation.

Conclusion: The STAR System is an RFA device that was safely and effectively used in the treatment of spine metastatic osseous lesions. This new device allows RFA treatment of previously untreatable lesions with resultant reduction in pain that was not controlled by systemic or radiation therapy.

Key words: Radiofrequency ablation, pain, osseous metastasis, spine, interventional oncology, oncology, pain management, tumor, vertebral augmentation

Pain Physician 2014; 17:317-327

Osseous metastatic lesions are common and have been seen in up to 80% of patients with cancer at the time of death (1), with spinal metastasis seen in approximately 50% of these patients (2). The predilection for growth of tumor cells within the bone microenvironment was recognized as far back as 1889 by Paget and has been termed the “seed and soil” hypothesis (3). While the pathogenesis remains unclear, bone metastasis remains the most prevalent cause of chronic pain within cancer patients (4).

The most frequent site of bone metastasis is the vertebrae, likely related to the high hematopoietic activity and vascularization of the spine (5). Management of these patients is challenging and traditionally involves a combination of radiation and chemotherapy in adjunct with analgesics. Surgery has remained a mainstay of treatment in patients with neurologic deficit, instability requiring stabilization, or with a longer life expectancy.

Surgical options in these patients with decreased life expectancy are often morbid and present a therapeutic dilemma. Minimally invasive procedures, including thermal ablation, are safe and effective treatments of painful osseous metastatic lesions in patients who are not surgical candidates or choose not to undergo surgery (6). Radiofrequency ablation (RFA) has been well established for the treatment of metastases to the liver and kidneys (7-9), and within the past few years has been increasingly utilized in management of osseous metastases. In the spine, this treatment has traditionally been limited to lesions within the anterior vertebral body since this location is more accessible and further away from sensitive neural elements (10). Plasma mediated RFA, the most reported method of tumor ablation within the spine, employs radiofrequency energy to excite electrolytes and create a plasma field that results in the disruption of molecular bonds at relatively low temperatures (40 to 70 degrees Celsius) (11,12). However, the resultant thermal profile and ablation zone cannot be monitored and are unpredictable, posing a potential risk of injury to nearby neural elements.

RFA uses thermal energy to destroy tissue surrounding an electrode, resulting in coagulative necrosis of tissue from high temperatures. Optimal tissue destruction occurs between 50 – 90°C (13). The radius of the ablation zone is dependent on the tissue temperature and time the tissue is maintained at that temperature. Accurate temperature measurements are critical to ensure proper tumor kill and also minimize unintended tissue destruction. In the short term, thermal destruction of

pain sensitive nerve fibers ceases transmission of pain signals. Tumor cell necrosis has also been implicated in decreasing the cytokine mediated pain pathways involving interleukins and tumor necrosis factor. RFA also delays tumor progression to the sensitive periosteum (14,15). The combination of these mechanisms leads to rapid decrease in pain that can provide long-lasting relief.

The purpose of this multicenter retrospective study was to determine the safety and efficacy of RFA using an articulating tumor ablation system that permits navigation within bone and real time monitoring of the peripheral edge of the ablation zone in spinal metastatic lesions. Additionally, vertebral augmentation was delivered via the same guiding cannula if there was already a pathological fracture, concern for fracture due to a large destructive lesion, or for potential structural instability.

METHODS

Patient Data

This retrospective analysis involved 5 institutions and included patients who received RFA as a treatment of osseous metastatic disease using the STAR tumor ablation system between March 2012 and March 2013. One hundred and twenty-eight osseous spine metastatic lesions were treated in 92 patients with or without concurrent vertebral augmentation. Two of these patients had a second RFA procedure at the same site of disease and 2 patients had a second RFA procedure for metastasis at a different site leading to a total of 96 procedures. All patients who underwent RFA with the STAR system in these 5 centers were included in the study. This retrospective analysis was approved by the Institutional Review Board.

The most common type of primary tumor was lung cancer (27%), followed by breast cancer (16%), and sarcoma (9%). Procedural outcomes including complications and pain relief were examined at each institution. All 5 institutions obtained visual analogue scale (VAS) scores on patients preoperatively and one month postoperatively. In addition to these time points, one institution obtained VAS scores one week postoperatively, and one institution obtained scores both one week and 6 months postoperatively. Table 1 summarizes the VAS scores obtained from all 5 centers.

More detailed data was available from the center which performed the largest number of cases, accounting for 34 of the 92 patients or 70 of the 128 treated

lesions (55%). This institution also included more detailed demographic and procedural data such as lesion location, ablation time, number of zones, and ablation temperatures, as well as post-procedural imaging when available. Table 2 summarizes the VAS scores obtained from this center.

Within this larger institution, 13 of the 34 patients (38%) were male and 21 (62%) were female. The population within this center ranged in age from 35 to 84 years old, and had a mean age of 60 years. Evidence of prior radiation was found in the records of 17 patients (43%) and prior chemotherapy in 24 patients (60%) as part of their treatment prior to ablation. Of the 70 spine lesions, half of these lesions were within the thoracic spine, 39% within the lumbar spine, and 11% within the sacrum. Additionally, vertebral augmentation was performed in 66 of the 70 (94%) spinal lesions to provide stabilization post-ablation or for pathological fracture. This demographic and augmentation data was not available for the other 4 institutions.

Procedure

Prior to the procedure, written informed consent was obtained after a detailed explanation of the therapy benefits, treatment alternatives, and complications. Pre-procedural planning was performed using cross-sectional imaging to determine pedicle access and the number of targeted ablations based on lesion location, size, and pre-clinical thermal distribution curves for the device. Magnetic resonance imaging (MRI) was

preferred due to better evaluation of posterior tumor extension and canal or neuroforaminal involvement.

Ninety-four of the procedures were performed under conscious sedation. The remaining 2 procedures were performed under general anesthesia due to intractable pain and inability to achieve pain control under conscious sedation. The preferred method of treatment is conscious sedation to enable monitoring of neurologic symptoms. Fluoroscopy or computed tomography (CT) was utilized for image guidance based on lesion characteristics and operator preference for safety reasons. Full sterile technique was used during the procedure including cap, mask, hand hygiene, sterile gloves, and sterile drape. RFA was performed with the STAR Tumor Ablation System (comprised of the SpineSTAR ablation instrument and the MetaSTAR generator, DFINE, San Jose, CA). The SpineSTAR is an articulating, navigational and bipolar radiofrequency electrode containing a pair of thermocouples positioned along the length of the electrode, 10 and 15 mm from the center of the ablation zone. There is a 3:2 length to width aspect ratio ablation zone with the maximum ablation zone of 3 cm by 2 cm when the proximal thermocouple reaches 50 degrees Celsius. The MetaSTAR generator continuously displays the 2 thermocouple readings permitting real time monitoring of the peripheral edge of the ablation zone (Fig. 1).

All vertebral lesions were targeted from a transpedicular/parapedicular approach using the provided 10-gauge co-axial working cannula. The working can-

Table 1. *Visual Analogue Scale (VAS) Scores at all centers.*

	Average	Standard Deviation	P Value ¹	Median	Number (n)
Pre-procedural	7.51	2.46		8.00	92
1 week	1.73	2.28	< 0.0001	1.00	56
1 month	2.25	2.44	< 0.0001	1.25	83
6 months	1.75	2.62	0.009	0.00	9

¹Based on matched two-tailed Student t test.

Table 2. *Visual Analogue Scale (VAS) Scores at our largest institution.*

	Average	Standard Deviation	P Value ¹	Median	Number (n)
Pre-procedural	7.35	2.90		8.00	34
1 week	2.47	2.42	< 0.0001	2.00	32
1 month	2.80	2.73	< 0.0001	2.25	29
6 months	1.75	2.62	0.009	0.00	9

¹Based on matched two-tailed Student t test.

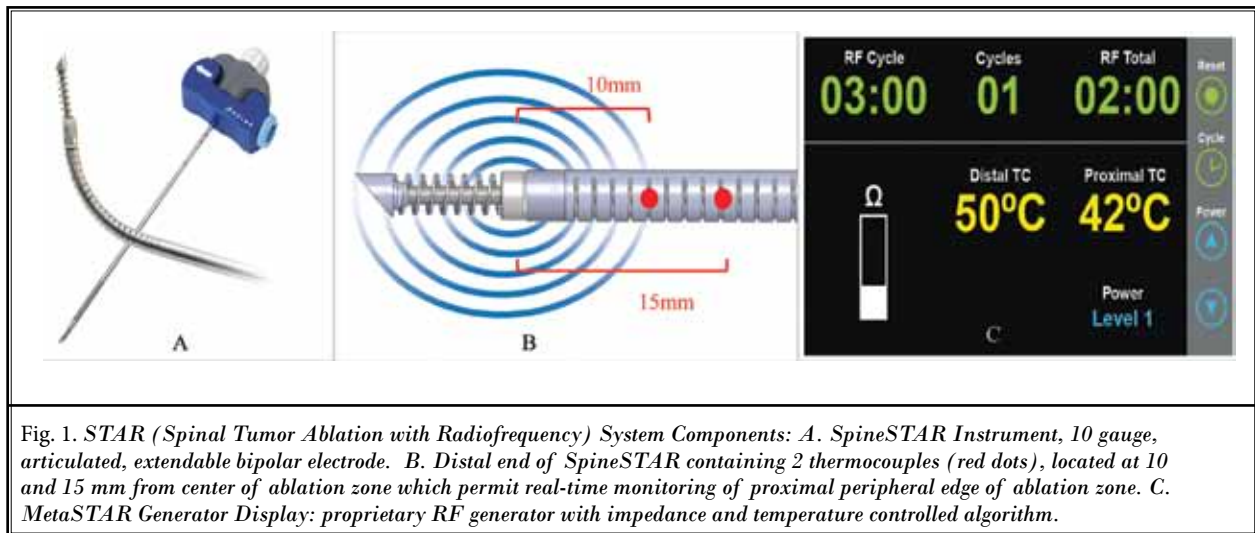


Fig. 1. STAR (Spinal Tumor Ablation with Radiofrequency) System Components: A. SpineSTAR Instrument, 10 gauge, articulated, extendable bipolar electrode. B. Distal end of SpineSTAR containing 2 thermocouples (red dots), located at 10 and 15 mm from center of ablation zone which permit real-time monitoring of proximal peripheral edge of ablation zone. C. MetaSTAR Generator Display: proprietary RF generator with impedance and temperature controlled algorithm.

nula was advanced into the portion of the vertebral body necessary for access to the lesion, and then the articulating midline osteotome was used to make desired channels prior to ablation. The SpineSTAR electrode was then deployed to the desired location.

A variable number of ablation zones, temperatures, and ablation times were utilized based on size, shape, and location of lesion. These variables were recorded for each procedure. In cases in which there was concern for adjacent neural damage, special neural thermal protection techniques, described by Buy et al (16), involving epidural or neuroforaminal thermocouples and injection of CO₂ or cooled 5% dextrose water were used. Following ablation, cement augmentation (StabilIT Vertebral Augmentation System, DFINE Inc, San Jose, CA) was performed in cases where there was a pathologic fracture or vertebral instability was of concern due to a large destructive lesion via the same working cannula.

RESULTS

RFA was technically successful in all of the 128 osseous metastatic lesions treated without complications or thermal injury. The VAS scores obtained from all centers as well as our largest center are summarized in Tables 1 and 2, respectively. The postoperative VAS scores at the one week, one month, and 6-month time points were statistically significant using a paired two-tailed Student t test.

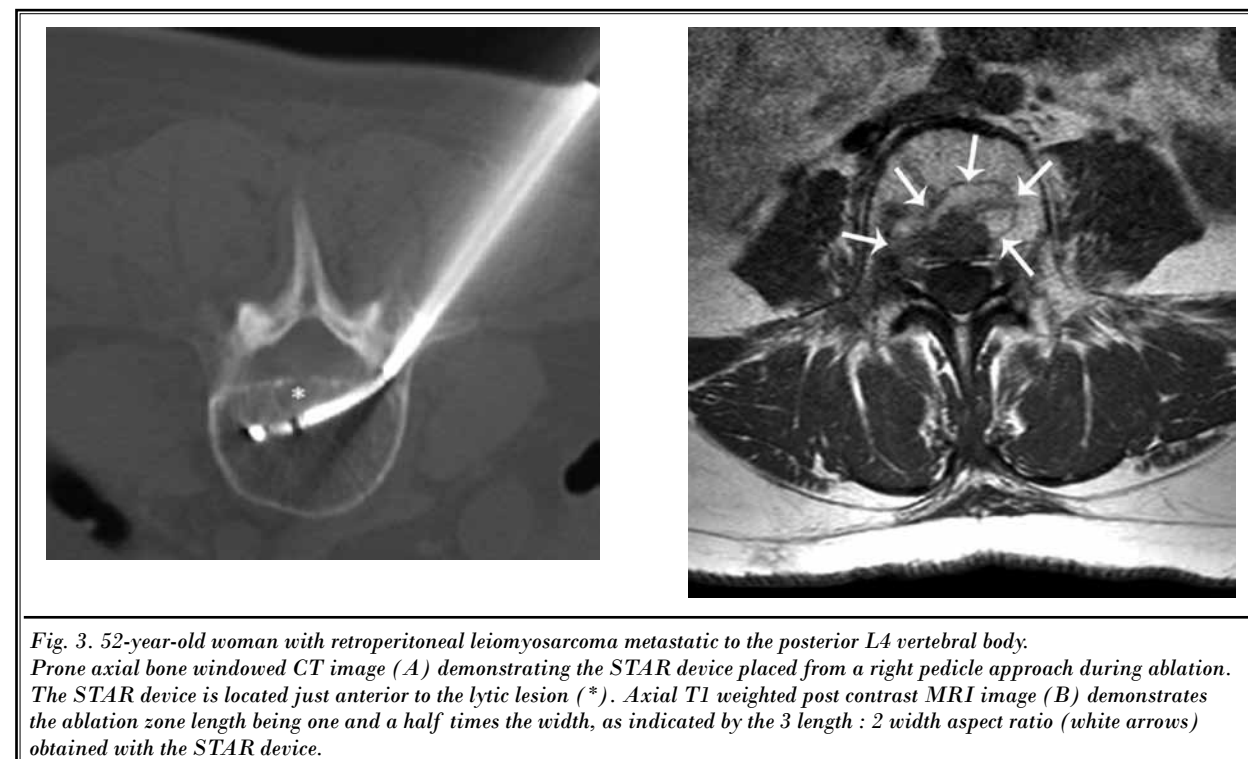
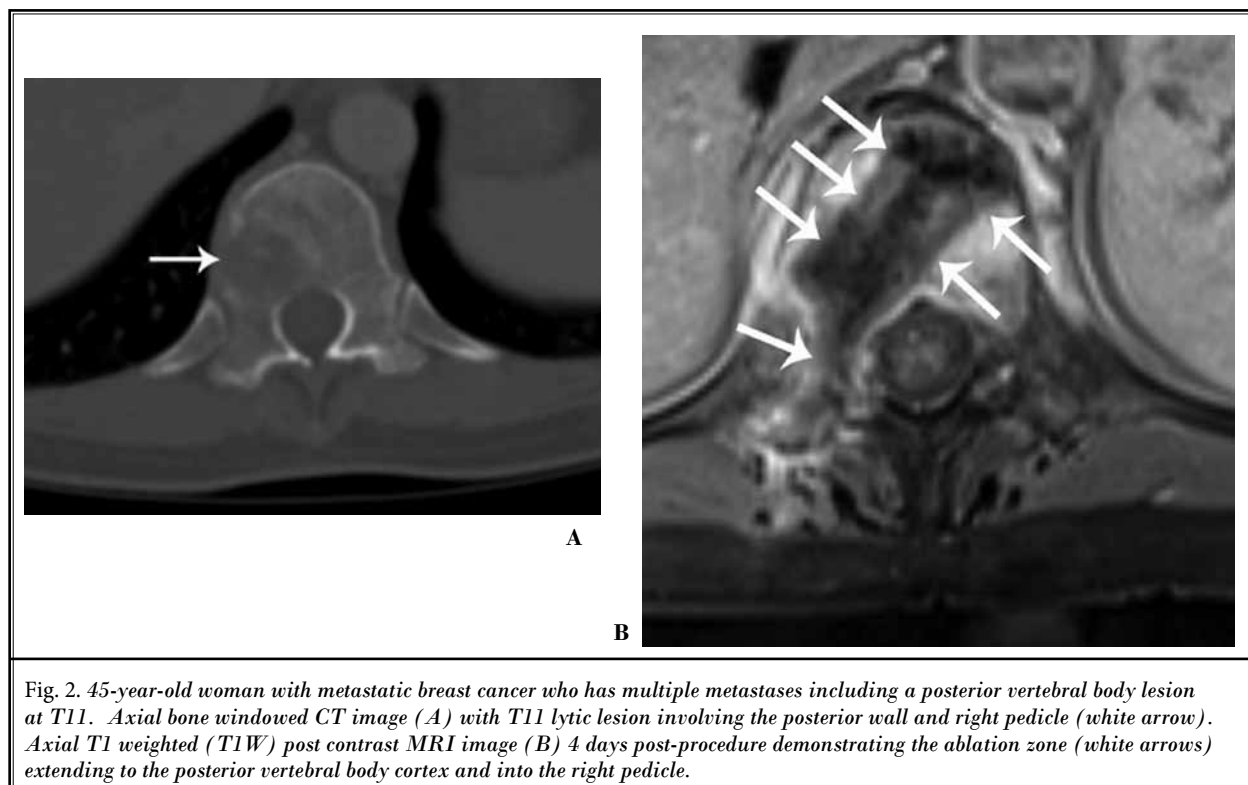
In the largest center, which comprised 34 of the 92 treated patients, detailed procedural information was obtained. The ablation time at each treated lesion ranged from 55 to 653 seconds, with an average

ablation time of 361 seconds. Each lesion was treated with an average of 4.3 overlapping ablation zones. The average temperature recorded at the proximal thermocouple on the electrode (representing the temperature reading at the most peripheral aspect of the ablation zone) was 50 degrees Celsius and the average temperature recorded at the distal thermocouple was 73 degrees Celsius. Twenty-one (62%) of the 34 patients had treatment of lesions located in the posterior vertebral body (Fig. 2).

In addition, within this largest institution, change in pain medication usage after the ablation was compared to the preoperative information at this institution. A decrease in pain medications was seen in 54% of patients after treatment, with 30% reporting no change in medication usage, and 16% saying their pain regimen had increased.

Cement augmentation was successfully performed in 92 of the 96 treated lesions through the same working cannula used for the RFA. Adequate fill was seen in all cases. Cement extravasation was noted in 2 patients, one into a draining vein and one into a sacral neural foramen. Both extravasations were asymptomatic. Two of the 4 patients not receiving vertebral augmentation went on to fracture and subsequently had cement augmentation at 3 months and one year.

Some patients underwent post-procedural MRI which demonstrated discrete ablation zones with a length to width aspect ratio of 3:2 consistent in size with that expected based on the temperatures obtained by the thermocouples during the ablation (Fig. 3). Thirteen of the 34 patients at the largest center had follow-up postoperative imaging, 10 of which demon-



strated stable or improved metastatic disease at the level of treatment after an average of 92 days. Three patients demonstrated progression at the treated level after an average of 82 days. Two of these patients underwent a second RFA with the STAR ablation system at the same levels. The third patient demonstrated diffusely increased metastatic progression after just 16 days and underwent systemic treatment.

Discussion

Bone is the most common site of metastatic disease after lung and liver (17) and one of the most common causes of chronic pain among cancer patients (18). Approximately two-thirds of cancer patients will develop bone metastases and it is estimated that over 10% of patients with cancer will develop symptomatic spinal metastases (19). More than 50% of patients with spinal metastases have multiple levels involved (20); because of this, treating osseous metastatic disease, particularly within the spine, is an important aspect of therapy and palliation among patients with advanced malignancy (21,22). Many patients have a minimal or only brief response to traditional therapies and onset of pain relief can take months (23). Additionally, invasive surgical procedures are usually not warranted in these patient populations due to short expected lifespan and comorbidities. RFA with or without cement augmentation does not hinder or delay the use of adjuvant therapies (24).

The first reported use of RFA in bone was in the treatment of osteoid osteoma by Rosenthal et al in 1992 (25), and since then has been used for treatment of osseous metastatic disease (10,26-29). The procedure's rapid onset of pain relief and low rates of morbidity make it an optimal technique in managing these lesions.

In a multicenter trial of 62 patients, Goetz et al noted pain relief in nearly 80% of patients treated with RFA (26). Callstrom et al demonstrated RFA to be an effective treatment of metastatic pain in approximately 83% of patients who failed chemoradiation therapy (26,27). Thanos et al also found RFA to provide significant pain relief in patients who failed standard treatment with pain relief achieved between 4 days and one week after therapy in 90% – 100% of patients (27,28). In the largest center of this study, 43% of patients were documented to have failed radiation while 60% failed chemotherapy as their pre-ablation treatment. The actual number of patients who failed these treatments is likely even higher as there was incomplete documen-

tation of these results within the oncology medical records. In all of these referenced cohorts and trials, spine lesions were actually a small percentage of the total lesions treated.

The use of RFA in the spine has traditionally been limited to the anterior vertebral body due to the close proximity of tumor to neural tissues and limited treatment angle derived from the trans- or extra-pedicular approach of conventional RFA systems (28). Over half of the lesions treated in our largest center were located in the posterior vertebral body, lesions that were previously thought to be untreatable with RFA. Treatment of lesions located more posteriorly or with posterior cortical bone destruction was contraindicated due to the close relationship of the spinal cord and nerve roots (29). The posterior wall lesions were easily accessed with the SpineSTAR articulating electrode which also provided the operator with the additional advantage of real time monitoring of the temperature at the peripheral edge of the ablation zone (Fig. 4).

The addition of cement posteriorly maintains a theoretical risk of spinal canal compromise, and should be done in experienced hands with caution. The posterior column is the strongest portion of the spine due to the large cortical margins and supporting posterior elements (30). The decreased necessity of adding cement to strengthen the column is a benefit. Therefore the STAR ablation system has the ability to treat these lesions which were previously deemed unsafe.

The ability to create multiple ablation zones through the same introducer needle using the navigational electrode resulted in an average of 4.3 ablation zones within each metastatic osseous lesion treated in this study allowing for more complete tumor ablation (Fig. 4).

In this study, statistically significant pain relief was seen among patients at the one week, one month, and 6 month post ablation time points. Many studies have reported significant and enduring reduction in pain control of bony metastasis with improvement in overall quality of life after RFA (26-29,31). Long-term pain relief has been reported as far out as one year in many cases (28,31). Additionally, treatment with RFA has been shown to decrease the use of analgesic medications postoperatively (26-28). Hoffman et al saw this decline in 70% of their treated patients (4). A decrease in pain medication was seen in 54% of the patients in this cohort.

Ninety-six percent of patients received vertebral augmentation following the ablation. Pain relief from

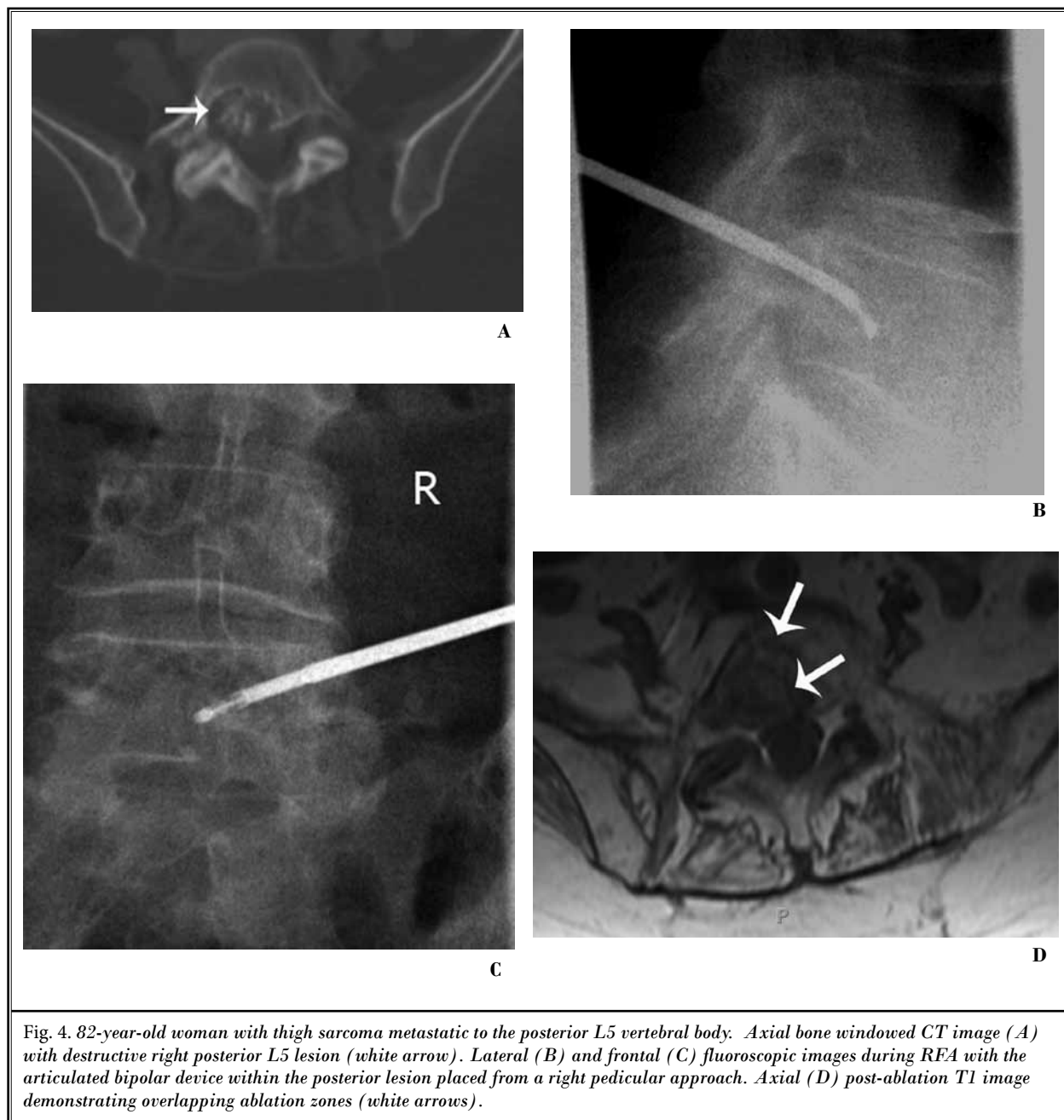


Fig. 4. 82-year-old woman with thigh sarcoma metastatic to the posterior L5 vertebral body. Axial bone windowed CT image (A) with destructive right posterior L5 lesion (white arrow). Lateral (B) and frontal (C) fluoroscopic images during RFA with the articulated bipolar device within the posterior lesion placed from a right pedicular approach. Axial (D) post-ablation T1 image demonstrating overlapping ablation zones (white arrows).

cementoplasty has been reported in the literature to range from 47% to 87% (32). Prior destruction of tumor with RFA has been linked to a more complete fill with cement providing additional structural support (12,33,34). A synergistic response between RFA and cementoplasty has been reported which can provide pain relief for an average of 7.3 months (35). The combination of cement augmentation following RFA using

the STAR tumor ablation system was shown to be both safe and efficient, allowing the patient to undergo both treatments using the same working cannula and decreasing the total sedation and procedural time.

There are several limitations to this retrospective study. While a prospective study design is preferred, observational studies are the mainstay for initial procedure reports.

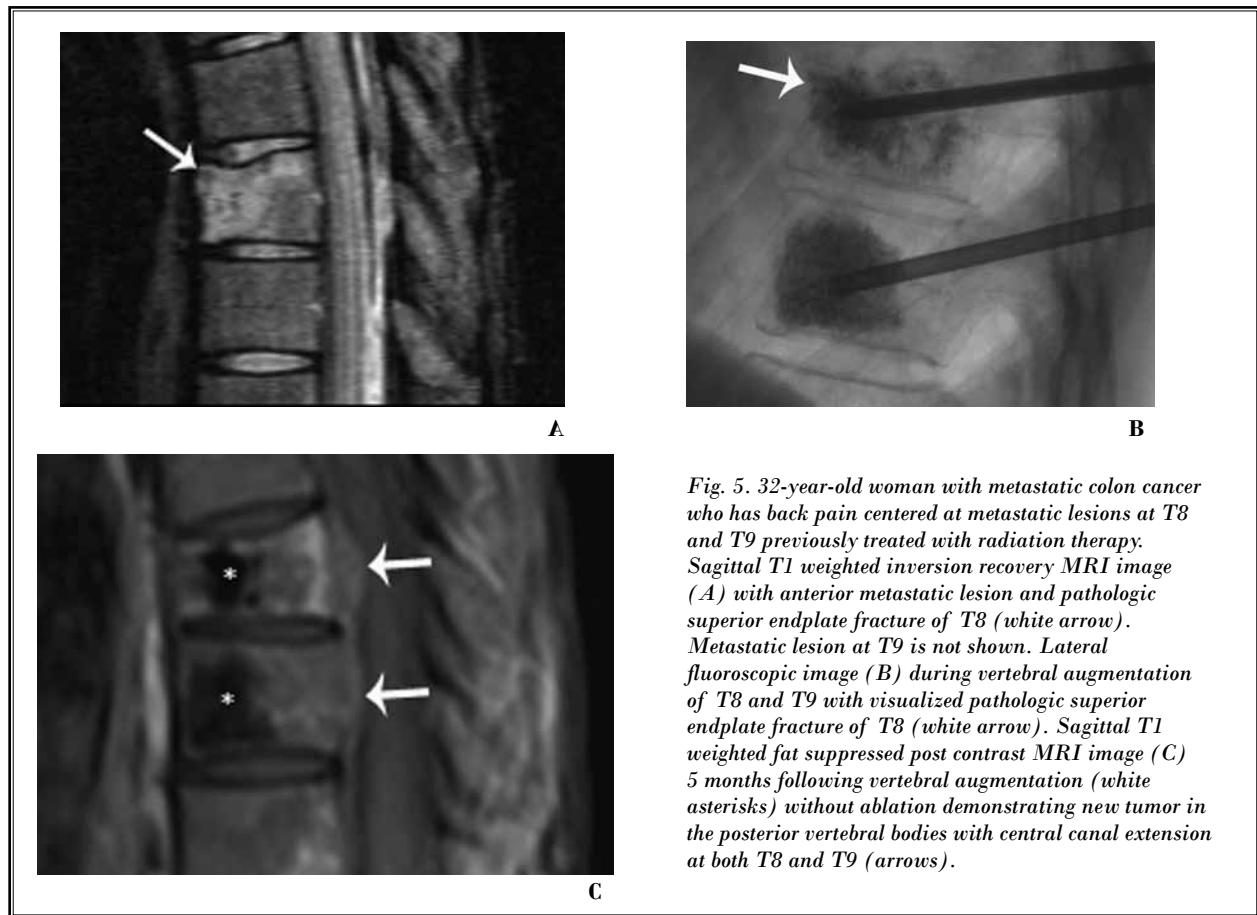


Fig. 5. 32-year-old woman with metastatic colon cancer who has back pain centered at metastatic lesions at T8 and T9 previously treated with radiation therapy. Sagittal T1 weighted inversion recovery MRI image (A) with anterior metastatic lesion and pathologic superior endplate fracture of T8 (white arrow). Metastatic lesion at T9 is not shown. Lateral fluoroscopic image (B) during vertebral augmentation of T8 and T9 with visualized pathologic superior endplate fracture of T8 (white arrow). Sagittal T1 weighted fat suppressed post contrast MRI image (C) 5 months following vertebral augmentation (white asterisks) without ablation demonstrating new tumor in the posterior vertebral bodies with central canal extension at both T8 and T9 (arrows).

The breadth of demographic and treatment data provided by each treatment center varied widely. Detailed data was obtained in the center which treated the most patients, but not available from the other 4 centers. While the calculated *P*-values were statistically significant within the 70 lesions treated by this one center, providing some support for the ability to generalize the data from this center, a more cohesive data set from all centers would have been beneficial. Data collected from each center was heterogeneous. Six month postoperative VAS scores were only recorded at one institution, and could only be obtained in 9 patients due to patient death from metastatic disease or loss to follow-up. By the same regard, VAS scores were not obtained at every time point for each patient even within the same institution.

Additionally, the patient population was very heterogeneous with a variety of primary tumor types and degree of metastatic involvement. Due to the innate severity of metastatic disease, many patients had only a few months to live allowing for a wide range of follow-up data.

The majority of the ablations were followed by cement augmentation which confounds the post-procedural pain evaluation as to the contributing factor of pain reduction. Most lesions had pathologic fractures or were at risk of fracture and vertebral augmentation was used for stabilization. It has well been accepted that vertebral augmentation is a therapeutic option for pain palliation and stabilization of pathologic fractures of the spine (36). However, with vertebral augmentation alone and especially in those who have failed or exhausted radiation therapy, there can be progression of disease in the posterior vertebral body where cement is typically absent with subsequent posterior wall destruction and canal extension (Fig. 5). In this series of patients with posterior wall involvement and posterior RFA, there were cases where posterior wall extension was halted following RFA while spinal tumors in other vertebra progressed during continued systemic therapy (Fig. 6). In the cases ($n = 2$) in which tumor progression was observed, the STAR procedure permitted additional

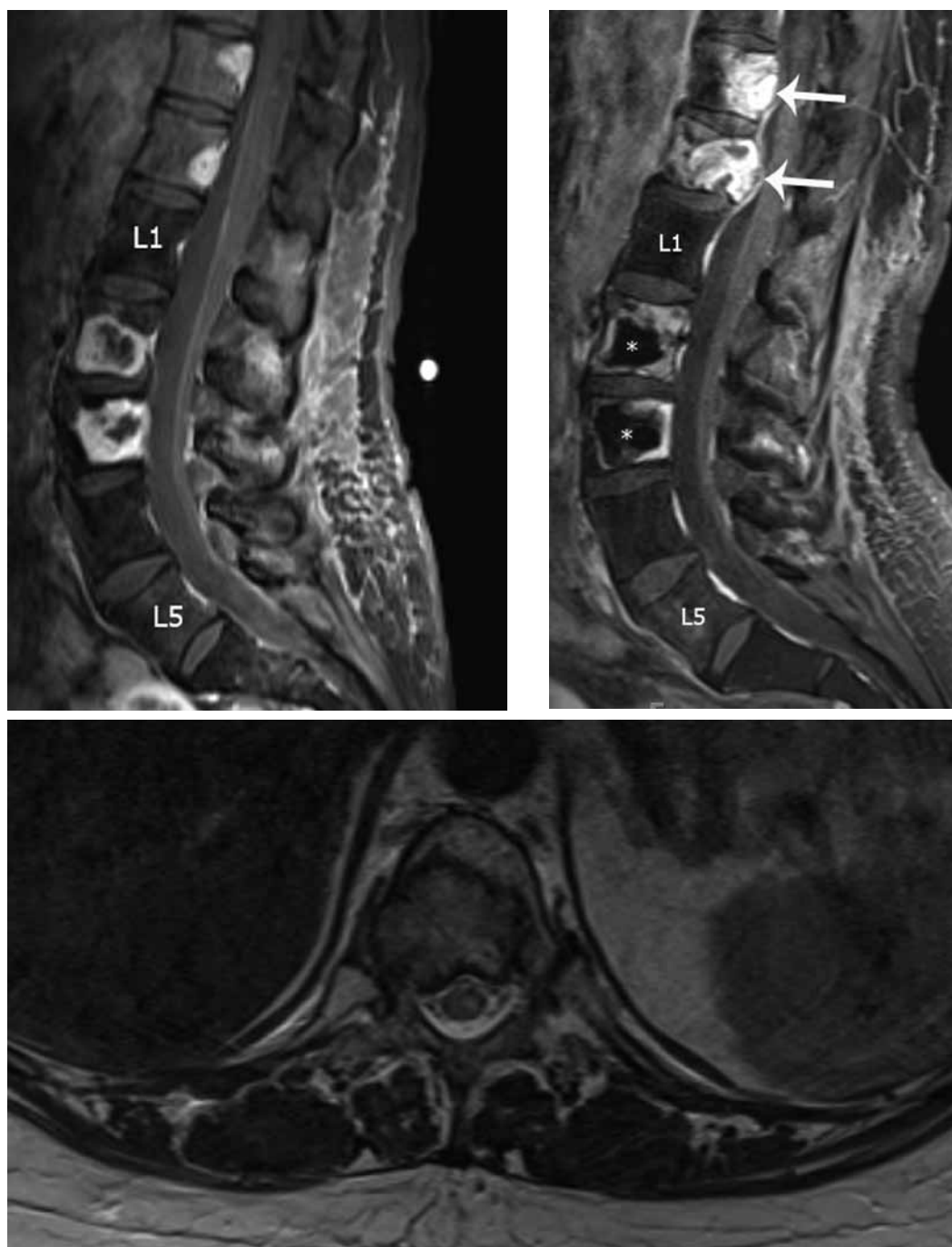


Fig. 6. 55-year-old woman who has metastatic renal cell cancer with back pain centered at metastatic lesions and pathologic fractures of L2 and L3 treated previously with radiation therapy. Sagittal T1 weighted post contrast MRI image (A) demonstrating large enhancing lesions at L2 and L3 and smaller enhancing lesions at T11 and T12 prior to ablation. L1 and L5 are labeled for counting purposes. Sagittal T1 weighted post contrast MRI image (B) 6 months post L2 and L3 ablation with cement augmentation demonstrating a lack of tumor progression within the treated levels, including posteriorly where no cement was administered (white asterisks), while the adjacent T11 and T12 non-ablated lesions (white arrows) markedly increased in size while on systemic therapy. Axial T2 weighted MRI image (C) demonstrates progression of the T11 tumor into the spinal canal.

treatment without cumulative toxicity associated with other adjunctive therapies.

CONCLUSION

In conclusion, this retrospective study demonstrates both the safety and efficacy of the STAR Tumor Ablation System for treatment of painful metastatic osseous lesions. There were reproducible, predictable ablation zones with real time monitoring of the peripheral edge of the ablation zone with the use of the 2 built-in thermocouples. Post-ablation MRI and PET/CT confirmed size of ablation with necrosis of the tar-

geted tissue. The ablation zone was consistent in size with that measured by the thermocouples and similar in morphology to that extrapolated from thermal distribution curves. The articulating electrode provided easy access to posterior vertebral body lesions that were previously difficult to access with other ablation devices. Follow-up imaging demonstrated no further growth or canal extension of treated tumor. In many cases, this technique allowed for access and treatment of individual lesions not accessible by conventional RFA devices and/or controlled by systemic chemotherapy or radiation therapy.

REFERENCES

- van der Horst G, van der Pluijm G. *Clinical and Preclinical Imaging in Osseous Metastatic Disease. Primer on the Metabolic Bone Diseases and Disorders of Mineral Metabolism*. Eighth Edition (ed C. J. Rosen), John Wiley & Sons, Inc., Ames, USA. 2013, pp 677-685.
- Harel R, Angelov L. Spine metastases: Current treatments and future directions. *European Journal of Cancer* 2010; 46:2696-2707.
- Paget S. The distribution of secondary growths in cancer of the breast. *Lancet* 1889; 1:571.
- Hoffmann RT, Jakobs TF, Trumm C, Weber C, Helmberger TK, Reiser MF. Radiofrequency ablation in combination with osteoplasty in the treatment of painful metastatic bone disease. *J Vasc Interv Radiol* 2008; 19:419-425.
- Husband DJ. Malignant spinal cord compression: Prospective study of delays in referral and treatment. *BMJ* 1998; 317:18-21.
- Kurup AN, Callstrom MR. Image-guided percutaneous ablation of bone and soft tissue tumors. *Semin Intervent Radiol* 2010; 27:276-284.
- Jakobs TF, Hoffmann RT, Trumm C, Reiser MF, Helmberger TK. Radiofrequency ablation of colorectal liver metastases: Mid-term results in 68 patients. *Anticancer Res* 2006; 26:671-680.
- Lencioni R, Della Pina C, Bartolozzi C. Percutaneous image-guided radiofrequency ablation in the therapeutic management of hepatocellular carcinoma. *Abdom Imaging* 2005; 30:401-408.
- Hoffmann RT, Jakobs TF, Trumm C, Helmberger TK, Reiser MF. RFA of renal cell carcinoma in a solitary kidney. *Abdom Imaging* 2008; 33:230-236.
- Dupuy DE, Hong R, Oliver B, Goldberg SN. Radiofrequency ablation of spinal tumors: Temperature distribution in the spinal canal. *Am J Roentgenol* 2000; 175:1263-1266.
- Georgy BA. Bone cement deposition patterns with plasma-mediated radiofrequency ablation and cement augmentation for advanced metastatic spine lesions. *Am J Neuroradiol* 2009; 30:1197-1202.
- Georgy BA, Wong W. Plasma-mediated radiofrequency ablation assisted percutaneous cement injection for treating advanced malignant vertebral compression fractures. *Am J Neuroradiol* 2007; 28:700-705.
- Brace CL. Radiofrequency and microwave ablation of the liver, lung, kidney, and bone: What are the differences? *Current Problems in Diagnostic Radiology* 2009; 38:135-143.
- Mannion RJ, Woolf CJ. Pain mechanisms and management: A central perspective. *Clin J Pain* 2000; 16:S144-S156.
- Cleeland CS, Gonin R, Hatfield AK, Edmonson JH, Blum RH, Stewart JA, Pandya KJ. Pain and its treatment in outpatients with metastatic cancer. *N Engl J Med* 1994; 330:592-596.
- Buy X, Tok CH, Szwarc D, Bierry G, Gangi A. Thermal protection during percutaneous thermal ablation procedures: Interest of carbon dioxide dissection and temperature monitoring. *Cardiovasc Intervent Radiol* 2009; 32:529-534.
- Sze WM, Shelley MD, Held I, Wilt TJ, Mason MD. Palliation of metastatic bone pain: Single fraction versus multifraction radiotherapy—a systematic review of randomized trials. *Clinical Oncology* 2003; 15:345-352.
- Maccauro G, Spinelli MS, Mauro S, Perisano C, Graci C, Rosa MA. Physiopathology of spine metastasis. *Int J Surg Oncol* 2011; 107969.
- Carrafiello G, Laganà D, Pellegrino C, Fontana F, Mangini M, Nicotera P, Petullà M, Bracchi E, Genovese E, Cuffari S, Fugazzola C. Percutaneous imaging-guided ablation therapies in the treatment of symptomatic bone metastases. *La Radiologia Medica* 2009; 114:608-625.
- Togawa D, Lewandrowsky KU. *The pathophysiology of spinal metastases. Cancer in the Spine*. Current Clinical Oncology, Humana Press, Totowa, NJ. 2006; 17-23.
- Lutz S, Berk L, Chang E, Chow E, Hahn C, Hoskin P, Howell D, Konski A, Kachnic L, Lo S, Sahgal A, Silverman L, von Gunten C, Mendel E, Vassil A, Bruner DW, Hartsell W; American Society for Radiation Oncology (ASTRO). Palliative radiotherapy for bone metastases: An ASTRO evidence-based guideline. *International Journal of Radiation Oncology Physics* 2011; 79:965-976.
- Ryu S, Jin R, Jin JY, Chen Q, Rock J, Anderson J, Movsas B. Pain control by image-guided radiosurgery for solitary spinal metastasis. *Journal of Pain and Symptom Management* 2008; 35:292-298.
- Valesin Filho ES, de Abreu LC, Lima GH, de Cubero DI, Ueno FH, Figueiredo GS, Valenti VE, Monteiro CB, Wajnsztein R, Fujiki EN, Neto MR, Rodrigues LM. Pain and quality of life in patients undergoing radiotherapy for spinal metastatic disease treatment. *Int Arch Med* 2013; 6:6

24. Dupuy DE, Liu D, Hartfeil D, Hanna L, Blume JD, Ahrar K, Lopez R, Safran H, DiPetrillo T. Percutaneous radiofrequency ablation of painful osseous metastases. *Cancer* 2010; 116:989-997.
25. Rosenthal DI, Alexander A, Rosenberg AE, Springfield D. Ablation of osteoid osteomas with a percutaneously placed electrode: A new procedure. *Radiology* 1992; 183:29-33.
26. Goetz MP, Callstrom MR, Charboneau JW, Farrell MA, Maus TP, Welch TJ, Wong GY, Sloan JA, Novotny PJ, Petersen IA, Beres RA, Regge D, Capanna R, Saker MB, Grönemeyer DH, Gevargez A, Ahrar K, Choti MA, de Baere TJ, Rubin J. Percutaneous image-guided radiofrequency ablation of painful metastases involving bone: A multicenter study. *J Clin Oncol* 2004; 22:300-306.
27. Callstrom MR, Charboneau JW, Goetz MP, Rubin J, Wong GY, Sloan JA, Novotny PJ, Lewis BD, Welch TJ, Farrell MA, Maus TP, Lee RA, Reading CC, Petersen IA, Pickett DD. Painful metastases involving bone: Feasibility of percutaneous CT- and US-guided radiofrequency ablation. *Radiology* 2002; 224:87-97.
28. Thanos L, Mylona S, Galani P, Tzavoulis D, Kalioras V, Tanteles S, Pomoni M. Radiofrequency ablation of osseous metastases for the palliation of pain. *Skeletal Radiol* 2008; 37:189-194.
29. Buy X, Basile A, Bierry G, Cupelli J, Gangi A. Saline-infused bipolar radiofrequency ablation of high-risk spinal and paraspinal neoplasms. *Am J Roentgenol* 2006; 186:322-326.
30. Denis F. The three column spine and its significance in the classification of acute thoracolumbar spinal injuries. *Spine* 1983; 8:817-831.
31. Belfiore G, Tedeschi E, Ronza FM, Belfiore MP, Della Volpe T, Zeppetella G, Rotondo A. Radiofrequency ablation of bone metastases induces long-lasting palliation in patients with untreatable cancer. *Singapore Med J* 2008; 49:565-570.
32. Chew C, Craig L, Edwards R, Moss J, O'Dwyer PJ. Safety and efficacy of percutaneous vertebroplasty in malignancy: A systematic review. *Clin Radiol* 2011; 66:63-72.
33. Munk PL, Rashid F, Heran MK, Papirny M, Liu DM, Malfair D, Badii M, Clarkson PW. Combined cementoplasty and radiofrequency ablation in the treatment of painful neoplastic lesions of bone. *J Vasc and Intervent Radiol* 2009; 20: 903-911.
34. Schaefer O, Lohrmann C, Herling M, Uhrmeister P, Langer M. Combined radiofrequency thermal ablation and percutaneous cementoplasty treatment of a pathologic fracture. *J Vasc Interv Radiol* 2002; 13:1047-1050.
35. Toyota N, Naito A, Kakizawa H, Hieda M, Hirai N, Tachikake T, Kimura T, Fukuda H, Ito K. Radiofrequency ablation therapy combined with cementoplasty for painful bone metastases: Initial experience. *Cardiovasc Intervent Radiol* 2005; 28:578-583.
36. Berenson J, Pflugmacher R, Jarzem P, Zonder J, Schechtman K, Tillman JB, Bastian L, Ashraf T, Vrionis F; Cancer Patient Fracture Evaluation (CAFE) Investigators. Balloon kyphoplasty versus non-surgical fracture management for treatment of painful vertebral body compression fractures in patients with cancer: A multicentre, randomised controlled trial. *Lancet Oncol* 2011; 12:225-235.

