

Case Report

Greater Trochanteric Pain Syndrome Due to Tumoral Calcinosis in a Patient with Chronic Kidney Disease

Dongjin Baek, MD¹, Sang Eun Lee, MD², Woo-Jin Kim, MD³, Sangyoon Jeon, MD², Kihwa Lee, MD², Jaewook Jung, MD², Hyunchul Joo, MD², Jaehong Park, MD², Yonghan Kim, MD², and Young-gyun Choi, MD²

From: ¹Department of Anesthesiology and Pain Medicine, Seoul Paik Hospital, Inje University, Seoul; ²Department of Anesthesiology and Pain Medicine, Haeundae Paik Hospital, Inje University, Busan; ³Department of Rehabilitation Medicine, Haeundae Paik Hospital, Inje University, Busan

Address Correspondence:
Sang Eun Lee, MD
Department of Anesthesiology and Pain Medicine, Haeundae Paik Hospital, Inje University, 875, Haeun-daero, Haeundae-gu, Busan, 612-896, Korea
E-mail:
painlse@gmail.com

Disclaimer: There was no external funding in the preparation of this manuscript. Conflict of interest: Each author certifies that he or she, or a member of his or her immediate family, has no commercial association (i.e., consultancies, stock ownership, equity interest, patent/licensing arrangements, etc.) that might pose a conflict of interest in connection with the submitted manuscript.

Manuscript received: 03-25-2014
Accepted for publication: 04-28-2014

Free full manuscript:
www.painphysicianjournal.com

Tumoral calcinosis is a rare syndrome characterized by massive subcutaneous soft tissue deposits of calcium phosphate near the large joints. It is more prevalent in patients with chronic kidney disease undergoing dialysis.

A 57-year-old woman was referred to our pain clinic with the complaint of severe pain in the left buttock and lateral hip. The patient had been suffering from chronic kidney disease for 10 years and had been undergoing peritoneal dialysis over the past 5 years. The patient's symptom was initially suspected to be of lumbar origin at the L5 level and a left L5 transforaminal epidural block was performed, but without success. Re-evaluation of the physical examination revealed severe tenderness over the left greater trochanter and piriformis muscle. On ultrasonographic evaluation, multiple mass-like lesions in the left buttock were observed. About 30 mL of fluid was aspirated from the cystic lesions, followed by 30 mL mixture of 0.08% levobupivacaine and triamcinolone 40 mg injected into the bursa under ultrasound guidance, which brought pain relief. Trochanteric bursitis was thought of as the cause of the symptoms. The patient was diagnosed with tumoral calcinosis based on the past medical history, simple plain radiographs, and hip magnetic resonance imaging (MRI).

We diagnosed a case of greater trochanteric pain syndrome due to tumoral calcinosis related to chronic kidney disease in a patient whose symptoms had initially been considered to be radiating leg pain caused by lumbar spinal disease. We report our experience of symptomatic improvement following the repeated ultrasound-guided aspiration of calcific fluid and the injection of a mixture of local anesthetic and steroid.

Key words: Trochanteric bursitis, greater trochanteric pain syndrome, tumoral calcinosis

Pain Physician 2014; 17:E775-E782

Tumoral calcinosis is an uncommon entity first described in 1943 by Inclan (1). The syndrome is characterized by the presence of tumor-like calcified masses adjacent to large joints including the hip, shoulder, and elbow (2). Because tumoral calcinosis is a rare, unusual, and unknown etiology, the condition is difficult to diagnose (3). It is observed not infrequently in patients with chronic kidney disease (CKD) and hyperparathyroidism who are undergoing dialysis (4). Most patients present with lumps adjacent to large joints. Tumoral calcinosis is ordinarily painless

and asymptomatic (5). Greater trochanteric pain syndrome (GTPS) is a term used to describe chronic pain overlying the lateral aspect of the hip (6). The main symptom of GTPS is persistent pain in the lateral hip and buttock radiating along the lateral aspect of the thigh to the knee and occasionally below the knee (7). Little is known about GTPS combined with tumoral calcinosis. We describe a case of a patient diagnosed with GTPS due to tumoral calcinosis, following the initial assumption of the patient's symptoms to be spinal in origin.

CASE REPORT

A 57-year-old woman was referred to our pain clinic with the complaint of severe pain in the left buttock and lateral hip. The patient experienced pain radiating along the lateral aspect of the thigh to the lateral ankle. Although the back pain and bilateral lower limb pain had begun one year earlier, the pain intensity had aggressively increased to a score of 90 on the visual analogue scale (VAS; 0 = no pain to 100 = worst pain imaginable) during the past week, and the patient was experiencing walking difficulty. The patient had been suffering from CKD for 10 years and had been undergoing peritoneal dialysis over the past 5 years. She had also been diagnosed with secondary hyperparathyroidism the previous month and had undergone parathyroidectomy.

On laboratory testing, the white blood cell count (WBC), erythrocyte sedimentation rate (ESR), and C-reactive protein (CRP) were in the normal range. Although the values of phosphate and parathyroid hormone (PTH) had been elevated one month earlier, serum levels of calcium, phosphate, and PTH were within the normal range following parathyroidectomy. The secondary hyperparathyroidism was demonstrated by consecutive laboratory tests. On physical examination, the straight leg raising test was positive on the left side while Patrick's test showed positive results on both sides. An MRI scan of the lumbar spine showed mild bilateral foraminal stenosis at L4-5 and L5-S1, due to bulging discs.

The patient's pain was initially suspected to be L5 radicular pain, so a left L5 transforaminal epidural block was performed as a diagnostic block. A mixed solution of 0.08% chirocaine, 4 mL (levobupivacaine 25 mg/10 mL, Abbott Laboratories Ltd., Abbott Park, IL, USA), and triamcinolone 10 mg (triamcinolone acetonide 50 mg/5 mL/V, Dong Kwang Pharmaceutical Company, Ltd., Seoul, Korea) was injected into the left L5 transforaminal epidural space. Although the pain improved to a VAS score of 30 one day after the treatment, it returned after that, again level 90 on the VAS. The patient continued to report shooting, aching, and pressing pain in the left buttock and lateral hip, spreading to the lateral ankle. The pain was exacerbated by sitting or standing positions, which also led to the difficulty walking. A re-evaluation of the physical examination revealed severe tenderness over the left greater trochanter and piriformis muscle. Bilateral hip flexor and knee extensor muscle strength was found to be normal, grade 5/5; hyposthesia, hyperesthesia, and hyperalgesia were not present. Patrick's test was positive, and the pain was aggravated by internal rotation of the left hip joint.

On ultrasonographic evaluation (Fig. 1), we observed multiple mass-like lesions in the left buttock. The lesions were composed of multilocular cystic masses and calcifications. Ultrasound-guided aspiration was performed, and about 30 mL of fluid was aspirated from the cystic lesions. The aspirated fluid was yellowish, odorless, turbid, and gritty, and laboratory testing revealed it to have an elevated protein level of 218 mg/dL (normal range 37.7 mg/dL) (Fig. 2). Based on these findings, we believed a tumor was causing the patient's

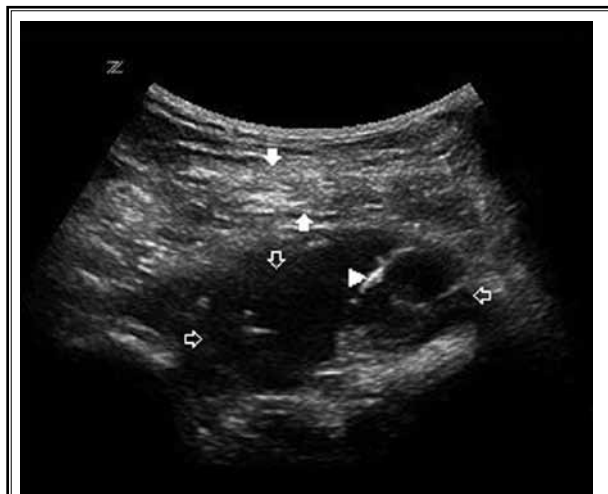

Fig. 1. Transverse 9-3 MHz US image shows a cystic mass (open arrow) with curvilinear calcific lesions (arrowhead) beneath the gluteus maximus muscle (white arrow) in the left buttock region.

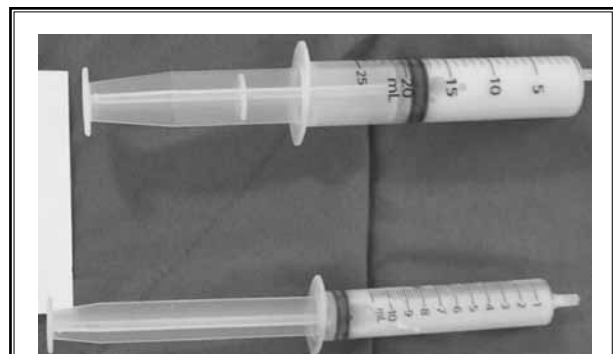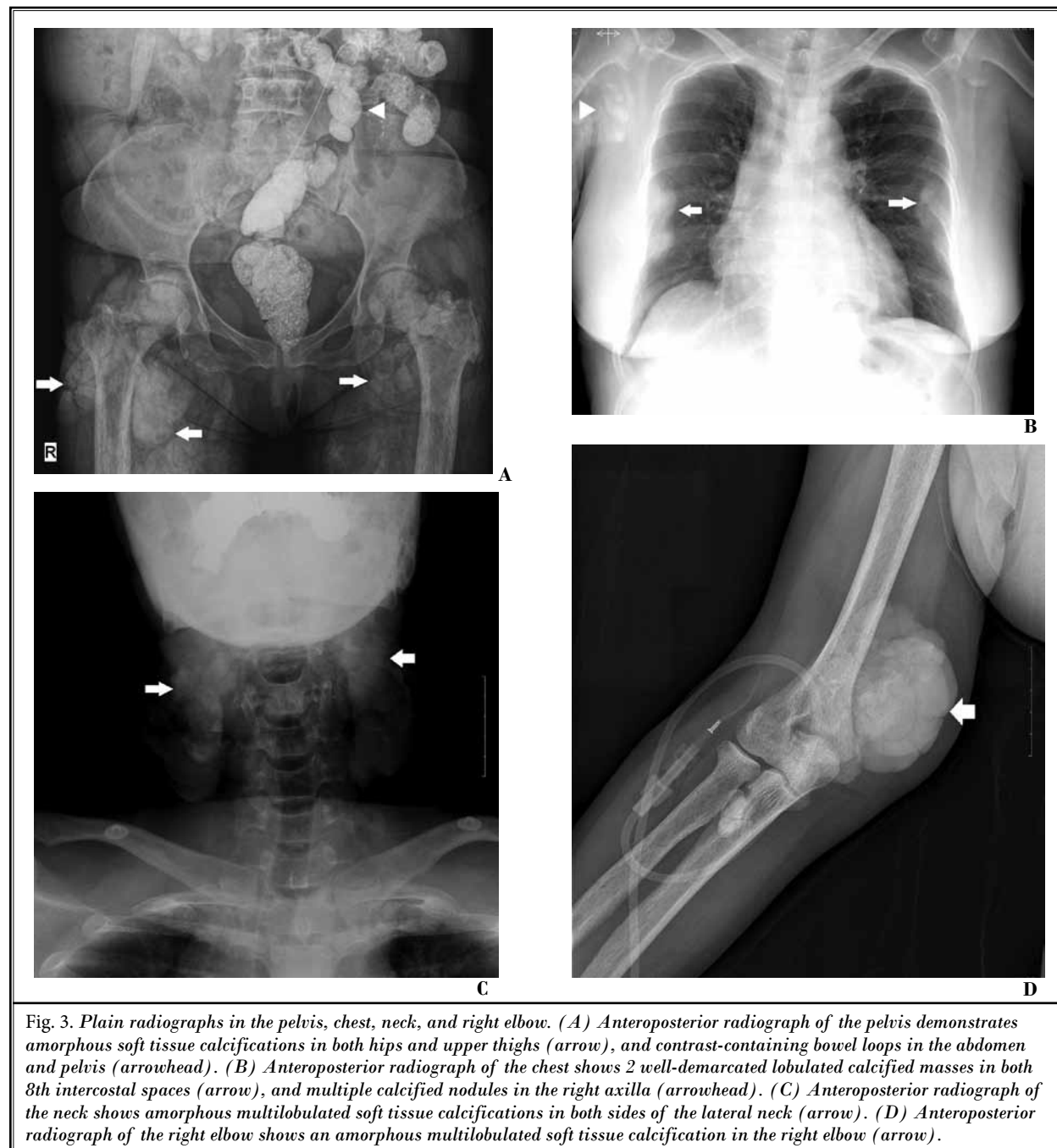


Fig. 2. The fluid obtained by aspiration from cystic lesions. About 30 mL of the aspirate was yellowish, odorless, turbid, and gritty.

pain. A 30 mL mixture of 0.08% levobupivacaine and triamcinolone 40 mg was injected into the bursa under ultrasound guidance. Following the injection, the patient's pain improved to a VAS score of less than 10.

We decided to further evaluate simple plain radiographs and a hip MRI scan to determine the exact diagnosis. Anteroposterior (AP) pelvic X-ray showed

multiple soft tissue calcifications located near both hip joints and proximal femurs (Fig. 3). Additionally, calcific masses were also identified in both sides of the neck, both 8th intercostal spaces, the right shoulder, and the right elbow (Fig. 3). Hip MRI revealed multilobular soft tissue masses like cystic lesions near both hip joints and thighs, located within the



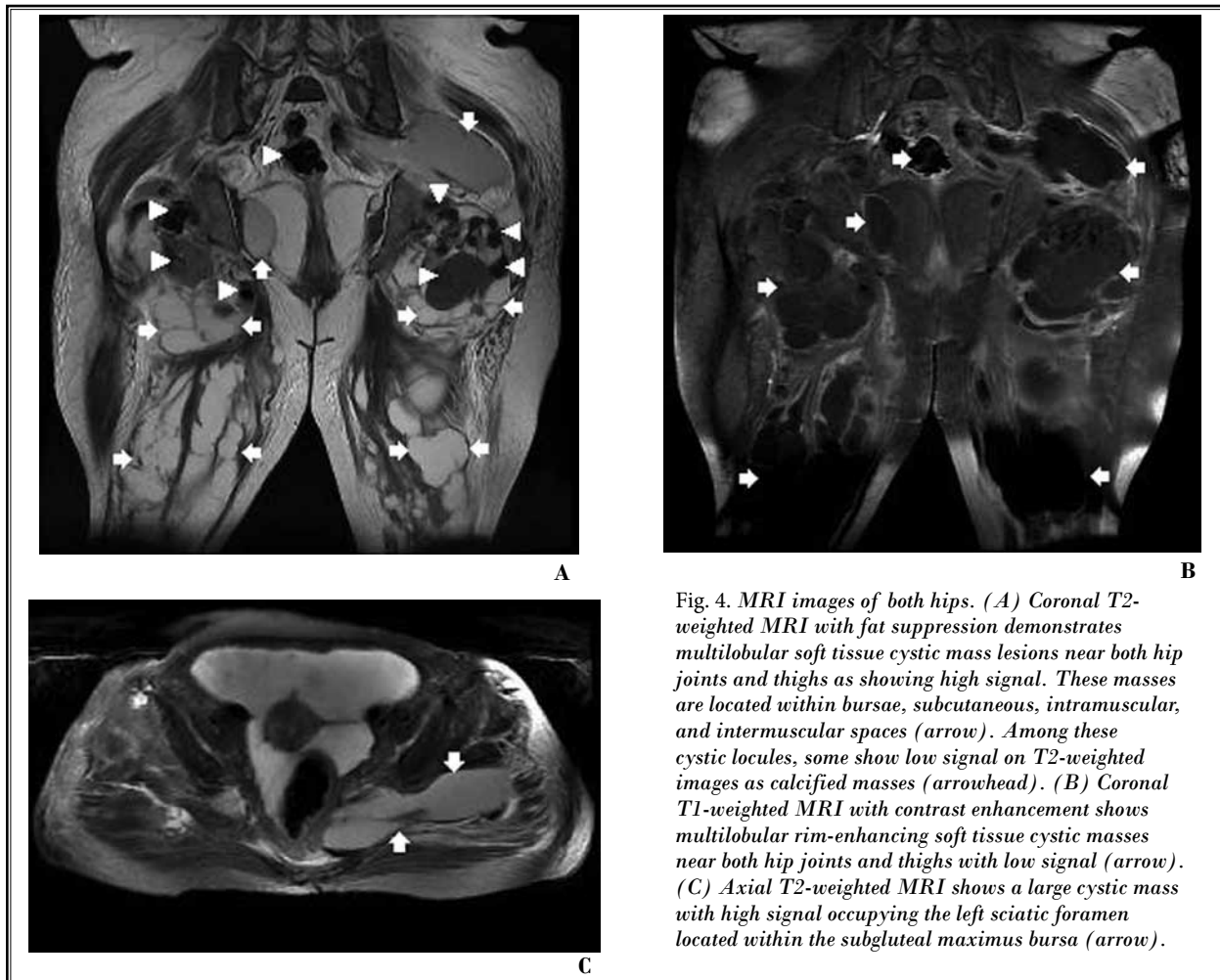


Fig. 4. MRI images of both hips. (A) Coronal T2-weighted MRI with fat suppression demonstrates multilobular soft tissue cystic mass lesions near both hip joints and thighs as showing high signal. These masses are located within bursae, subcutaneous, intramuscular, and intermuscular spaces (arrow). Among these cystic locules, some show low signal on T2-weighted images as calcified masses (arrowhead). (B) Coronal T1-weighted MRI with contrast enhancement shows multilobular rim-enhancing soft tissue cystic masses near both hip joints and thighs with low signal (arrow). (C) Axial T2-weighted MRI shows a large cystic mass with high signal occupying the left sciatic foramen located within the subgluteal maximus bursa (arrow).

bursae, intramuscular, and intermuscular spaces (Fig. 4). Based on the past medical history and test results, the patient was diagnosed with secondary tumoral calcinosis.

Three weeks later, the patient experienced right buttock pain of more than 90 on the VAS. This pain was similar to the previous left-sided pain, also causing difficulty in walking. About 40 mL of fluid was aspirated and 30 mL of 0.08% levobupivacaine with triamcinolone 40 mg injected around the right greater trochanteric bursa. After the treatment, the intensity of pain was reduced to a VAS score of less than 20. However, after one month, the right buttock pain recurred at a level of 90 on the VAS scale. About 70 mL of fluid was aspirated and 25 mL of 0.08% levobupivacaine with triamcinolone 40 mg injected around the right greater trochanteric bursa.

Following this treatment, there was no later recurrence of pain. Afterwards, a low phosphate diet and

the administration of phosphate binders such as calcium carbonate 1500 mg, lanthanum carbonate 1500 mg, or sevelamer 1600 mg per day, along with dialysis successfully reduced the tumoral calcinosis in the patient. Thirty months later, the calcified masses were decreased in the right hip joint, right shoulder, and chest regions. There was no evidence of calcinosis in the left hip and femur, right elbow, and neck (Fig. 5).

DISCUSSION

In this case, we identified GTPS in a patient presenting with severe tumoral calcinosis manifested with CKD and hyperparathyroidism. Ultrasonography was not only useful for the diagnosis and treatment of GTPS in a patient whose symptoms were initially thought to be due to a lumbar origin, but also provided an opportunity to further evaluate for tumoral calcinosis.

The lesions of tumoral calcinosis are characterized

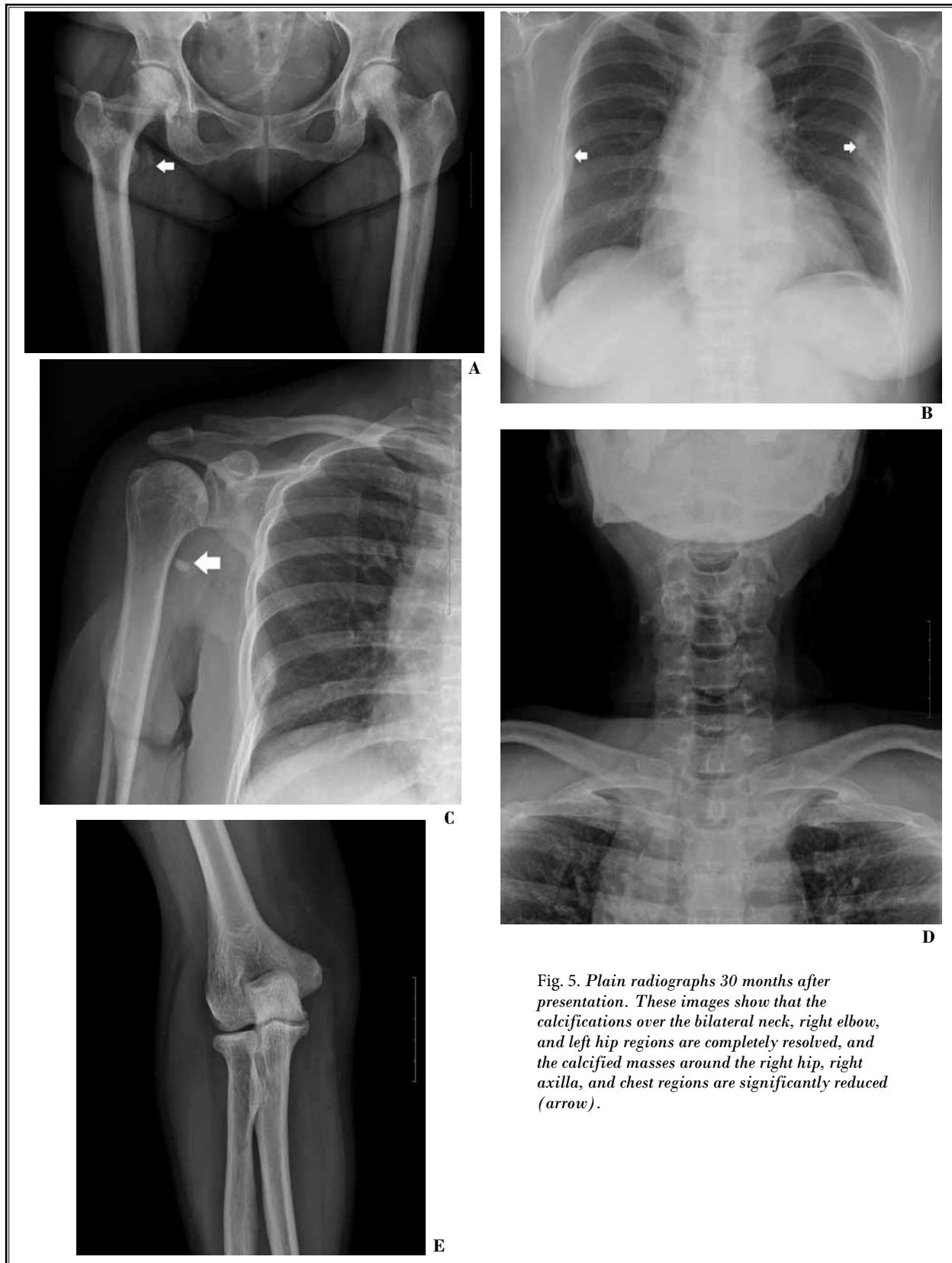


Fig. 5. Plain radiographs 30 months after presentation. These images show that the calcifications over the bilateral neck, right elbow, and left hip regions are completely resolved, and the calcified masses around the right hip, right axilla, and chest regions are significantly reduced (arrow).

as lobular, densely calcified masses confined to the soft tissue, generally at the extensor surface of the joint in the anatomic distribution of a bursa. The most commonly involved joints are the hip, shoulder, and elbow, but the underlying bone is normal (1). Tumoral calcinosis is usually classified as primary (idiopathic or familial) or secondary (8). The primary form typically presents with soft tissue masses in childhood or adolescence, and the cause is thought to be due to a hereditary metabolic dysfunction of phosphate regulation that results in hyperphosphatemia and associated high calcium-phosphate products ($> 75 \text{ mg}^2/\text{dL}^2$) (2,9). Secondary tumoral calcinosis can be differentiated from primary tumoral calcinosis with careful elicitation of patient history and laboratory evaluation. The secondary form occurs mainly in patients with CKD, and has been attributed to secondary hyperparathyroidism. The prevalence of tumoral calcinosis ranges from 0.5% to 3% in chronic hemodialysis patients (10). In these patients, hyperparathyroidism probably increases the uncontrolled secretion of PTH, and the relentless calcium efflux from bone increases the oversaturation of the calcium-phosphate product, and facilitates the extra-skeletal deposition of hydroxyapatite (11).

Tumoral calcinosis should be differentiated from calcinosis universalis, calcinosis circumscripta, soft tissue chondroma, pseudogout, and calcific tendinitis based on its clinical or pathologic characteristics (1). Tumoral calcinosis has a typical appearance on plain radiographs, with amorphous, cystic, and multilobulated calcifications located in a periarticular distribution. The calcifications are often associated with multiple and bilateral periarticular joints. This feature, as well as the frequent occurrence of multiple lesions, aid in the diagnosis of tumoral calcinosis. Computed tomography (CT) and MRI can better delineate the calcified masses. Another feature which distinguishes tumoral calcinosis from other pathologies is the lack of erosion or osseous destruction by adjacent soft-tissue masses (12). When underlying osseous changes are noted, histological examination is required for the differential diagnosis of malignant diseases such as synovial sarcoma and osteosarcoma. The diagnosis of tumoral calcinosis is generally based on the medical history and radiologic findings (1). In this case, we had initially overlooked the swelling around both hip joints as well as plain radiographs. Diagnostic images in this case revealed multiple periarticular calcifications without involvement of the underlying joints such as the hip, shoulder, and elbow joints. Finally, tumoral calcinosis could be diagnosed in

a patient with CKD based on the medical history and systemic radiologic findings.

The GTPS is a pain syndrome that occurs from structures that attach to the greater trochanter. GTPS can be due to bursitis or to abductor muscle (gluteus medius and gluteus minimus) tendinopathy or tear. The bursae of the greater trochanter are composed of the subgluteus maximus bursa, subgluteus medius bursa, subgluteus minimus bursa, piriformis bursa, and genitofemoral bursa. The deep subgluteus maximus bursa is often referred to as the trochanteric bursa. The trochanteric bursae are commonly implicated as a cause of lateral hip pain (6). GTPS is a common disorder, with reported incidence in primary care settings of around 1.8 patients per 1000 per year (13). GTPS typically presents as persistent pain and tenderness over the lateral hip and buttock. Approximately 50% of patients experience pain radiating along the lateral aspect of the thigh to the knee, and occasionally below the knee (14). Tortolani et al (15) found that 62.7% of patients with GTPS had previously been evaluated by spine surgeons for suspected radicular symptoms. In this case, as well, the spine surgeon, the nephrologist, and the pain physician initially thought that the patient's pain originated from a lumbar spine disorder.

The use of ultrasound for guiding musculoskeletal procedures has increased over the past several years (16). Advantages of ultrasound in this case include its soft tissue imaging capabilities, which allowed the identification of multilocular cystic lesions, and its utility in continuous real time monitoring of the insertion of needles into the cystic lesions. In addition, ultrasonography was very useful for the aspiration of calcific fluid and the injection of drugs in this case. It also revealed that a large amount of fluid was located within the left trochanteric bursa. Abscess was suspected due to the yellowish color of the aspirated fluid but because the fluid was odorless, and WBC, ESR, and CRP were within the normal range, infection could be excluded. In addition, chemical analysis of the aspirated fluid demonstrated a high protein level without infection. McGregor et al (17) previously reported that the cysts in tumoral calcinosis were filled with fluid largely composed of calcific material and calcospherites, and the composition was 78% carbonate apatite, 15% calcium carbonate, and 7% protein. Unfortunately, calcium contents of the aspirated fluid were not measured in this case.

Tumoral calcinosis can be differentiated into active and inactive stages based on images. A mass contain-

ing cystic-like lesions may suggest increased metabolic activity, whereas collagen sclerosis without fluid may indicate inactivity (18). In the active phase, amorphous calcified materials, multinucleated giant cells, and macrophages are present within the cysts. However, in the inactive phase, the inflammatory infiltrate is absent (17). In this case, the hip MRI showed multiple cystic lesions located within the greater trochanteric bursa, intramuscular, subcutaneous, and intermuscular spaces in the left buttock and occupying the left sciatic foramen. It was demonstrated that inflammatory greater trochanteric bursitis was the main cause of the left-sided sciatica-like symptoms. Ultrasound-guided injections with local anesthetics and steroids were very effective in the management of severe greater trochanteric bursitis due to uremic tumoral calcinosis (19).

The approach to therapy can be expected to differ to an extent on the basis of differing etiologies of tumoral calcinosis (8). Factors implicated in the occurrence of uremic tumoral calcinosis include calcium-phosphorus product elevation due to hyperphosphatemia. Treatment of chronic hyperphosphatemia is generally required in patients with CKD. Therefore, the principal modalities such as low calcium diet, low phosphate diet, and phosphate binders are used in an attempt to reverse and prevent the calcified masses of

uremic tumoral calcinosis (20). Additionally, increasing urinary phosphate excretion by the administration of acetazolamide may be beneficial (21). If the therapeutic outcome is unsatisfactory, subtotal parathyroidectomy should be performed (11). Surgical resection of calcified masses can be performed as a last resort (5). In the current report, the continuation of a low phosphate diet, phosphate binders, and peritoneal dialysis after subtotal parathyroidectomy succeeded in reducing swelling and preventing recurrence of pain.

CONCLUSION

Tumoral calcinosis is frequently misdiagnosed because it is a rare and poorly understood entity. GTPS is also often underdiagnosed despite its characteristic symptoms of diffuse pain in the buttocks and lateral thigh. Symptomatic periarticular soft tissue swellings initially require radiological evaluation. If soft tissue calcification is identified in a patient with CKD, tumoral calcinosis should be strongly suspected. If the diagnosis of tumoral calcinosis is rendered, it is likely to be related to GTPS. It is suggested that ultrasound is useful for the diagnosis and management of GTPS due to tumoral calcinosis, and ultrasound-guided injections with local anesthetics and steroids afford immediate and lasting pain relief.

REFERENCES

- Olsen KM, Chew FS. Tumoral calcinosis: Pearls, polemics, and alternative possibilities. *Radiographics* 2006; 26:871-885.
- Chaabane S, Chelli-Bouaziz M, Jelassi H, Mrad K, Smida M, Ladeb MF. Idiopathic tumoral calcinosis. *Acta Orthop Belg* 2008; 74:837-845.
- Mockel G, Buttgerit F, Labs K, Perka C. Tumoral calcinosis revisited: Pathophysiology and treatment. *Rheumatol Int* 2005; 25:55-59.
- Pecovnik-Balon B, Kramberger S. Tumoral calcinosis in patients on hemodialysis. Case report and review of the literature. *Am J Nephrol* 1997; 17:93-95.
- Leung YY, Lai R. Tumoral calcinosis: A case report. *J Orthop Surg (Hong Kong)* 2011; 19:108-112.
- Williams BS, Cohen SP. Greater trochanteric pain syndrome: A review of anatomy, diagnosis and treatment. *Anesth Analg* 2009; 108:1662-1670.
- Fearon AM, Scarvell JM, Neeman T, Cook JL, Cormick W, Smith PN. Greater trochanteric pain syndrome: Defining the clinical syndrome. *Br J Sports Med* 2013; 47:649-653.
- Farzan M, Farhoud AR. Tumoral calcinosis: What is the treatment? Report of two cases of different types and review of the literature. *Am J Orthop (Belle Mead NJ)* 2011; 40:E170-E176.
- Carmichael KD, Bynum JA, Evans EB. Familial tumoral calcinosis: A forty-year follow-up on one family. *J Bone Joint Surg Am* 2009; 91:664-671.
- Hamada J, Tamai K, Ono W, Saotome K. Uremic tumoral calcinosis in hemodialysis patients: Clinicopathological findings and identification of calcific deposits. *J Rheumatol* 2006; 33:119-126.
- Younes M, Belghali S, Zrour-Hassen S, Bejia I, Touzi M, Bergaoui N. Complete reversal of tumoral calcinosis after subtotal parathyroidectomy in a hemodialysis patient. *Joint Bone Spine* 2008; 75:606-609.
- Banks KP, Bui-Mansfield LT, Chew FS, Collinson F. A compartmental approach to the radiographic evaluation of soft-tissue calcifications. *Semin Roentgenol* 2005; 40:391-407.
- Lievens A, Bierma-Zeinstra S, Schouten B, Bohnen A, Verhaar J, Koes B. Prognosis of trochanteric pain in primary care. *Br J Gen Pract* 2005; 55:199-204.
- Klauser AS, Martinoli C, Tagliafico A, Bellmann-Weiler R, Feuchtner GM, Wick M, Jaschke WR. Greater trochanteric pain syndrome. *Semin Musculoskelet Radiol* 2013; 17:43-48.
- Tortolani PJ, Carbone JJ, Quartararo LG. Greater trochanteric pain syndrome in patients referred to orthopedic spine specialists. *Spine J* 2002; 2:251-254.
- Soneji N, Peng PW. Ultrasound-guided pain – interventions – a review of techniques for peripheral nerves. *Korean J Pain* 2013; 26:111-124.
- McGregor DH, Mowry M, Cherian R, McAnaw M, Poole E. Nonfamilial tumoral calcinosis associated with chronic

- renal failure and secondary hyperparathyroidism: Report of two cases with clinicopathological, immunohistochemical, and electron microscopic findings. *Hum Pathol* 1995; 26:607-613.
18. Huang YT, Chen CY, Yang CM, Yao MS, Chan WP. Tumoral calcinosis-like metastatic calcification in a patient on renal dialysis. *Clin Imaging* 2006; 30:66-68.
19. McEvoy JR, Lee KS, Blankenbaker DG, Del Rio AM, Keene JS. Ultrasound-guided corticosteroid injections for treatment of greater trochanteric pain syndrome: Greater trochanter bursa versus subgluteus medius bursa. *AJR Am J Roentgenol* 2013; 201:W313-W317.
20. Eddington H, Hoefield R, Sinha S, Chrysochou C, Lane B, Foley RN, Hegarty J, New J, O'Donoghue DJ, Middleton RJ, Kalra PA. Serum phosphate and mortality in patients with chronic kidney disease. *Clin J Am Soc Nephrol* 2010; 5:2251-2257.
21. Yamaguchi T, Sugimoto T, Imai Y, Fukase M, Fujita T, Chihara K. Successful treatment of hyperphosphatemic tumoral calcinosis with long-term acetazolamide. *Bone* 1995; 16:247S-250S.