

Case Report

Neurolytic Transversus Abdominal Plane Block with Alcohol for Long-Term Malignancy Related Pain Control

Joseph C. Hung, MD¹, Nyla Azam, MD², Vinay Puttaniah, MD¹, Vivek Malhotra, MD¹, and Amitabh Gulati, MD¹

From: ¹Memorial Sloan Kettering Cancer Center, New York, NY; ²New York Presbyterian Hospital, Weill Cornell Medical Center, New York, NY

Address Correspondence:
Joseph C. Hung, MD
Assistant Attending
Memorial Sloan Kettering Cancer Center
Anesthesiology and Critical Care
1275 York Avenue, H-914
New York, NY 10065
E-mail: hungj@mskcc.org

Disclaimer: Presented at the American Society of Regional Anesthesia and Pain Medicine Meetings, Chicago, April 2014. Conflict of interest: Each author certifies that he or she, or a member of his or her immediate family, has no commercial association (i.e., consultancies, stock ownership, equity interest, patent/licensing arrangements, etc.) that might pose a conflict of interest in connection with the submitted manuscript.

Manuscript received: 05-16-2014
Accepted for publication:
06-18-2014

Free full manuscript:
www.painphysicianjournal.com

There have been several case reports in the literature of neurolytic transversus abdominis plane (TAP) blocks being used for malignant abdominal wall pain. However, most used phenol as a neurolytic agent. We found only a single case report by Sakamoto using alcohol for TAP neurolysis. Unfortunately this patient passed away only 5 days after performance of the block. We attempt to extend upon the existing literature by describing neurolytic TAP blockade outcomes using alcohol on 3 cancer patients with metastatic disease to the abdominal wall. Two of our 3 patients had colorectal cancer invading the abdominal musculature. The third patient had a metastatic neuroendocrine nodule in the left rectus muscle. In our case series, all 3 patients had sustained and significant (greater than 50%) relief of abdominal wall pain after performing TAP neurolysis using alcohol. Ultrasound guidance was used for all blocks. The concentration of alcohol used varied from 33% to 77% between patients. Duration of relief lasted between 17 days and 6 months. Opioid use either decreased or remained relatively stable for prolonged periods of time after neurolysis. Other than one patient with transient post-procedure pain related to alcohol injection, there were no significant complications. Addition of a depo steroid for diagnostic TAP blockade prior to neurolysis did not appear to extend or provide additional analgesia. Based on our observations, TAP neurolysis using alcohol also offers a feasible option for long-term control of malignant abdominal wall pain. Further investigation is needed to determine if alcohol offers any significant advantage compared with phenol.

Key words: Transversus abdominis plane block, TAP Block, cancer pain, neurolysis, alcohol, ultrasound, abdominal pain, interventional pain management

Pain Physician 2014; 17:E755-E760

The transversus abdominis plane (TAP) block has been typically used for acute pain management following abdominal wall surgery. Several variations of the technique have been described including using a subcostal approach to cover more cephalad abdominal dermatomes and leaving a catheter in the TAP plane for continuous analgesia (1). All of these techniques involve blockade of the sensory afferent branches of the mid to lower thoracic intercostal and upper lumbar nerves that supply

sensation to the anterior abdominal wall. In the postoperative setting after abdominal surgery, the TAP block has been shown to reduce postoperative opioid requirements (1,2). However, the feasibility of using neurolytic TAP blocks to treat either chronic or cancer related abdominal wall pain remains relatively unclear.

Despite the availability of the World Health Organization analgesic guidelines for cancer pain, many patients still suffer from inadequate analgesia (3-5). Fur-

thermore, while opioids may provide pain relief, their use is associated with many side effects that may reduce quality of life (3). For these reasons, interventional pain relieving procedures may offer an attractive alternative option while reducing opioid-related adverse side effects.

There have been several case reports of neurolytic TAP blocks used for palliation of malignant abdominal wall pain (6-8). Thus far Sakamoto et al (8) appear to be the only ones to publish a case report using alcohol. The remainder of the existing articles all used phenol as a neurolytic agent (6,7). While effective, the patient described by Sakamoto et al passed away only 5 days after the procedure (8). We attempt to expand upon the existing literature by describing 3 patients for whom we performed neurolytic TAP block using alcohol for palliation of abdominal wall malignant pain.

CASE REPORT

All patients or an authorized representative provided written consent for this publication.

Patient 1

A 49-year-old woman with stage IV colon cancer was admitted in July 2013 for a small bowel obstruction. Her obstruction resolved gradually with conservative management. However, she was left with persistent periumbilical and bilateral abdominal wall pain thought to be secondary to infiltration from the underlying tumor. Physical examination was significant for a well-healed midline surgical incision from the previous resection, periumbilical tenderness with erythema, and allodynia around the lower aspect of her abdominal scar. A computed tomography (CT) scan from the same admission showed increased peritoneal carcinomatosis, a small amount of ascites, and peritoneal disease extending into the anterior abdominal wall measuring 5.0 x 3.1 cm. Her abdominal pain was persistent despite using 97 mg IV morphine through Patient Controlled Analgesia (PCA) over the past 24 hours.

Our anesthesia pain service was consulted with regards to interventional options for pain control. Given failure to achieve analgesia despite use of intravenous opioids, we performed 2 sets of TAP neurolytic blocks over the next 2 weeks – the first using the standard lumbar triangle of Petit (LTOP) approach and the second using the subcostal approach. The initial set of TAP blocks (diagnostic and then neurolytic) were performed in the inpatient setting via the standard LTOP approach for periumbilical abdominal wall pain. The patient had

near complete pain relief of this discomfort and was discharged from the hospital on immediate release morphine 15 mg q4h PRN – a substantial reduction given her previous morphine PCA usage. Upon follow-up in the outpatient pain clinic 2 weeks later, she was noted to have residual upper abdominal wall discomfort during her evaluation. Though she reported having continued relief of her original periumbilical pain, her residual tenderness was located in more cephalad dermatomes than before. Accordingly, a second set of TAP blocks (diagnostic and then neurolytic) were performed using the subcostal approach. These blocks occurred 9 days after her initial inpatient discharge.

Of note, a CT scan performed in this time frame revealed progression of the disease in both the lungs and abdominal wall. Two previous abdominal wall implants (3.1x2.1 cm and 2.9x2.9 cm) grew to 4.2x2.3 cm and 5.0x4.1 cm within a 2 week span.

Ultrasound guidance and a 25-gauge 1.5 inch needle were used for all procedures. Both diagnostic TAP blocks (LTOP and subcostal approach) were performed using 10 mL of bupivacaine 0.25% with Kenalog 40 mg on each side (20mL total volume for each block). Following both of these diagnostic blocks, she had near complete relief of associated abdominal wall pain for nearly 24 hours before returning back to baseline.

The initial neurolytic TAP block (LTOP approach) was performed first using 2 mL of lidocaine 1% on each side to ensure proper needle tip placement within the TAP plane. Following this, 10 mL of 80% alcohol was injected bilaterally. Including the lidocaine preceding injection of alcohol, 12 mL of total volume was used on each side – diluting the overall concentration of alcohol to 67%. For the second neurolytic TAP block (subcostal approach) confirmation of needle tip placement was confirmed using 3 mL of lidocaine 1% on each side followed by 10 mL of 100% alcohol. Overall, 13 mL of volume was used bilaterally with an overall concentration of alcohol diluted to 77%.

The patient tolerated all injections very well with no evidence of side effects. Even during the neurolytic procedures, she experienced almost no alcohol related burning pain upon injection.

Approximately one month after performing the initial neurolytic TAP block (LTOP approach), the patient returned to the hospital with worsening abdominal pain, nausea, and vomiting. She was found to have another small bowel obstruction associated with progression of the disease. At this point, her clinical status deteriorated rapidly with worsening diffuse pain,

dyspnea, and lower extremity edema. She passed away in the hospital shortly thereafter. However, up until her death, the patient reported having continued relief (greater than 50%) of her original abdominal wall pain following TAP neurolysis. Her statements were corroborated in multiple progress notes by both the oncology and surgery services noting very little abdominal wall tenderness during physical examination.

After the initial neurolytic TAP block (LTOP approach), the patient continued to have adequate analgesia using only morphine immediate release 15 mg q4h PRN up until her last hospital admission prior to

her death. Overall, she had 50 days of lower abdominal pain relief following LTOP approach neurolytic TAP block and 36 days of upper abdominal pain relief following extension of the original block using the subcostal approach (Fig. 1).

Patient 2

A 56 year-old woman with stage IV well-differentiated neuroendocrine tumor metastatic to the abdominal wall, liver, and spine was referred to the outpatient pain clinic for uncontrolled abdominal pain. During her initial evaluation, she described her pain as sharp, stab-

If range dose is indicated, begin with the lowest dose initially, unless, a higher dose is indicated based on nursing assessment.		Allergies/Reaction (Record in Red): NKDA										Year 2013
Two RNs/LIPs are required to complete the 3 checks upon initiation of a new PCA order, change in PCA settings, and change in medication and/or administration of a new bag of the current medication	DATE	7/7	7/7	7/7	7/7	7/8	7/8	7/8	7/8	7/9	7/9	
	TIME	12:30	17:00	17:00	18:00	01:40	05:45	8:15	10:10	02:00		
Check 1- Verify medication with current C/S order. Verify bag or cassette label against current/new C/S order for name, MRN, date, drug, concentration, basal rate, rescue dose		✓	✓	✓	✓	✓	✓	✓	✓	✓	✓	
Respirations (per minute)		18	18	18	20	18	20	18	18	18	18	
RASS* (+4 to -5)		0	0	0	0	0	0	0	0	0	0	
Epidural only extremity numbness or weakness (Y = Yes N = No NA = not applicable)		NA	NA	NA	NA	NA	NA	NA	NA	NA	NA	
PAIN SCALE. N = Numeric WB = Wong-Baker FACES F = FLACC C = CPOT		N	N	N	N	N	N	N	N	N	N	
Pain Score at Rest		0	1	1	0	0	0	3	0	0	0	
Pain Score with Movement		0	2	2	1	1	1	5	1	1	1	
Is Pain Relief Acceptable? (Y = Yes or N = No)		Y	Y	Y	Y	Y	Y	Y	Y	Y	Y	
Check 2- Verify PCA settings to current order. Verify C/S order against PCA setting for concentration, basal rate, rescue dose, lock level & lockout interval		✓	✓	✓	✓	✓	✓	✓	✓	✓	✓	
Medication: <u>Morphine</u> (✓)		✓	✓	✓	✓	✓	✓	✓	✓	✓	✓	
Route: <input checked="" type="checkbox"/> IV <input type="checkbox"/> subcutaneous <input type="checkbox"/> epidural <input type="checkbox"/> intrathecal (✓)		✓	✓	✓	✓	✓	✓	✓	✓	✓	✓	
Reservoir (residual) Volume (ml)		3	3	100	100	100	100	93	84	84	84	
Units: <input checked="" type="checkbox"/> mg <input type="checkbox"/> ml <input type="checkbox"/> micrograms (✓)		✓	✓	✓	✓	✓	✓	✓	✓	✓	✓	
Concentration: <u>1mg</u> per ml (✓)		✓	✓	✓	✓	✓	✓	✓	✓	✓	✓	
Continuous (Basal) Rate Per Hour		0	0	0	0	0	0	0	0	0	0	
Demand (Rescue) Dose		1	1	1	1	1	1	1	1	1	1	
Demand Dose Lockout Interval (minutes)		10	10	10	10	10	10	10	10	10	10	
Maximum Doses Per Hour		6	6	6	6	6	6	6	6	6	6	
# Doses Given / # Attempts		97 / 142	97 / 142	0 / 0	0 / 0	0 / 0	0 / 0	7 / 9	14 / 17	14 / 17	14 / 17	
Total Amount Given		97	97	0	0	0	0	0	14	14.0	14.0	
Lock Level (#)		42	42	42	42	42	42	2	42	42	42	

Fig. 1. Reduction in PCA usage after TAP neurolysis (Patient 1).

bing, and non-radiating. She localized her pain just lateral to the umbilicus on the left. Physical examination was significant for tenderness to palpation in the same area. No significant erythema or palpable tumor was present. A CT imaging of the abdomen taken the same day of her pain management consultation revealed a 1.0 x 0.8 cm left rectus nodule consistent with a metastatic implant. This CT scan was also significant for bilobar hepatic metastatic disease in addition to multiple sclerotic lesions located in the left ilium and T12 vertebral body. At the time of her initial consultation she was using only a small amount of opioid – oxycodone 5 mg PRN 1 – 3 tablets daily. However, she was very insistent on pursuing interventional therapies for pain control rather than escalating opioid therapy.

Given her wishes, a diagnostic TAP block was performed on the left using the standard LTOP approach. Ultrasound guidance was used to direct a 20G 2-inch block needle into the TAP plane. After proper placement, 20 mL of bupivacaine 0.25% was administered. The patient had no apparent ill effects from this procedure and reported having near complete pain relief afterwards. However, like patient 1, she had return of baseline abdominal pain within 24 hours. Two days after the initial diagnostic block, we proceeded with a neurolytic TAP block. The exact same approach was used (left sided LTOP approach) except that 15 mL of 100% alcohol was injected instead of bupivacaine. Prior to injecting alcohol, the TAP plane was dissected using 10 mL of lidocaine 1%. Including the lidocaine injected prior to the alcohol, 25 mL of total volume was used on the left side with an overall alcohol concentration of 60%.

The patient did experience moderate burning with alcohol injection but was able to return home after the procedure. During a follow-up phone call the next day, her postprocedure pain evolved into a diffuse left flank soreness described as “being kicked in the side.” This postprocedure tenderness persisted for about one week before subsiding to an acceptable level.

Follow-up oncology notes at 3 and 6 months after the neurolytic TAP block documented continued pain relief of the patient’s left sided abdominal pain. These observations were confirmed through follow-up phone calls from our service. At her 3 month follow-up, the patient did report having worsening contralateral abdominal discomfort. Subsequent imaging revealed progression of the disease in the liver and also a new sclerotic lesion within the right sixth rib. However, the patient refused to come into the pain clinic for follow-up evalu-

ation. She stated that she did not want any more injections despite having adequate long-term results from TAP neurolysis. Throughout the 6-month follow-up period the patient had stable analgesic requirements – remaining on oxycodone 5 mg PRN (Fig. 2).

Patient 3

A 52-year-old man with stage IV colon cancer was referred to the outpatient pain clinic for significant abdominal pain related to rapid progression of the disease. At the time of the referral, he was scheduled for home hospice admission and wanted a nerve block to control his excruciating pain prior to transfer. He described his pain as throbbing, stabbing, aching, and diffusely affecting the entire left side of his abdomen. Physical examination revealed significant erythema, allodynia, and hyperpathia along his entire left abdominal wall. The tumor was visibly protruding through the skin. A CT imaging from 2 weeks prior showed numerous and enlarged hepatic metastatic disease compared with one month prior. Imaging was also significant for an abdominal wall implant localized in the left upper quadrant measuring 8.8 x 4.6 cm which was previously 6.1 x 4.8 cm. At the time of this evaluation, his analgesic regimen consisted of methadone 5 mg q12h, dilaudid 12 mg q3h PRN, and oxycontin 60 mg q8h.

Given the patient’s limited life expectancy, it was decided to proceed directly with a neurolytic TAP block (and forego a diagnostic block) the day of his initial consultation. The patient had 2 neurolytic TAP blocks performed on the left side – the first via the LTOP approach and the other via the subcostal approach. Both were ultrasound guided and performed using a 20G 2-inch block needle. Injectate for each approach consisted of 10 mL of 50% alcohol preceded by 5 mL of lidocaine 1%. Including the lidocaine injected prior to the alcohol, 15 mL of total volume was used for each block with an overall alcohol concentration of 33%.

The patient did experience moderate burning pain upon injection of alcohol which subsided within 30 minutes after the block. Otherwise, there were no apparent procedure related complications.

Despite the patient’s advanced disease, he was managed in home hospice for the next 17 days on oral analgesics. His pain management regimen did not change much; he remained on oxycontin 60 mg q8h and methadone 5 mg q12h but dilaudid usage increased from 12 mg to 16 mg q3h PRN. Two days before his death, the patient was transferred to inpatient hospice for increasing delirium and agitation. At this point,

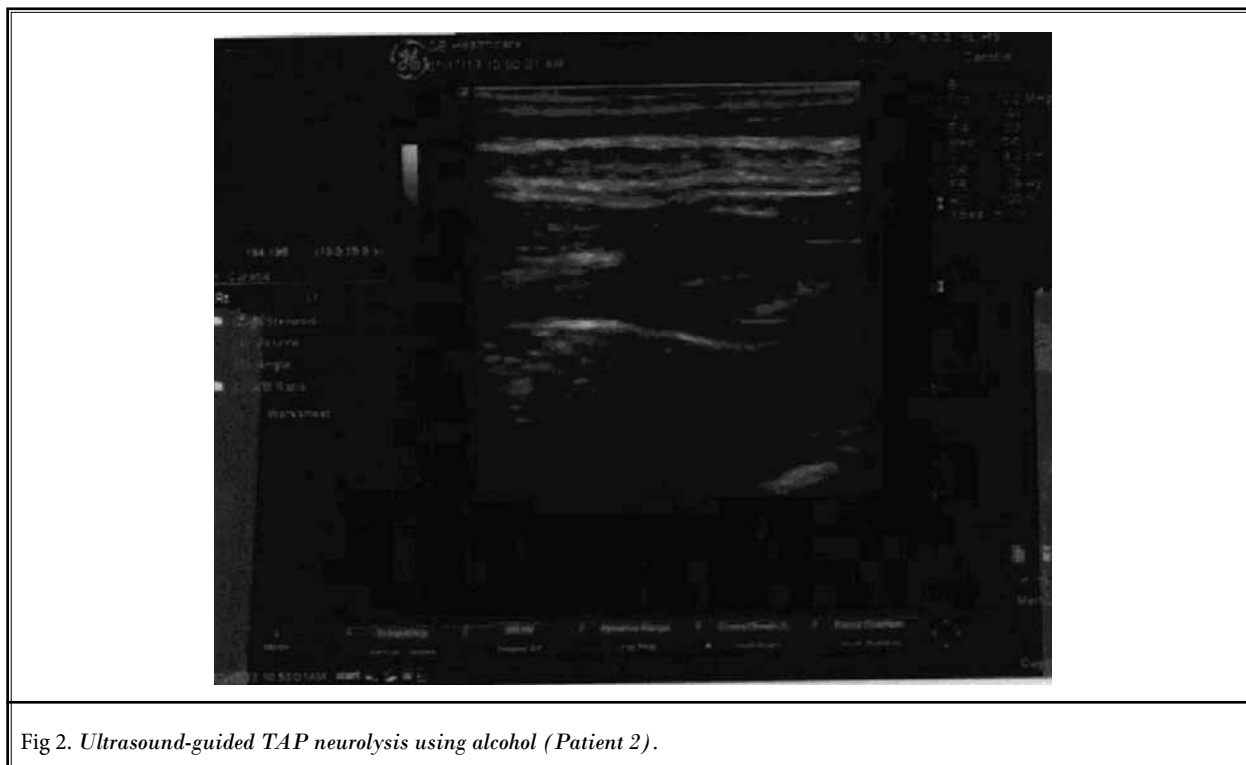


Fig 2. *Ultrasound-guided TAP neurolysis using alcohol (Patient 2).*

he was placed on ativan and dilaudid infusions. Up until this mental status change, the patient continued to report having at least 50% pain relief of his abdominal wall pain following TAP neurolysis through follow-up telephone conversations. Prior to inpatient hospice admission, he had 17 days of total pain relief from this procedure.

Discussion

We believe there are several important points of discussion from our case series.

First, the approach used for TAP block (LTOP versus subcostal) does make a difference when correlated with the anatomic location of pain. Patient 1 had very good relief of periumbilical pain following TAP neurolysis using the LTOP approach. However, she did have residual upper abdominal wall pain which was subsequently relieved using the subcostal TAP approach. Additional evidence for using different TAP approaches can be further corroborated through the cadaver study performed by Milan (9). After performing TAP block on cadavers using 40 mL of dye via 3 different anatomic approaches, Milan found that subcostal TAP block covered dermatomes T7-L1 while the LTOP approach spread only through T10-L1 (9).

Second, the addition of kenalog to bupivacaine did not appear to provide additional analgesia or prolong diagnostic TAP blockade. The addition of dexamethasone to local anesthetic for peripheral nerve blockade has been shown to extend sensory block duration for hours (10). The use of other corticosteroids in order to potentiate local anesthetic blockade has not been extensively studied. However, in animal studies, the extension of nerve blockade appears to be proportional to glucocorticoid potency (11). We chose to use a depot steroid in order to better target inflammation in the abdominal wall associated with tumor growth (12,13). However, all patients in our case series had a return of abdominal wall pain back to baseline within 24 hours after the diagnostic TAP blockade whether or not a steroid was added.

Finally, in terms of procedure related adverse effects, patient 2 had significant pain upon injection of alcohol which lasted for days following the procedure. She repeatedly stated this postprocedure pain was similar to "being kicked in the side." Though she later had progression of the disease to the contralateral side of her abdomen, postprocedure related pain from her initial neurolysis prevented her from returning to the pain clinic for another intervention. While it is very possible

that the needle tip migration resulted in an intramuscular injection of alcohol, it should be noted that patient 2 had the highest volume and concentration of alcohol (15 mL of 100% alcohol) injected at once. Use of a moderate volume of lidocaine (10 mL) prior to injecting the neurolytic agent did not help even though it should have theoretically expanded the TAP plane, anesthetized the anatomic area, diluted the overall concentration of alcohol (to 60%), and prevented intramuscular infiltration. While we also used 100% alcohol during TAP neurolysis for patient 1, a smaller volume (10 mL) and a different approach (subcostal versus LTOP) was used. Whether the injected concentration of neurolytic agent, final (diluted) neurolytic agent concentration, injectate volume, and/or anatomic variation between the subcostal versus the LTOP approach are responsible for more procedure related pain remains an area for further investigation.

The use of phenol as a neurolytic agent may mitigate postprocedure pain because it does have local anesthetic properties as opposed to alcohol (6,14). However, its viscous nature may make injection difficult through smaller bore needles. In addition, given its

thickness, it is unclear if the spread of phenol in the TAP plane differs markedly from that of alcohol.

CONCLUSION

In our case series, all patients had intolerable abdominal wall pain related to metastatic infiltration unresponsive to opioid analgesics. Following neurolytic TAP block using alcohol, all had significant relief (at least 50%) of their original symptoms. Duration of pain relief lasted between 17 days and 6 months. Of note, opioid requirements did vary significantly between patients. However, all had a progression of their metastatic disease to anatomic areas not covered by the TAP blockade. Patient 1 had the most marked reduction in terms of opioid requirement – initially using nearly 100 mg intravenous morphine daily but then requiring only morphine immediate release 15 mg q4h PRN after her initial TAP neurolysis.

Based on our observations, neurolytic TAP block using alcohol offers a feasible option for long-term control of malignant abdominal wall pain. This case series extends upon the existing literature describing the use of phenol for the same indication.

REFERENCES

1. Johns N, O'Neill S, Ventham NT, Barron F, Brady RR, Daniel T. Clinical effectiveness of transversus abdominis plane (TAP) block in abdominal surgery: A systematic review and meta-analysis. *Colorectal Dis* 2012; 14:e635-e642.
2. Charlton S, Cyna AM, Middleton P, Griffiths JD. Perioperative transversus abdominis plane (TAP) blocks for analgesia after abdominal surgery. *Cochrane Database Syst Rev* 2010:CD007705.
3. Breivik H, Cherny N, Collett B, de Conno F, Filbet M, Foubert AJ, Cohen R, Dow L. Cancer-related pain: A pan-European survey of prevalence, treatment, and patient attitudes. *Ann Oncol* 2009; 20:1420-1433.
4. Costantini M, Ripamonti C, Beccaro M, Montella M, Borgia P, Casella C, Miccinesi G. Prevalence, distress, management, and relief of pain during the last 3 months of cancer patients' life. Results of an Italian mortality follow-back survey. *Ann Oncol* 2009; 20:729-735.
5. van den Beuken-van Everdingen MH, de Rijke JM, Kessels AG, Schouten HC, van Kleef M, Patijn J. High prevalence of pain in patients with cancer in a large population-based study in The Netherlands. *Pain* 2007; 132:312-320.
6. Gebhardt R, Wu K. Transversus abdominis plane neurolysis with phenol in abdominal wall cancer pain palliation. *Pain Physician* 2013; 16:E325-330.
7. Restrepo-Garces CE, Asenjo JF, Gomez CM, Jaramillo S, Acosta N, Ramirez LJ, Lopera LM, Vargas JF. Subcostal transversus abdominis plane phenol injection for abdominal wall cancer pain. *Pain Pract* 2014; 14:278-282.
8. Sakamoto B, Kuber S, Gwirtz K, Elshahy A, Stennis M. Neurolytic transversus abdominis plane block in the palliative treatment of intractable abdominal wall pain. *J Clin Anesth* 2012; 24:58-61.
9. Milan Z, Tabor D, McConnell P, Pickering J, Kocarev M, du Feu F, Barton S. Three different approaches to transversus abdominis planeblock: A cadaveric study. *Med Glas (Zenica)* 2011; 8:181-184.
10. Choi S, Rodseth R, McCartney CJ. Effects of dexamethasone as a local anesthetic adjuvant for brachial plexus block: A systematic review and meta-analysis of randomized trials. *Br J Anaesth* 2014; 112:427-439.
11. Castillo J, Curley J, Hotz J, Uezono M, Tigner J, Chasin M, Wilder R, Langer R, Berde C. Glucocorticoids prolong rat sciatic nerve blockade in vivo from bupivacaine microspheres. *Anesthesiology* 1996; 85:1157-1166.
12. Frey H, Norman N. Duration of action of depot-corticosteroids. II. Triamcinolone acetonide and triamcinolone diacetate. *Eur J Clin Pharmacol* 1971; 3:229-231.
13. Rakoff-Nahoum S. Why cancer and inflammation? *Yale J Biol Med* 2006; 79:123-130.
14. Rathmell JP. Atlas of Image-guided Intervention in Regional Anesthesia and Pain medicine. Lippincott Williams & Wilkins, Philadelphia, 2006.