

Report of an Unusual Complication of Radiofrequency Neurotomy of Medial Branches of Dorsal Rami

To the Editor

Radiofrequency neurotomy (RFN) of the medial branches (MB) of the lumbar dorsal rami is a common procedure to treat facetogenic backache. Serious complications are unusual when guidelines are followed (1). We report for the first time, the development of severely painful camptocormia (inability to straighten the back in the upright position that disappears in the recumbent position) as a complication immediately following MB RFN. The myofascial consequences of MB RFN are highlighted.

Case Presentation

A 65-year-old woman was referred to us with a one month history of back pain and camptocormia, developing one day after bilateral RFN of MB at L1-2, 3-4, L5-S1 (Fig. 1A). The referring pain physician had documented 2 60% positive test doses prior to MB RFN. Prior oral neuromodulators and transforaminal

epidural injection of triamcinolone had not relieved her magnetic resonance imaging (MRI) proven back-related problems of 3 years.

She presented with paraesthesia (tingling and numbness), hyperalgesia in the back and thighs, sleep disturbance, continuous burning aching lumbar back, and bilateral knee pain [7/10 on Numeric Rating Pain Scale (NRS)]. Camptocormia [resulting from a mismatch between the actions of back flexors and extensors] and analgic gait in short steps necessitated the use of a walker.

Neurology consultation and MRI was sought for medico-legal purposes. In the meantime the patient requested treatment for her painful camptocormia. After an explanation that ultrasound-guided dry needling (USGDN) could probably reduce the camptocormia resulting from a mismatch between the actions of back flexors and extensors, she requested a trial of twice-

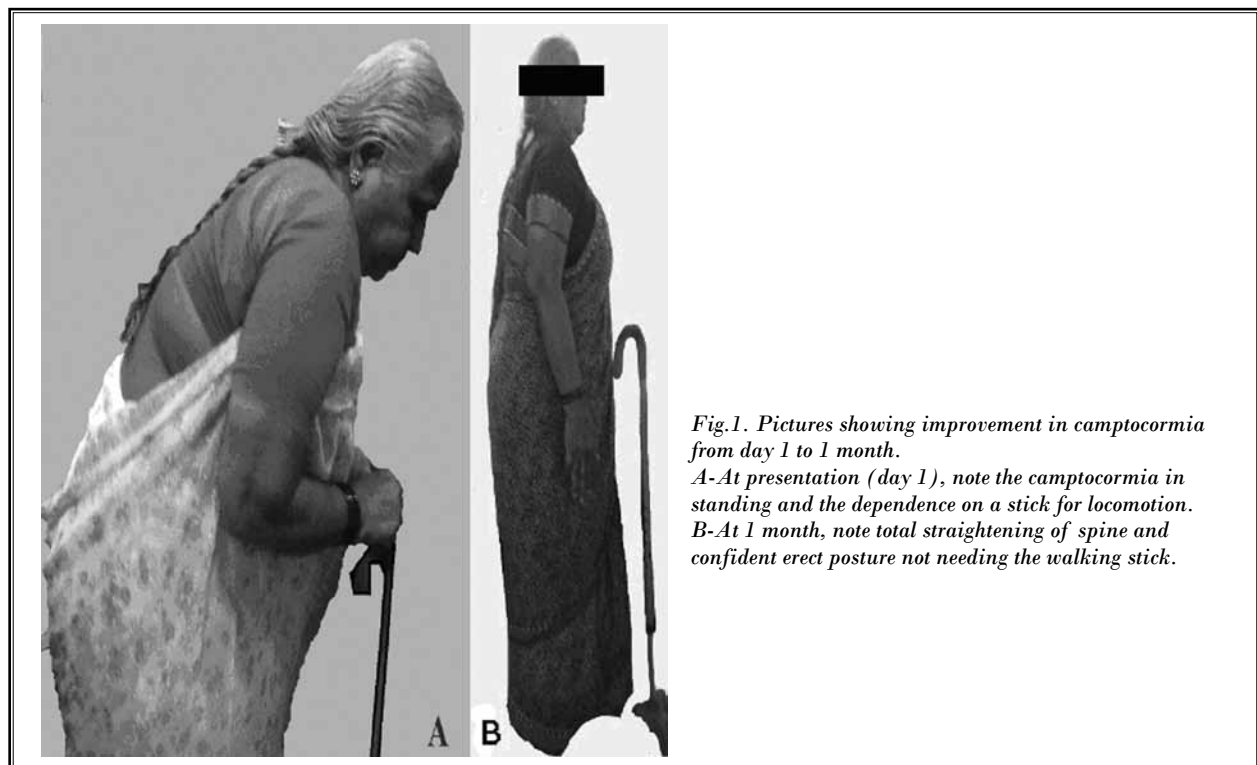


Fig.1. Pictures showing improvement in camptocormia from day 1 to 1 month.

A-At presentation (day 1), note the camptocormia in standing and the dependence on a stick for locomotion.

B-At 1 month, note total straightening of spine and confident erect posture not needing the walking stick.

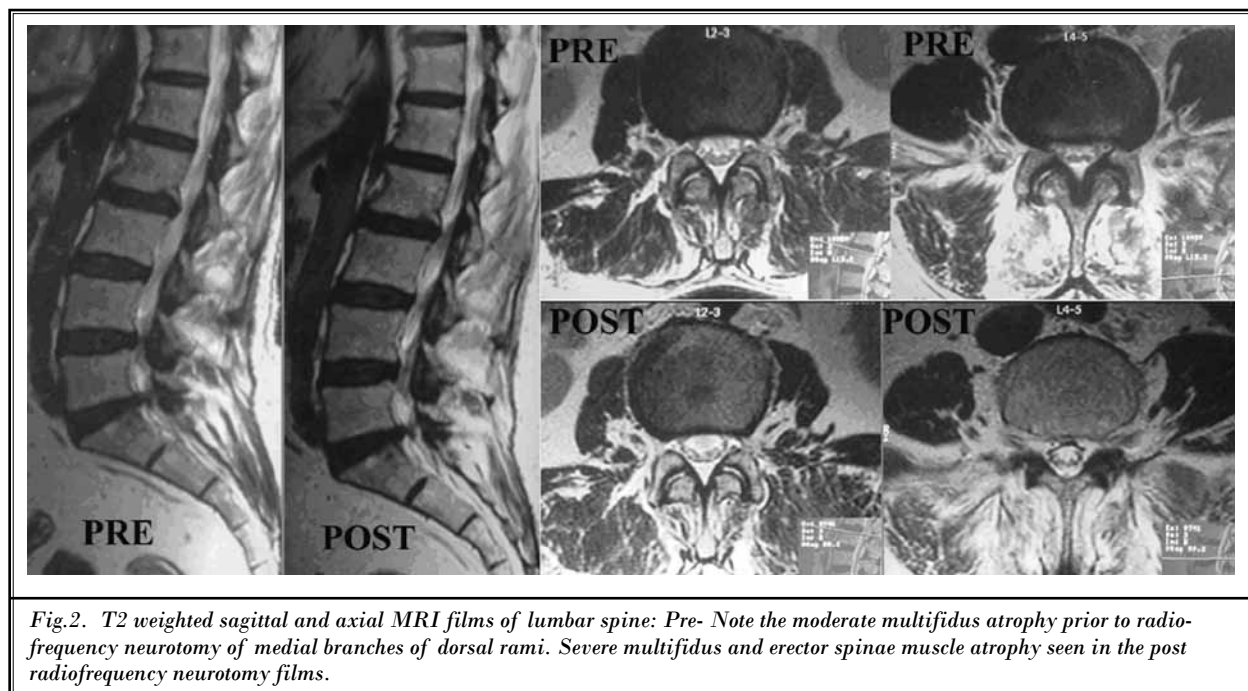


Fig.2. T2 weighted sagittal and axial MRI films of lumbar spine: Pre- Note the moderate multifidus atrophy prior to radiofrequency neurotomy of medial branches of dorsal rami. Severe multifidus and erector spinae muscle atrophy seen in the post radiofrequency neurotomy films.

weekly USGDN. Targeting spinalis, longissimus, and iliocostalis components of erector spinae and psoas muscle with 32 gauge, 40 – 75 mm long needles reduced the NRS score by 50% and improved her posture in 15 days. At one month, she was quite happy with her pain relief, improved gait, and posture (Fig. 1B).

The neurologist diagnosed Parkinson's disease (PD) and levodopa was prescribed. The radiologist specifically reported a newly observed atrophy of lumbar paraspinal muscles on MRI (Fig. 2). At 2 months neither pain nor camptocormia, but the knee pain restricted her activities.

We treated the knee pain as a chronic post-surgical pain (CPSP), but with our protocol for addressing neuromyopathy (2), with pulsed radiofrequency (PRF) of the knee nerve supply and USGDN of muscles acting across the knee. Outcome measures like NRS (3), PainDETECT (4), Oxford Knee Score (OKS) (5), Western Ontario and McMaster University Osteoarthritis Index (WOMAC) score (likert version) (6), and Short Form 12 version 2 (SF12v2) (7) showed improvement sustained for a year (Fig. 3).

Discussion

Potential side effects of MB RFN could be painful cutaneous dysesthesias, increased pain due to neuritis or neurogenic inflammation, anesthesia dolorosa, cuta-

neous hyperesthesia, and deafferentation pain. It is recommended that, for lumbar MB RFN to be anatomically accurate, electrodes should be placed parallel to the target nerve to ensure lesions along the maximal available length of the nerve. Multiple needle placements are expected to compensate for variations in nerve location. Multifidus atrophy is reported after MB RFN (8). However, if the active tip of the needle is positioned proximal to the eye of the scotty dog, the whole medial branch along with the motor supply of polysegmentally innervated multifidus could be ablated, leading to loss of segmental stabilization (9). If the RFN needle is located at the main dorsal ramus, its lateral division, supplying ileocostalis and longissimus components of erector spinae could be ablated (lumbar dorsal ramus syndrome). Resultant atrophy of multifidus and all 3 components of erector spinae would lead to significant loss of extension and the stabilization effect produced by these muscles on the spine.

In our patient the pre-RFN MRI displayed mildly atrophic multifidus which worsened significantly along with a new onset of severe atrophy of spinalis, longissimus components of the erector spinae seen in the post-RFN MRI, led to our assumption of RFN needle placement at the main dorsal ramus or its lateral division. Atrophy of spine extensors in the presence of a normal psoas led to camptocormia. The hitherto un-

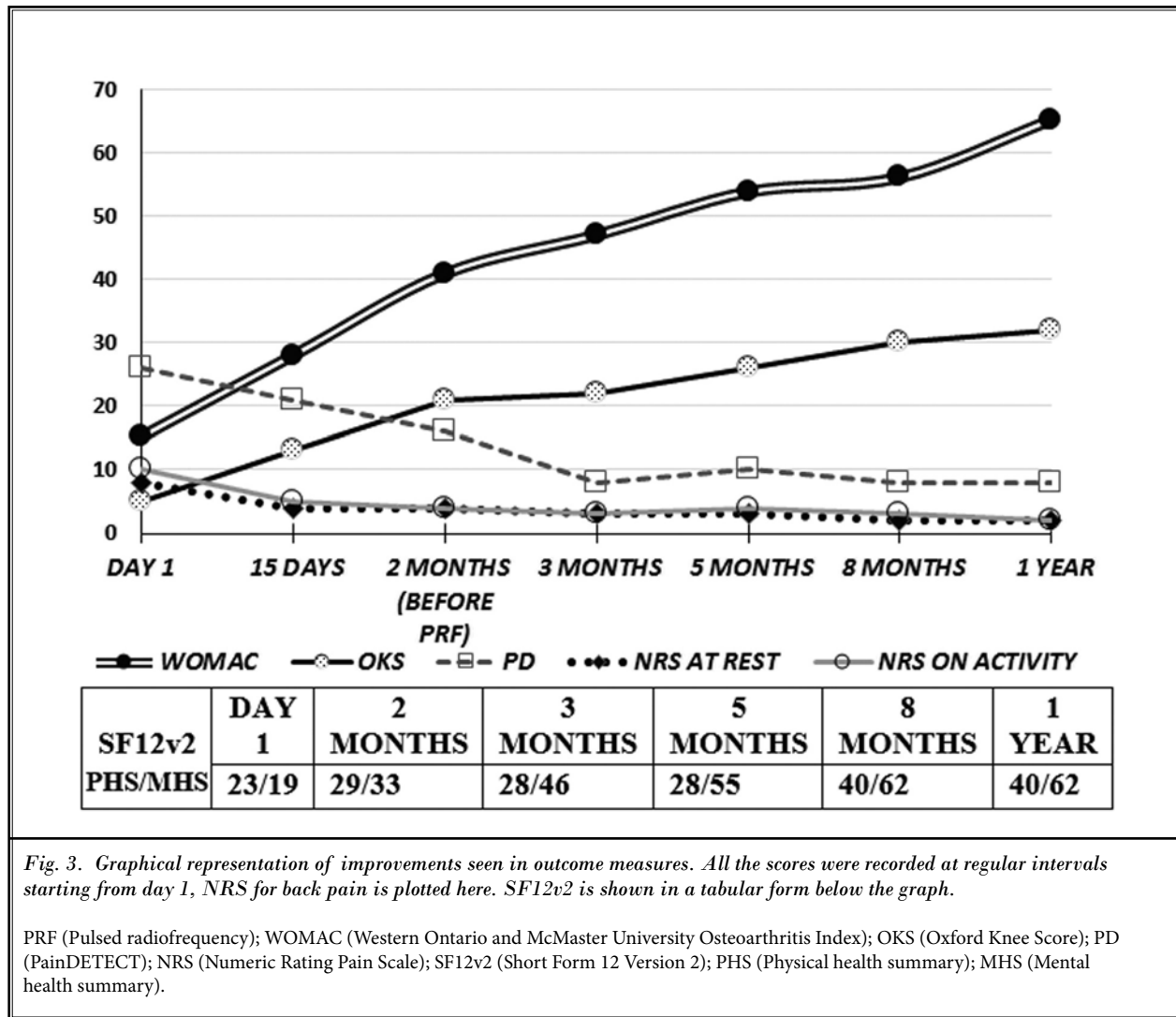


Fig. 3. Graphical representation of improvements seen in outcome measures. All the scores were recorded at regular intervals starting from day 1, NRS for back pain is plotted here. SF12v2 is shown in a tabular form below the graph.

PRF (Pulsed radiofrequency); WOMAC (Western Ontario and McMaster University Osteoarthritis Index); OKS (Oxford Knee Score); PD (PainDETECT); NRS (Numeric Rating Pain Scale); SF12v2 (Short Form 12 Version 2); PHS (Physical health summary); MHS (Mental health summary).

diagnosed PD might also have predisposed her to this complication.

Complete recovery of camptocormia by USGDN in our patient was remarkable because treatment options for PD related camptocormia, like physiotherapy, orthoses, drugs, injection of botulinum toxin in abdominal and iliopsoas muscles, psychotherapy, withdrawal of causative drugs, electroconvulsive therapy, surgical correction, and deep brain stimulation have shown limited efficacy. By the time the diagnosis of PD was made in our patient, pain and camptocormia had already improved. This strongly supports a new role for USGDN in the treatment of PD related camptocormia, to relax the myofascial trigger points causing the taut bands in the spinal muscles.

USGDN for the relief of camptocormia has not been reported. We used this unconventional treatment based on our understanding of muscle kinesiology of spine flexion and its effectiveness in relieving muscle spasm. USGDN relaxed the presently dominant psoas causing camptocormia. The camptocormia would be expected to stretch the erector spinae to cause exacerbation of pain on standing. As an extrapolation of Starlings law, shortened muscle fibers forming myofascial bands in the atrophic erector spinae would be the first to respond to stretch, with rest of fibers of normal length remaining unstretched and therefore unresponsive. Relaxation and restoration of these taut bands to their normal muscle fiber length by USGDN would logically recruit more erector muscle bulk for contraction.

The improved extensor functionality of erector spinae coupled with the relaxation of the flexor pull of psoas relieved both camptocormia and the axial back pain exacerbated by RFN. Another consideration was that trophic factors associated with needling could facilitate regeneration of contractile muscle fibers within the fibrous framework of atrophic multifidus and erector spinae muscles (10).

We addressed the CPSP in the operated knee restricting our patient's total recovery as a neuromyopathy. PRF addressed the neural component and USGDN relaxed the stiffened muscles acting across the knee to relieve the myofascial component. This combination of therapies significantly relieves both pain and stiffness (2). One year later with improved knee function and quality of life, she has managed to lose 15 kg of weight. In conclusion, we wish to highlight that new therapies like USGDN and PRF may play a significant role in customizing therapy for uncommon clinical presentations.

Lakshmi Vas, MD
MD Anesthesia,
Ashirvad Institute for Pain Management and Research (AIPMR),
Plot. no. 117, Shubh Ashirvad, Road no. 5,
Hindu colony, Dadar east.
Mumbai – 400 014.
India.
lakshmi@paincareindia.com

Nishigandha Khandagale, MD
Ashirvad Institute for Pain Management
and Research
Mumbai, India
E-mail: drkhandagale@gmail.com

Renuka Pai, MD
Diploma
Ashirvad Institute for Pain Management
and Research,
Mumbai, India
E-mail: pairenuka@yahoo.co.in

REFERENCES

1. Bogduk N, Dreyfuss P, Baker R, Yin W, Landers M, Hammer M, April C. Complications of spinal diagnostic and treatment procedures. *Pain Med* 2008; 9:11-34.
2. Vas L, Khandagale N, Pai R. Successful management of chronic post-surgical pain following total knee replacement. *Pain Med*. Article first published online: DOI: 10.1111/pme.12508.
3. McCaffery M. Pain management: Problems and progress. In: McCaffery M, Pasero C (eds), *Pain: Clinical Manual*. 2nd ed. Mosby, St. Louis, MO, 1999, pp 16.
4. Freynhagen R, Baron R, Gockel U, Tölle TR. painDETECT: A new screening questionnaire to identify neuropathic components in patients with back pain. *Curr Med Res Opin* 2006; 22:1911-1920.
5. Dawson J, Fitzpatrick R, Murray D, Carr A. Questionnaire on the perceptions of patients about total knee replacement. *J Bone Joint Surg [Br]* 1998; 80:63-69.
6. Bellamy N. WOMAC osteoarthritis index. *A User's Guide*. Ontario: London Health Services Centre, 1996.
7. Ware JE, Kosinski M, Keller SD. How to Score the SF-12 Physical and Mental Health Summary Scales. 2nd ed. The Health Institute, Boston, 1995.
8. Dreyfuss P, Stout A, Aprill C, Pollei S, Johnson B, Bogduk N. The significance of multifidus atrophy after successful radiofrequency neurotomy for low back pain. *PM R* 2009; 1:719-722.
9. Wu PB, Date ES, Kingery ES. The lumbar multifidus muscle is polysegmentally innervated. *Electromyogr Clin Neurophysiol* 2000; 40:483-485.
10. Tough EA, White AR, Cummings TM, Richards SH, Campbell JL. Acupuncture and dry needling in the management of myofascial trigger point pain: A systematic review and meta-analysis of randomized controlled trials. *Eur J Pain* 2009; 13:3-10.