

## Case Reports

## Use of Targeted Transversus Abdominus Plane Blocks in Pediatric Patients with Anterior Cutaneous Nerve Entrapment Syndrome

Sarah L Nizamuddin, MD, Katharine M Koury, BA, Mary E Lau, BS, Lisa D Watt, PNP, and Padma Gulur, MD

From: Massachusetts General Hospital,  
Boston, MA.

Address Correspondence:  
Padma Gulur, MD  
204 Lonetree  
Irvine, CA 92603  
E-mail:  
pgulur@yahoo.com

Disclaimer: There was no external  
funding in the preparation of this  
manuscript.

Conflict of interest: Each author certifies  
that he or she, or a member of his or her  
immediate family, has no commercial  
association (i.e., consultancies, stock  
ownership, equity interest, patent/  
licensing arrangements, etc.) that might  
pose a conflict of interest in connection  
with the submitted manuscript.

Manuscript received:  
01-16-2014

Revised manuscript received:  
04-30-2014

Accepted for publication  
05-19-2014:

Free full manuscript:  
[www.painphysicianjournal.com](http://www.painphysicianjournal.com)

Anterior cutaneous nerve entrapment syndrome (ACNES) is a commonly overlooked source of chronic abdominal wall pain. A diagnosis of ACNES should be considered in cases of severe, localized abdominal pain that is accentuated by physical activity. Providers should consider diagnosing ACNES once a patient has both a positive result from a Carnett's test and precise localization of pain. We describe the use of transversus abdominus plane (TAP) blocks to treat ACNES in the pediatric patient population. TAP blocks are a treatment modality which have been described less frequently in the management of this syndrome, with rectus sheath blocks being used more commonly. TAP blocks can be used effectively for ACNES by targeting the site of maximal tenderness, which was identified using ultrasound guidance. Moreover, TAP blocks are an attractive procedure option for ACNES as they are less invasive than other commonly used techniques. We present 3 case series reports of pediatric patients evaluated at our institution for severe abdominal pain to describe the clinical manifestations, sequelae, and outcome of ACNES. Though the exact incidence of ACNES in the pediatric population is unknown, this condition has significant implications from chronic pain. Chronic pain can lead to significant emotional and social impacts on these pediatric patients, as well as their on their families. Further, the extensive utilization of health care resources is impacted when children with undiagnosed ACNES undergo invasive treatments when ACNES is not in the early differential. The purpose of this case series report is to prompt better recognition of the condition ACNES, and to highlight the efficacy of TAP blocks as a management strategy.

**Key words:** TAP block, pediatric patients, abdominal pain, ACNES

**Pain Physician 2014; 17:E623-E627**

**C**hronic abdominal wall pain (CAWP) has been defined as abdominal tenderness which is chronic or intermittent that lasts for over one month, is very localized or with a fixed location of tenderness, and has a positive Carnett's test (1). CAWP can originate from the muscles or from nerve entrapment. Trigger points in the abdominal musculature are not commonly described or encountered in clinical practice. Anterior cutaneous nerve entrapment syndrome (ACNES) appears to be a common source of CAWP that is often overlooked in patients (1). Although ACNES has been implicated

as a source of abdominal pain in up to 30% of adult cases, information about children is less prevalent (2). Described as a sharp, localized pain, ACNES is caused by the entrapment of a branch of the lower thoracic (T7-T12) intercostal nerves in the abdominal wall muscle (3). As the condition goes undiagnosed, patients may begin to describe additional diffuse components in the abdomen or worsening of symptoms where they associate worsening pain that is precipitated by factors such as food intake. Failure to make an accurate diagnosis may be, in part, due to clinicians' lack of awareness and can result in unnecessary

examinations and invasive treatments. According to a study of 16 patients in 2001 by Thompson et al (4), an average of \$6,727 was spent on patients complaining of abdominal pain before a diagnosis of abdominal wall syndrome was made. With a simple Carnett's test, the majority of patients with chronic abdominal wall pain can be identified with little risk of missing intra-abdominal pathology (1,2,5). Briefly, it involves palpating the area of greatest tenderness on the patient. If the pain increases or stays the same severity with contraction of abdominal wall muscles, then the source of pain likely originates from the abdominal wall itself (6). Treatment strategies have ranged from trigger point injections and rectus sheath blocks all the way to surgical decompression. The point of maximum tenderness most likely represents the site of nerve entrapment. When the differential of nerve entrapment is considered, the transversus abdominus plane (TAP) or rectus sheath blocks are the best diagnostic tests to confirm ACNES. Our approach intends to block the nerve where it is entrapped based on the reported point of tenderness by the patient. We feel this technique is superior to trigger point injections or rectus sheath blocks which are not directed towards the irritated nerve itself. This also allows for targeted deposition of smaller volumes of anesthetic and the steroid is closer to the required site of action.

## OBJECTIVE

The purposes of this case series is to describe the clinical manifestations, sequelae, and outcome of ACNES in adolescent patients to prompt better recognition of the condition and to elaborate a more effective treatment option in the form of targeted TAP blocks.

## METHODS

Three case series reports (Table 1) are presented of adolescents evaluated for severe, debilitating abdominal pain at a tertiary care, pediatric chronic pain clinic within a large, urban hospital.

## Procedure

All cases received a TAP block for ACNES. The point of maximal tenderness was identified by the patients in conjunction with palpation by the provider. Ultrasound imaging was then employed over this point of maximal tenderness and the external oblique, internal oblique, and TAPs were identified. After sterile prep and drape, the skin over the point of entry was anesthetized using 2 mL of 1% lidocaine with a 1½ inch 25-gauge needle. A 25-gauge spinal needle was then directed under ultrasound guidance to the junction of the internal oblique and TAPs. After negative aspiration, an injectate containing Triamcinolone and 2% lidocaine was injected in this plane. The needle was then removed.

Table 1. Evaluation of patients in 3 cases.

	Case 1	Case 2	Case 3
Age	15	15	16
Gender	Female	Female	Male
Persisting Complaint	Right upper quadrant abdominal pain	Right upper quadrant abdominal pain	Left upper quadrant abdominal pain
<b>Prior Work-up:</b>			
• Tests	Celiac Test	Celiac Test and Lyme Disease	N/A
• Imaging	CT Scan, Abdominal Ultrasound, Hepatobiliary Scan, Endoscopic Ultrasound	Ultrasound, MRI, and Upper GI Series	Gastric Emptying Scan, Upper GI Series
• Procedure	Endoscopy, Mucosal Resection	Endoscopy, Colonoscopy, and Laparoscopic Appendectomy	Endoscopy
Medication(s)	NSAIDs and Tylenol	Oral opioid, antidepressant, benzodiazepine, and NSAIDs	Oral opioid and antidepressants
Intervention	Targeted TAP Block	Targeted TAP Block	Targeted TAP Block
Solution Used	1 mL of 40 mg/mL Kenalog and 4 mL of 1% lidocaine	1 mL of 40 mg/mL of Triamcinolone Acetate and 4 mL of 1% lidocaine	4 mL of 10 mg/mL Kenalog and 2 mL of 1% Lidocaine
Multiple Blocks; #	Yes; 2	Yes; 3	No; 1

### Case 1

A 15-year-old girl was referred for pain management with an 8 month history of right upper quadrant (RUQ) pain of unclear etiology. She reported sharp and intermittent pain rated between 6 to 8 out of 10, which was localized to the RUQ of her abdomen. An extensive evaluation to rule out intrabdominal pathology by a gastroenterologist was unrevealing. It included an endoscopy which revealed a benign gastric mass in the antrum and mild distal esophagitis for which she underwent endoscopic mucosal resection. Pancreatic heterotopia was shown on pathology, with no evidence of malignancy and her pain did not appear to be related to this. Conservative management with medications at the time of referral did not provide relief. On exam at our pain clinic, she had a positive Carnett's test with pain localized lateral to the rectus sheath in her RUQ. She denied allodynia or dysesthesia to light touch/pressure at the site of localized pain. After informed consent, we proceeded with a diagnostic cum therapeutic TAP block localized to her point of maximal tenderness (Table 1)

While she had significant relief immediately after the injection, it took 2 to 4 days for the pain to subside completely and she was able to return to her normal activities. She remained pain free for approximately a 2 month period before she began to experience a gradual return of her intermittent abdominal pain, which occurred during strenuous activity such as heavy lifting and long periods of swimming but was still at a level lower than her initial presentation to us. She underwent a repeat targeted TAP block. With the second block she actually experienced transient worsening of symptoms for a day or 2 before the pain subsided completely once again. She returned to full function and sports activities and has not had to return for care now 4 months after her second procedure.

### Case 2

A 15-year-old girl was referred to the pain center with a more than one year history of severe RUQ abdominal pain. Prior to consultation, she had been extensively worked up to rule out intra-abdominal pathology by several gastroenterologists and a gynecologist. She had also visited the emergency department multiple times and required inpatient admissions for pain control. At one admission she eventually underwent an appendectomy. The pain continued and was debilitating resulting in decreased function and poor school attendance (missed 3 months of school). Treatments had included opioids, antidepressants, and a benzodiazepine

with minimal reported effect and NSAIDs with reported moderate effect. Pain at rest was reported to be 4 to 6 out of 10, with exacerbation to 7 to 10 out of 10. Upon physical exam, she had a positive Carnett's test and localized the pain (at 11 o'clock), again lateral to the rectus sheath. She denied allodynia or dysesthesia to light touch/pressure at the site of localized pain. After an extensive discussion of differentials, she underwent a diagnostic cum therapeutic targeted TAP block at her point of maximal tenderness under ultrasound guidance at the junction between the internal oblique and transverse abdominus muscles. Postprocedure she reported a minimal decrease in abdominal pain. Upon follow-up 3 weeks later, she reported improved function but minimal improvement in pain control. She was able to return to a full school schedule. Two months later however she complained of return of pain which interestingly she had previously never reported as gone. We performed a repeat TAP block at that point again targeted to the point of maximal tenderness. Upon follow-up one month after, she reported improved pain control and improved function. However she eventually had a gradual return of the same pain symptoms but this time it was 8 months later. We chose to proceed with a third targeted TAP block given she had received even longer benefit from the second one. She has returned to a full school schedule and sports activities. At this time she is one year and 8 months from the third block and has not had to come to clinic for a return of pain.

### Case 3

A 16-year-old boy was referred to the pain center with a 3 month history of severe left upper quadrant (LUQ) abdominal pain. Prior to consultation, he was extensively evaluated by a gastroenterologist to rule out intra-abdominal pathology, which at most showed mild esophagitis not in keeping with the location of his pain. His pain was debilitating, resulting in decreased function and poor school attendance (missed 2 months of school). He had gone to the emergency department a few times for pain control. Treatments included an oral opioid and antidepressants with minimal reported effect. He reported constant localized abdominal pain, 10 out of 10, which was localized to the LUQ. Upon physical exam, the patient had a positive Carnett's test with pain localized (at 2 o'clock) lateral to the rectus sheath in the LUQ. He denied allodynia or dysesthesia to light touch/pressure at the site of localized pain. After an extensive discussion of differentials, he under-

went a diagnostic cum therapeutic targeted TAP block at the point of maximal tenderness under ultrasound guidance at the junction between the internal oblique and transverse abdominus muscles. Postprocedure, he reported an immediate decrease in pain. He had improved function for about 2 months when he had started to report a gradual return of his symptoms. We had planned to repeat the block if the symptoms worsened; however, the patient was lost to follow-up.

## Discussion

Pain originating from the abdominal wall is often overlooked in the early differential of children presenting with abdominal pain. After initial work-up to rule out acute intrabdominal pathology, abdominal wall pain should also be considered. Often this evolves into a chronic pain issue. Chronic pain can have significant emotional and social impact on children and their families. Suffering from pain daily can limit a child's ability to attend school, socialize with peers, and participate in physical activity. In addition, the physical and psychological sequelae associated with chronic pain may impact overall health, predisposing a child for the development of adult chronic pain (7,8). Of the main causes of CAWP, ACNES appears to be the most common cause (1).

The 3 case series reports highlight the impact undiagnosed ACNES

may have on children, including prolonged and debilitating pain, unnecessary examinations, invasive treatments, as well as disruption of daily activities and school attendance. While a comprehensive psychological evaluation was not performed, it is noteworthy that each patient also reported frustration, anxiety, and/or negative effect on mood due to prolonged pain. As a result, 2 of the 3 cases were given a psychiatric diagnosis and prescribed a course of antidepressants by an outside provider.

Though diagnosis can be difficult, a positive result on Carnett's test and the precise localization of the pain should prompt the provider to consider the diagnosis of ACNES.

While various treatment options have been reported in the literature, nerve entrapment is localized and we targeted our treatment to the site of maximal tenderness, which in our patients was well lateral to the rectus sheath. The use of ultrasound guidance allowed precise localization of the junction between the internal oblique and transversus abdominis where the anterior cutaneous nerves traverse and this direct visualization also allowed us to deposit a smaller amount of injectate. In our practice where we aim to perform a diagnostic cum therapeutic injection, the injectate includes local anesthetic to numb the nerves for diagnostic clarity and steroid for long-lasting effect on presumed inflammation (Fig. 1). The steroid was not diluted in large volumes and directed to the most likely site of inflammation which would allow for maximal efficacy. While the patients needed multiple blocks, each block resulted in longer periods of pain relief.

Substantial pain relief after an accurately targeted TAP block is both diagnostic and therapeutic for ACNES. Other treatment options for

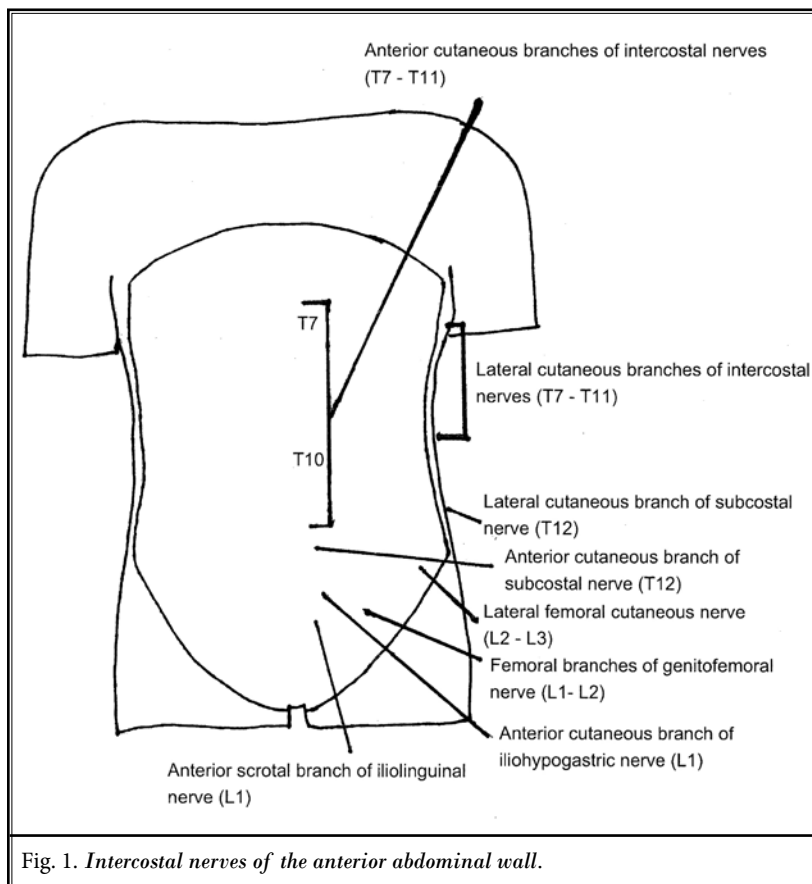


Fig. 1. Intercostal nerves of the anterior abdominal wall.

ACNES that have been tried in the past including rectus sheath blocks and trigger point injections. Two recent publications have presented case series that demonstrate the successful treatment of ACNES with rectus sheath blocks in pediatric patients (9,10). However, because one-third of patients have anterior cutaneous nerves which do not run in the rectus sheath but rather anteriorly to the sheath, this may not be a targeted approach (11). We do not feel that trigger point injections are a reliable method of treatment because the anterior cutaneous nerves course through a deeper muscle plane, and injecting local anesthetic and steroids superficially at the point of tenderness may not lead to sustained relief. Lastly, an anterior cutaneous neurectomy has been described as successfully treating children with ACNES (12). While it is a short ambulatory surgical procedure, we feel initial attempts with a less invasive TAP block may be beneficial to the patient in

order to avoid a more invasive treatment option and given data in the literature on recurrence with neurectomies in other sites in the body.

## CONCLUSION

Prompt identification and treatment of ACNES can have implications for the future as persistent abdominal pain in childhood is significantly associated with a decreased quality of life and an increased risk of psychiatric disorder in adulthood (7). Our case series reports demonstrates the successful use of targeted TAP blocks to treat ACNES which allows for the use of a smaller amount of medications. We hope that with increasing awareness, early differential diagnosis, and a more targeted and effective treatment option, children with ACNES will be less likely to suffer the long-term consequences of chronic pain.

## REFERENCES

1. Srinivasan R, Greenbaum DS. Chronic abdominal wall pain: A frequently overlooked problem. Practical approach to diagnosis and management. *Am J Gastroenterol* 2002; 97:824-830.
2. Lindsetmo RO, Stulberg J. Chronic abdominal wall pain – a diagnostic challenge for the surgeon. *Am J Surg* 2009; 198:129-134.
3. Applegate WV. Abdominal cutaneous nerve entrapment syndrome. *Surgery* 1972; 71:118-124.
4. Thompson C, Goodman R, Rowe WA. Abdominal wall syndrome: A costly diagnosis of exclusion. *Gastroenterology* 2001; 120:A637.
5. Thompson WH, Dawes RF, Carter SS. Abdominal wall tenderness: A useful sign in chronic abdominal pain. *Br J Surg* 1991; 78:223-225.
6. Takada T, Ikusaka M, Ohira Y, Noda K, Tsukamoto T. Diagnostic usefulness of Carnett's test in psychogenic abdominal pain. *Intern Med* 2011; 50:213-217.
7. Campo JV, Di Lorenzo C, Chiappetta L, Bridge J, Colborn DK, Gartner JC Jr, Gaffney P, Kocoshis S, Brent D. Adult outcomes of recurrent abdominal pain: Do they just grow out of it? *Pediatrics* 2001; 108:E1.
8. Walker LS, Garber J, Van Slyke DA, Greene JW. Long-term health outcomes in patients with recurrent abdominal pain. *J Pediatr Psychol* 1995; 20:233-245.
9. Skinner AV, Lauder GR. Rectus sheath block: Successful use in the chronic pain management of pediatric abdominal wall pain. *Paediatr Anaesth* 2007; 17:1203-1211.
10. Akhnikh S, de Korte N, de Winter P. Anterior cutaneous nerve entrapment syndrome (ACNES): The forgotten diagnosis. *Eur J Pediatr* 2014; 173:445-449.
11. Simpson DM, Tyrrell J, De Ruiter J, Campbell FA. Use of ultrasound-guided subcostal transversus abdominis plane blocks in a pediatric patient with chronic abdominal wall pain. *Paediatr Anaesth* 2011; 21:88-90.
12. Scheltinga MR, Boelens OB, Tjon A Ten WE, Roumen RM. Surgery for refractory anterior cutaneous nerve entrapment syndrome (ACNES) in children. *J Pediatr Surg* 2011; 46:699-703.

