

## Case Report

## Transverse Abdominal Plane Neurostimulation for Chronic Abdominal Pain: A Novel Technique

Mayank Gupta, MD, and Robert Goodson, MD

From: Anesthesiology Professionals, Overland Park, KS  
Dr. Goodson is a medical student in a six year program.

Address Correspondence:  
Mayank Gupta, MD  
President,  
Anesthesiology Professionals,  
10985 Cody Street,  
Overland Park, KS  
66210  
E-mail:  
mayankempire@yahoo.com

Disclaimer: There was no external funding in the preparation of this manuscript.

Conflict of interest: Each author certifies that he or she, or a member of his or her immediate family, has no commercial association (i.e., consultancies, stock ownership, equity interest, patent/licensing arrangements, etc.) that might pose a conflict of interest in connection with the submitted manuscript.

Manuscript received: 01-29-2014  
Revised manuscript received:  
04-15-2014  
Accepted for publication:  
04-28-2014

Free full manuscript:  
www.painphysicianjournal.com

Management of chronic abdominal pain can be challenging. Sometimes patients fail to get adequate response from multiple medications and nerve blocks. We present a patient case report of chronic abdominal pain with a history of multiple surgeries managed successfully by neuromodulation of the transverse abdominis plane (TAP).

The TAP block is a procedure in which local anesthetic is injected into the abdominal fascial plane that carries sensory nerves to the abdominal wall in order to block pain sensation. It has been shown to reduce postoperative pain and analgesic dependence after abdominal and gynecological surgeries.

A 60-year-old woman presented to us for chronic abdominal pain for which medications provided little relief. She had an extensive history of abdominal surgeries and was also treated for lower back pain with surgery and less invasive procedures in the past. Under our care, she underwent 2 TAP blocks with almost complete resolution of her abdominal pain. Her pain, however, came back within a few of weeks of the procedures.

Since our patient found pain relief from the TAP blocks, we proceeded with neurostimulation of the TAP for long-term pain relief. We placed a dorsal column stimulator 16 contact lead for lower back and leg pain and 8 contact leads placed in the TAP under ultrasound guidance. She has had multiple follow-ups since her TAP lead placement procedure with continued and near complete resolution of her abdominal pain. The TAP lead stimulation was helping her abdominal pain and the dorsal column lead stimulation was helping her back and leg pain.

**Key words:** Chronic abdominal pain, neuromodulation, transverse abdominis plane, ultrasound, transverse abdominis plane block, multiple abdominal surgeries

**Pain Physician 2014; 17:E619-E622**

**T**he transverse abdominis plane (TAP) block is a peripheral nerve block designed to anesthetize the nerves supplying the anterior abdominal wall (T6 to L1). A.N. Rafi et al first described it in 2001 as a traditional blind landmark technique using the lumbar triangle of Petit (1). Local anesthetic is injected between the internal oblique and transverse abdominis muscles fascial plane (the plane through which the sensory nerves from T6 to L1 pass). In a recent meta-analysis, the TAP block was shown to reduce the need

for postoperative opioid use, increase the time to first request for further analgesia, and provide more effective pain relief, while decreasing opioid related side effects such as sedation and postoperative nausea and vomiting (2). Studies included a combination of both general abdominal and gynecologic procedures (3,4). The introduction of ultrasound has allowed providers to identify the appropriate tissue plane and perform this block with greater accuracy under direct visualization (5). The TAP block is a simple procedure

that can be used as an adjunct for postoperative pain control in abdominal, gynecologic, or urologic surgery involving the T6 to L1 distribution (1,3,4,5).

### CASE DESCRIPTION

We present a case of a 60-year-old woman referred to us for the primary complaint of chronic abdominal pain. Her past medical history was significant for multiple abdominal surgeries that included a cholecystectomy, umbilical herniorrhaphy, inguinal hernia surgery, exploratory laparotomy, and hysterectomy. She also had complaints of chronic low back pain and leg pain. For her chronic back and leg pain she had multiple epidurals and underwent fusion surgery as well. The majority of her complaint was chronic abdominal pain. For this she had tried multiple medications including opioids, non-steroidal anti-inflammatory drugs, muscle relaxants, gabapentin, nortriptyline, duloxetine, etc. When she came to see us she was taking 3200 mg gabapentin, oxycodone/acetaminophen 5/325 3 to 4 tablets per day, duloxetine 30 mg, cyclobenzaprine 10 mg tablet as needed, and celecoxib 200 mg tablet. Her average VAS (Visual Analog Scale) pain score was 6–8 out of 10. Her chronic abdominal pain was limiting her activities of daily living. She was unable to do household activities or sit in car for more than 30 minutes without pain. Pain was also interfering with her sleep. On examination her abdomen had multiple scar marks from previous sur-

geries. It was soft, non-distended, and mildly tender on deep palpation. There was diffuse generalized abdominal pain. She was treated with bilateral TAP block on 2 separate occasions, approximately 2 weeks apart. The blocks were performed under ultrasound guidance while we administered 10 mL of block solution on each side containing 80 mg of injectable suspension of methylprednisolone acetate and 19 mL of 0.5% bupivacaine. The TAP block made her completely pain free for about 2 weeks and then pain started coming back. We hypothesized that if a TAP block provided short-term relief, then neurostimulation of T6 to L1 nerves can provide long-term relief.

### PROCEDURE DESCRIPTION

A neurostimulator trial was performed using a dorsal column stimulator 16 contact lead for low back and leg pain. Eight contact leads were placed in the TAP using ultrasound guidance (Fig. 1). The stimulation setting was set for both the dorsal column lead and peripheral lead placed in the TAP plane. The dorsal column lead was helping her back and leg pain. The TAP leads were helping with her mid-abdominal pain. With the TAP lead individual stimulation our patient was feeling stimulation in her abdomen starting from the lateral aspect to the mid-abdomen. Settings for the leads were as follows: bi-pole configuration at 1.5 ma, 250 pw, and 40 hz.

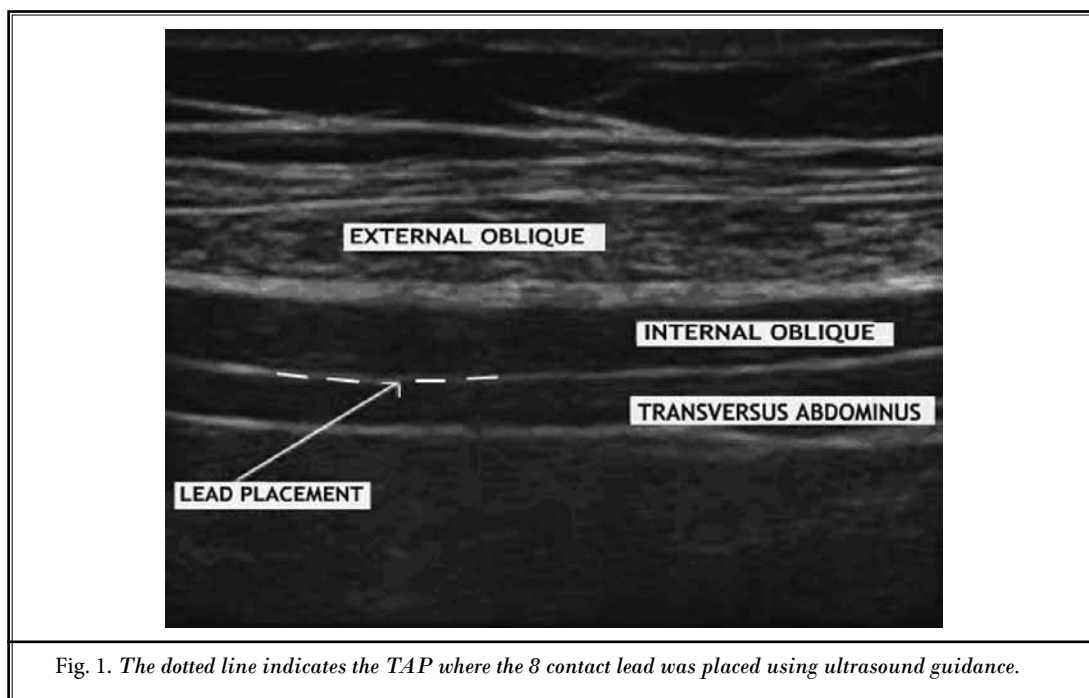


Fig. 1. The dotted line indicates the TAP where the 8 contact lead was placed using ultrasound guidance.

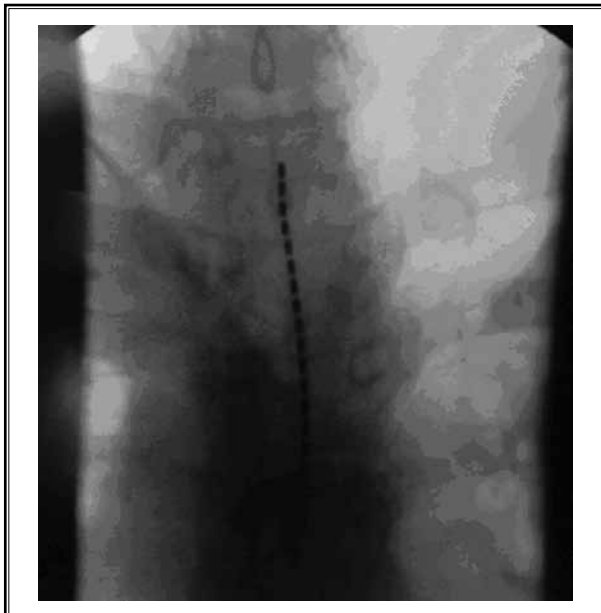


Fig. 2. Placement of the 16 contact dorsal column percutaneous lead.



Fig. 3. Ultrasound-guided lead placement.

The trial was done for 5 days. Our patient reported 90% relief in abdominal pain and back pain and had cut down on pain medication use significantly. Since our patient achieved good responses during the trial phase, we decided to proceed with permanent implants.

One 16 contact dorsal column percutaneous lead was placed (Fig. 2). Two 8 contact leads were placed in the TAP by surgically exposing the plane between the internal oblique and transverse abdominis muscle under ultrasound guidance (Figs. 3 and 4). Leads were placed laterally between the iliac crest and twelfth rib. Post-operative stimulator settings were as follows: DC lead – virtual guarded cathodes at 4.5 ma, 400 pw, and 60 hz; TAP leads were not turned on at this time due to postoperative pain.

Our patient had follow-ups at one week, 2 weeks, one month, 6 weeks, and 3 months after surgery. Our patient reported pain on VAS as 1 – 2 out of 10 with 80% – 90% relief consistently. She reported reduction in her pain medication consumption by more than 50%. She has cut down her gabapentin from 3200 mg to 1800 mg daily dosage. Occasionally she takes one tablet of oxycodone/acetaminophen 5/325 per day or celecoxib 200 mg per day, which she claims she takes for knee arthritis. No side effects or complications were reported from surgery. She reported some soreness at the surgery site up to 2 weeks after surgery. She is now able

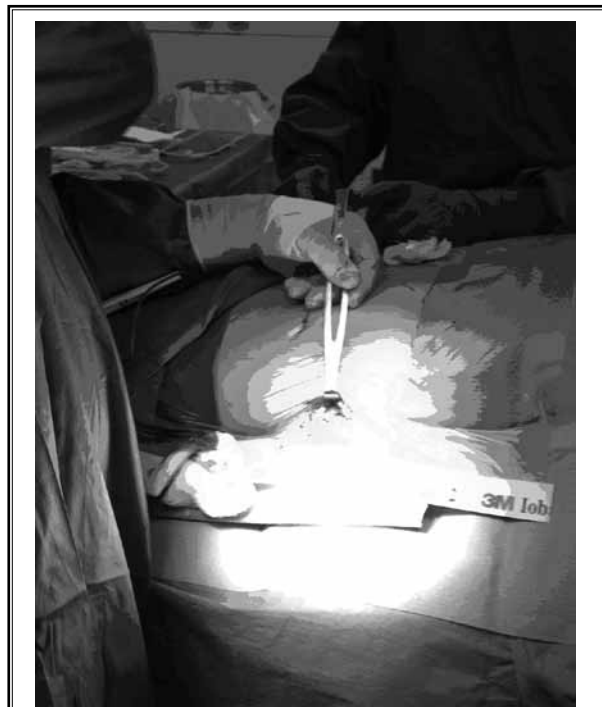

Fig. 4. Incision site.

to execute her activities of daily living with more ease. She can ride in a car for 3 hours with little to no pain, clean her house with little to no pain, and she is able to sleep better with less medication. Three months after surgery, stimulator settings were as follows: DC lead – virtual guarded cathodes (electrodes 3, 4) were set at 3.8 ma, 680 pw, and 30 hz; right TAP lead – 2 anodes (electrodes 5, 6) and 2 cathodes (electrodes 3, 4) were set at 1.4 ma, 330 pw, and 40 hz; and left TAP lead – one anode (electrode 6) and one cathode (electrode 3) were

set at 1.1 ma, 330 pw, and 40 hz. She was using both the dorsal column and peripheral leads.

### **CONCLUSION**

Management of chronic abdominal pain is challenging, as sometimes medical management and nerve blocks fail to provide adequate long-term relief. We report a technique in which abdominal pain can be effectively managed by neuromodulation of the nerves T6-L1 in the transverse abdominis plane.

---

### **REFERENCES**

1. Rafi AN. Abdominal field block: A new approach via the lumbar triangle. *Anaesthesia* 2001; 56:1024-1026.
2. Petersen PL, Mathiesen O, Torup H, Dahl JB. The transversus abdominis plane block: A valuable option for post-operative analgesia? A topical review. *Acta Anaesthesiol Scand* 2010; 54:529-535.
3. Siddiqui MR, Sajid MS, Uncles DR, Cheek L, Baig MK. A meta-analysis on the clinical effectiveness of transversus abdominis plane block. *J Clin Anesth* 2011; 23:7-14.
4. McDonnell JG, Curley G, Carney J, Benton A, Costello J, Maharaj CH, Laffey JG. The analgesic efficacy of transversus abdominis plane block after cesarean delivery: A randomized controlled trial. *Anesth Analg* 2008; 106:186-191; table of contents.
5. McDonnell JG, O'Donnell B, Curley G, Heffernan A, Power C, Laffey JG. The analgesic efficacy of transversus abdominis plane block after abdominal surgery: A prospective randomized controlled trial. *Anesth Analg* 2007; 104:193-197.
6. Aveline C, Le Hetet H, Le Roux A, Vautier P, Cognet F, Vinet E, Tison C, Bonnet F. Comparison between ultrasound-guided transversus abdominis plane and conventional ilioinguinal/iliohypogastric nerve blocks for day-case open inguinal hernia repair. *Br J Anaesth* 2011; 106:380-386.