

Retrospective Analysis

Optimal Needle Entry Angle for Cervical Transforaminal Epidural Injections

Boqing Chen, MD, PhD, Leia Rispoli, MSIV, Todd P. Stitik, MD, Patrick M. Foye, MD, and John S. Georgy, MD,

From: Department of Physical
Medicine and Rehabilitation
Rutgers - New Jersey Medical
School, Newark, NJ

Address Correspondence:
Boqing Chen, MD, PhD
Department of Physical Medicine
and Rehabilitation
Rutgers - New Jersey Medical
School
90 Bergen Street, DOC-3100,
Newark, NJ 07103-2499
E-mail:
Boqing_Chen@yahoo.com

Disclaimer: There was no
external funding in the
preparation of this manuscript.
Conflict of interest: Each author
certifies that he or she, or a
member of his or her immediate
family, has no commercial
association (i.e., consultancies,
stock ownership, equity interest,
patent/licensing arrangements,
etc.) that might pose a conflict of
interest in connection with the
submitted manuscript.

Manuscript received: 07-22-2013
Revised manuscript received:
11-27-2013
Accepted for publication:
12-18-2013

Free full manuscript:
www.painphysicianjournal.com

Background: Cervical epidural steroid injections can be performed through either interlaminar or transforaminal approaches, although the interlaminar approach is more frequently used, for cervical radicular pain as a result of cervical disc herniation or spinal stenosis. Cervical selective nerve root block (CSNRB) is an injection that uses a similar approach to that of cervical transforaminal epidural steroid injection (CTFESI) but CSNRB is mainly used for diagnostic injection, often with local anesthetic only.

Objective: The aim of this study was to investigate an optimal needle entry angle for cervical transforaminal epidural steroid injection (CTFESI) or cervical selective nerve root block (CSNRB) using the fluoroscopically guided anterior oblique approach. The angle for optimal entry into the neuroforamen was measured at various vertebral levels using cross-sectional cervical spine computed tomography (CT) scans.

Study Design: Retrospective case series analysis.

Methods: From March 2009 to July 2012, consecutive patients with presumed discogenic neck pain underwent cervical post discography CT scans. The axial images of these CT scans were used to measure the optimal angle for needle entry into the neuroforamen. The angles were taken bilaterally at levels of C3-4, C4-5, C5-6, C6-7, and C7-T1. The average angle between the patient's left and right side was calculated. A total of 190 patients were analyzed, including 73 men and 117 women, with ages ranging from 21 to 78 years old.

Results: In both men and women, the mean optimal angle (in degrees) with standard deviation measured in the 190 patients at C3-4, C4-5, C5-6, C6-7, and C7-T1 were 48 ± 4 , 49 ± 4 , 49 ± 4 , 49 ± 5 , 48 ± 6 , respectively. The 95% confidence interval for the true value of the parameter is within 39.84 to 57.56 degrees.

Limitations: The data for the optimal needle entry angle for CTFESI has yet to be tested or confirmed in clinical studies.

Conclusion: This is the first study investigating the optimal needle entry angle for performing CTFESIs or CSNRB. Based on a patient population of 190, the optimal entry angle using the anterior oblique approach appears to be between the range of 33 to 68 degrees with an average of slightly less than 50 degrees. Further research with angle of needle entry and/or initial fluoroscopic alignment of approximately 50 degrees in CTFESI or CSNRB is warranted to confirm the usefulness of these findings.

Key words: Pain medicine, transforaminal, cervical, epidural, cervical selective nerve root block, cervical disc herniation, interlaminar, neck pain, vertebral artery, radiculomedullary artery

Pain Physician 2014; 17:139-144

Cervical epidural steroid injections can be performed through either interlaminar or transforaminal approaches, although the interlaminar approach is more frequently used, for cervical radicular pain as a result of cervical disc herniation or spinal stenosis (1-6). Cervical selective nerve root block (CSNRB) is an injection that uses a similar approach to that of cervical transforaminal epidural steroid injection (CTFESI) but CSNRB is mainly used for diagnostic injection, often with local anesthetic only.

Cervical interlaminar epidural steroid injection (CIESI) was shown to be efficacious in reducing neck pain and radicular pain in randomized clinical trials and systematic reviews (1-3). Meanwhile, the efficacy of CTFESI is less convincing due to a sub-optimally designed randomized study (7); but multiple prospective studies indicated that CIESI are effective in reducing radicular neck pain and the need for surgery (8-10). There is no prospective randomized clinical trial comparing the efficacy of CIESI with CTFESI or CSNRB.

CTFESI and CSNRB have been associated with rare but serious neurological complications (11-22). The catastrophic neurological complications such as paralysis and death are thought to be the results of unintentional needle cannulation and injection of particulate corticosteroids into the vertebral artery or radiculomedullary artery, inducing embolic infarction in the terminal arterioles supplying the spinal cord, brainstem, and cerebrum (11-22). Cervical interlaminar epidural injections also carry infrequent risks such as dural puncture and epidural hematoma injury of the spinal cord resulting in paralysis.

Despite the uncertainty of the efficacy of CTFESI and CSNRB, a study of epidural steroid injections on Medicare beneficiaries from 2000 to 2011 demonstrated a 142% increase in the performance of cervical/thoracic transforaminal epidural injections (23). Therefore, proper techniques of needle placement in the posterior bony wall of the cervical neuroforamen to avoid the needle penetration of the vertebral artery are important to improve the safety of CTFESI or CSNRB.

In the cervical spine, the techniques for CTFESI and CSNRB have been described, yet no studies have been performed regarding the optimal needle entry angle. The objective of this study is to investigate the orientation and angles of the posterior bony wall of the cervical neuroforamina in the supine position. It is evident that if the needle is introduced in an angle that is parallel to and eventually touches the poste-

rior wall of neuroforamen, the chance of the needle encountering the vertebral artery while performing CTFESIs or CSNRBs may be avoided or minimized, which may increase the safety of CTFESI and CSNRB (9). However, it is important to note that this needle location can still encounter the spinal radicular artery (18,24,25).

METHODS

Study Design

This was a retrospective case series analysis. The protocol for this study was approved by the institutional review board.

Patients

From March 2009 to July 2012, a total of 190 consecutive patients underwent computed tomography (CT) scans of the cervical spine. The axial sections of these scans were used to measure the potential optimal angle for needle entry into the neuroforamen. The patients' ages ranged from 21 to 78; a total of 190 patients were analyzed (73 men and 117 women).

Measurements

Data were collected by measuring angles from the axial sections of cervical post-discography CT scans from C3-4 through C7-T1 levels. The axial sections traversing the intervertebral disc (IVD) and the upper third of the superior articular process (SAP) were chosen to reflect the fact that the needle tip during a transforaminal epidural injection should be located in the middle aspect (level of IVD) of the posterior bony wall (upper portion of SAP) of the neuroforamen. The angles on the axial sections of 190 CT scans were measured using engineering software. One line was drawn along the inner surface of the posterior wall of the neuroforamen. The other line bisected the vertebra and spinous process of the same vertebral segment (Fig. 1). The angle between the 2 arms formed represents the potential optimal needle entry angle, or the obliquity of ipsilateral rotation of the fluoroscope during the cervical transforaminal epidural injection. The needle entering the neuroforamen obliquely along the arm of this angle should land immediately anterior to the posterior bony wall of the neuroforamen. The structures anterior to the needle are the exiting cervical spinal nerve and/or dorsal root ganglion and the vertebral artery. The angle was measured at the C3-4, C4-5, C5-6, C6-7, and C7-T1 levels bilaterally, and

each average between the 2 sides was used as a data point.

RESULTS

The mean optimal angle (in degrees) measured in the 190 patients (with standard deviation) at C3-4, C4-5, C5-6, C6-7, and C7-T1 were the following: 48 ± 4 , 49 ± 4 , 49 ± 4 , 49 ± 5 , and 48 ± 6 , respectively (Fig. 2). In the 73 men (average age 44 ± 10), the optimal angles measured at C3-4, C4-5, C5-6, C6-7, and C7-T1 were the following: 48 ± 4 , 49 ± 4 , 49 ± 4 , 49 ± 4 , and 48 ± 6 , respectively (Fig. 3). In the 117 women (average age 44 ± 10), the optimal angle measured at C3-4, C4-5, C5-6, C6-7, and C7-T1 were the following: 48 ± 4 , 49 ± 4 , 50 ± 4 , 49 ± 4 , and 48 ± 5 , respectively (Fig. 4).

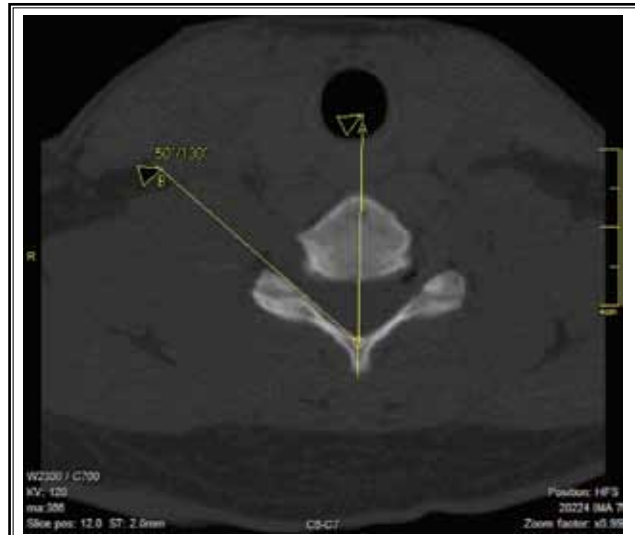

Fig. 1. CT scan showing lines used to measure optimal angle of entry at vertebral/foraminal level.

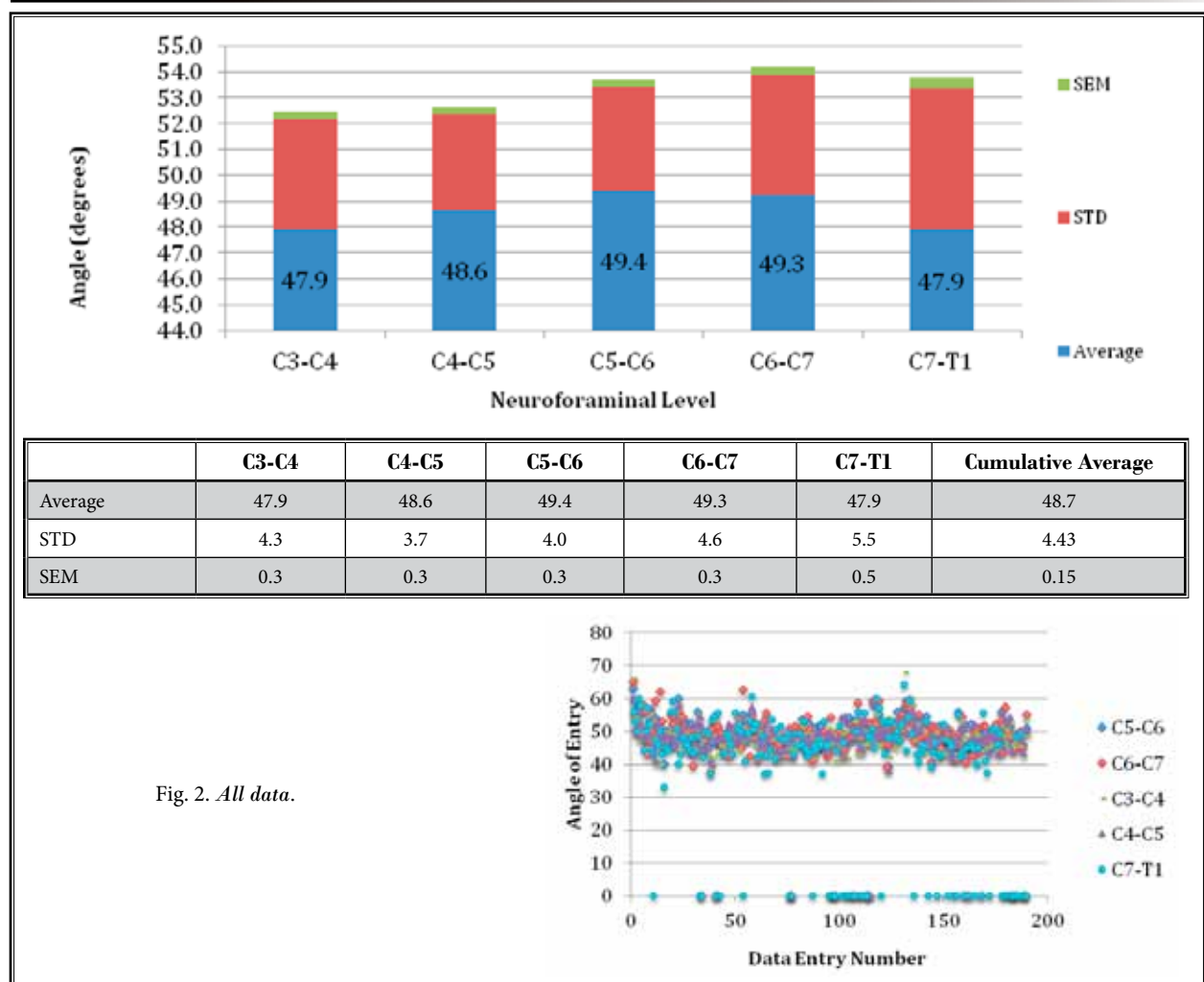
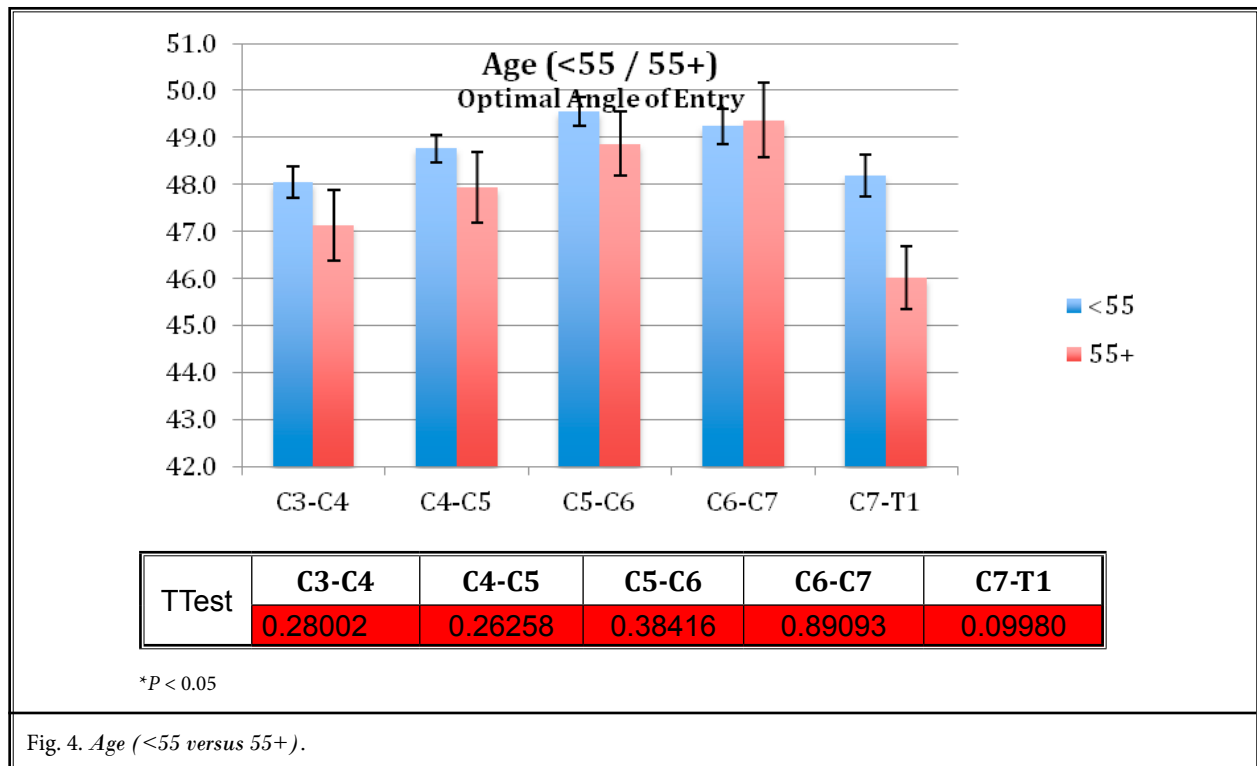
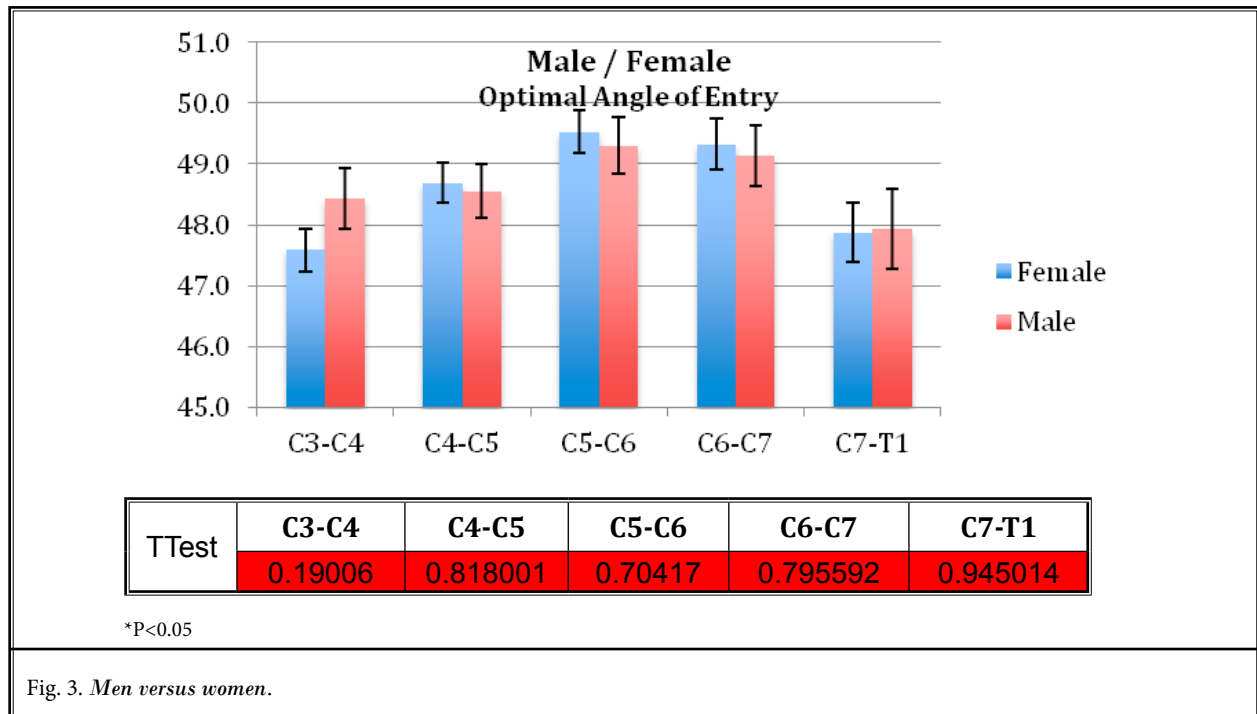


Fig. 2. All data.



DISCUSSION

This is the first study measuring the angles of orientation of the cervical neuroforamina and thus inferred needle entry angles for CTESIs or CSNRBs performed via the anterior lateral approach in order to optimize safety.

The 190 patients analyzed in this study displayed minimal variation between cervical vertebral levels, with averages ranging from 47.9 to 49.4 degrees (standard deviation range 3.7 to 5.5).

There is 95% confidence that the true value of the parameter is within the interval of 39.84 to 57.56 degrees. It is important to note that this is reference data and does not represent the entire population, but certainly provides an estimate.

The average angles between men and women were statistically significant but not clinically significant as the difference of the angle was relatively small (difference of 49.4 vs. 47.9 i.e., only 1.5 degrees). In clinical practice, it is difficult to discern the angle with a difference of only 1.5 degrees. Similarly, when comparing the average angles between age groups below 55 and above 55 years of age, there was also a difference that was statistically significant but not clinically significant.

From the data of this study, the optimal entry angle for CTESI or CSNRB using the anterior oblique approach appears to lie in the range of slightly less than 50 degrees (cumulative average angle of 48.7 degrees). Although there are many approaches to CTESIs, the data from our study suggested that this procedure should be performed under fluoroscopic guidance aligning the image at approximately 50 degrees using an anterior oblique approach and then moving the c-Arm back and forth slightly until optimal visualization of the foramen is seen. This position allows the needle tip to stay away from the vertebral vessels yet remain adjacent to the exiting nerve root (26). This angle represents the posterior aspect of the neuroforamen, where the entry needle tip during CTESI and CSNRB would lie. Specifically, the needle at this angle would be expected to lie directly anterior to the surface of posterior bony wall of neuroforamen formed by the superior articular facet. The needle tip in this position of the neuroforamen

is posterior to the cervical nerve root or dorsal root ganglion and the vertebral artery. By maintaining the needle tip against the posterior bony wall and away from these vital structures, the likelihood of unintentional needle injury to the spinal nerve root or dorsal root ganglion and needle entry into the vertebral artery causing dissection may be avoided or significantly reduced. However, a recent study has revealed location variations with up to 29% of vertebral arteries within 2 mm of the posterior wall in the neuroforamen (27). Therefore, the axial sections of cervical spine magnetic resonance imaging (MRI) or CT scans should be evaluated for the exact location of vertebral artery before the CTESI or CSNRB to avoid needle penetration.

It is important to note that the optimal angle targeting the posterior bony wall of the foramen aims to avoid major structures, mainly the vertebral artery and its adjacent exiting spinal nerves. The angle does not aim to avoid cannulation of, or injection into, the radiculomedullary arteries in the neuroforamen. Recent studies have investigated the variability of arterial anatomy in the cervical spine amongst patients, presenting additional concern for injuring the ascending and deep cervical arteries (24,25). These arteries either anastomose with the vertebral artery or supply the segmental radiculomedullary branches to the anterior spinal artery. Occlusion of the segmental medullary arteries that give rise to the anterior spinal artery has been shown to result in the devastating anterior spinal artery syndrome (28). Therefore, other techniques such as applying real time fluoroscopic guidance with contrast enhancement, digital subtraction angiography (DSA) (29), test doses of local anesthetic (30), and non-particulate corticosteroids (19,31-33) are tools to decrease the likelihood of such devastating complications (34,35).

CONCLUSION

Further research prospectively using oblique angle needle entry in CTESI or CSNRB is warranted to confirm the usefulness of the 50 degree oblique angle as the optimal angle for needle entry and/or initial fluoroscopic alignment.

REFERENCES

1. Manchikanti L, Cash KA, Pampati V, Wargo BW, Malla Y. A randomized, double-blind, active control trial of fluoroscopic cervical interlaminar epidural injections in chronic pain of cervical disc herniation: Results of a 2-year follow-up. *Pain Physician* 2013; 16: 465-478.
2. Diwan S, Manchikanti L, Benyamin RM, Bryce DA, Geffert S, Hameed H, Sharma ML, Abdi S, Falco FJ. Effectiveness of cervical epidural injections in the management of chronic neck and upper extremity pain. *Pain Physician* 2012; 15:E405-434.
3. Benyamin RM, Singh V, Parr AT, Conn A, Diwan S, Abdi S. Systematic review of the effectiveness of cervical epidurals in the management of chronic neck pain. *Pain Physician* 2009; 12:137-157.

4. Candido KD, Knezevic N. Cervical epidural steroid injections for the treatment of cervical spinal (neck) pain. *Curr Pain Headache Rep* 2013; 17:314.
5. Bicket MC, Gupta A, Brown CH 4th, Cohen SP. Epidural injections for spinal pain: A systematic review and meta-analysis evaluating the "control" injections in randomized controlled trials. *Anesthesiology* 2013; 119:907-931.
6. Smuck M, Demirjian R, Kennedy DJ. Cervical foraminal versus interlaminar epidurals: Risks, benefits, and alternatives. *Curr Phys Med Rehabil Rep* 2013; 1:125-134.
7. Anderberg L, Annertz M, Persson L, Brandt L, Saveland H. Transforaminal steroid injections for the treatment of cervical radiculopathy: A prospective and randomised study. *Eur Spine J* 2007; 16:321-328.
8. Stav A, Ovadia L, Sternberg A, Kaadan M, Weksler N. Cervical epidural steroid injection for cervicobrachialgia. *Acta Anaesthesiol Scand* 1993; 37:562-566.
9. Bush K, Hillier S. Outcome of cervical radiculopathy treated with periradicular/epidural corticosteroid injections: A prospective study with independent clinical review. *Eur Spine J* 1996; 5:319-325.
10. Vallee JN, Feydy A, Carlier RY, Mutschler C, Mompoin D, Vallee CA. Chronic cervical radiculopathy: Lateral-approach periradicular corticosteroid injection. *Radiology* 2001; 218:886-892.
11. Scanlon GC, Moeller-Bertram T, Romanowsky SM, Wallace MS. Cervical transforaminal epidural steroid injections: More dangerous than we think? *Spine (Phila Pa 1976)* 2007; 32:1249-1256.
12. Rozin L, Rozin R, Koehler SA, Shakir A, Latham S, Barmada M, Dominick J, Wecht CH. Death during transforaminal epidural steroid nerve root block (C7) due to perforation of the left vertebral artery. *Am J Forensic Med Pathol* 2003; 24:351-355.
13. Ruppen W, Hugli R, Reuss S, Aeschbach A, Urwyler A. Neurological symptoms after cervical transforaminal injection with steroids in a patient with hypoplasia of the vertebral artery. *Acta Anaesthesiol Scand* 2008; 52:165-166.
14. Lee JH, Lee JK, Seo BR, Moon SJ, Kim JH, Kim SH. Spinal cord injury produced by direct damage during cervical transforaminal epidural injection. *Reg Anesth* 2008; 33:377-379.
15. Muro K, O'Shaughnessy B, Ganju A. Infarction of the cervical spinal cord following multilevel transforaminal epidural steroid injection: Case report and review of the literature. *J Spinal Cord Med* 2007; 30:385-388.
16. Derby R, Lee SH, Kim BJ, Chen Y, Seo KS. Complications following cervical epidural steroid injections by expert interventionalists in 2003. *Pain Physician* 2004; 7:445-449.
17. Ludwig MA, Burns SP. Spinal cord infarction following cervical transforaminal epidural injection: A case report. *Spine (Phila Pa 1976)* 2005; 30:E266-268.
18. Baker R, Dreyfuss P, Mercer S, Bogduk N. Cervical transforaminal injection of corticosteroids into a radicular artery: A possible mechanism for spinal cord injury. *Pain* 2003; 103:211-215.
19. Tiso RL, Cutler T, Catania JA, Whalen K. Adverse central nervous system sequelae after selective transforaminal block: The role of corticosteroids. *Spine J* 2004; 4:468-474.
20. Karasek M, Bogduk N. Temporary neurologic deficit after cervical transforaminal injection of local anesthetic. *Pain Med* 2004; 5:202-205.
21. Rathmell JR, Aprill C, Bogduk N. Cervical transforaminal injection of steroids. *Anesthesiology* 2004; 100:1595-1600.
22. Bogduk N, Dreyfuss P, Baker R. Complications of spinal diagnostic and treatment procedures. *Pain* 2008; 9:S11-S34.
23. Manchikanti L, Pampati V, Falco FJ, Hirsch JA. Assessment of the growth of epidural injections in the Medicare population from 2000 to 2011. *Pain Physician* 2013; 16:E349-E364.
24. Huntoon MA. Anatomy of the cervical intervertebral foramina: Vulnerable arteries and ischemic neurologic injuries after transforaminal epidural injections. *Pain* 2005; 117:104-111.
24. Hoeft MA, Rathmell JP, Monsey RD, Fonda BJ. Cervical transforaminal injection and the radicular artery: Variation in anatomical location within the cervical intervertebral foramina. *Reg Anesth* 2006; 31:270-274.
25. Ma DJ, Gilula LA, Riew KD. Complications of fluoroscopically guided extraforaminal cervical nerve blocks. An analysis of 1036 injections. *J Bone Joint Surg Am* 2005; 87:1025-1030.
26. Beckworth WJ, Sood R, Katzer AF, Wu B. Anomalous location of the vertebral artery in relation to the neural foramen. Implications for cervical transforaminal epidural steroid injections. *Pain Med* 2013; 14:1119-1125.
27. Huston CW. Cervical epidural steroid injections in the management of cervical radiculitis: Interlaminar versus transforaminal. A review. *Curr Rev Musculoskelet Med* 2009; 2:30-42.
28. McLean JP, Sigler JD, Plastaras CT, Garvan CW, Rittenberg JD. The rate of detection of intravascular injection in cervical transforaminal epidural steroid injections with and without digital subtraction angiography. *PMR* 2009; 1:636-642.
29. Karasek M, Bogduk N. Temporary neurologic deficit after cervical transforaminal injection of local anesthetic. *Pain Med* 2004; 5:202-205.
30. Derby R, Lee SH, Date ES, Lee JH, Lee CH. Size and aggregation of corticosteroids used for epidural injections. *Pain Med* 2008; 9:227-234.
31. Okubadejo GO, Talcott MR, Schmidt RE, Sharma A, Patel AA, Mackey RB, Guarino AH, Moran CJ, Riew KD. Perils of intravascular methylprednisolone injection into the vertebral artery: An animal study. *J Bone Joint Surg Am* 2008; 90:1932-1938.
32. Dreyfuss P, Baker R, Bogduk N. Comparative effectiveness of cervical transforaminal injections with particulate and nonparticulate corticosteroid preparations for cervical radicular pain. *Pain Med* 2006; 7:237-242.
33. Rathmell JR, Aprill C, Bogduk N. Cervical transforaminal injection of steroids. *Anesthesiology* 2004; 100:1595-1600.
34. Bogduk N, Dreyfuss P, Baker R. Complications of spinal diagnostic and treatment procedures. *Pain Med* 2008; 9:S11-34.