

Case Report

Jose De Andres, MD, PhD, Miguel J. Esparza, MD, Jose Ferrer-Rebolleda, MD, Ascension Castillo-Ruiz, MD, and Vicente Villanueva-Perez, MD

From: Anesthesia, Critical Care, and Multidisciplinary Pain Management Department, General University Hospital, Valencia, Spain

Dr. DeAndres is Professor of Anesthesiology, Valencia University Medical School. Chairman of the Anesthesia Department and Director of the Multidisciplinary Pain Management Department. Valencia University General Hospital. Dr. Esparza is a 4th year Resident in Training for the Department of Anesthesia. Multidisciplinary Pain Management Department. Valencia University General Hospital. Dr. Ferrer-Rebolleda is Chairman Nuclear Medicine Department. Valencia University General Hospital. Dr. Castillo-Ruiz is with the Neurology Department. Valencia University General Hospital. Dr. Villanueva-Perez is with the Multidisciplinary Pain Management Department, Department of Anesthesia, General University Hospital.

Address Correspondence:
Dr. Jose De Andres
Anesthesia, Critical Care, and Multidisciplinary Pain Management Department
General University Hospital
Avda. Tres Cruces s/n
46014 – Valencia (Spain)
E-mail: deandres_jos@gva.es

Disclaimer: See Page E93.

Manuscript received: 07-25-2013
Revised manuscript received: 08-31-2013
Accepted for publication: 09-11-2013

Free full manuscript:
www.painphysicianjournal.com

Background: Spontaneous intracranial hypotension (SIH) and related headache after intrathecal pump implantation is a possibility. Knowing the exact location of the cerebrospinal fluid (CSF) leak is mandatory for managing with interventional therapies.

Objectives: Radioisotope cisternography (RICG) is a common procedure in nuclear medicine and may be used as an additional procedure in the differential diagnosis of headaches due to intracranial liquor hypotension syndrome caused by microleakage of CSF.

Study Design: We report an imaging case of complex chronic headache in a patient with an implanted drug delivery pump. The symptomatology of the patient was considered typical of spontaneous intracranial hypotension (SIH). Therefore, the initial suspicion was the loss of CSF due to the implanted pump catheter. The negativity of the routine headache test can exclude any leakage of CSF at the site of catheter insertion.

Setting: Anesthesia, Critical Care, and Multidisciplinary Pain Management Department, General University General Hospital, Valencia, Spain.

Results: Many patients are treated with implanted intrathecal infusion systems. In these patients, any neurological symptoms are readily attributed to the invasive neuroaxial system, especially severe cephalalgia. RICG was helpful in this particular case to make a diagnosis of exclusion of the diagnosis of SIH due to CSF leakage.

Conclusion: RICG may be considered as an additional diagnostic technique in patients with chronic pain and implanted spinal infusion devices for whom standard detection procedures have been exhausted.

Key words: Intrathecal drug delivery (IDD), chronic headache (CH), radioisotope cisternography (RICG), cerebrospinal fluid leakage, spontaneous intracranial hypotension (SIH)

Pain Physician 2014; 17:E89-E94

Spontaneous intracranial hypotension (SIH) is an uncommon condition caused by cerebrospinal fluid (CSF) leakage, with resultant CSF hypovolemia and intracranial hypotension. Although in some patients SIH may be preceded by minor trauma, it often occurs in the absence of any identifiable initiating event (1). In patients with chronic pain, bearing a

spinal infusion pump, the presence of headache is correlated, in many cases, and as a primary factor, with the presence of the catheter at the spinal level and the possibility of leakage of CSF. In a very recent paper published by Neuman et al (2), the incidence of post-dural puncture headache (PDPH) after intrathecal drug delivery system (IDDS) implantation was 23%, the

majority of these patients had self-limited symptoms that resolved with conservative medical management, but some were refractory to conservative measures.

Knowing the exact location of CSF leak is mandatory for managing with interventional therapies. It can be evidenced by non-invasive methods, such as magnetic resonance imaging (MRI) and computed tomography (CT) scans (3), or more invasive techniques such as MR myelography (4), radioisotope cisternography (RICG) (5-7), or single photon emission computed tomography (SPECT/CT) Fusion Imaging by RICG (8). The effectiveness of non-invasive procedures in the diagnosis of CSF leaks does have limited value, as it does not usually show alterations in spinal structures, and only occasionally can subdural fluid collections be seen. CSF loss must be compensated by hyperemic venous return, appearing as diffuse pachymeningeal enhancement on gadolinium-enhanced MRI scans, whereas no significant changes are seen on non-gadolinium MRI.

RICG is a common procedure in nuclear medicine for differential diagnosis of hydrocephalus and diagnosis of patency of surgical shunts (9). Also, RICG may be used as an additional procedure in the differential diagnosis of headaches due to SIH caused by microleakage of CSF. In this context, RICG provides relevant physiological information to establish the CSF leak site in SIH (9).

Our objective is to present the role of RICG in determining the cause of headache in patients with severe chronic pain bearing an IDD infusion pump.

CASE REPORT

Our case report is based on a 36-year-old woman who was referred to the pain management department, from the neurology department, with a diagnosis of multiple sclerosis (MS) with related spasticity. She was subsequently included in a chronic spinal baclofen infusion protocol, implanting a SynchroMed II™ 8731SC/40 infusion pump (Medtronic Inc., Minneapolis, MN), with the level of the meningeal puncture at L2L3, inserting radiopaque silicone rubber subarachnoid catheter model 8731SC™, outer diameter 1.4 mm (4.2 French) (Medtronic Inc., Minneapolis, MN), placing the tip at T12-L1.

Six years after implantation of the infusion pump, the patient presented with severe exertion-related headache. She described the pain as being pounding, diffuse, and associated with nausea, vomiting, dizziness, and diplopia or blurred vision in the most severe instances. A CSF leak was suspected to have occurred

as a consequence of the catheter implanted infusion system.

When she had her medical history collected, the patient reported having been involved in a road traffic accident during the previous year and attributed her present clinical symptoms to that (10). According to our standard of care (11), a routine plain x-ray AP and lateral (Fig. 1 A and B) and lumbar MRI scan were performed to visualize the subarachnoid access point of the spinal infusion catheter. The catheter was shown in the same position as in the patient's post-implant follow-up scan; the dura mater was shown to be correctly sealed around the catheter; and the presence of an extradural CSF collection suggestive of a fistula was excluded.

The patient was prescribed a medical regimen for symptomatic headache treatment without improvement.

A cranial MRI scan was performed to assess for organic disease, and a pineal mass was found. The case was reviewed by a neurosurgeon who concluded that the headache was not caused by this tumor as it exerted no mass effect and no hydrocephalus was present.

After consultation with the neuroradiology and nuclear medicine departments, it was decided that a RICG would be performed with lumbar puncture and administration of intrathecal isotopes to exclude microleakage of CSF. We needed to consult the manufacturer of the intrathecal infusion pump, Medtronic Inc. (Minneapolis, MN, USA), about the feasibility of a procedure, as no relevant information was found on the product label or in the medical literature. The company responded that there would be no specific technical impediments to the procedure. With the patient in the left lateral recumbent position, an intradural puncture was performed under radioscopic guidance below the implanted intrathecal catheter, using a Spinocan® 27G needle (B. Braun Medical S.A., Rubí, Spain), 0.5 mL of indium-111-labeled diethylene triamine pentaacetic acid (¹¹¹In-DTPA) solution was injected (DTPA Covidien sol. iny., Covidien, Sant Joan Despi, Spain). A sample of CSF was taken for analysis, and subsequent results showed the protein content in the normal range.

Following this, the patient was placed in the supine position and planar imaging scans of the brain and spine were taken at one hour (Fig. 2A), 4 hours, and 24 hours (Fig. 2B) post-injection. Adequate distribution was observed in the spinal canal and lateral ventricles, with no areas of tracer uptake outside these regions that would point to leakage of CSF. Similarly, no leakage was seen

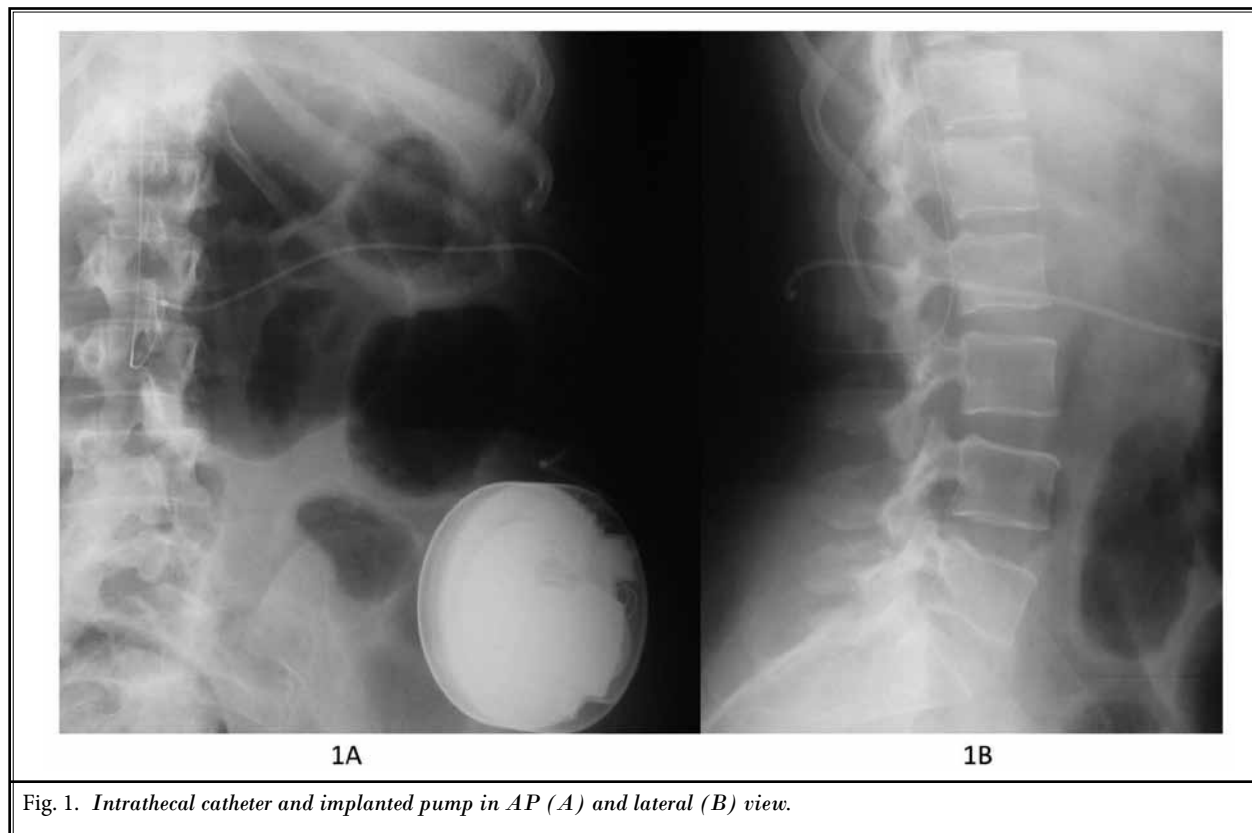


Fig. 1. Intrathecal catheter and implanted pump in AP (A) and lateral (B) view.

around the insertion area of the subarachnoid catheter or in the puncture site of the present procedure.

In light of the negative results, we ruled out a diagnosis of headache associated with intracranial hypotension due to CSF leakage. The patient was instead diagnosed with chronic headache secondary to the referred head and neck trauma, and continued to receive medical treatment with trazodone and verapamil. When this diagnostic procedure was completed, the patient was discharged from our pain clinic. She continued to receive follow-up for her headaches at the neurology department and periodic assessments for her pineal tumor at neurosurgery.

Discussion

The first step in the diagnosis of cephalalgia is to identify it among the various types of headaches that constitute specific disease entities (primary headaches) as opposed to those that are symptoms of other diseases (secondary headaches). At this stage, detailed and accurate collection of the patient's case history, following a structured interview, can be sufficient to establish an exact diagnosis of the type of headache (12).

Headache associated with SIH is characterized by decreased CSF pressure and orthostatic cephalalgia, which may be primary and spontaneous or secondary to other conditions. Primary CSF hypotension patients usually refer to a small trauma or physical strain, whereas the most common cause for secondary cases is dural puncture. Other causes include CSF fistulas due to meningeal rupture, expansive growths, or even excessive drainage of a shunt valve (12). In all of these cases, the clinical manifestations are similar. The headache begins in the occipital region and spreads toward the frontal-temporal regions, and is triggered or exacerbated by sitting up or standing and relieved by lying down. In the most severe cases, headaches are associated with stiffness of the neck, nausea, vomiting, dizziness, and tinnitus (13).

Spontaneous SIH is a poorly understood entity that may result from an occult CSF leak, but some posit that SIH is caused by venous hypotension that results in increased CSF absorption (14). Leaks can occur at dural root sleeves throughout the spine and may be a potential mechanism for orthostatic headache following motor vehicle accidents (10,15).

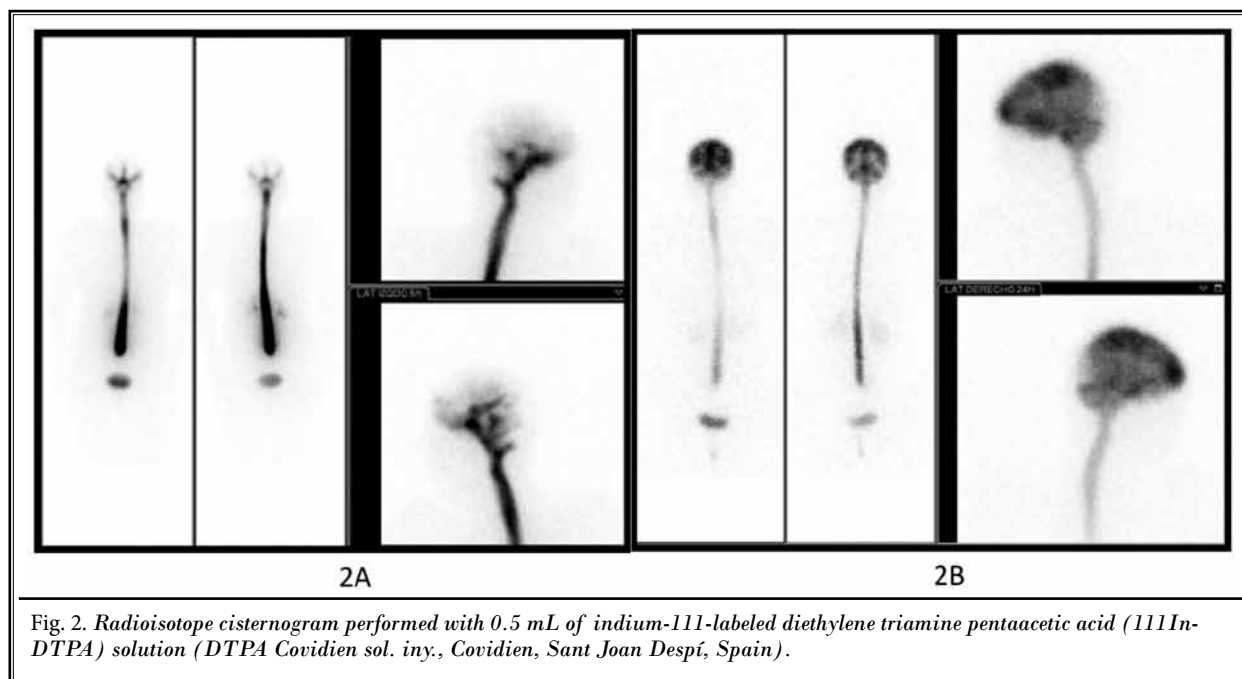


Fig. 2. Radioisotope cisternogram performed with 0.5 mL of indium-111-labeled diethylene triamine pentaacetic acid ($^{111}\text{In-DTPA}$) solution (*DTPA Covidien sol. iny.*, Covidien, Sant Joan Despí, Spain).

Today many chronic pain patients are treated with implanted intrathecal infusion systems. In these patients, such as ours, neurological symptoms, especially severe cephalalgia, are readily attributed to the invasive neuroaxial system. Leakage of the CSF through the orifice by which the catheter is connected to the intradural space is an uncommon complication and may initially develop as a predominantly occipital, pounding headache that is worsened by standing and exertion. Therefore, such cases may be mistaken for headaches occurring following dural puncture. The standard imaging procedure to rule out these complications is MRI. Findings to be assessed on MRI include brain descent, changes in the size of the subarachnoid cisterns and intracerebral ventricles, enlargement of the cranial meninges and presence or absence of clusters of subdural hygromas or hematomas, changes in the size of the pituitary gland, and changes in the spinal cord. Slight meningeal enhancement is sometimes seen (14), but this finding has very limited sensitivity to detect micro-leaks (13).

In our department we apply a very strict protocol in the follow-up of patients with post-dural puncture headache (16), and more specifically in patients with IDDS on which epidural fibrin glue is used as a conservative treatment (17), if persistent CSF leakage is detected after spinal catheterization (18).

In accordance with previous published papers

(19,20), RICG is useful for detecting CSF leakage in SIH patients. The radiopharmaceutical used in RICG must follow the CSF flow without affecting its dynamics; it must be then reabsorbed quickly into the arachnoid villi. The chelating agent, diethylene triamine pentaacetic acid (DTPA), is ideal for these purposes. DTPA shows no metabolism or absorption along the ependyma before reaching the arachnoid villi and it has low lipid solubility. Indium-111-labeled DTPA is the agent of choice because of its long half life (67 hours) and its good imaging characteristics (8). Within one hour, the substance reaches the basal cisterns. The frontal poles and the Sylvian fissure are reached within 2 to 6 hours. The cerebral convexities are reached within 12 hours and the arachnoid villi in the sagittal sinus are reached at 24 hours. The radiopharmaceutical does not usually enter the ventricular system because CSF flows physiologically in the opposite direction.

Recently Bonetto et al (21) suggested spinal MRI with dedicated subtraction analysis could represent a useful diagnostic tool in the management of patients with SIH, thus leaving invasive investigation for selected patients, such those requiring dural surgery. Other imaging tests like gadolinium myelography, digital subtraction myelography, and dynamic CT myelography have been suggested in the diagnosis of SIH. Each seems to have an as-yet poorly defined role in the diagnosis of CSF leaks. A very recent publication (22) found that

MR gadolinium myelography, for example, was able to localize CSF leaks in 5 of 24 patients in whom suspected leaks were unable to be identified on CT myelography.

According Leep Hunderfund and Mokri (23), orthostatic headaches can occur without evidence of intracranial hypotension or detectable CSF leak despite extensive diagnostic testing. Among other possibilities increased compliance of the lower spinal CSF space without actual leak is presented.

In our case, RICG was preferentially chosen over other techniques like myelography and CT myelography. RICG may be useful to detect an intermittently active CSF fistula. Use of radioactive material into the spinal fluid usually localizes the CSF leak (24), being more accurate and specific in relation to the patient's clinical picture. According to Mokri (25), RICG typically shows the absence of activity over the cerebral convexities, even at 24 or 48 hours, and the early appearance of activity in the kidneys and urinary bladder, and may sometimes reveal the level of the leak. Yoo et al (7) reported a sensitivity rate of 93.3% in 15 patients. Most others have reported radioisotope cisternography to have low sensitivity (true positives divided by the sum

of true positives and false negatives) for detection of CSF leaks. Schievink et al (5), reported a study of 11 patients with proven spontaneous intracranial hypotension who had radionuclide cisternography performed, reported a 30% false negative rate. More recently, RICG detected the site of CSF leak in only 4 of 6 patients with spontaneous intracranial hypotension (6).

CONCLUSION

We believe that this case illustrates that when confirming the diagnosis of suspected SIH due to microleakage of CSF, in a chronic pain patient bearing an implanted infusion pump, RICG is an alternative diagnostic procedure to detect CSF microleaks.

DISCLAIMER

There was no external funding in the preparation of this manuscript.

Conflict of interest: Each author certifies that he or she, or a member of his or her immediate family, has no commercial association (i.e., consultancies, stock ownership, equity interest, patent/licensing arrangements, etc.) that might pose a conflict of interest in connection with the submitted manuscript.

REFERENCES

- Schwedt TJ, Dodick DW. Spontaneous intracranial hypotension. *Curr Pain Headache Rep* 2007; 11:56-61.
- Neuman SA, Eldrige JS, Qu W, Freeman ED, Hoelzer BC. Post dural puncture headache following intrathecal drug delivery system placement. *Pain Physician* 2013; 16:101-107.
- Spelle L, Boulin A, Tainturier C, Visot A, Graveleau P, Pierot L. Neuroimaging features of spontaneous intracranial hypotension. *Neuroradiology* 2001; 43:622-627.
- Jeyrani R, Paul A, Doerfler A, Egelhof T. Intracranial hypotension due to leakage of cerebrospinal fluid: Could myelography be a therapeutic option? *Neuroradiology* 2005; 47:43-45.
- Schievink WI, Meyer FB, Atkinson JL, Mokri B. Spontaneous spinal cerebrospinal fluid leaks and intracranial hypotension. *J Neurosurg* 1996; 84:598-605.
- Nowak DA, Takano B, Topka H. Spontaneous cerebrospinal fluid hypovolemia: A therapeutic dilemma? *Eur J Neurol* 2006; 13:1128-1138.
- Yoo HM, Kim SJ, Choi CG, Lee DH, Lee JH, Suh DC, Choi JW, Jeong KS, Chung SJ, Kim JS, Yun SC. Detection of CSF leak in spinal CSF leak syndrome using MR myelography: Correlation with radioisotope cisternography. *Am J Neurotrauma* 2008; 29:649-654.
- Taguchi Y, Takashima S, Konishi H, Tanaka K. SPECT/CT fusion imaging by radionuclide cisternography in intracranial hypotension. *Intern Med* 2011; 50:2433-2434.
- Ziessman HA, O'Malley JP, Thrall JH. *Nuclear Medicine: The Requisites in Radiology*. 3rd ed. Elsevier Mosby, Philadelphia, 2006. 419-450.
- Moriyama E, Terada H, Ishikawa S. Spinal cerebrospinal fluid leakage after motor vehicle accident. *Neurol Med Chir (Tokyo)* 2009; 49:306-309.
- De Andrés J, Villanueva V, Palmisani S, Cerdá-Olmedo G, López-Alarcón MD, Monsalve V, Mínguez A, Martínez-Sanjuán V. The safety of magnetic resonance imaging in patients with programmable implanted intrathecal drug delivery systems: A 3-year prospective study. *Anesth Analg* 2011; 112:1124-1129.
- Headache Classification Subcommittee of the International Headache Society. The International Classification of headache disorders. 2nd edition. *Cephalalgia* 2004; 24:9-160.
- Reina MA, Álvarez-Linera J, López A, Benito-León J, De Andrés JA, Sola RG. Magnetic resonance in dural post-puncture headache in patient with cerebrospinal fluid hypotension. *Rev Esp Anestesiol Reanim* 2002; 49:89-100 (English Abstract).
- Rahman M, Bidari SS, Quisling RG, Friedman WA. Spontaneous intracranial hypotension: Dilemmas in diagnosis. *Neurosurgery* 2011; 69:4-14.
- Ishikawa S, Yokoyama M, Mizobuchi S, Hashimoto H, Moriyama E, Morita K. Epidural blood patch therapy for chronic whiplash-associated disorder. *Anesth Analg* 2007; 105:809-814.
- García-Aguado R, Gil F, Barcia JA, Aznar J, Hostalet F, Barberá J, Grau F. Prophylactic percutaneous sealing of lumbar

- postdural puncture hole with fibrin glue to prevent cerebrospinal fluid leakage in swine. *Anesth Analg* 2000; 90:894-898.
17. De Andrés J, López-Alarcon MD, Moliner S, Cerda-Olmedo G. Repeated subarachnoid catheter displacement as a complication of spinal infusion using an internal infusion pump. *Reg Anesth Pain Med* 2000; 25:204-207.
 18. Asensio Samper JM, Fabregat Cid G, Valia-Vera JC, De Andrés JA. Epidural fibrin glue injection as a conservative treatment for persistent cerebrospinal fluid leakage after spinal catheterization. *Rev Esp Anesthesiol Reanim* 2011; 58:391-393 (English Abstract).
 19. Sugino T, et al. Intracranial hypotension due to cerebrospinal fluid leakage detected by radioisotope cisternography. *Neurol Med Chir (Tokyo)* 2000; 40:404-407.
 20. Sakurai K, Nishio M, Yamada K, Shimohira M, Ozawa Y, Matsukawa N, Oguri T, Ueki Y, Tohyama J, Yamawaki T, Shibamoto Y. Comparison of the radioisotope cisternography findings of spontaneous intracranial hypotension and iatrogenic cerebrospinal fluid leakage focusing on chronological changes. *Cephalalgia* 2012; 32:1131-1139.
 21. Bonetto N, Manara R, Citton V, Cagnin A. Spinal subtraction MRI for diagnosis of epidural leakage in SIH. *Neurology* 2011; 77:1873-1876.
 22. Akbar JJ, Luetmer PH, Schwartz KM, Hunt CH, Diehn FE, Eckel LJ. The role of MR myelography with intrathecal gadolinium in localization of spinal CSF leaks in patients with spontaneous intracranial hypotension. *AJNR Am J Neuroradiol* 2012; 33:535-540.
 23. Leep Hunderfund AN, Mokri B. Orthostatic headache without CSF leak. *Neurology* 2008; 71:1902-1906.
 24. Thomas DL, Menda Y, Graham MM. Radioisotope cisternography in detecting cerebrospinal fluid leak in spontaneous intracranial hypotension: A series of four case reports. *Clin Nucl Med* 2009; 34:410-416.
 25. Mokri B. Spontaneous intracranial hypotension. *Curr Pain Headache Rep* 2001; 5:284-291.