

Case Report

Combined Ultrasound and Fluoroscopic Guidance for Radiofrequency Ablation of the Obturator Nerve for Intractable Cancer-Associated Hip Pain

Jonathan Stone, BS, and Gerald Matchett, MD

From: UT Southwestern Medical Center, Dallas, TX

Address Correspondence:
Gerald Matchett
Anesthesiologist
UT-Southwestern Medical Center
Anesthesiology & Pain Management
5323 Harry Hines Blvd, MC 9068
Dallas, TX 75390-9068
Email: Gerald.matchett@utsouthwestern.edu

Manuscript received: 07-10-2013
Revised manuscript received:
08-08-2013
Accepted for publication: 08-13-2013

Free full manuscript:
www.painphysicianjournal.com

Management of pain from skeletal metastases is notoriously difficult. Case reports and case series have described radiofrequency ablation of the obturator nerve branches to the femoral head for treatment of intractable hip pain. Ablation of the obturator branches to the femoral head is technically difficult because of bony and vascular anatomy, including close proximity of the femoral vessels. Here we present the case of a 79-year-old woman with intractable right hip pain and inability to ambulate secondary to metastatic non-small cell lung cancer in the femoral head and acetabulum, treated with thermal radiofrequency ablation of the obturator and femoral nerve branches to the femoral head. Ablation of the obturator nerve was done via anterior placement of the radiofrequency needle under combined ultrasound and fluoroscopic guidance, passing the radiofrequency needle between the femoral artery and femoral vein. Real-time ultrasound guidance was used to avoid vascular puncture. Thermal radiofrequency ablation resulted in sustained pain relief, and resumption in the ability of the patient to ambulate. From this case we suggest that an anterior approach to the obturator nerve branches to the femoral head may be technically feasible using combined ultrasound and fluoroscopic guidance to avoid vascular puncture.

Key words: Obturator nerve, radiofrequency ablation, cancer associated pain

Pain Physician 2014; 17:E83-E87

A 79-year-old woman with a history of stage IV non-small cell lung cancer, with bone metastasis to the right femoral head and acetabulum, was admitted to the oncology service with worsening right hip pain over the preceding 2 weeks, causing the patient to be unable to walk. Prior to admission the patient had a history of a right femoral metastatic lesion based on MRI. Symptomatic treatment of this prior to admission included 5 fractions of radiation therapy, receiving 2000 cGY in total. Repeat MRI imaging shortly before admission demonstrated progressive neoplastic disease in the femoral head and acetabulum (Fig. 1). Physical examination was noteworthy for substantial pain with movement of the hip joint and a complete inability to ambulate. After

oral systemic opioid and co-analgesic medication optimization, the patient still had 10/10 pain with movement while taking sustained-release oxycodone 10 mg daily and hydrocodone/acetaminophen 10/325 every 6 hours. Further upward titration of opioid medications was not feasible because of sedation. The pain service was consulted for evaluation of nerve block therapy.

A diagnostic nerve block at the hip joint, including the lateral femoral cutaneous nerve, was performed with a combination of lidocaine 2%, 50 mcg clonidine, and 40 mg triamcinolone acetate. Following this the patient experienced 12 hours of complete pain relief and was able to ambulate. By 48 hours the patient's pain had returned.

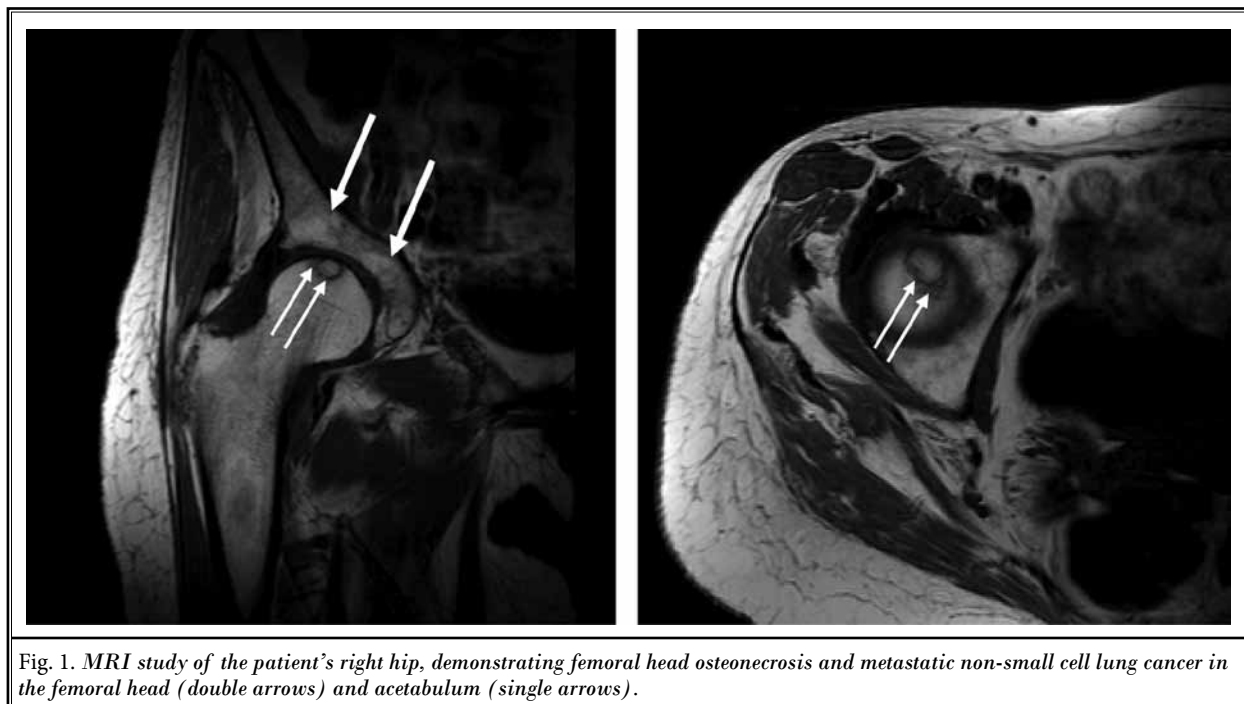

Fig. 1. MRI study of the patient's right hip, demonstrating femoral head osteonecrosis and metastatic non-small cell lung cancer in the femoral head (double arrows) and acetabulum (single arrows).

Seventy-two hours after the diagnostic block the patient received thermal radiofrequency ablation of the lateral femoral cutaneous nerve (LFCN), femoral nerve branches to the femoral head, and obturator nerve branches to the femoral head. The patient was placed in the supine position and her right hip was prepped and draped in the standard sterile manner using chlorhexidine swabs. The LFCN was identified by standard ultrasound approach, as described by Fowler et al (1) (Fig. 2). A 21 Ga radiofrequency cannula was placed in proximity to the lateral femoral nerve, resulting in sensory paresthesia at 0.7 V with no motor response. The LFCN was blocked with a combination of lidocaine 2% with triamcinalone acetate 80 mg and clonidine 50 mcg, and subsequently ablated at 80°C for 80 seconds, using a similar technique described by Fowler et al (1), although in this case using thermal ablation. The femoral nerve sensory branches to the head of the femur were blocked with the aforementioned nerve block solution and then ablated using a lateral approach described by Kawaguchi et al (2), using thermal ablation at 80°C for 80 seconds. Prior to ablation we observed a good sensory paresthesia response at 0.7 V with no motor response.

We performed radiofrequency ablation of the obturator nerve branches to the femoral head via the anterior approach, using an ultrasound probe to guide

the radiofrequency needle between the femoral artery and vein. After contacting the anterior surface of the junction of the ischium and acetabulum, we were able to achieve good sensory stimulation at 0.7 V, with obturator motor stimulation noted at 1.5 V. Contrast dye demonstrated spread along muscle planes (Fig. 3). After blocking the obturator nerve branches to the femoral head with 3 mL of the aforementioned nerve block solution, we performed thermal radiofrequency ablation at 80°C for 80 seconds. Dorsalis pedis and tibialis posterior arterial pulses were palpable both before and after the ablation.

Following the radiofrequency ablation the patient's pain remained controlled to the extent that she was able to walk again with assistance. Retrospectively we reviewed the patient's worst Visual Analogue Scale (VAS) pain score each day out of 10, and compared pre- vs post-block scores. Pre-block the daily average worst VAS was 9 + 1.2, and post-block the average daily worst VAS score was 4.1 + 3.0. She was ultimately discharged to hospice 8 days after the procedure. At the time of discharge she was taking a combination of sustained release oxycodone 10 mg twice daily and hydrocodone/acetaminophen 10/325 every 6 hours as needed for pain. At the time of discharge she was able to flex her hip to 90 degrees, and was able to ambulate with assistance.

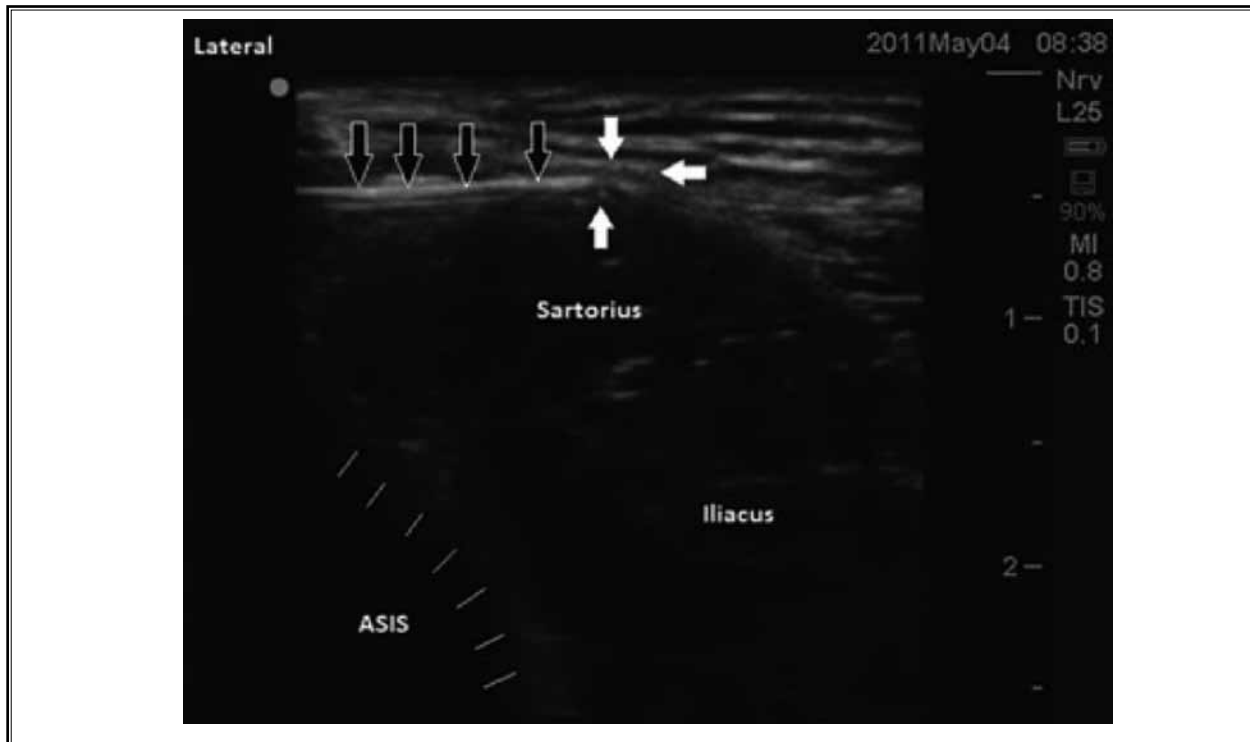


Fig. 2. Ultrasound image showing standard approach to the lateral femoral cutaneous nerve (LFCN), by Fowler et al 2012. The radiofrequency needle is outlined by the solid black arrows; its tip can be seen in contact with the LFCN, which is indicated by the solid white arrows. Also labeled is the anterior superior iliac spine (ASIS), as well as the iliacus and sartorius muscles. Reprinted from Fowler et al, 2012, with permission from the publisher and copyright holder.

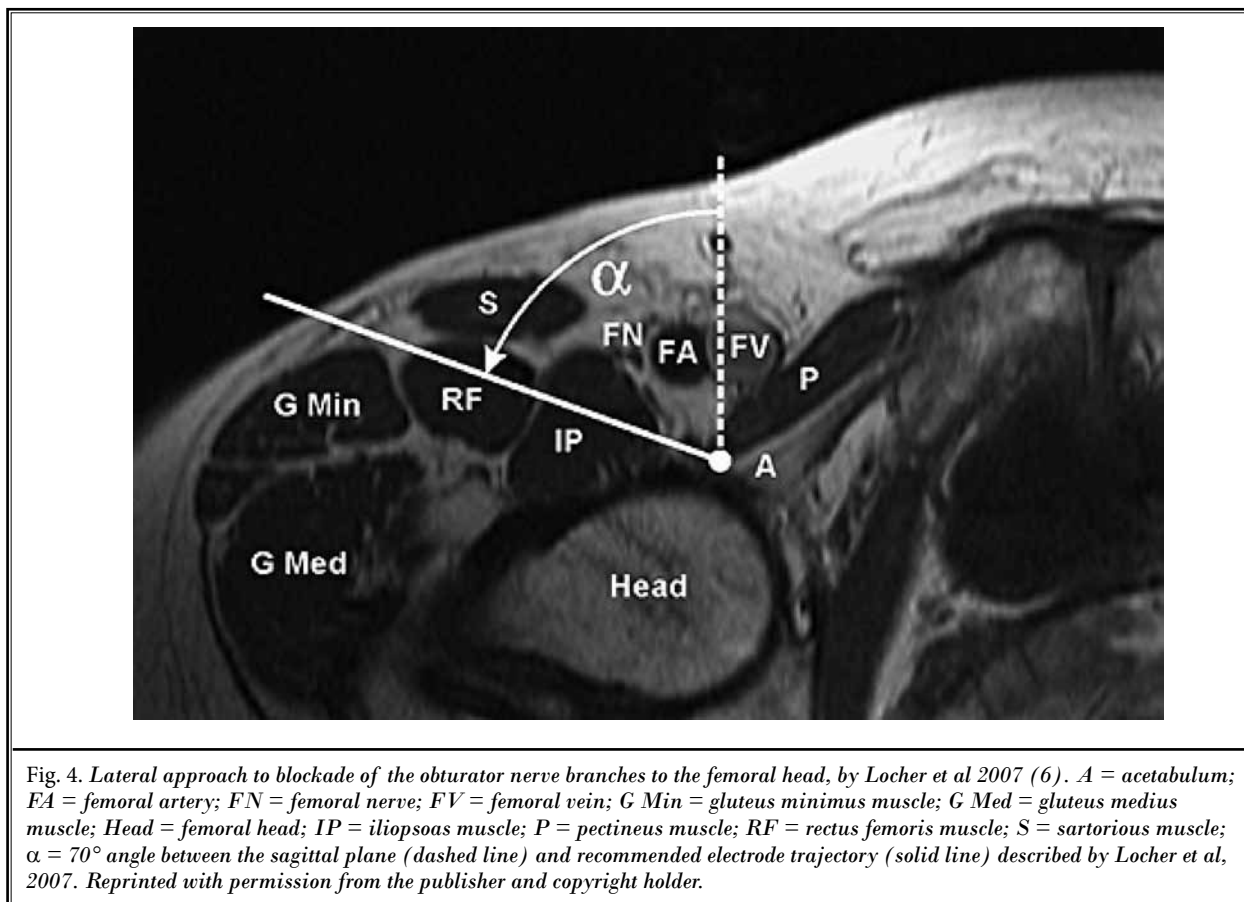
DISCUSSION

Pain arising from bony metastatic disease is notoriously difficult to treat, and many common cancers have a proclivity for bony metastatic spread (3). Successful pain management is especially challenging in elderly patients who are relatively intolerant of systemic opioid and co-analgesic therapy. Relatively few case reports or case series to date have described thermal radiofrequency ablation of the femoral and obturator nerve branches to the hip joint for management of intractable cancer pain, although a small number of patients with cancer have been reported (2,4,5).

In this case report we used thermal radiofrequency ablation of the femoral and obturator nerve branches to the femoral head. We used an anterior approach to the obturator branches, passing the radiofrequency needle between the femoral artery and vein with combined ultrasound and fluoroscopic guidance. To our knowledge, a combined ultrasound and fluoroscopic guided approach, so as to avoid the femoral vessels,

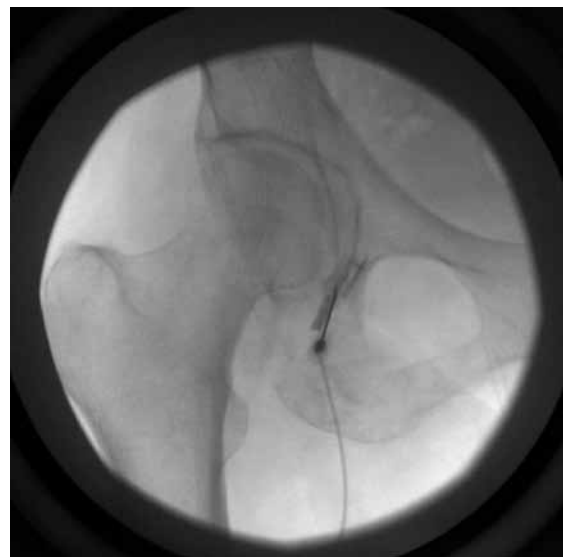

Fig. 3. Anterior placement of a radiofrequency needle abutting the acetabulum, having been passed between the femoral artery and femoral vein with ultrasound.



has not been described before. Previous reports have described lateral or medial approaches that ensure needle placement is not close to the femoral artery and vein (2,6).

The principle concern regarding an anterior approach to the obturator nerve is the vulnerability of the femoral artery and vein. In a cadaver study, Locher et al (6) used 20 MRI scans to trace a hypothetical electrode trajectory along an antero-posterior line. They found that it punctured one of the great femoral vessels in all but one simulation (6). Because of the potential to puncture the femoral vessels, a far lateral approach has been advocated, shown as the solid line in Fig. 4 (reprinted with permission from the publisher and copyright holder). In our experience, the far-lateral technique described by Locher et al (6) is a valuable approach when the more-simple anterior approach is precluded by local anatomy. In the present case we were able to approach the obturator nerve branches in a trajectory approximated by the dashed line in Fig. 4.

There is a lengthy tradition of ultrasound-guided

peripheral nerve blockade, and the use of ultrasound to avoid puncture of major vessels, including the femoral artery and vein in the setting of femoral nerve block. In this case we were able to avoid the femoral vessels using real-time ultrasound guidance. Rather than approaching the nerve from 2 angles, one in the parasagittal plane and the other more obliquely, as outlined by Locher et al (6), we were able to both anesthetize and ablate the nerve using a singular ultrasound-guided anterior approach. Placing the radiofrequency cannula between the femoral artery and vein proved to be both safe and technically feasible in this case.

Other than inadvertent vascular puncture, one other theoretical disadvantage of approaching the obturator nerve branches anteriorly is that the needle tip is in a plane that is perpendicular, not parallel, to the nerve branches. Because only a small lesion is generated in a circumferential fashion around the shaft of an active radiofrequency electrode, the ideal orientation of the needle and nerve is thought to be

in parallel and as close together as possible (6-8). However, we suggest that if the femoral artery and vein can be safely avoided using ultrasound guidance, then perhaps the anterior approach may be the more direct and technically simple option.

There are obvious limitations to this case report. Our report represents a single data point, and thus cannot be generalized to all patients with hip pain. For this patient the tumor was confined to the osseous structures of her hip, and thus was not an impediment to placement of the needle. Tumor burden directly at the site of the obturator nerve would make this approach difficult, and possibly more dangerous. In addition, the vascular anatomy of some patients would undoubtedly preclude the technique we describe here, necessitating the technique described by Locher et al (6) or another approach.

CONCLUSION

We propose that combined ultrasound and fluoroscopic guided blockade and radiofrequency ablation of the obturator nerve may be an effective technique for management of intractable cancer-associated hip pain. An anterior approach to the obturator nerve branches to the femoral head, guided by both ultrasound and fluoroscopy, may be technically feasible and safe.

DISCLAIMER

Disclaimer: There was no external funding in the preparation of this manuscript.

Conflict of interest: Each author certifies that he or she, or a member of his or her immediate family, has no commercial association (i.e., consultancies, stock ownership, equity interest, patent/licensing arrangements, etc.) that might pose a conflict of interest in connection with the submitted manuscript.

REFERENCES

1. Fowler IM, Tucker AA, Mendez RJ. Treatment of meralgia paresthetica with ultrasound-guided pulsed radiofrequency ablation of the lateral femoral cutaneous nerve. *Pain Pract* 2012; 12:394-398.
2. Kawaguchi M, Hashizume K, Iwata T, Furuya H. Percutaneous radiofrequency lesioning of sensory branches of the obturator and femoral nerves for the treatment of hip joint pain. *Reg Anesth Pain Med* 2001; 26:576-558.
3. Roodman GD. Mechanisms of bone metastasis. *N Engl J Med* 2004; 350:1655-1664.
4. Akatov OV, Dreval ON. Percutaneous radiofrequency destruction of the obturator nerve for treatment of pain caused by coxarthrosis. *Stereotact Funct Neurosurg* 1997; 69:278-280.
5. Malik A, Simopolous T, Elkersh M, Aner M, Bajwa ZH. Percutaneous radiofrequency lesioning of sensory branches of the obturator and femoral nerves for the treatment of non-operable hip pain. *Pain Physician* 2003; 6:499-502.
6. Locher S, Burmeister H, Böhlen T, Eichenberger U, Stoupis C, Moriggl B, Curatolo, M. Radiological anatomy of the obturator nerve and its articular branches: Basis to develop a method of radiofrequency denervation for hip joint pain. *Pain Med* 2008; 9:291-298.
7. Lord SM, Barnsley L, Wallis BJ, McDonald GJ, Bogdk N. Percutaneous radiofrequency neurotomy for chronic cervical zygapophyseal-joint pain. *N Engl J Med* 1996; 335:1721-1726.
8. Rivera F, Mariconda C, Annaratone G. Percutaneous radiofrequency denervation in patients with contraindications for total hip arthroplasty. *Orthopedics* 2012; 35:e302-e305.

