

Case-Control Study

Common Anatomical Variation in Patients with Idiopathic Meralgia Paresthetica: A High Resolution Ultrasound Case-Control Study

Thomas Moritz, MD, Helmut Prosch, MD, Dominik Berzaczy, MD, Wolfgang Happak, MD, Doris Lieba-Samal, MD, Maria Bernathova, MD, Eduard Auff, MD, Prof, and Gerd Bodner, MD

From: Department of Radiology
Medical University of Vienna
A-1090 Vienna
Austria

Address Correspondence:
Thomas Moritz, MD
Department of Radiology
Medical University of Vienna
A-1090 Vienna
Austria
E-mail:
thomas.moritz@meduniwien.
ac.at

Disclaimer: There was no
external funding in the
preparation of this manuscript.
Conflict of interest: None.

Manuscript received: 01-06-2013
Revised manuscript received:
03-03-2013
Accepted for publication:
03-08-2013

Free full manuscript:
www.painphysicianjournal.com

Background: Meralgia paresthetica (MP) is a mononeuropathy of the lateral femoral cutaneous nerve (LFCN) characterized by pain, numbness or paresthesia on the anterolateral aspect of the thigh. Though several contributing factors have been identified, the cause of its idiopathic form still remains unclear. Anatomic and clinical studies have demonstrated a variable course for the LFCN and have suggested a contribution to the pathogenesis of MP.

Objective: It was the aim of the present case-control study to assess the anatomical course and compression site of the LFCN using high resolution ultrasound (HRUS) in patients suffering from idiopathic MP, and compare the anatomical course in these patients to an asymptomatic control group.

Study Design: Case-control study.

Setting: Nerve imaging center at a large university hospital in Austria.

Methods: Twenty-eight patients with a diagnosis of MP were included in this study (20 men, 8 women; mean age 54 years). The diagnosis was established by clinical history, physical examination, and diagnostic anesthetic block. Fifteen age- and gender-matched healthy volunteers served as the control group.

Standardized HRUS examinations were performed by one experienced radiologist from June 2004 through April 2012. Two experienced radiologists reviewed the patients' standardized HRUS examinations and performed examinations in the control group to measure the minimal distance between the LFCN and the anterior superior iliac spine (ASIS).

Outcomes: The minimal distance between the ASIS and the LFCN was measured using HRUS.

Results: The LFCN could be seen in all patients and volunteers. In MP patients, the mean distance between the LFCN and the ASIS was 0.52 cm (SD 0.46 cm), compared to a mean distance of 1.79 cm (SD 1.48 cm) in the control group ($P < 0.001$).

Limitations: Limited sample size, retrospective design.

Conclusions: The results of this study demonstrate a significantly different course of the LFCN, closer to the ASIS in patients with idiopathic MP.

Key words: Ultrasound, meralgia paresthetica, entrapment neuropathy, assessment

Pain Physician 2013; 16:E287-E293

Meralgia paresthetica (MP) is a mononeuropathy of the lateral femoral cutaneous nerve (LFCN) characterized by pain, sensory loss, and dysesthesia at the anterolateral aspect of the thigh. It can develop spontaneously, or can be caused secondarily by local trauma or surgical intervention (1,2). Though many contributing medical conditions for the development of the spontaneous form of MP have been identified, it is still considered idiopathic (2).

Anatomic and clinical studies have demonstrated a variable course of the LFCN at its passage through the inguinal ligament (3,4). The distance to the anterior superior iliac spine (ASIS) has been reported to range from a few millimeters to 7 cm (Fig. 1) (5-8). Previous studies have suggested a relation between a small ASIS-LFCN distance and an elevated risk for the development of MP, most likely due to an increased mechanical stress to the LFCN caused not only by the bone but also by the tendon of the sartorius muscle and the inguinal ligament as the nerve was found ensheathed in these structures in 50% of human specimens (3).

Recent technical developments have made high resolution ultrasound (HRUS) a powerful tool with which to visualize the peripheral nerves, allowing non-invasive assessment of small nerve anatomy and pathology (5,9). In patients with MP, ultrasound (US) has been proven to be a feasible tool for the measurement of the ASIS-LFCN distance (4,5,10).

OBJECTIVES

It was the aim of the present case-control study to assess the anatomical course and compression site of the LFCN in patients suffering from idiopathic MP, and to compare the anatomical course in these patients to the LFCN course in an asymptomatic control group.

METHODS

The study was conducted according to the Declaration of Helsinki and was approved by the local Institutional Ethics Review Board (IRB) of the Medical University of Vienna (IRB Number 1094/2012). All patients gave informed consent for diagnostic investigations and interventions. The IRB waived the need for an informed consent for the retrospective analysis of the data.

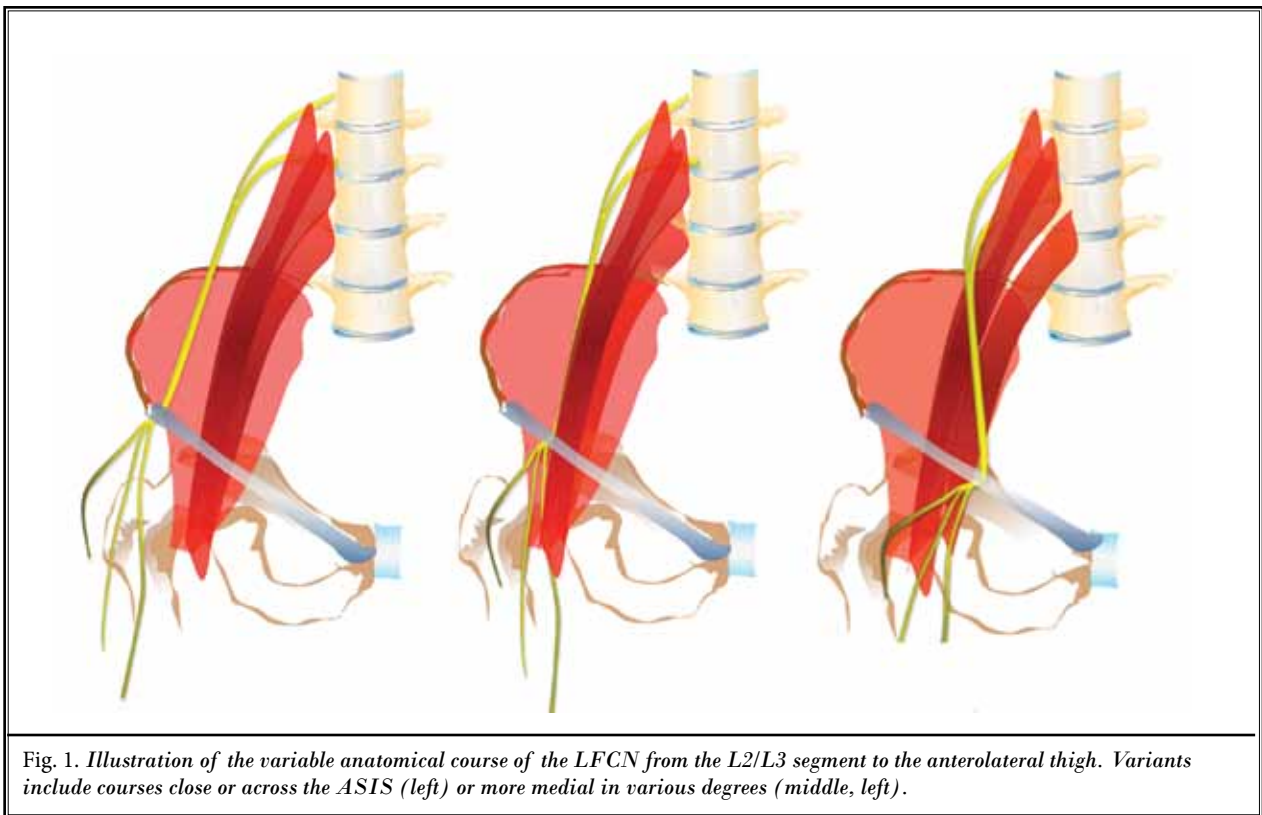


Fig. 1. Illustration of the variable anatomical course of the LFCN from the L2/L3 segment to the anterolateral thigh. Variants include courses close or across the ASIS (left) or more medial in various degrees (middle, right).

Data Acquisition

Patient data were retrieved from the nerve ultrasound quality assurance database of our department (total $n = 268$ patients), which identified 40 patients with MP who were evaluated from June 2004 through April 2012. Patients with nonidiopathic causes of MP, including a history of trauma ($n = 2$), tumors ($n = 1$), or previous surgery ($n = 6$) in the inguinal area were excluded from the study. Furthermore, patients suffering from diabetes were excluded ($n = 4$). There were no pregnant patients among our study population. The remaining 28 patients had spontaneous development of symptoms. The group consisted of 20 men and 8 women (mean age, 54 years; range, 38 – 77 years). Meralgia paresthetica was located in the left thigh in 16 patients and in the right thigh in 12 patients. Nearly every patient ($n = 26$) presented with pain and sensory loss or a burning sensation over the lateral and anterolateral thigh. Two patients presented with hypesthesia only in the LFCN sensory area. For quantification of pain sensation, pain assessment by a Visual Analog Scale (VAS, 0 – 10) was routinely performed prior to the US examination to quantify pain sensation.

The diagnosis was established by clinical history, physical examination, and diagnostic blocks with local anesthetics. Since HRUS and US-guided nerve block are routine procedures in our center, HRUS-guidance was used for the diagnostic blocks as described below.

Control Group Assessment

For the establishment of a control group, the LFCN of 15 asymptomatic age- and gender-matched healthy volunteers (mean age, 50 years; range, 30 – 75, 10 men and 5 women) was scanned bilaterally ($n = 30$) by 2 investigators (GB, TM) who were blinded to the results of the other investigator's findings. The control group was not only established to allow a comparison of the measurement technique to the published results of earlier studies, but also to ensure consistency of the results by using the same measurement technique performed by the same examiners in patients and controls.

Clinical Record Review

The patient history and relevant clinical data were retrieved from the hospital information system of our hospital by one author (TM). Radiological reports, reports of functional tests (e.g., nerve conduction studies), surgical reports, and patient discharge letters were accessed and analyzed for information on patient history,

course, and treatment, insofar as they were relevant to the study. All stored data were encrypted with a key known only to the investigators.

Examination Technique

Ultrasound examinations were performed by 2 radiologists with more than 20 (GB) and 3 years' (TM) experience in peripheral nerve US, using high frequency probes up to 18 MHz (Philips IU22, L17-5, Philips Medical Systems, the Netherlands and GE logic E9, L8-18i, GE Healthcare, USA). All examinations were performed following a standardized examination protocol. The LFCN was consistently located in a fat pad over the anterolateral thigh, underneath the fascia lata, and superficial to the sartorius muscle, as described in a previous study (Fig. 2). Normally, the nerve appears as a small hypoechoic oval structure in short-axis views, and as a hypoechoic linear structure in a long-axis view (4).

The nerve was followed cephalad toward the inguinal ligament. Before performing the measurement, the US transducer was aligned in a transversal plane parallel to an imaginary line between the ASIS on both sides. The distance between the LFCN and the ASIS was measured using the measurement tool included in the local PACS (Picture Archiving and Communication System; Impax Client ES, Version 5302, AGFA Healthcare, Mortsel, Belgium) and documented in a table using commercially available spreadsheet software (Microsoft Excel 2011, Microsoft Corp., Seattle, WA). The measurement technique is demonstrated in Fig. 3. In volunteers with a distance from the LFCN to the ASIS greater than the footprint of the US transducer, an expanded field-of-view image was created using vendor software (GE logic E9, L8-18i, GE Healthcare, USA). The examinations had been documented following a standardized protocol by still images and video clips. For the purpose of this study, all US images and video clips of the symptomatic patients were retrospectively reviewed in consensus by the same 2 radiologists.

Diagnostic US-Guided Perineural Injection

The diagnostic block of the LFCN was performed according to the technique described in a previous study (4). Ultrasound-guided injection of local anesthetic (0.3 – 0.5 mL lidocaine 2%, 25-gauge needle) adjacent to the affected nerve was routinely performed under aseptic conditions to confirm the suspected clinical diagnosis. Patients were followed clinically for at least 3 months after the injection.

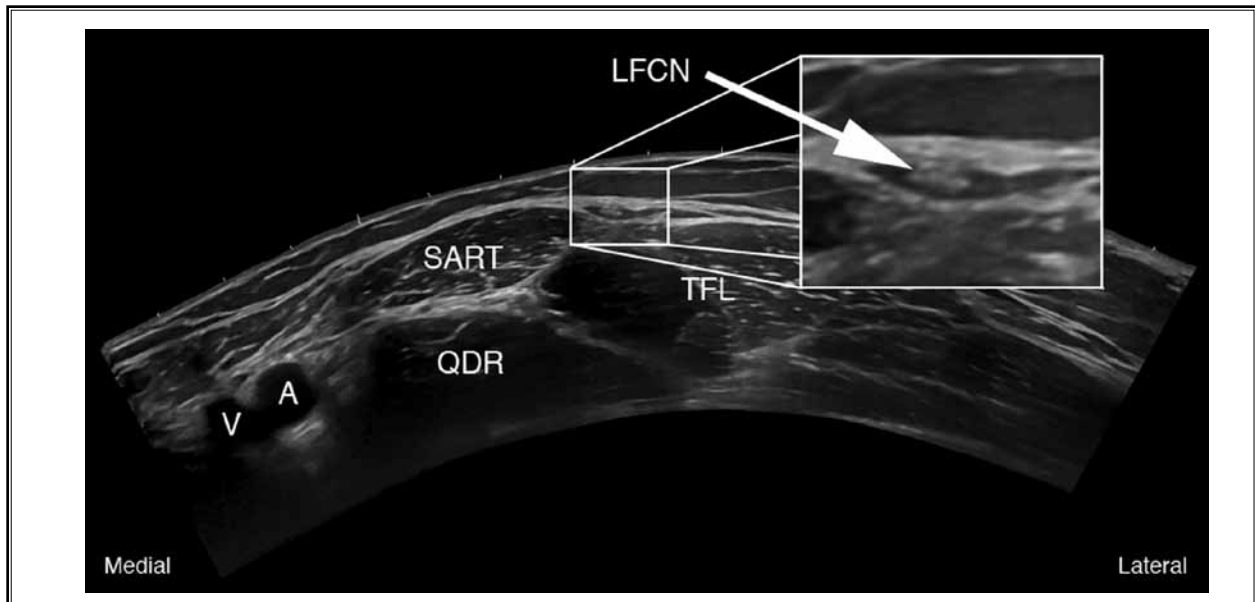


Fig. 2. Extended field-of-view Image at the proximal thigh in axial orientation. The LFCN is typically located in a fat pad superficial to the sartorius (SART) and tensor fasciae latae (TFL) muscles. QDR: Quadriceps muscle; A, V: Femoral artery and vein.

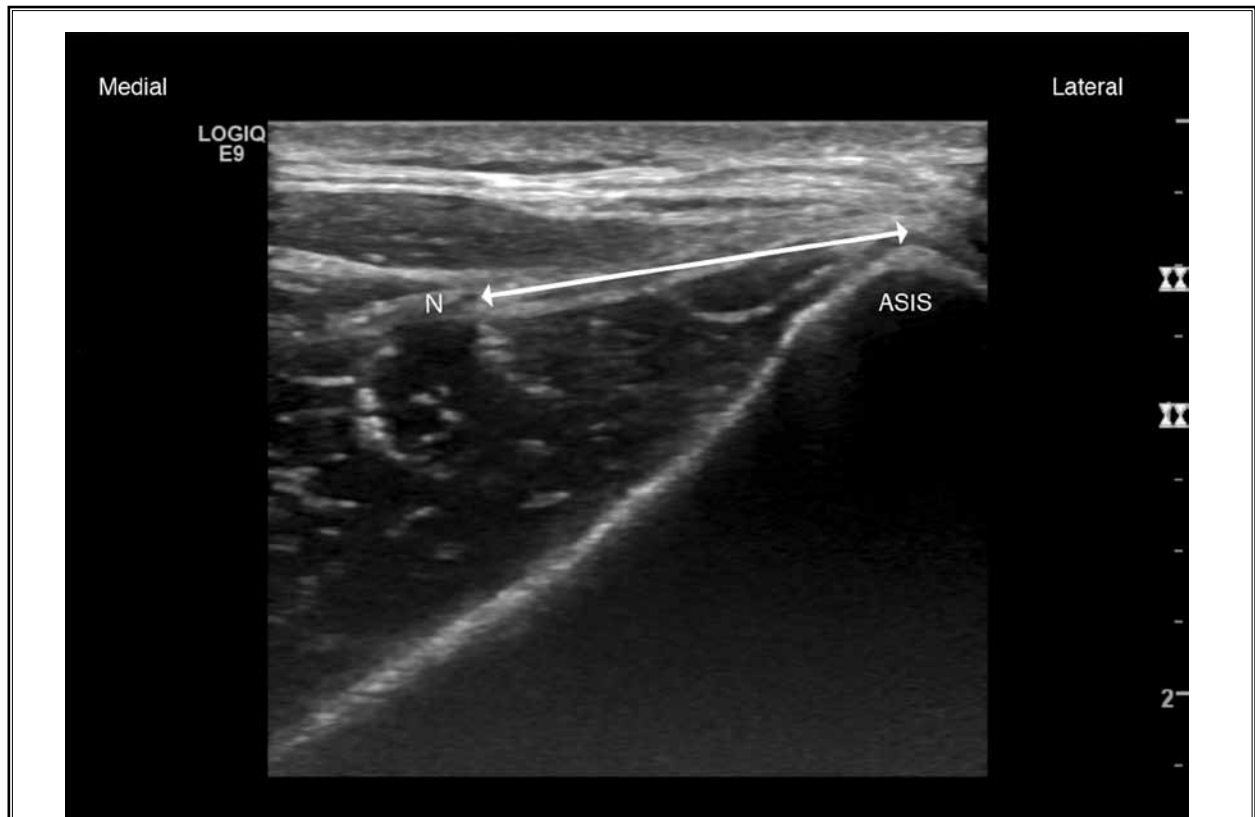

Fig. 3. Measurements were performed in an axial plane. The shortest distance from the anterior superior iliac spine (ASIS) to the LFCN (N) was measured.

Statistical Analysis

Data were analyzed using the SPSS statistical package (SPSS, Version 20.0, IBM Corporation, Armonk, NY). Metric data, such as age and distance, were expressed using means \pm standard deviations (SD). Nominal data, such as gender, are presented in absolute numbers and percentages. To compare patients and controls, a mixed model analysis of variance (ANOVA) with an unstructured matrix of covariance was used when considering multiple measurements per control. An intraclass correlation coefficient as well as a Bland-Altman plot was calculated to describe inter-rater agreement. A *P*-value equal to or less than 0.05 was considered to indicate a significant result. An experienced biomedical statistician performed the statistical analysis.

RESULTS

Patients

There were 28 patients included in this case-control study. Pain levels ranged from 5 to 10 on the VAS, with a mean pain level of 8.

The nerve was depicted in a fat pad at the anterolateral aspect of the thigh and could be followed proximally in all patients (Fig. 2). The US appearance was

consistently that of a tubular structure in cross-section or a linear structure in a longitudinal section. The nerve was thickened in terms of an increase in diameter and the loss of a fascicular pattern at the passage through the inguinal ligament in all patients ($n = 28/28$) and bilaterally in one control ($n = 2/30$, Control 11). Because of the small nerve diameter, the cross-sectional diameter of the nerve could not be reliably assessed.

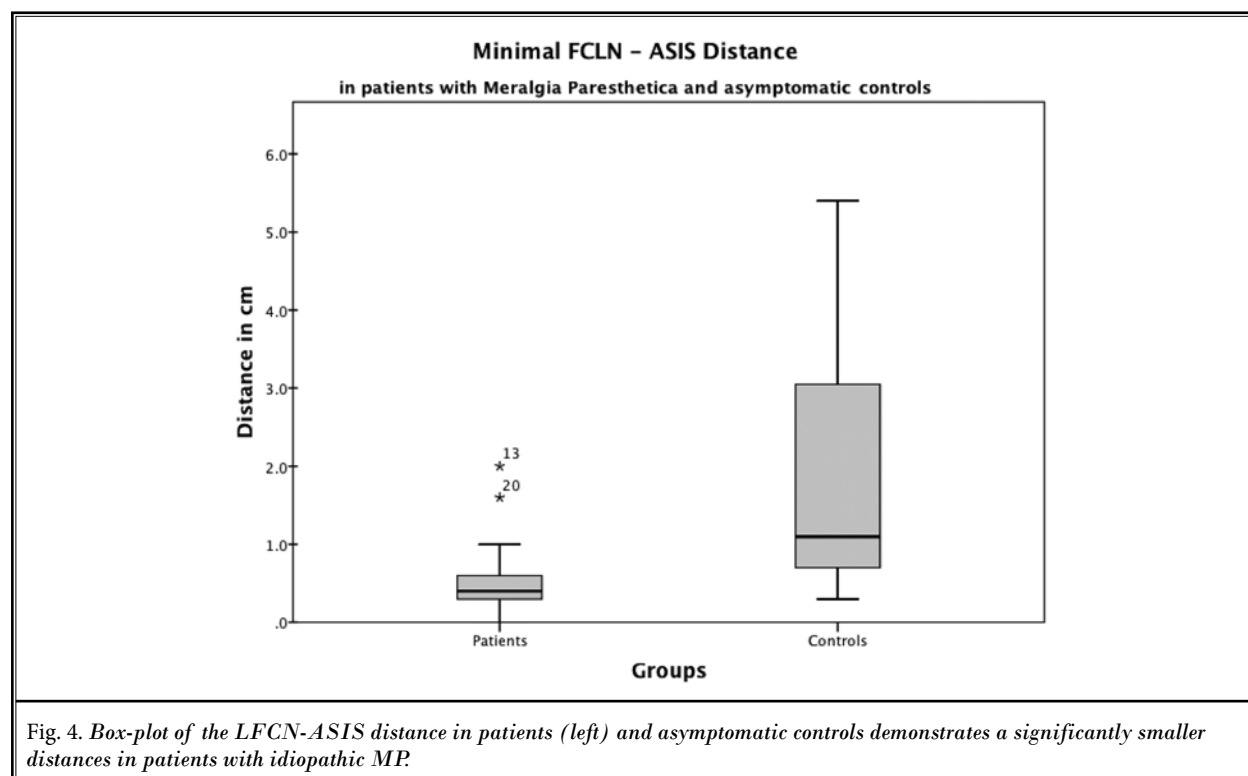
In MP patients, the mean distance between the LFCN and the ASIS was 0.52 cm (SD 0.46 cm). In all but 2 patients, the LFCN passed the inguinal ligament within 0.8 cm of the ASIS. In 4 of these patients, the LFCN was riding across the edge of the ASIS. Ultrasound findings are illustrated in Fig. 4.

Diagnostic US-guided injection of local anesthetic was successful in all patients (VAS decrease $> 50\%$).

Control Group

The LFCN could be detected in all volunteers bilaterally by both examiners. The mean distance between the LFCN and the ASIS for control volunteers was 1.85 cm (SD 1.5 cm) for Examiner 1 (TM) and 1.73 cm (SD 1.45 cm) for Examiner 2 (GB) (Overall: 1.79 cm [SD 1.49 cm]).

The intra-class correlation for the examiners was 0.947. The measurements correlated with $r = .948$. No



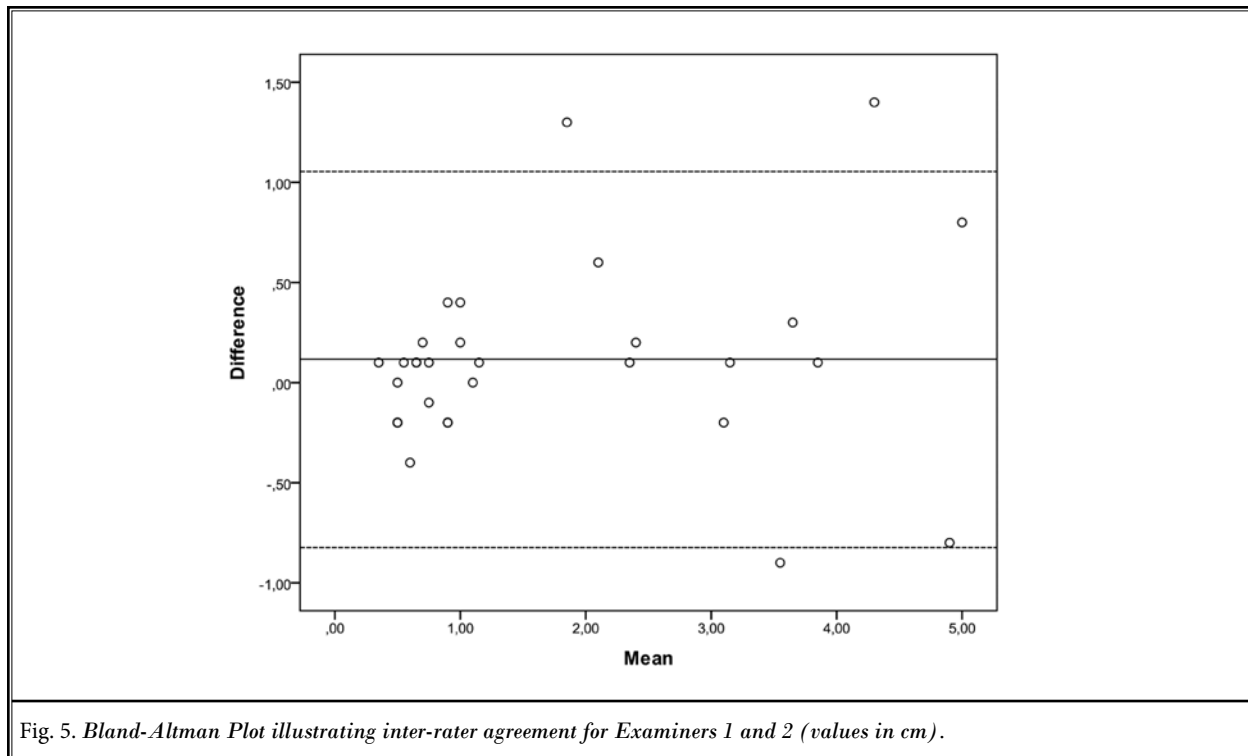


Fig. 5. Bland-Altman Plot illustrating inter-rater agreement for Examiners 1 and 2 (values in cm).

systematic measurement differences were detectable. The Bland-Altman diagram showed a good inter-observer correlation for measurements up to 2 cm. However, the diagram indicated increased measurement variability for distances greater than 2 cm (Fig. 5).

Comparison of Patients and Control Group

Using the mixed model ANOVA, there was a significant difference in the distance between the LFCN and the ASIS when patients were compared to control volunteers ($P < 0.001$). There was no significant difference in distance regarding the affected patient sides ($P = 0.462$) (Fig. 4).

Discussion

This study for the first time provides evidence about the significant differences of the anatomical course of the LFCN in patients suffering from idiopathic MP compared to a control group.

The technical progress in small nerve US imaging increasingly enables the routine visualization of small peripheral nerves and may thereby lead to a better understanding of the pathophysiology in peripheral small nerve disease. However, beyond mere visualization, techniques such as US-guided palpation ("sonopalpa-

tion" [11]) and US-guided infiltration are invaluable in determining a diagnosis and in providing targeted therapy (4,12-14).

In the present study, the LFCN could consistently be visualized using HRUS. The previously described approach, following the nerve from a fat pad over the anterolateral thigh, proximal to the ASIS, proved to be a practical approach in our setting (4). Furthermore, US-guided perineural injection could be performed successfully in all patients to confirm the diagnosis of MP.

The cause for the spontaneous form of MP is subdivided into mechanical, metabolic, and idiopathic forms (10). The results of this analysis of 28 patients with idiopathic MP, to our knowledge the largest number in the literature with idiopathic MP who have been studied, support a mechanical pathophysiological component in the pathogenesis of MP. Patients with symptomatic idiopathic MP showed a significantly closer spatial relationship of the nerve to the ASIS and focal nerve swelling with loss of fascicular structure when compared to asymptomatic individuals. In our opinion, the mechanical relationship of the LFCN to the ASIS and adjacent structures, such as the origin of the sartorius muscle or the firm structures of the insertion of the inguinal ligament, may represent a central factor in the pathogen-

esis of idiopathic MP, a concept that is also known from other nerve entrapment syndromes, such as supinator syndrome (3,15). The close mechanical relationship may lead to local friction of the nerve, scar formation, and restriction of the nerve's gliding ability, all factors that may lead to nerve damage (16).

However, there is a significant fraction of asymptomatic control volunteers who showed a short LFCN-ASIS distance, which suggests that while distance is an important factor in the pathogenesis of MP, it is most certainly not the only contributing factor. An increased mechanical stress at the compression site due to changes in a patient's physique or increased vulnerability of the nerve due to metabolic changes, combined with age, seem to have a role in the problem as well (17).

The retrospective study design leads to several study limitations. The contralateral side of patients suffering from MP was not systematically examined. However, the measurements in control volunteers showed a significant variation in the LFCN-ASIS dis-

tance between the sides. The high variation in the LFCN-ASIS distance measurements results from the low accuracy of measurements in extended field-of-view images.

The study design was focused on the anatomical assessment of the LFCN course, and thus, co-morbidities and factors such as body mass index were not systematically taken into account. However, the results were highly statistically significant and correlated well with the clinical experience in our population, which, to our knowledge, is the largest population studied by HRUS in the literature; no systematic randomized controlled trials about MP exist (18).

CONCLUSION

In conclusion, the results of this study show a significantly lower LFCN-ASIS distance in patients with idiopathic MP, compared to an asymptomatic control group. This offers a possible hint at the pathogenesis of MP.

REFERENCES

- Majkrzak A, Johnston J, Kacey D, Zeller J. Variability of the lateral femoral cutaneous nerve: An anatomic basis for planning safe surgical approaches. *Clin Anat* 2010; 23:304-311.
- Harney D, Patijn J. Meralgia paresthetica: Diagnosis and management strategies. *Pain Med* 2007; 8:669-677.
- Aszmann OC, Dellon ES, Dellon AL. Anatomical course of the lateral femoral cutaneous nerve and its susceptibility to compression and injury. *Plast Reconstr Surg* 1997; 100:600-604.
- Bodner G, Bernathova M, Galiano K, Putz D, Martinoli C, Felfernig M. Ultrasound of the lateral femoral cutaneous nerve: Normal findings in a cadaver and in volunteers. *Reg Anesth Pain Med* 2009; 34:265-268.
- Tagliafico A, Serafini G, Lacelli F, Perrone N, Valsania V, Martinoli C. Ultrasound-guided treatment of meralgia paresthetica (lateral femoral cutaneous neuropathy): Technical description and results of treatment in 20 consecutive patients. *J Ultrasound Med* 2011; 30:1341-1346.
- Hospodar PP, Ashman ES, Traub JA. Anatomic study of the lateral femoral cutaneous nerve with respect to the ilioinguinal surgical dissection. *J Orthop Trauma* 1999; 13:17-19.
- Grothaus MC, Holt M, Mekhail AO, Ebraheim NA, Yeasting RA. Lateral femoral cutaneous nerve: an anatomic study. *Clin Orthop Relat Res* 2005; 437:164-168.
- Beltran L, Bencardino J, Ghazikhanian V, Beltran J. Entrapment neuropathies III: Lower limb. *Semin Musculoskelet Radiol* 2010; 14:501-511.
- Kim JE, Lee SG, Kim EJ, Min BW, Ban JS, Lee JH. Ultrasound-guided lateral femoral cutaneous nerve block in meralgia paresthetica. *Korean J Pain* 2011; 24:115-118.
- Patijn J, Mekhail N, Hayek S, Lataster A, van Kleef M, Van Zundert J. Meralgia paresthetica. *Pain Pract* 2011; 11:302-308.
- Boon AJ, Smith J, Harper CM. Ultrasound applications in electrodiagnosis. *PM R* 2012; 4:37-49.
- Bargalló X, Carrera A, Sala-Blanch X, Santamaría G, Morro R, Llusá M, Gilabert R. Ultrasound-anatomic correlation of the peripheral nerves of the upper limb. *Surg Radiol Anat* 2010; 32:305-314.
- Tagliafico A, Bodner G, Rosenberg I, Palmieri F, Garelo I, Altafini L, Martinoli C. Peripheral nerves: Ultrasound-guided interventional procedures. *Semin Musculoskelet Radiol* 2010; 14:559-566.
- Bodner G, Harpf C, Gardetto A, Kovacs P, Gruber H, Peer S, Mallhoui A. Ultrasonography of the accessory nerve: Normal and pathologic findings in cadavers and patients with iatrogenic accessory nerve palsy. *J Ultrasound Med* 2002; 21:1159-1163.
- Jacobson J, Fessell D, Lobo LDG, Yang LJS. Entrapment neuropathies I: Upper limb (carpal tunnel excluded). *Semin Musculoskelet Radiol* 2010; 14:473-486.
- Rempel DM, Diaó E. Entrapment neuropathies: Pathophysiology and pathogenesis. *J Electromyogr Kinesiol* 2004; 14:71-75.
- Parisi TJ, Mandrekar J, Dyck PJB, Klein CJ. Meralgia paresthetica: Relation to obesity, advanced age, and diabetes mellitus. *Neurology* 2011; 77:1538-1542.
- Khalil N, Nicotra A, Rakowicz W. Treatment for meralgia paresthetica. *Cochrane Database Syst Rev* 2012 (12):CD004159.

