

Review

Comparison of Balloon Kyphoplasty with the New Kiva® VCF System for the Treatment of Vertebral Compression Fractures

Lucia A. Otten, Rahel Bornemann, Tom R. Jansen, Koursh Kabir, MD, Peter H. Pennekamp, MD, Dieter C. Wirtz, MD, Brit Stuwe, and Robert Pflugmacher, MD

From: Universitätsklinikum
Bonn, Germany

Address Correspondence:
Lucia Otten
Universitätsklinikum
Bonn, Klinik und Poliklinik
für Orthopädie und
Unfallchirurgie,
Sigmund-Freud-Str. 25, 53127
Bonn, Germany
E-mail: luotten@uni-bonn.de

Disclaimer: There was no
external funding in the
preparation of this manuscript.

Conflict of interest: Each
author certifies that he or
she, or a member of his or
her immediate family, has no
commercial association, (i.e.,
consultancies, stock ownership,
equity interest, patent/
licensing arrangements, etc.)
that might post a conflict of
interest in connection with the
submitted manuscript.

Manuscript received:
11-27-2012

Revised manuscript received
02-17-2013

Accepted for publication:
03-08-2013

Free full manuscript:
www.painphysicianjournal.com

Background: Vertebral compression fractures are common among the elderly, which is conditioned by osteoporosis. They cause back pain and limit the patient's activities. The Kiva® VCF Treatment System is a new device to treat vertebral compression fractures. Compared to other methods, the utilization of the Kiva System reduces the risk for complications and delivers improvements in back pain reduction and functionality.

Objectives: Evaluation of safety and effectiveness of the Kiva System in comparison to balloon kyphoplasty on the basis of matched pairs.

Methods: 52 patients (47 - 89 years, 68 fractures) were treated with balloon kyphoplasty or with the new Kiva System. Back pain and impairment of motility were assessed preoperatively and 6 months postoperatively, with the Visual Analog Scale (VAS) and Oswestry Disability Index (ODI). The operation time and cement extravasation were recorded. Control radiographs were evaluated for new fractures and vertebral heights.

Results: Mean VAS values in both groups improved from preoperatively 87.6 ± 12.8 and 83.1 ± 14.9 to 10.8 ± 20.8 and 24.6 ± 11.0 6 months after the treatment. The improvement after 6 months in the Kiva group was significantly better than in the balloon kyphoplasty group ($P < 0.0001$). Mean ODI scores in both groups also improved from $68.7\% \pm 15.8\%$ in the Kiva group and $80.6\% \pm 8.6\%$ in the balloon kyphoplasty group preoperatively to $24.8 \pm 18.6\%$ and $33.2 \pm 6.3\%$ 6 months after treatment. The mean operation time for the Kiva group was 12.7 ± 3.7 minutes per vertebra and cement leakage occurred in 6 patients. The mean operation time for the balloon kyphoplasty group was 34.1 ± 7.0 minutes per vertebra and cement leakage occurred in 8 patients. Anterior and mid vertebral height in the Kiva group increased from preoperatively 21.06 ± 7.44 mm and 18.36 ± 5.64 mm to postoperatively 22.41 ± 7.14 mm and 20.41 ± 6.00 mm. Anterior and mid vertebral height in the balloon kyphoplasty group increased from preoperatively 21.68 ± 2.06 mm and 21.97 ± 1.78 mm to postoperatively 25.09 ± 2.54 mm and 25.29 ± 2.10 mm. Vertebral height restoration could be therefore maintained with both procedures for 6 months. In the Kiva group 2 cases of nonadjacent fractures and one case of adjacent fractures were observed. In the balloon kyphoplasty group 9 cases of adjacent, as well as 5 cases of nonadjacent, fractures were observed. In the Kiva group significant fewer fractures occurred.

Limitations: The study includes only 26 patients for each procedure, which were compared on the basis of matched pairs.

Conclusion: The Kiva System appears to be a safe and effective procedure for the treatment of vertebral compression fractures. Six months after treatment with the Kiva System, better VAS values than the values after the treatment with balloon kyphoplasty were recorded. Reduction in functional impairment was as successful as it was after balloon kyphoplasty. Vertebral height restoration was observed in both groups, which was sustained for 6 months. The risk of cement extravasation during the Kiva Treatment is nearly the same as in balloon kyphoplasty; however, it requires a shorter operation time and produces fewer new fractures.

Key words: Vertebral compression fracture, Kiva, kyphoplasty, vertebral augmentation, osteoporosis, back pain

Pain Physician 2013; 16:E505-E512

Vertebral body fractures are steadily increasing due to the aging population. They cause severe pain and limit daily activities substantially. Patients are usually treated with conservative therapies; however, in cases where results remain unsuccessful, surgical procedures such as vertebroplasty or kyphoplasty are further options. Kyphoplasty can here be considered as a further development of vertebroplasty. During kyphoplasty the bone cement is not solely injected with pressure into the vertebral body, but also targeted into a cavity, which had been created by means of a balloon in the vertebral body. The total amount of bone cement required to fill the cavity is higher compared to the amount required during vertebroplasty. However, kyphoplasty results in a lower risk of bone cement leakage than vertebroplasty. Both augmentation techniques allow rapid pain reduction and mobilization of patients; nevertheless, the risk of adjacent fractures in patients with osteoporosis and the mentioned risk of cement leakage have to be considered (1-4). The Kiva® VCF Treatment System from Benvenue Medical (Santa Clara, USA) presents a new development for the treatment of osteoporotic vertebral body fractures. Thereby, a spiral shaped nitinol coil is inserted percutaneously into the vertebral body, which preserves the cancellous architecture of the bone. The implant is then delivered over the removable guide wire coil to provide structural support to the vertebral body and to serve as a conduit for the bone cement. Vertebral displacement by the implant should result in endplate re-elevation and fracture reduction. Bone cement is then delivered through the lumen of the implant.

To assess the treatment results for both augmentation procedures, a prospective comparison, regarding clinical efficacy and safety, was conducted between the Kiva® VCF Treatment System and the KyphX®-Systems (Kyphon Inc., Sunnyvale, USA) for balloon kyphoplasty.

METHODOLOGY

The Kiva® VCF Treatment System is a sterile, single-use device for the treatment of pathological compression fractures of the thoracic and lumbar spine. It is a newly developed product of Benvenue Medical (USA), which bears the CE mark and is available for sale in Europe. In the USA and Canada it is limited to investigational use by qualified investigators. The internationally conducted interventional study (KAST) that evaluates the safety and effectiveness of the Kiva® VCF Treatment System in comparison to balloon kyphoplasty is regis-

tered at ClinicalTrials.gov (Identifier: NCT01123512). All study procedures were conducted in accordance with the ethical principles as laid down in the Declaration of Helsinki and the research on the Kiva® VCF Treatment System and balloon kyphoplasty was approved by the local ethical committee, respectively.

Patients

For the retrospective comparison only patients with one or 2 A1.1, A1.2, or A1.3 (AO Spine Fracture classification) painful osteoporotic vertebral fracture(s) at the thoracic and lumbar spine were considered. Before surgery, a detailed study of the patients' medical history was conducted. They all underwent a complete physical examination, including complete radiological examinations/magnetic resonance imaging (MRIs) in order to confirm the presence, location, and severity of vertebral compression fracture(s). The reported data for the Kiva® VCF Treatment System was collected at the University of Bonn between 2010 and 2011. The data for balloon kyphoplasty was collected from procedures conducted between 2004 and 2009.

The criteria to match pairs across the 2 groups, Kiva group and balloon kyphoplasty group, were defined by the cranial vertebral body treated, the age, and the approximately caudal acantha. Both groups consisted of 26 patients with mean age 73.6 ± 8.6 year (range 54 - 89 years) in the Kiva group (Kiva) and mean age 66.4 ± 8.9 years (range 47 - 83 years) in the balloon kyphoplasty group (BKP). In each group 18 patients received treatment in only one vertebral body and 8 patients received treatment in 2 vertebral bodies. In total 68 vertebral compression fractures were treated at different levels of the thoracic and lumbar spine. The patients' characteristics are summarized in Table 1.


Interventions

The pKiva® VCF Treatment System (Benvenue Medical, Santa Clara, USA) procedure was performed under general anesthesia, or local anesthesia (when general anesthesia was contraindicated) with fluoroscopic guidance. Fluoroscopy ensured proper deployment and placement of the devices, the implant, and the bone cement. A unipedicular approach was used for the treatment (Fig. 1). The nitinol coil of the KIVA® VCF Treatment System was guided through a deployment cannula into the vertebral body and acted as a guide wire for the implant. After correct placement of the nitinol coil in the cancellous portion of the vertebral body, the implant was delivered over the coil until

Comparison of Balloon Kyphoplasty with Kiva VCF System

Table 1. Patient's characteristics of both treatment groups

		Kiva	BKP
Age	Mean \pm SD	73.6 \pm 8.6	66.4 \pm 8.9
	Range	54 - 89	47 - 83
Subjects	male	6 (23.1%)	11 (57.7%)
	female	20 (76.9%)	15 (42.3%)
Treated fractures per patient	n = 1	18	18
	n = 2	8	8
Fracture locations	Th7	1	1
	Th8	1	2
	Th9	3	2
	Th10	3	5
	Th11	3	2
	Th12	8	5
	L1	5	5
	L2	4	5
	L3	1	2
L4	5	5	



the desired amount of height restoration or filling was accomplished. The implant, made of PEEK-OPTIMA® (Invibio Inc., West Conshohocken, Pennsylvania), contains 15% barium sulfate for radiopacity and forms a nesting, cylindrical column. Afterwards the guide wire was removed and bone cement was injected through the lumen of the implant until the column was filled.

For a pre-post comparison see Fig. 2.

Balloon kyphoplasty was already described as an established procedure in various publications (5-6). In this study balloon kyphoplasty was performed under general anesthesia and biplanar fluoroscopy for control. The KyphX®-Systems (Kyphon Inc., Sunnyvale, California, USA) was used and a bilateral approach into

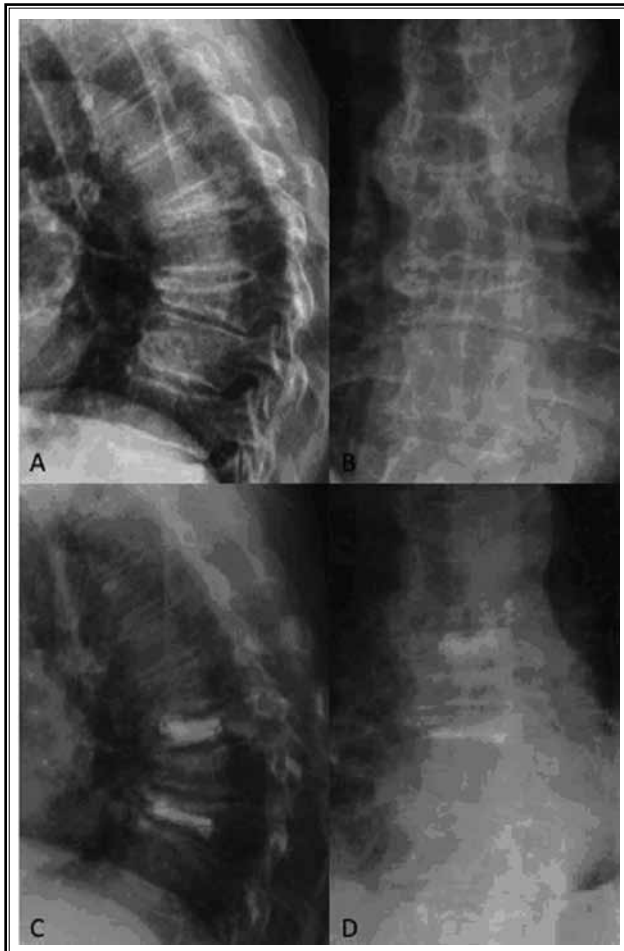


Fig. 2. Preoperative (A, B) and postoperative (C, D) radiographs of a patient treated by the Kiva® Treatment System at vertebrae T7 and T9 (lateral view = A, C; anterior-posterior view = B, D)

the vertebral body was chosen. The KyphX Xpander® balloons, available in lengths of 10, 15, and 20 mm, were inserted via 2 working channels. Their placement should ideally be centered between the endplates in the anterior two-thirds of the vertebral body, which can be controlled by 2 radiopaque makers at the ends of the balloon. The inserted balloons were inflated to create a cavity. They were deflated and removed when the KyphX Xpander® balloon made contact with the cortical wall of the vertebrae, the maximal inflation volume was reached, and if the pressure exceeded 400 psi.

The resulting cavity in the vertebral body was then

filled with bone cement according to the following procedure: First the KyphX® Bone Filler Device containing 1.5 mL polymethylmethacrylate (PMMA) is filled with the bone cement, the filled KyphX® Device is then guided through the working cannula to the anterior part of the cavity where subsequently the cement is slowly extruded out of the device into the cavity. In the final step the KyphX® Bone Filler Device is removed. The same procedure was repeated at the contralateral pedicle.

Outcomes

Patient-reported outcomes were measured pre-operatively before device implantation and 6 months after treatment. Back pain severity was evaluated with the standard 10 cm VAS (Visual Analog Scale) for the Kiva® VCF Treatment System and a numeric rating scale (0-100, steps of 10) for balloon kyphoplasty. Condition-specific functional impairment was evaluated with the ODI (Oswestry Disability Index) score. During surgery the operation time was recorded. All adverse events, which could be attributed to the treatment and further complications, such as new fractures, were documented.

Cement extravasations and their location were confirmed by intra-operative fluoroscopy and post-operative radiography. New fractures were evaluated by radiographic controls.

The anterior and mid vertebral heights were measured radiologically in the digital system by caliper pre-operatively, postoperatively, 3 months, and 6 months postoperatively.

Statistical Analyses

Data were analyzed by using the statistic software PSPP (GPL version 3.). Continuous data were reported in mean \pm standard deviation and categorical data were reported in frequencies and percentages.

The VAS baseline values, VAS values 6 months after the treatment with the Kiva® VCF Treatment System, and corresponding values for balloon kyphoplasty were compared using the Wilcoxon-test. The ODI values, at baseline and 6 months after treatment with the Kiva® VCF Treatment System, were compared with corresponding values from balloon kyphoplasty using the t-test, 2-tailed. Using the Chi²-test, data on postoperative fractures between the groups and data on cement leakage between the groups were compared.

RESULTS

The mean preoperative VAS for pain in the Kiva group was 87.6 ± 12.8 and improved, 6 months post-treatment, to 10.8 ± 20.8 . In the balloon kyphoplasty group, the preoperative 83.1 ± 14.9 mean VAS score also improved to 24.6 ± 11.0 , 6 months post-treatment. The Kiva group showed a significantly lower VAS score 6 months after treatment than the BKP group ($P < 0.0001$). In the Kiva group 96.2% of the patients and in the balloon kyphoplasty group 100% of the patients experienced pain relief 6 months after the treatment. Mean ODI scores also improved in both groups: in the KIVA group from $68.7 \pm 15.8\%$ preoperatively to $24.8 \pm 18.6\%$ 6 months post-treatment and in the balloon kyphoplasty group from $80.6 \pm 8.6\%$ preoperatively to 33.2 ± 6.3 6 months post-treatment. The test of equality showed no difference between the values at 6 months post-treatment ($P = 0.03$). One hundred percent of the patients in the Kiva group and 100% of the balloon kyphoplasty group experienced an increased functional ability after the treatment. All VAS and ODI values for each treatment are graphically illustrated in Figs. 3 and 4.

The mean operation time, using the Kiva® VCF Treatment System, was 12.7 ± 4.7 min. per vertebra and during balloon kyphoplasty the mean operation time was 46.5 ± 20.0 min. per vertebra. Six cases of cement extravasations were observed in the Kiva group and 8 cases in the balloon kyphoplasty group. There was no significant difference of cement extravasation between both treatment groups. In 2 cases in the Kiva group the cement extravasation was located lateral, in one case crania-caudal, in one case dorsal, and in 2 cases ventral. For the balloon kyphoplasty group 7 cases of the cement extravasations were located lateral and one case cranial.

New fractures occurred in 3 patients from the Kiva group and 14 patients from the balloon kyphoplasty group. In the Kiva group, 2 of the new fractures were observed at the adjacent level and one of them at a non-adjacent level. In the balloon kyphoplasty group 9 of the new fractures were observed at the adjacent levels and 5 at non-adjacent levels. No new fractures at the treated levels were reported in either group.

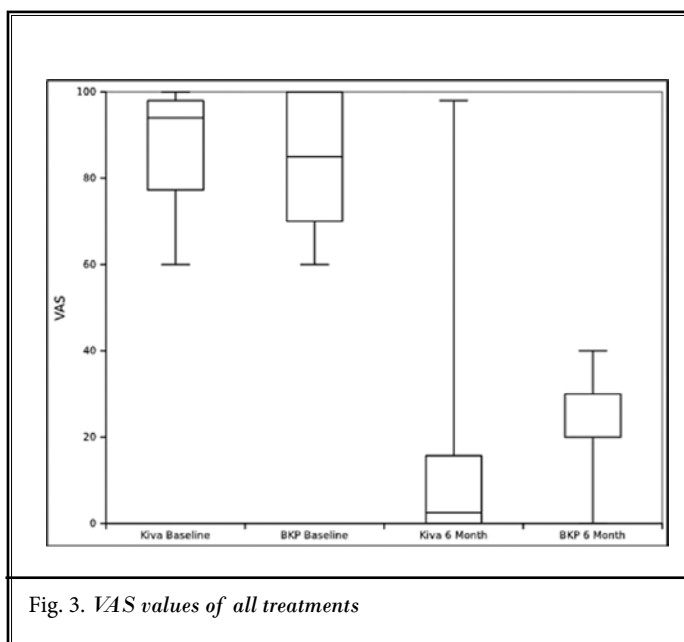


Fig. 3. VAS values of all treatments

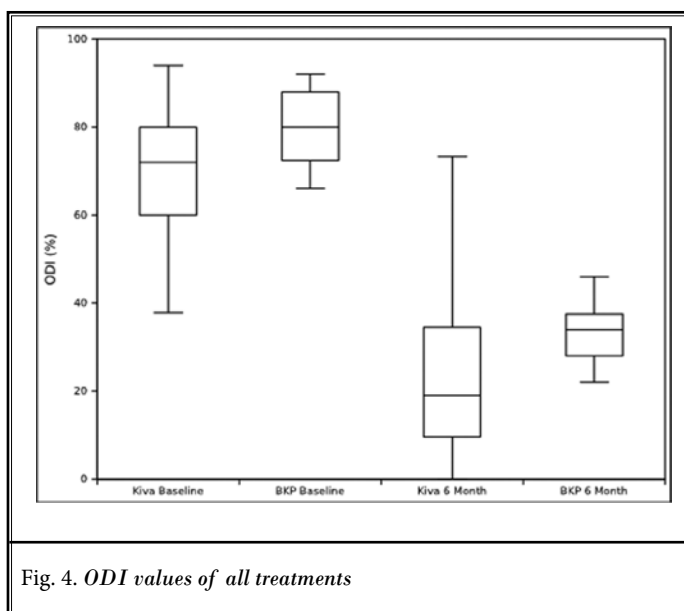


Fig. 4. ODI values of all treatments

In summary, results from the Kiva group show that the occurrence of new fractures is significantly lower ($P < 0.0001$) than in the balloon kyphoplasty group after 6 months.

Table 2 presents the results for operation time, cement extravasation, and new fractures in both treatments.

The mean post-fracture height in the Kiva group was 21.06 ± 7.44 mm at the anterior vertebral wall and $18.36 \pm$

Table 2. Parameters of the treatments

		Kiva	BKP
Op time (minutes per vertebra) mean \pm SD		12.7 \pm 3.7	34.1 \pm 7.0
Cement leakage		23.1% (n=6)	30.7% (n=8)
Following fracture		11.5% (n=3)	53.8% (n=14)
	adjacent	7.7% (n = 2)	34.6% (n = 9)
	no adjacent	3.8% (n = 1)	19.2% (n = 5)

Table 3. Change of anterior and mid-vertebral height for both treatments (mean \pm SD mm)

		Pre-op	Post-op	3 months	6 months
KIVA	anterior	21.06 \pm 2.77 (n = 34)	22.41 \pm 7.14 (n = 34)	22.40 \pm 7.08 (n = 32)	22.28 \pm 6.85 (n = 33)
	mid	18.36 \pm 5.64 (n = 34)	20.89 \pm 6.00 (n = 34)	21.06 \pm 5.90 (n = 32)	21.19 \pm 6.08 (n = 33)
BKP	anterior	21.68 \pm 2.08 (n = 34)	25.09 \pm 2.54 (n = 34)	24.55 \pm 2.25 (n = 33)	24.56 \pm 2.27 (n = 34)
	mid	21.97 \pm 1.78 (n = 34)	25.29 \pm 2.10 (n = 34)	25.00 \pm 2.09 (n = 34)	24.91 \pm 2.08 (n = 34)

5.64 mm at the mid-vertebral region. The mean post-fracture height in the balloon kyphoplasty group was 21.68 \pm 2.08 mm at the anterior vertebral wall and 21.97 \pm 1.78 mm at the mid-vertebral region. The mean postoperative height in the Kiva group was 22.41 \pm 7.14 mm at the anterior vertebral wall and 20.89 \pm 6.00 mm at the mid-vertebral region. The mean postoperative height in the balloon kyphoplasty group was 25.09 \pm 2.54 mm at the anterior vertebral wall and 25.09 \pm 2.10 mm at the mid-vertebral region. A significant ($P < 0.001$) increase in the anterior and mid wall height was seen in both groups preoperatively compared with postoperatively (Table 3).

At 6 months follow-up the vertebral height did not change significantly in both groups.

Discussion

Osteoporotic vertebral compression fractures cause pain, restrict daily activities, and cause height loss and kyphosis (7). The frequently applied vertebral augmentations procedures, vertebroplasty and kyphoplasty, are very successful but also fraught with risks such as subsequent fractures, cement leakages, embolisms, or infections (1,3).

Over the past few years, new vertebral augmentation procedures have been developed in order to optimize the treatment and minimize the risks (8-10). The newly developed Kiva® VCF Treatment System consists of an implant that will be inserted into the vertebral body and filled with bone cement.

A biomechanical study indicates that the Kiva® VCF Treatment System exhibits similar biomechanical performance to balloon kyphoplasty, but reduces the risk of cement extravasation (11). The reduced risk of cement extravasation when applying the Kiva® VCF Treatment System rather than balloon kyphoplasty is also indicated in the study at hand, but no significant difference between the treatment groups could be shown. Other studies confirm that the Kiva® VCF Treatment System only has a minimal risk of cement extravasation: 4.8% and 8% (12,13). The results of this study show a higher percentage of cement extravasation, which may be linked to the relatively small sample size and the method of matched pairs selection.

Reported values on the risk of cement extravasation during balloon kyphoplasty vary between 7% and 15% (14-17). The results observed in this comparative study, however, are slightly higher compared with the prior data. This discrepancy may be also linked to the relatively low number of patients selected to match pairs. In a large, randomized and controlled trial, which compared the efficacy and safety of balloon kyphoplasty with non-surgical care, cement extravasation occurred in approximately 27% of the cases treated with balloon kyphoplasty (18).

Our study revealed that the Kiva® VCF Treatment System had a shorter operation mean time of 12.7 \pm 4.7 min. per vertebra than that of balloon kyphoplasty, which had 46.5 \pm 20.0 min. per vertebra. The determined operation time for balloon kyphoplasty was

comparable to other reported durations with 32 min. – 61 min. (2,5,19). A possible reason for the shorter operation time when applying the Kiva® VCF Treatment System could be the simplified handling and the unipedicular approach instead of the bipedicular approach for balloon kyphoplasty, as well as the shorter period of radiation needed to launch the surgical procedure.

The incidents of newly occurring fractures after an intervention with the Kiva® VCF Treatment System were significantly lower than after balloon kyphoplasty. Rosales Olivarez et al (13) treated 34 fractures in 30 patients, 12 months after their treatment with the Kiva® VCF Treatment System, 5 new fractures were observed at adjacent levels, 2 at nonadjacent levels, and one was a refracture at an index level which had previously been treated. Korovessis et al (12), however, did not report any new fractures at treated or at adjacent levels, after reviewing the patients 6 months after their treatment with the Kiva® VCF Treatment System.

Previous studies report a 4% - 26% (2,14,16,17) risk of suffering new fractures for balloon kyphoplasty. However, the risk of an adjacent level fracture observed through our study is moderately higher than previously reported data. The results indicating this higher risk could be related to various factors such as the smaller number of patients involved, the applied augmentation procedure, or progressive osteoporosis.

The reason for fewer new fractures in the Kiva group could be attributed to the lower amount of cement injected and the accurate guidance during injection by the cylindrical coil. Mean cement volumes injected during balloon kyphoplasty were 4.7 mL – 7.5 mL (5,11,15) and during Kiva® VCF Treatment System 2.2 mL – 2.6 mL per vertebra (11,13). The injected cement is different from the native bone structure and consequently influences the mechanical forces to each part of the spine. Therefore, a higher amount of injected cement may influence the distribution of the forces negatively, e.g., the treated vertebrae gets more inelastic caused by the cement with the result that the acanthas below the treated vertebrae have to absorb more than before.

Vertebral height restoration was observed in the Kiva group and balloon kyphoplasty group after surgery and was sustained for 6 months after the procedure, which is of importance due to a lower risk of back pain or the occurrence of new fractures. The increased vertebral height after balloon kyphoplasty is already known from other clinical studies (2,5,14). An *ex vivo*

comparison study also showed no differences of anterior vertebral height between balloon kyphoplasty and the Kiva® VCF Treatment System after cyclic loading (11).

Both augmentation systems, Kiva® VCF Treatment System and balloon kyphoplasty, improve back pain and function. Notable is the pronounced improvement through the Kiva® VCF Treatment System revealed through our study. These findings are comparable with results of other studies on the treatment of vertebral compression fractures with balloon kyphoplasty (2,4,5,16,18,20) and with the Kiva® VCF Treatment System (12-13).

Improvements in functionality and back pain are important factors for the social life and independence of the patient. Klezl et al (20) reported in a study with a 12 month follow-up period a drift to a lower level of social functionality, defined by level of independence, in 53% of the patients treated conservatively and 21% of the patients treated with balloon kyphoplasty. In order to determine the sustainability of an improved social life and independence through the Kiva® VCF Treatment System, follow-up periods must exceed the 6 months given in this study. This indicates that the short follow-up period of 6 months in this study provides only an intermediate follow-up period and is a further limitation to the relatively small study population. The time between the incidence of the fracture and the treatment is an important factor in pain relief (17). On that note, further randomized prospective studies with larger patient samples and prolonged follow-up periods are necessary in order to predicate about long-term outcomes after the intervention.

CONCLUSION

The Kiva VCF Treatment System appears to be a safe and effective procedure for the treatment of vertebral compression fractures. In comparison to treatment with balloon kyphoplasty, treatment via the Kiva Treatment System delivered better VAS values after 6 months. Moreover, functional impairment was as effectively reduced through the Kiva Treatment System as it was after balloon kyphoplasty. Vertebral height restoration was observed in both groups after surgery, which was sustained for 6 months. Both methods pose nearly the same level of risk in cement extravasation; however, the operation time needed to complete the procedure with the Kiva Treatment System is shorter and it produced fewer new fractures.

REFERENCES

1. Hadjipavlou AG, Tzermiadianos MN, Katonis PG, Szpalski M. Percutaneous vertebroplasty and balloon kyphoplasty for the treatment of osteoporotic vertebral compression fractures and osteolytic tumors. *The Journal of Bone and Joint Surgery* 2005; 87-B:1595-1604.
2. Liu JT, Liao WJ, Tan WC, Lee J, Liu CH, Chen YH, Lin TB. Balloon kyphoplasty versus vertebroplasty for the treatment of osteoporotic vertebral compression fracture: A prospective, comparative, and randomized clinical study. *Osteoporosis International* 2010; 21:359-364.
3. McCall T, Cole C, Dialek A. Vertebroplasty and kyphoplasty: A comparative review of efficacy and adverse events. *Curr Rev Musculoskelet Med* 2008; 1:17-23.
4. Bornemann R, Deml M, Wilhelm KE, Jansen TR, Wirtz DC, Pflugmacher R. [Long-term efficacy and safety of balloon kyphoplasty for treatment of osteoporotic vertebral fractures]. *Zeitschrift für Orthopädie und Unfallchirurgie* 2012; 150:381-388.
5. Pflugmacher R, Taylor R, Agarwal A, Melcher I. Balloon kyphoplasty in the treatment of metastatic disease of the spine: A 2-year prospective evaluation. *Eur Spine J* 2008; 17:1042-1048.
6. Robinson Y, Heyde CE, Försth P, Olerud C. Kyphoplasty in osteoporotic vertebral compression fractures – guidelines and technical considerations. *Journal of Orthopaedic Surgery and Research* 2011; 6:43.
7. Silverman SL. Quality-of-life issues in osteoporosis. *Current Rheumatology Reports* 2005; 7:39-45.
8. Kettler A, Schmoelz W, Shezifi Y, Ohana N, Ben-Arye A, Claes L, Wilke HJ. Biomechanical performance of the new BeadEx implant in the treatment of osteoporotic vertebral body compression fractures: Restoration and maintenance of height and stability. *Clinical Biomechanics* 2006; 21:676-682.
9. Piazzolla A, De Giorgi S, Solarino G, Mori C, De Giorgi G. Vertebral body reconstruction system B-Twin® versus corset following non-osteoporotic Magerl A1.2 thoracic and lumbar fracture. Functional and radiological outcome at 12 month follow-up in a prospective randomized series of 50 patients. *Orthopaedics & Traumatology* 2011; 97:846-851.
10. Rotter R, Martin H, Fuerderer S, Gabl M, Roeder C, Heini P, Mittlmeier T. Vertebral body stenting: A new method for vertebral augmentation versus kyphoplasty. *Eur Spine J* 2010; 19:916-923.
11. Wilson DC, Connolly RJ, Zhu Q, Emery JL, Kingwell SP, Kitchel S, Cripton PA, Wilson DR. An ex vivo biomechanical comparison of a novel vertebral compression fracture treatment system to kyphoplasty. *Clinical Biomechanics* 2012; 27:346-353.
12. Korovessis P, Reppantis T, Miller LE, Block JE. Initial clinical experience with a novel vertebral augmentation system for treatment of symptomatic vertebral compression fractures: A case series of 26 consecutive patients. *BMC Musculoskeletal Disorders* 2011; 12:206.
13. Rosales Olivarez LM, Dipp JM, Flores Escamilla R, Bajares G, Perez A, Stubbs HA, Block JE. Vertebral augmentation treatment of painful osteoporotic compression fractures with the Kiva VCF Treatment System. *SAS Journal* 2011; 5:114-119.
14. Bouza C, López T, Magro A, Navalpotro L, Amate JM. Efficacy and safety of balloon kyphoplasty in the treatment of vertebral compression fractures: A systemic review. *Eur Spine J* 2006; 15:1050-1067.
15. Frankel BM, Monroe T, Wang, CW. Percutaneous vertebral augmentation: An elevation in adjacent-level fracture risk in kyphoplasty as compared with vertebroplasty. *The Spine Journal* 2007; 7:575-582.
16. Robinson, Y, Tschöke SK, Stahel PF, Kayser R, Heyde CE. Complications and safety aspects of kyphoplasty for osteoporotic vertebral compression fractures: A prospective follow-up study in 102 consecutive patients. *Patient Safety in Surgery* 2008; 2:2.
17. Taylor RS, Fritzell P, Taylor RJ. Balloon kyphoplasty in the management of vertebral compression fractures: An updated systematic review and meta-analysis. *Eur Spine J* 2007; 16:1085-1100.
18. Wardlaw D, Cummings SR, Meirhaeghe JV, Bastian L, Tillman JB, Ranstam J, Eastell R, Shabe P, Talmadge K, Boonen S. Efficacy and safety of balloon kyphoplasty compared with non-surgical care for vertebral compression fracture (FREE): A randomised controlled trial. *The Lancet* 2009; 373:1016-1024.
19. Izadpaha K, Konrad G, Südkamp NP, Oberst M. Computer navigation in balloon kyphoplasty reduce the intraoperative radiation exposure. *Spine* 2009; 34:1325-1329.
20. Klezl Z, Bhangoo N, Phillips J, Swamy G, Calthorpe D, Bommireddy R. Social implications of balloon kyphoplasty: Prospective study from a single UK centre. *Eur Spine J* 2012; 21:1880-1886.