

## Case Report

## Intracranial Hypotension Headache Caused by a Massive Cerebrospinal Fluid Leak Successfully Treated with a Targeted C2 Epidural Blood Patch: A Case Report

Kenneth T. Sykes, MD PhD, and Xiaobin Yi, MD

From: Division of Pain Management  
Department of Anesthesiology  
Washington University School of Medicine  
St. Louis, Missouri

Address Correspondence:  
Xiaobin Yi, MD  
Campus Box 8054  
Division of Pain Management  
Department of Anesthesiology,  
Washington University School of Medicine  
660 S. Euclid Avenue,  
St. Louis, MO 63110  
Email: yix@anest.wustl.edu

Disclaimer: There was no external funding in the preparation of this manuscript.  
Conflict of interest: None.

Manuscript received: 12-08-2012  
Revised manuscript submitted: 03-23-2013  
Accepted for publication: 03-28-2013

Free full manuscript:  
[www.painphysicianjournal.com](http://www.painphysicianjournal.com)

Cervical epidural steroid injections, administered either intralaminarly or transforaminally, are common injection therapies used in many interventional pain management practices to treat cervicogenic or cervicobrachial pain secondary to spondylosis or intervertebral disc displacement of the cervical spine. Among the risks associated with these procedures are the risk for inadvertent dural puncture and the development of positional headache from intracranial hypotension. We report the case of a 31-year-old woman with a history of migraine and cervicogenic pain from cervical spine spondylosis and cervical disc degenerative disease that developed an intractable orthostatic headache accompanied by nausea and vomiting after a therapeutic high cervical intralaminar epidural steroid injection was administered directly to the C1-C2 spinal level. Although the initial magnetic resonance imaging of the brain was unremarkable, a computed tomography myelogram study revealed a massive cerebrospinal fluid (CSF) leak from the cervical spine. Repeated cervical epidural blood patches using a catheter targeted to the high cervical spine (C2) to inject 15 mL of autologous blood was required to totally alleviate her symptoms after she failed conservative therapy. Determining the optimal location or approach to administer an epidural blood patch can be a challenge depending on the location of the CSF leak. Our case demonstrates that targeted cervical epidural blood patch placement using an easily manipulated catheter under fluoroscopic guidance is a safe and effective approach to treat a massive CSF leak in the high cervical spine region caused by prior therapeutic cervical spine epidural steroid injection.

**Key words:** Cervical epidural blood patch, intracranial hypotension, intracranial hypotension headache, spinal headache, orthostatic headache, epidural steroid injection, cerebrospinal fluid leak, post dural headache

**Pain Physician 2013; 16:399-404**

Cervical epidural steroid injections are common interventional therapies used for the treatment of cervicogenic or cervicobrachial pain secondary to cervical spondylosis or cervical intervertebral disc displacement. Among the risks associated with these procedures are the risk for dural puncture and subsequent headache from intracranial hypotension. We present a case of massive cervical cerebrospinal fluid (CSF) leak from a therapeutic cervical epidural steroid injection that required 2 targeted cervical epidural blood patches using a catheter for successful treatment

of positional headache associated with intracranial hypotension.

A 31-year-old woman with a prior history of migraine and cervicogenic pain from cervical spine spondylosis and cervical disc degenerative disease was admitted to our hospital complaining of severe bifronto-bitemporal headache. Her headache was improved by lying flat, worsened by standing up, and was associated with severe nausea and vomiting, blurred vision, phonophobia, and photophobia. She was fully conscious and there were no focal neurological deficits. Four

days prior to admission, she underwent a therapeutic epidural steroid injection directly at the C1-C2 level for radicular neck pain and associated non-positional headache at an outside hospital. Approximately one hour after the procedure she developed a severe headache that she characterized as the worst headache she had ever experienced. The headache initially improved with supine positioning for a few hours but later returned causing her to go to the emergency department at a local hospital. Lumbar puncture in the emergency department showed that the opening CSF pressure was too low to measure. Magnetic resonance imaging (MRI) of the brain was unremarkable for acute intracranial processes. Computed tomography (CT) myelogram showed subtle regions of dilute extradural contrast accumulation at the C1-C2 level with contrast tracking down into the middle thoracic epidural space according to the radiologist's report. All together, the findings suggested CSF leakage in the cervical spine region resulting in intracranial hypotension. Twenty-four hours of conservative therapy, including bed rest, intravenous fluid hydration, muscle relaxants, non-steroidal anti-inflammatory drugs, caffeine, and narcotics, was ineffective at improving her headache. The patient was transferred to our hospital for further management and the pain management service was consulted. After evaluating the patient, the decision was made to perform a fluoroscopically guided cervical epidural blood patch with catheter for suspected intracranial hypotension associated with iatrogenic cervical CSF leak.

After reviewing the patient's laboratory data and imaging studies, the patient was brought to the procedural suite and placed in the prone position. Fluoroscopy was used to visualize the cervical intralaminar space, the epidural needle position, and the catheter path. The skin was infiltrated with local anesthetic and a 17-gauge Tuohy needle was inserted at the T1-T2 level. The needle was advanced to the epidural space using the saline loss of resistance technique under fluoroscopic guidance. The proper needle position was confirmed by anterior-posterior and lateral fluoroscopic views. With the needle in place in the epidural space, a catheter was threaded through the Tuohy needle up to the C2 level. Contrast solution (one mL, Omnipaque 300) was injected through the catheter and the contrast distribution was visualized from C2 to C4 as confirmed by anteroposterior and lateral fluoroscopic views again. Next, blood was sterilely collected from the patient's right radial artery (intravenous access was difficult secondary to the patient's dehydration status), and 10 mL

of autologous blood was injected incrementally over 2 minutes into the epidural space through the catheter. No paresthesias were encountered during injection of the autologous blood, and the patient reported virtually immediate resolution of her headache in the recovery room.

Despite her immediate relief, after 3 days her orthostatic headache returned accompanied by neck pain, nausea, and vomiting. This headache was similar in character to the headache she had prior to the epidural blood patch, yet now she reported more pain lateralized to the left fronto-temporal area. Given the continued positional character of her headache and the prior complete, but transient, relief she experienced after the prior epidural blood patch, the decision was made to repeat the cervical epidural blood patch. She underwent another cervical epidural blood patch, this time with the catheter targeted to the C2 level slightly to the left given the laterality of her headache. The appropriate positioning of the catheter was confirmed with fluoroscopy by injecting one mL of contrast which outlined the cervical epidural space clearly (Fig. 1). Fifteen mL of autologous blood was injected through the catheter this time. After the second blood patch her headache improved immediately and was fully resolved by the next day. The patient remained without headache and was able to return to work a few days after the second procedure. Two weeks after her second cervical epidural blood patch, the patient returned to the pain clinic for a follow up visit; her headache had completely and totally resolved. To our knowledge, she has remained headache-free since the second epidural blood patch was performed.

## DISCUSSION

Intracranial hypotension results when CSF surrounding the brain and spinal cord is too low from either decreased production or the presence of a CSF leak causing intracranial hypovolemia (1,2). CSF leaks may be due to spontaneous or traumatic disruption of the dura, or more commonly associated with dural perforation from diagnostic or therapeutic procedures that involve accessing the intrathecal or epidural space. Intracranial hypotension is popularly recognized clinically by orthostatic or postural headache. However, it can present with other signs and symptoms including neck pain, shoulder pain, audiovisual disturbances, cranial nerve paresis, memory loss, ataxia, obtundation, nausea, and vomiting (1,2). Intracranial hypotension headache is initially treated with conservative, support-

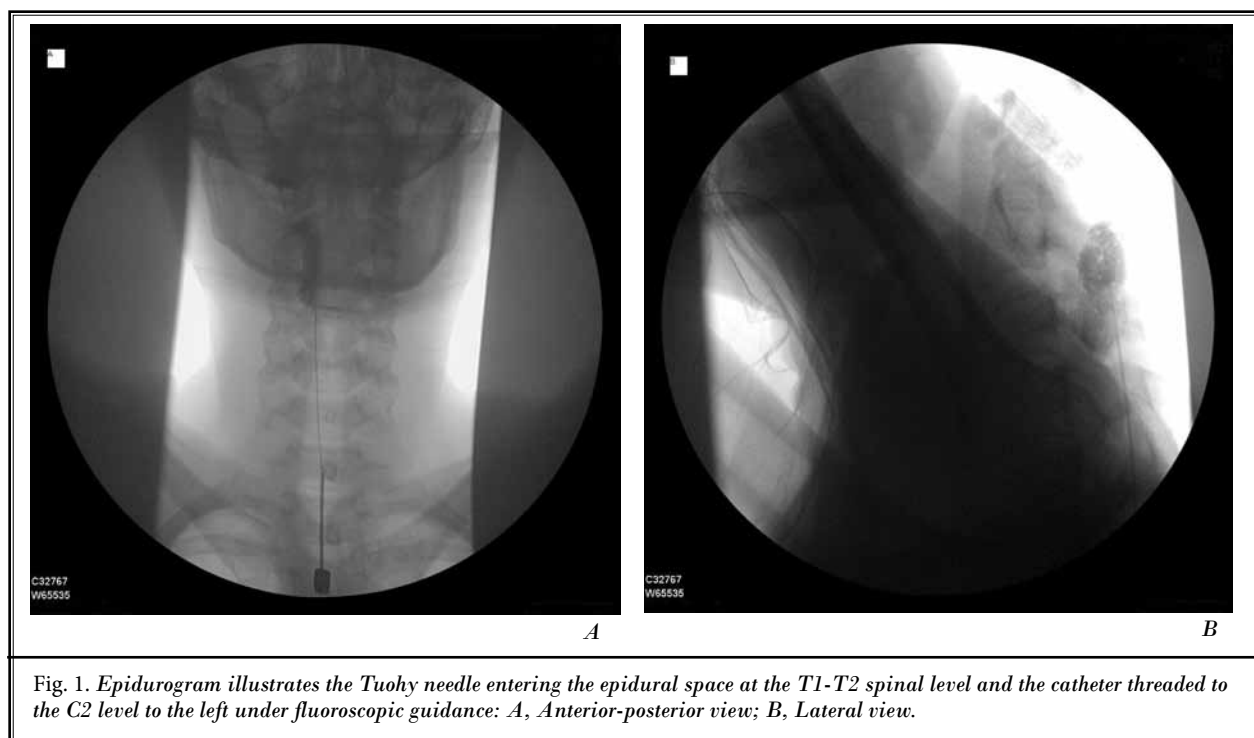


Fig. 1. Epidurogram illustrates the Tuohy needle entering the epidural space at the T1-T2 spinal level and the catheter threaded to the C2 level to the left under fluoroscopic guidance: A, Anterior-posterior view; B, Lateral view.

ive therapies, including bed rest, intravenous fluids, abdominal binders, caffeine, theophylline, corticosteroids, nonsteroidal anti-inflammatory drugs, and narcotics (1,2). When these have failed, the next treatment option is often an epidural blood patch, which provides complete, long-lasting relief in most patients (3).

This case report demonstrates several notable points regarding epidural blood patches in the context of cervical dural puncture. In our patient, the final diagnosis of intracranial hypotension headache was determined from a combination of the classic post-dural puncture headache clinical features, the temporal relationship with the recent medical history, and the imaging studies. The classic clinical manifestation of post-dural puncture headache is a positional, or orthostatic, bilateral headache that may be accompanied by photophobia, phonophobia, or nausea and vomiting. Therefore, our patient's prior history of chronic neck pain and non-positional headache meant that a change in the character of her headache in conjunction with the clinical context was highly suggestive of CSF leak. Positional headache due to intracranial hypotension is commonly linked to intentional or inadvertent dural puncture associated with procedures that involve accessing a compartment of the lumbar spinal cord for therapeutic or diagnostic purposes (1-3). Indeed, CSF

leakage from dural puncture is a real risk associated with therapeutic thoracic and cervical intralaminar and transforaminal epidural steroid injections for thoracic and cervical pain. In our patient, for instance, significant CSF leakage was caused from a prior therapeutic intralaminar C1-C2 epidural steroid injection without report of a witnessed wet tap. With the clinical presentation and the clinical context together, ultimately a CT myelogram, showing evidence of a massive CSF leak with large contrast dilution spreading from the cervical to mid-thoracic epidural space confirmed the diagnosis.

Our patient's orthostatic headache was resistant to the initial conservative, supportive therapy. Therefore, definitive treatment with a cervical epidural blood patch was attempted for complete alleviation of her symptoms. Determining the optimal location or approach to administer an epidural blood patch can be a challenge depending on the location of the known or suspected CSF leak. Multiple case reports describe treatment of known CSF leak in the cervical spine region with blood patches administered intralaminarly in the lumbar spine region (4-6). However, in some instances this treatment approach was ultimately ineffective, requiring the blood patch to be administered directly to the cervical region for complete resolution

of the patient's symptoms (4,5,7). Although epidural blood patches have traditionally been administered blindly to the lumbar epidural region for the treatment of thoracocervical dural puncture headache due to technical ease, increasing reports show that effective treatment requires targeted thoracic or cervical blood patches to control large leaks in the cervical region (7-15). One report even describes administration of a transforaminal epidural blood patch for the treatment of traumatic spinal headache (16). Cervical intralaminar epidural blood patch or transforaminal epidural blood patch may be a reasonable option for cervical post-dural puncture headaches not only intractable to conservative therapy, but also intractable to repeat lumbar intralaminar epidural blood patches.

One of the interesting findings about our case is the initial but short-lived success of the first epidural blood patch; its failure signaled by the return of the orthostatic headache. The failure of the first epidural blood patch to definitively resolve her headache beyond a few days could be due to a number of factors including an incorrect initial diagnosis, presentation of a new and different headache type after the initial resolution of the first presumably post-dural puncture headache, or a suboptimally performed epidural blood patch. On her original presentation and with return of her headache following the initial procedure, we, of course, considered a number of other headache etiologies including things like meningitis, subdural hematoma, intracranial hemorrhage, or cerebral venous thrombosis. The slight laterality of her headache after the first blood patch was essentially the only characteristic that was different compared to her initial presentation. The absence of critical symptoms and signs like seizures, altered level of consciousness, and focal motor or sensory deficits suggested that other more serious diagnoses were likely not causes or contributors to her headache presentation before and after the first blood patch. Furthermore, the maintenance of the postural characteristic of her headache, the clinical context of a documented CSF leak radiographically, and the initial improvement in her headache following the first blood patch supported our belief that her primary headache and the returning headache were due to dural puncture.

It is not entirely surprising that the headache returned after the first blood patch. Although the initial short-term relief from an epidural blood patch can be as high as 100%, the overall long-term relief can range from 60% to 75% (17). However, with the diagnosis likely intracranial hypotension headache associated

with dural puncture as discussed above, suboptimal blood patch seemed to be the more likely cause of the headache return. There are a number of reasons why the first blood patch may have failed. Epidural blood patches are thought to alleviate intracranial hypotension by 2 mechanisms: (1) immediate increase in CSF pressure by tamponade or mass-effect of the blood volume within the extradural space, and (2) eventual "sealing" of the dural perforation by clot and scar formation from autologous blood introduced into the epidural space (3). The patching effect of the injected blood may, in fact, be the more variable aspect of the therapeutic effect of the blood patch compared to the initial pressure restoring aspect (18). Furthermore, in addition to placement less than 24 hours after dural puncture, another suggested risk factor for failure of an epidural blood patch is the use of inadequate volume (18). Indeed, a cervical epidural blood patch must be applied to the specific level of the dural perforation as there may be insufficient volume spread to nearby levels to achieve adequate patching. This patient had a very large CSF leak according to diagnostic imaging, such that the 10 mL of autologous blood injected during the first procedure may have been adequate to elicit immediate relief but inadequate to facilitate sufficient patching of her dural puncture, or insufficient to cause enough scar formation that would sustain moderate increases in intrathecal pressure. Lastly, following administration of autologous blood into the epidural space, it is important that the patient avoid increases in intrathecal pressure, as these increases can theoretically dislodge the newly formed scar. Although not reported by the patient upon return of her headache following the initial blood patch, it is possible that the patient physically overexerted herself resulting in increased intrathecal pressure, dislodgement of the patch, and return of her intracranial hypotension headache.

In light of the plausible reasons for initial blood patch failure, the continued positional character of her headache, and the knowledge that persistent intracranial hypotension headache can lead to increased morbidity, we felt it reasonable to repeat the injection with the intent to use a larger injected volume (greater than 10 mL with a goal of 15-20 mL) as limited by patient discomfort. The natural history of a post-dural puncture headache suggests that most will resolved by about 7 days, with rare occurrences lasting several months (19). Therefore, since the second epidural blood patch was given later in the natural healing process of the initial dural tear, a second epidural blood patch is more likely

to be effective. If the second epidural was again ineffective at giving her sustained headache relief, or if her symptoms changed markedly, alternative diagnoses would have been considered and further evaluation including a repeat CT myelogram pursued. Multiple failed epidural blood patches with known dural tear warrant further investigation and probable surgical intervention.

Although our case required repeated cervical epidural blood patches, it should be noted that similar to lumbar epidural blood patches, cervical epidural blood patches using the targeted catheter technique are not without potential serious complications. These would include things like spinal cord and nerve root compression, epidural abscess, permanent paraplegia, seizures, arachnoiditis, chemical meningitis, injection of blood intrathecally, repeat wet-tap, persistent headache, back pain and neck pain, and facial palsy. For this reason, blood patches, including targeted cervical or transforaminal blood patches, should not be used as first-line therapy. Further, these patients should be monitored closely during the procedure and perhaps for several hours after the procedure is completed.

## CONCLUSION

In conclusion, we presented a case of postural headache due to intracranial hypotension following

therapeutic high cervical epidural steroid injection for cervicogenic neck pain that resolved only after repeated cervical epidural blood patches targeted to the high cervical spine (C2) using passage of a catheter. Interventional pain practitioners performing therapeutic cervical intralaminar or transforaminal epidural steroid injections for cervicogenic headache or neck pain should be cautious of complications like dural puncture associated with these procedures. Intracranial hypotension headaches that are refractory to conservative therapy can be successfully treated with epidural blood patches targeted to the specific level using the catheter approach. Although most headaches resolve after a single appropriately placed blood patch, it is not uncommon for a second epidural blood patch to be required for definitive treatment in cases where there is massive CSF leakage and there is an inability to give appropriate volumes as limited by patient discomfort. Of course, nondiscriminant use of cervical epidural blood patches is not prudent or supported in instances where the headache is no longer postural, or there are critical changes like gross neurological deficits, seizures, or altered level of consciousness suggestive of other, more serious, intracranial etiologies. In these instances, further evaluation and diagnostic modalities should be aggressively pursued.

## REFERENCES

- Inamasu J, Guiot BH. Intracranial hypotension with spinal pathology. *Spine J* 2006; 6:591-599.
- Schievink WI. Spontaneous spinal cerebrospinal fluid leaks and intracranial hypotension. *JAMA* 2006; 295:2286-2296.
- Safa-Tisseront V, Thormann F, Malassine P, Henry M, Riou B, Coriat P, et al. Effectiveness of epidural blood patch in the management of post-dural puncture headache. *Anesthesiology* 2001; 95:334-339.
- Kantor D, Silberstein SD. Cervical epidural blood patch for low CSF pressure headaches. *Neurology* 2005; 65:1138.
- Rai A, Rosen C, Carpenter J, Miele V. Epidural blood patch at C2: Diagnosis and treatment of spontaneous intracranial hypotension. *AJNR Am J Neuroradiol* 2005; 26:2663-2666.
- Franzini A, Zekaj E, Messina G, Mea E, Broggi G. Intracranial spontaneous hypotension associated with CSF cervical leakage successfully treated by lumbar epidural blood patch. *Acta Neurochir (Wien)* 2010; 152:1997-1999.
- Peng PW, Farb R. Spontaneous C1-2 CSF leak treated with high cervical epidural blood patch. *Can J Neurol Sci* 2008; 35:102-105.
- Allegri M, Lombardi F, Custodi VM, Scagnelli P, Corona M, Minella CE, Braschi A, Arienta C. Spontaneous cervical (C1-C2) cerebrospinal fluid leakage repaired with computed tomography-guided cervical epidural blood patch. *J Pain Symptom Manage* 2010; 40:e9-e12.
- Colonna-Romano P, Linton P. Cervical dural puncture and lumbar extradural blood patch. *Can J Anaesth* 1995; 42:1143-1144.
- Hayek SM, Fattouh M, Dews T, Kapural L, Malak O, Mekhail N. Successful treatment of spontaneous cerebrospinal fluid leak headache with fluoroscopically guided epidural blood patch: A report of four cases. *Pain Med* 2003; 4:373-378.
- Cousins MJ, Brazier D, Cook R. Intracranial hypotension caused by cervical cerebrospinal fluid leak: Treatment with epidural blood patch. *Anesth Analg* 2004; 98:1794-1797.
- Donovan JS, Kerber CW, Donovan WH, Marshall LF. Development of spontaneous intracranial hypotension concurrent with grade IV mobilization of the cervical and thoracic spine: A case report. *Arch Phys Med Rehabil* 2007; 88:1472-1473.
- Buvanendran A, Byrne RW, Kari M, Kroin JS. Occult cervical (C1-2) dural tear causing bilateral recurrent subdural hematomas and repaired with cervical epidural blood patch. *J Neurosurg Spine*

- 2008; 9:483-487.
14. Kim SY, Hong JH. Epidural blood patches in a patient with multi-level cerebrospinal fluid leakage that was induced by spontaneous intracranial hypotension. *Korean J Pain* 2010; 23:46-50.
  15. Nipatcharoen P, Tan SG. High thoracic/cervical epidural blood patch for spontaneous cerebrospinal fluid leak: A new challenge for anesthesiologists. *Anesth Analg* 2011; 113:1476-1479.
  16. Weil L, Gracer RI, Frauwirth N. Transforaminal epidural blood patch. *Pain Physician* 2007; 10:579-582.
  17. Taivainen T, Pitkanen M, Tuominen M, Rosenberg PH. Efficacy of epidural blood patch for postdural puncture headache. *Acta Anaesthesiol Scand* 1993; 37:702-705.
  18. Hurley RW, Jerman JD, Benzon HT. *Postmeningeal puncture headache and spontaneous intracranial hypotension. Essentials of Pain Medicine.* 3rd edition. Elsevier Saunders, Philadelphia, 2011, pp 272-277.
  19. Vandam LD, Dripps RD. Long-term follow-up of patients who received 10,098 spinal anesthetics: Syndrome of decreased intracranial pressure (headache and ocular and auditory difficulties). *JAMA* 1956; 161:586-591.