

Preliminary Prospective Study

Preliminary Results of the Clinical Effectiveness of Percutaneous Adhesiolysis Using a Racz Catheter in the Management of Chronic Pain Due to Cervical Central Stenosis

Chan Hong Park, MD, PhD¹, Sang-Ho Lee, MD, PhD², and Sang-Chul Lee, MD, PhD³

From:¹Department of Anesthesiology and Pain Medicine, Daegu Wooridul Spine Hospital, Daegu, South Korea;

²Department of Neurosurgery, Seoul Wooridul Spine Hospital, Seoul, South Korea; and

³Department of Anesthesiology and Pain Medicine, Seoul National University Hospital, Seoul, South Korea

Address Correspondence:
Chan Hong Park
Daegu Wooridul Spine Hospital
648 Gukchaebosang-ro,
Jung-gu, Daegu,
South Korea 700732
E-mail: magary1@hanmail.net

Disclaimer: There was no external funding in the preparation of this manuscript.
Conflict of interest: None.

Manuscript received: 01-23-2013
Revised manuscript received:
03-04-2013
Accepted for publication:
03-26-2013

Free full manuscript:
www.painphysicianjournal.com

Background: Cervical central stenosis (CCS) is a narrowing of the spinal canal that can cause mechanical compression of the spinal nerve and roots, leading to neck pain and/or radicular pain. Cervical epidural steroid injections are commonly used in the treatment of CCS. After failure of epidural steroid injections, the next sequential step is percutaneous adhesiolysis with a targeted drug delivery.

Objective: The aim of our study is to evaluate the effectiveness of percutaneous cervical epidural adhesiolysis in patients with chronic posterior neck pain and upper extremity pain due to CCS.

Study Design: This was a preliminary, prospective study.

Methods: Thirty-nine patients with CCS were enrolled and all subjects underwent cervical spine magnetic resonance imaging. All patients received percutaneous adhesiolysis and appropriate placement of a Racz catheter®, followed by an injection of 5 mL of 0.2 % preservative-free ropivacaine containing 1,500 units of hyaluronidase and 4 mg of dexamethasone. In the recovery room, each patient also received 6 mL of 10% hypertonic sodium chloride solution, after which the catheter was removed. Outcome measures were obtained using a 5-point patient's satisfaction scale at 2 weeks and at 6 months post-treatment. To evaluate treatment effectiveness, we divided the patients into 2 groups according to their treatment response.

Limitations: Secondary outcomes were not measured. The study did not include a long-term follow-up period or control group.

Results: Improvement designated as reports of moderate pain, little pain, and no pain was observed in 30 patients (77.0 %) at 2 weeks and 28 patients (71.8 %) at 6 months after the procedure. There was no statistically significant correlation between pain relief and the severity of CCS.

Conclusion: Percutaneous adhesiolysis utilizing local anesthetic steroids and hypertonic sodium chloride solution may be an effective management strategy in patients with chronic posterior neck and upper extremity pain due to cervical central spinal stenosis, although there is no correlation between therapeutic response and the grade of CCS.

Key words: Neck, spinal stenosis, cervical vertebra, adhesiolysis

Pain Physician 2013; 16:353-358

Cervical central stenosis (CCS) is a common degenerative disease defined as a narrowing of the spinal canal by both bone and soft tissues, capable of causing mechanical compression of the spinal nerve roots (1-3). The compression of these nerve roots can be asymptomatic, but it can also result in weakness, alteration in reflexes, motor and sensory changes, radicular pain, or atypical arm pain.

Cervical epidural steroid injection (CESI) is commonly used in patients with cervical stenosis or disc herniation (4,5). Kwon et al (4) reported that 60 - 86% of patients with herniated discs experienced significant pain relief with CESI. In a study by Lee et al (6) more than 80% of surgical candidates with cervical radiculopathy were able to avoid surgery with this treatment. Lee et al (6) also reported that there were no significant differences in outcome parameters or radiological factors between surgical and non-surgical patients after CESI, including the location of the disc herniation (central vs. foraminal vs. or both), the neural compression ratio, and the incidence of multilevel nerve compression.

Percutaneous epidural adhesiolysis is used in patients with refractory chronic low back pain or following failed back surgery syndrome (7). The goal of adhesiolysis is to eliminate problematic adhesions while enabling targeted delivery of medications. Percutaneous adhesiolysis involves multidrug use (local anesthetic delivery, steroid administration, and hypertonic sodium chloride) (8).

The degree of radiographic CCS has not been shown to be correlated with clinical symptoms (9). In the lumbar region, neither the lumbar dural sac cross sectional area nor the spinal canal dimensions correlate with the efficacy of adhesiolysis or epidural steroid injection for pain symptoms (10,11).

To the best of our knowledge, the response to percutaneous adhesiolysis and the correlation between the degrees of CCS has not yet been clearly established. One aim of this study is to evaluate the role of percutaneous adhesiolysis with hypertonic sodium chloride solution, and to determine the relationship between the severity of CCS and the patient's response to percutaneous adhesiolysis in patients with chronic intractable pain secondary to cervical central spinal stenosis.

METHODS

Study Design

Thirty-nine patients with CCS were enrolled in this prospective study. The diagnosis of CCS was made

based on clinical symptoms, neurological examinations, and imaging studies that included plain radiography as well as magnetic resonance imaging (MRI) of the cervical spine. Our Institutional Review Board approved our study and all subjects gave written informed consent.

Participants

The inclusion criteria for the current study were as follows: (1) a diagnosis of CCS was present, accompanied by neck pain, arm pain, and/or neurological symptoms; (2) pain did not improve after more than 4 weeks of conservative treatment including physical therapy, chiropractic manipulation, exercises, drug therapy, and bed rest; (3) clear evidence of CCS was present on MRI cross-sectional images confirmed by our radiologists as well as by outside radiologic reports; (4) the patient had also failed to respond appropriately to fluoroscopically directed epidural injections. Exclusion criteria were as follows: (1) unclear symptom descriptions; (2) foraminal or extraforaminal stenosis on the cross-sectional MRI; (3) prior neck surgery; (4) definite motor weakness with a muscle grade lower than IV; (5) symptoms of myelopathy; (6) no cerebrospinal fluid seen around the cord on the MRI.

All subjects underwent cervical spine MRI (Achieva 1.5T, Philips, Netherland). T2 sagittal images were obtained. The image matrix was 296 X 188 pixels, the field of view was 16 cm, the section thickness was 4 mm, the intersection gap was 0.44 mm, and the echo train length was 25.

Grading of CCS was assigned using the following system: grade 0, absence of canal stenosis; grade 1, subarachnoid space obliteration exceeding 50%; grade 2, spinal cord deformity; and grade 3, spinal cord signal change (9) (Figs. 1-3). Two radiologists, both blinded to the patient's clinical symptoms and prior radiologic reports scored the images.

All percutaneous adhesiolysis procedures were performed in the operating room. With the patient in a prone position, the needle insertion site was prepared with betadine and draped. A 15-gauge, 3-1/2-inch RX epidural needle was introduced into the T1-T2 interspace with the tip needle directed toward the midline. Once the needle placement was confirmed via loss of resistance, 0.5 mL of contrast agent (Omnipaque® 300) was injected. We confirmed that there was no intravascular or subarachnoid placement of the needle; if such mal-positioning occurred, the needle was repositioned. After the appropriate confirmation with epidurography, a Racz epidural catheter was advanced through the RX needle into the area of the filling defect or the site

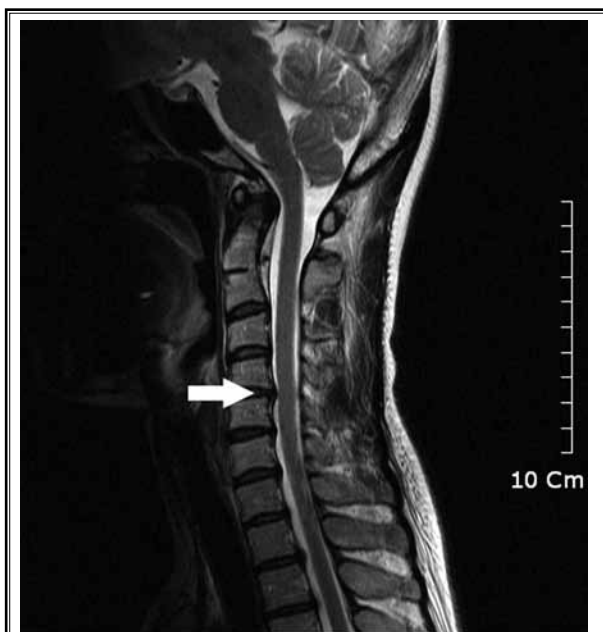

Fig 1. A 43-year-old woman with cervical canal stenosis. Sagittal T2-weighted fast spin-echo image shows grade 1 stenosis with obliteration of CSF space exceeding 50% of the arbitrary subarachnoid space at the C4-5 level (arrow).

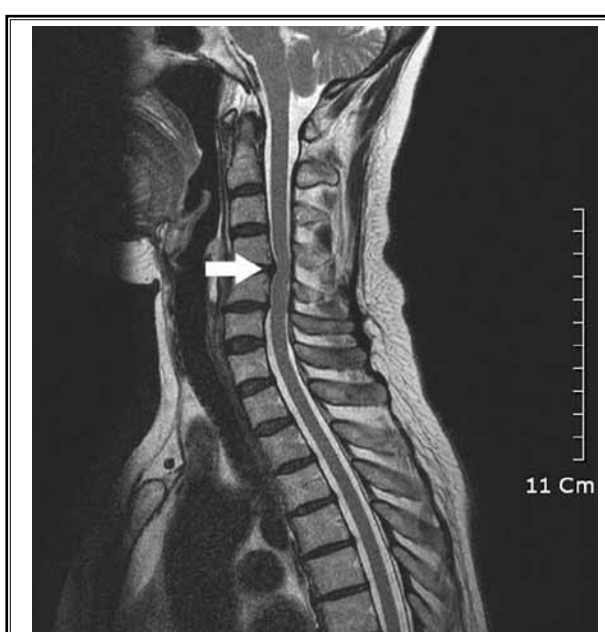

Fig 2. A 55-year-old woman with cervical canal stenosis. Sagittal T2-weighted fast spin-echo image shows grade 2 stenosis at the C4-5 level (arrow). The spinal cord is compressed and deformed but displays no signal changes.

of pathology, as determined by MRI. Adhesiolysis was then carried out, and the final positioning was achieved in the epidural space and into the lateral and ventral epidural space. Following the satisfactory positioning of the catheter, at 0.5-1 mL of contrast was injected (Fig. 4). If no subarachnoid, intravascular, or other extra epidural filling occurred and satisfactory filling was obtained with the epidural and targeted regions, 5 mL of 0.2 % preservative-free ropivacaine containing 1,500 units of hyaluronidase and 4 mg of dexamethasone was injected. To reduce the chance of loculation of the injected contents, the slow injection continued until the contrast was seen exiting the neural foramen from the epidural space, after which the patient was asked to rotate their head and neck from left to right (chin tuck rotation). One hour following the procedure, 6 mL of 10% sodium chloride solution was epidurally infused over 30 min in the recovery room under monitoring. The intravenous line and epidural catheter were removed and the patient was discharged if all parameters were satisfactory. The first follow-up was performed 2 weeks following the procedure. During this time, all subjects received non-steroidal anti-inflammatory drugs (NSAIDs) and muscle relaxants. In addition, patients who were non-responsive to this therapy were given opioid

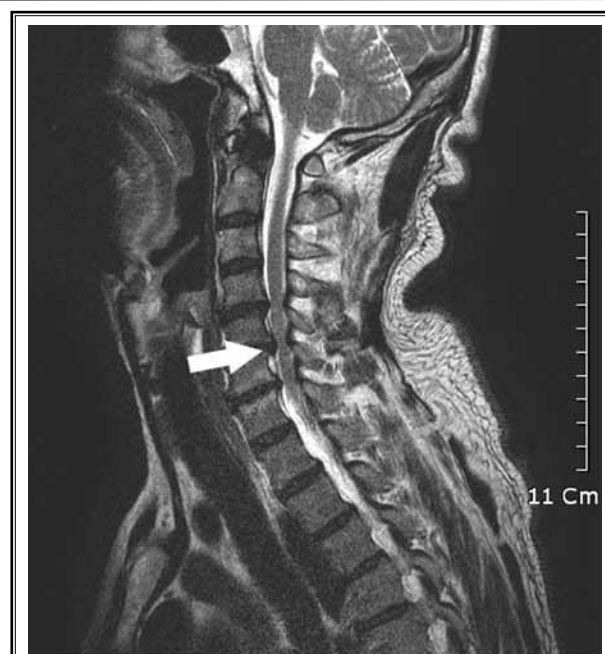

Fig 3. A 52-year-old man with cervical canal stenosis. Sagittal T2-weighted fast spin-echo image shows grade 3 cervical canal stenosis at the C5-6 level (arrow). The spinal canal is significantly narrowed at this level, and the signal intensity of the spinal cord is increased at the corresponding level.

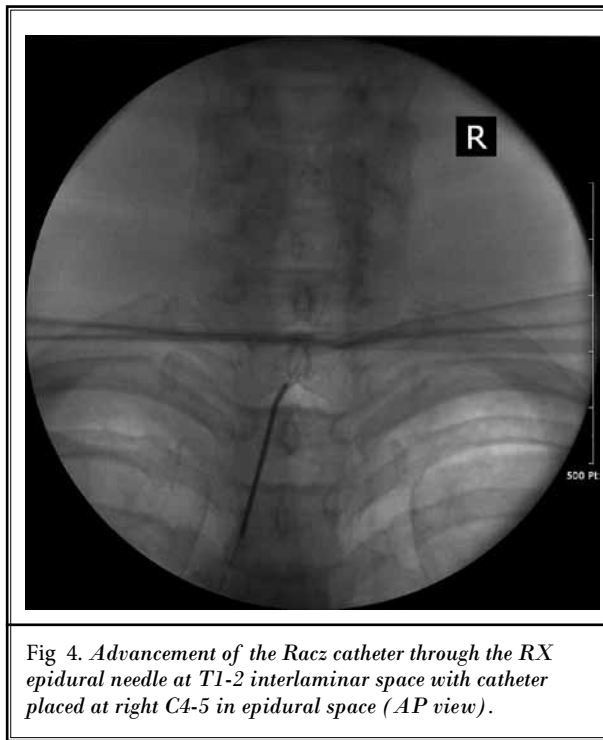


Fig 4. Advancement of the Racz catheter through the RX epidural needle at T1-2 interlaminar space with catheter placed at right C4-5 in epidural space (AP view).

or non-opioid analgesics after the first follow-up visit.

Outcome measures were obtained at 2 weeks and 6 months post-procedure using the Roland 5-point Patient's Satisfaction Scale. Using this scale, 0 indicated the absence of pain, 1 indicated little pain, 2 indicated moderate pain, 3 indicated bad pain, 4 indicated very bad pain, and 5 indicated almost unbearable pain (12). To evaluate the correlations between pain reduction and severity of CCS, we divided the patients into 2 groups according to their procedure response. These groups corresponded to those patients reporting improvement (Roland scale 0-2) or no improvement (Roland scale 3-5).

Statistical Analysis

A sample size of 39 was specified in advance to provide 80% power to detect a difference in the mean between treatments (G^* power 3). The correlation between pain relief and CCS grading system score was evaluated using the Chi-square test. A P-value of less than or equal to 0.05 was considered statistically significant.

RESULTS

The 39 patients ranged in age from 28 to 71 years, had a mean age of 52.7 years and were comprised of 19 men and 20 women. Table 1 displays the levels and sites of the affected regions and the frequency of ste-

Table 1. Patient characteristics.

N = 39	Frequency	Percentage (%)
Sex		
Male	19	48.7
Female	20	51.3
Procedure level		
C3-4	1	2.6
C4-5	3	7.7
C5-6	10	25.6
C6-7	25	64.1
Grade		
1	17	48.7
2	11	28.2
3	11	28.2

nosis grades. The C6-7 level was the most frequently implicated and grade 1 was seen in 17 patients (48.7%).

Improvement (indication of no pain, little pain, or moderate pain) following the procedure was observed in 30 patients (77.0%) and 28 patients (71.8%) at 2 weeks and 6 months, respectively (Table 2). Three patients underwent spinal surgery during the follow-up period. There was no statistically significant correlation between pain relief and the grade of CCS at either 2 weeks or 6 months (Tables 3, 4).

DISCUSSION

We demonstrated pain reduction in 71% of patients with CCS at 6 months after percutaneous adhesiolysis, with no apparent correlation between pain relief and the severity of CCS. The results of this present study propose that percutaneous adhesiolysis with targeted delivery of medication is superior to cervical interlaminar epidural injections in central spinal stenosis, specifically in those who have failed to respond to fluoroscopically directed cervical epidural injections.

The benefits of adhesiolysis are attributable to dissolution of adhesions, enabling various drugs (local anesthetics, steroids, and hypertonic sodium chloride solution) to target affected sites (13). Corticosteroids have been shown to reduce inflammation by inhibiting the synthesis of a number of pro-inflammatory mediators (14). Local anesthetics also have been described as providing short- to long-term symptomatic relief based on various mechanisms, including separation of nociceptive discharge, blockade of the sympathetic reflex arc and sensitization, anti-inflammatory effect, and blockade of axonal transport of nerve fibers (15). In addition, 10% hypertonic sodium chloride solution

has been shown to provide analgesia and adhesiolysis (16).

In our study, there was no relationship between the severity of CCS and the analgesic effect of adhesiolysis. Several factors, including duration of symptoms, age, and pain etiology, can affect the pain-relief prognosis for epidural steroid injection (4,5,17,18). As the space for neural structures becomes smaller with advanced stenosis, the risk of developing motor disturbances of medullary or radicular origin increases (19). Therefore, our expectation was that patients with a higher degree of CCS severity would have less reduction in their pain, but this was not evidenced in our result. We are not able to specify an exact reason for this, but we hypothesize that the mechanism of pain in spinal stenosis may be complex, and although the inflammatory effects of mechanical nerve root compression are considerable, they are not the sole determinants of pain (20). Nerve root compromise is known to occur less easily in disc CCS than herniation or foraminal stenosis (18) and dynamic stenosis has been reported as a contributing element (21). Hence, uniplanar spinal canal dimensions, as seen on MRI, may not fully reflect the pathology of spinal stenosis (11), and the inconsistencies between symptoms and degree of spinal canal stenosis may be explained by the our use of static images to assess what is actually a dynamic process (22). In addition, Lee et al (6) reported that the percentage of patients with neural compression ratio after CESI is not significantly different between the nonsurgical and surgical groups. In our present study, 3 patients had subsequent surgery during follow-up due to lack of pain reduction. These 3 patients had more increased pain pre-procedurally and good pain relief post-operatively.

Epidural fibrosis is a common phenomenon following lumbar laminectomy (23), but it may also develop in the absence of such surgery (24,25). In this study, our patients did not have prior surgical procedures. Hyaluronidase was used because it is thought that it may relieve tissue edema and is more likely to open up lateral run-off (25-27).

In our study, there were no complications related to the procedure, including hematomas or loculations (28). If catheter contrast injection showed venous run-off, the catheter was withdrawn and re-injected until contrast remained within the epidural space. If fluid spread from the injection site to the opposite of spinal canal, the spinal cord risked compression from both sides, perivenous or spread (PVSC) (28). Immediately

Table 2. Response after percutaneous adhesiolysis as assessed by the 5-point patient satisfaction scale.

Response	2 weeks (n = 39)	6 months (n = 39)
Little pain	15 (38.5%)	15 (38.5%)
Moderate pain	15 (38.5%)	13 (33.3%)
Bad pain	6 (15.4%)	8 (20.5%)
Very bad pain	3 (7.7%)	0
Surgery	0	3 (7.7%)

Table 3. Comparison of grade of CCS and patient response at 2 week follow-up.

N = 39	Little pain	Moderate pain	Bad pain	Very bad pain	Total	P
Grade 1	5	10	1	1	17	0.911
Grade 2	4	3	4	0	11	
Grade 3	6	2	1	2	11	
Total	15	15	6	3	39	

Table 4. Comparison of grade of CCS and patient response at 6 month follow-up.

N = 36	Little pain	Moderate pain	Bad pain	Total	P
Grade 1	5	9	2	16	0.379
Grade 2	4	2	5	11	
Grade 3	6	2	1	19	
Total	15	13	6	36	

after all medication injections, our patients performed repetitive chin to shoulder flexion rotations until lateral run off was seen. Also to reduce the chance of dural puncture, we used a blunt-tipped epidural needle instead of a sharp-tipped epidural needle.

There are several limitations to the present study. Aside from the small sample size and brief follow-up interval, procedural outcomes were measured as subjective patient pain scores. Alternative treatment endpoints such as functional status, medication requirements, or psychological effects were not addressed. We also did not include variable factors affecting the prognosis of percutaneous adhesiolysis. Finally, we did not differentiate between neck pain and arm pain.

CONCLUSION

In conclusion, percutaneous adhesiolysis is effective for the treatment of CCS in patients whose pain

is refractory to conventional conservative remedies, although there is no correlation between therapeutic response and the grade of CCS. Further follow-up studies are required.

ACKNOWLEDGMENTS

The authors thank HJ Yoon, RN, and EY Guak, RN, for the preparation of this manuscript.

REFERENCES

- Epstein BS, Epstein JA, Jones MD. Cervical spinal stenosis. *Radiol Clin North Am* 1977; 15:215-226.
- Moyano M. [Anatomical observations on stenosis of the cervical spinal canal secondary to intervertebral disk diseases. Possible correlations with cervical myelopathy]. *Chir Organi Mov* 1970; 58:316-329.
- Lamothe G, Muller F, Vital JM, Goossens D, Barat M. Evolution of spinal cord injuries due to cervical canal stenosis without radiographic evidence of trauma (SCI-WORET): A prospective study. *Ann Phys Rehabil Med* 2011; 54:213-224.
- Kwon JW, Lee JW, Kim SH, Choi JY, Yeom JS, Kim HJ, Kwack KS, Moon SG, Jun WS, Kang HS. Cervical interlaminar epidural steroid injection for neck pain and cervical radiculopathy: Effect and prognostic factors. *Skeletal Radiol* 2007; 36:431-436.
- Lin EL, Lieu V, Halevi L, Shamie AN, Wang JC. Cervical epidural steroid injections for symptomatic disc herniations. *J Spinal Disord Tech* 2006; 19:183-186.
- Lee SH, Kim KT, Kim DH, Lee BJ, Son ES, Kwack YH. Clinical outcomes of cervical radiculopathy following epidural steroid injection: A prospective study with follow-up for more than 2 years. *Spine (Phila Pa 1976)* 2012; 37:1041-1047.
- Manchikanti L, Saini B, Singh V. Spinal endoscopy and lysis of epidural adhesions in the management of chronic low back pain. *Pain Physician* 2001; 4:240-265.
- Manchikanti L, Cash KA, McManus CD, Pampati V, Singh V, Benyamin R. The preliminary results of a comparative effectiveness evaluation of adhesiolysis and caudal epidural injections in managing chronic low back pain secondary to spinal stenosis: A randomized, equivalence controlled trial. *Pain Physician* 2009; 12:E341-354.
- Kang Y, Lee JW, Koh YH, Hur S, Kim SJ, Chai JW, Kang HS. New MRI grading system for the cervical canal stenosis. *AJR Am J Roentgenol* 2011; 197:W134-140.
- Park CH, Lee SH, Jung JY. Dural sac cross-sectional area does not correlate with efficacy of percutaneous adhesiolysis in single level lumbar spinal stenosis. *Pain Physician* 2011; 14:377-382.
- Campbell MJ, Carreon LY, Glassman SD, McGinnis MD, Elmlinger BS. Correlation of spinal canal dimensions to efficacy of epidural steroid injection in spinal stenosis. *J Spinal Disord Tech* 2007; 20:168-171.
- Roland M, Morris R. A study of the natural history of back pain. Part I: development of a reliable and sensitive measure of disability in low-back pain. *Spine (Phila Pa 1976)* 1983; 8:141-144.
- Boswell MV, Trescot AM, Datta S, Schultz DM, Hansen HC, Abdi S, Sehgal N, Shah RV, Singh V, Benyamin RM, Patel VB, Buenaventura RM, Colson JD, Cordner HJ, Epter RS, Jasper JF, Dunbar EE, Atluri SL, Bowman RC, Deer TR, Swicegood JR, Staats PS, Smith HS, Burton AW, Kloth DS, Giordano J, Manchikanti L; American Society of Interventional Pain Physicians. Interventional techniques: Evidence-based practice guidelines in the management of chronic spinal pain. *Pain Physician* 2007; 10:7-111.
- Lee HM, Weinstein JN, Meller ST, Hayashi N, Spratt KF, Gebhart GF. The role of steroids and their effects on phospholipase A2. An animal model of radiculopathy. *Spine (Phila Pa 1976)* 1998; 23:1191-1196.
- Cassuto J, Sinclair R, Bonderovic M. Anti-inflammatory properties of local anesthetics and their present and potential clinical implications. *Acta Anaesthesiol Scand* 2006; 50:265-282.
- Racz GB, Heavner JE, Trescot A. Percutaneous lysis of epidural adhesions--evidence for safety and efficacy. *Pain Pract* 2008; 8:277-286.
- Cyteval C, Thomas E, Decoux E, Sarrahere MP, Cottin A, Blotman F, Taourel P. Cervical radiculopathy: Open study on percutaneous periradicular foraminal steroid infiltration performed under CT control in 30 patients. *AJNR Am J Neuroradiol* 2004; 25:441-445.
- Fish DE, Kobayashi HW, Chang TL, Pham Q. MRI prediction of therapeutic response to epidural steroid injection in patients with cervical radiculopathy. *Am J Phys Med Rehabil* 2009; 88:239-246.
- Debois V, Herz R, Berghmans D, Hermans B, Herregodts P. Soft cervical disc herniation. Influence of cervical spinal canal measurements on development of neurologic symptoms. *Spine (Phila Pa 1976)* 1999; 24:1996-2002.
- Arbit E, Pannullo S. Lumbar stenosis: A clinical review. *Clin Orthop Relat Res* 2001; 384:137-143.
- Inufusa A, An HS, Lim TH, Hasegawa T, Haughton VM, Nowicki BH. Anatomic changes of the spinal canal and intervertebral foramen associated with flexion-extension movement. *Spine (Phila Pa 1976)* 1996; 21:2412-2420.
- Sirvanci M, Bhatia M, Ganiyusufoglu KA, Duran C, Tezer M, Ozturk C, Aydogan M, Hamzaoglu A. Degenerative lumbar spinal stenosis: Correlation with Oswestry Disability Index and MR imaging. *Eur Spine J* 2008; 17:679-685.
- Fritsch EW, Heisel J, Rupp S. The failed back surgery syndrome: reasons, intraoperative findings, and long-term results: A report of 182 operative treatments. *Spine (Phila Pa 1976)* 1996; 21:626-633.
- Cooper RG, Freemont AJ, Hoyland JA, Jenkins JP, West CG, Illingworth KJ, Jayson MI. Herniated intervertebral disc-associated periradicular fibrosis and vascular abnormalities occur without inflammatory cell infiltration. *Spine (Phila Pa 1976)* 1995; 20:591-598.
- Parke WW, Watanabe R. Adhesions of the ventral lumbar dura. An adjunct source of discogenic pain? *Spine (Phila Pa 1976)* 1990; 15:300-303.
- Kim SB, Lee KW, Lee JH, Kim MA, Kim BH. The additional effect of hyaluronidase in lumbar interlaminar epidural injection. *Ann Rehabil Med* 2011; 35:405-411.
- Yousef AA, EL-Deen AS, Al-Deeb AE. The role of adding hyaluronidase to fluoroscopically guided caudal steroid and hypertonic saline injection in patients with failed back surgery syndrome: A prospective, double-blinded, randomized study. *Pain Pract* 2010; 10:548-553.
- Racz GB, Heavner JE. Cervical spinal canal loculation and secondary ischemic cord injury--PVCS--perivenous counter spread--danger sign! *Pain Pract* 2008; 8:399-403.