

Prospective Evaluation

## Effectiveness of Percutaneous Transforaminal Adhesiolysis in Patients with Lumbar Neuroforaminal Spinal Stenosis

Chan-Hong Park, MD, PhD<sup>1</sup>, and Sang Ho Lee, MD, PhD<sup>2</sup>

From: <sup>1</sup>Department of Anesthesiology and Pain Medicine, Daegu Wooridul Spine Hospital, Daegu, South Korea  
<sup>2</sup>Department of Neurosurgery, Seoul Wooridul Spine Hospital, Seoul, South Korea

Address Correspondence:  
Chan Hong Park  
Daegu Wooridul Spine Hospital  
648 Gukchaebosang-ro,  
Jung-gu, Daegu,  
South Korea 700732  
E-mail: magaryu@hanmail.net

Disclaimer: There was no external funding in the preparation of this manuscript.  
Conflict of interest: None.

Manuscript received: 07-21-2012  
Revised manuscript received: 08-28-2012  
Accepted for publication: 09-21-2012

Free full manuscript:  
[www.painphysicianjournal.com](http://www.painphysicianjournal.com)

**Background:** Lumbar foraminal spinal stenosis (LFSS) is a narrowing of the bony exit of a nerve root, which causes mechanical compression of spinal nerve roots. Low back pain and/or leg pain, and possibly neurogenic claudication, may result due to mechanical neural compression. Transforaminal epidural steroid injections (TFESIs) are commonly used for treating LFSS. Patients refractory to TFESIs may benefit from percutaneous epidural adhesiolysis.

**Objective:** Our intent was to assess transforaminal adhesiolysis (TFA) as treatment for LFSS, analyzing patient response by severity of stenosis and evaluating the short-term effectiveness of TFA.

**Study Design:** Prospective study.

**Methods:** Following IRB approval, 35 patients with LFSS were enrolled, all of whom underwent magnetic resonance imaging (MRI) of the lumbar spine. Sagittal MRI views were evaluated to grade the severity of LFSS. TFA was routinely conducted in the operating room. One hour after the procedure, each patient received 6 mL of 10% sodium chloride, infused over 30 minutes, with monitoring. Posttreatment outcomes were determined at 2 weeks and 3 months using a 5-point patient satisfaction scale. To test predictive value, patients were stratified by response (improvement versus no improvement).

**Results:** Improvement (defined as little pain, moderate pain, or no pain) was observed in 25 patients (71.4%) at 2 weeks and in 22 patients (62.8%) at 3 months following the procedure. Among patients showing improvement, those with Grade 3 spinal stenosis outnumbered those with Grade 2. At the 3-month follow-up, no statistically significant correlations between pain relief and the grade of LFSS was evident.

**Limitations:** Secondary outcomes were not measured and the follow-up period was relatively brief.

**Conclusion:** Short-term results indicate that percutaneous TFA is an effective treatment for LFSS, although therapeutic outcomes and the severity of LFSS showed no correlation.

**Key words:** Lumbar, foraminal stenosis, adhesiolysis, effectiveness.

**Pain Physician 2013; 16:E37-E43**

Lumbar foraminal spinal stenosis (LFSS) is a disorder marked by narrowing of the bony exit of a nerve root. Its cause includes diminished intervertebral disc height, osteoarthritic changes of

facet joints, cephalad subluxation of the superior articular process of the inferior vertebra, and buckling of the ligamentum flavum or protrusion of the annulus fibrosus (1,2). Afflicted patients may or

may not display signs/symptoms, such as weakness, reflex alterations, gait disturbances, motor and sensory changes, radicular pain or atypical leg pain, and neurogenic claudication (3,4). Stenosis may develop in any region of the spinal canal, including the central zone or lateral recess and foraminal or extraforaminal sites (3,5-8). Involvement of the lateral spinal canal is a common source of lumbar radicular pain (9).

Lumbar epidural steroid injections are commonly used to treat LFSS (4,10-14), albeit with inconsistent results (12). Botwin et al (15) cited positive long-term outcomes in 75% of patients with > 50% reduction in postinjection pain scores (versus baseline) at an average of 1.9 transforaminal epidural steroid injections per patient.

Percutaneous epidural adhesiolysis is used in patients with refractory chronic low back pain or following failed back surgery syndrome (13,16). With failed back surgery syndrome, epidural fibrosis may account for 20%-36% of cases (17). Proliferation of fibrous tissue in the epidural space effectively tethers the dura and nerve roots, causing a significant subset of patients to experience chronic low back and lower extremity pain (18). The goal of adhesiolysis is to eliminate problematic adhesions while enabling the targeted delivery of medications. Indeed, percutaneous adhesiolysis does facilitate multidrug use (local anesthetic delivery, steroid administration, and hypertonic sodium chloride) (19). With this approach for lumbar central stenosis (LCSS), 2 publications report significant pain relief ( $\geq 50\%$ ) in 66% of patients at 6 months follow-up, and 76% at one year follow-up (19,20).

When analyzing patients by their degree of lumbar spinal stenosis (20-22), there is no distinct correlation with clinical symptoms, Oswestry Disability Index scores, or clinical outcomes after adhesiolysis (5,20,21). Park et al (20) studied the relationship between the dural cross-sectional area and the effectiveness of percutaneous adhesiolysis in LCSS. They showed that the dimensions of the spinal canal do not correlate with the success or failure of percutaneous adhesiolysis in this setting (20).

To our knowledge, there are no published studies examining patients' responses to percutaneous transforaminal adhesiolysis (PTFA) by degree/severity of LFSS. The aim of the current study was to examine the relationship between the grade of LFSS and patient response to lumbar PTFA, focusing on short-term outcome.

## **METHODS**

### **Study Design**

Thirty-five patients were enrolled in the study; each had a diagnosis of LFSS made based on clinical symptoms, neurologic examinations, and confirmatory radiographic evidence (plain films and magnetic resonance imaging [MRI] of the lumbar spine). The study was approved by our Institutional Review Board and each patient signed an informed consent form.

Inclusion criteria were symptomatic LFSS with leg pain and diagnostic confirmation of LFSS by sagittal and cross-sectional spinal MRI. Exclusion criteria were unclear or questionable symptoms; central, paracentral, or extraforaminal stenosis on cross-sectional MRI views, and spondylolisthesis or previous back surgery.

All patients underwent lumbar spinal MRI. T1-weighted spin echo sagittal and axial images and T2-weighted fast spin echo sagittal and axial images were obtained (slice thickness, 4 mm; slice gap, 0.44 mm; field of view 32 cm for sagittal images and 16 cm for axial images; matrix 512x 512). The grade of LFSS was assigned according to the LFSS grading system: Grade 1 is defined as mild LFSS, in which there is perineural fat obliteration in 2 opposing directions, vertical or transverse; Grade 2 is defined as moderate LFSS, in which perineural fat obliteration is seen in 4 directions without morphologic change in both vertical and transverse direction; and Grade 3 is defined as severe LFSS, in which nerve root collapse or morphologic change can be observed (23). The status of LFSS was evaluated via conventional sagittal magnetic resonance images as needed. Two radiologists blinded to the corresponding clinical symptoms and radiologic reports scored the images (Figs. 1,2).

All PTFA procedures were performed in a surgical operating room. With the patient in the prone position, the site of needle insertion was sterilized with povidone iodine and draped. The targeted disc endplates were aligned as for discography, with an appropriate caudal or cranial tilt of the C-arm. The beam was then rotated so that the lateral surface of the superior articular process (SAP) bisected the interspace. An RK epidural needle was advanced slowly and cautiously past the lateral surface of the SAP, avoiding penetration of both the segmental nerve and the disc (Fig 3). Lateral radiographic imaging was also used while advancing past the SAP to minimize the risk of disc penetration. After confirming the appropriate placement of the epidural needle, a Racz catheter was advanced through the RK epidural needle to the area of the filling defect or the

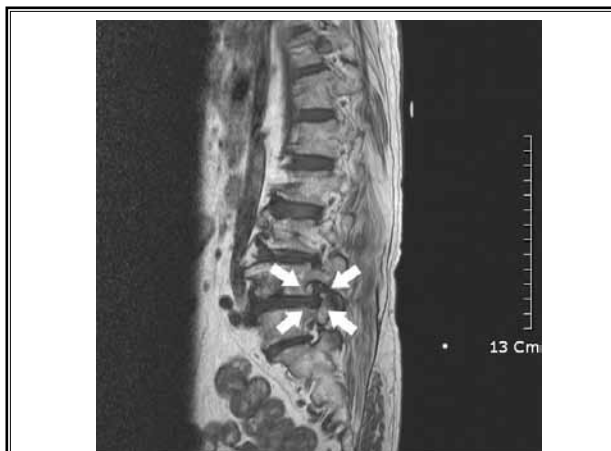

Fig. 1. Grade 2 foraminal stenosis: T1-weighted sagittal image of 65-year-old man with right lower extremity pain shows narrowing of intervertebral disc space, thickened ligamentum flavum, and focal disk protrusion in foraminal zone due to perineural fat obliteration surrounding nerve (arrows).

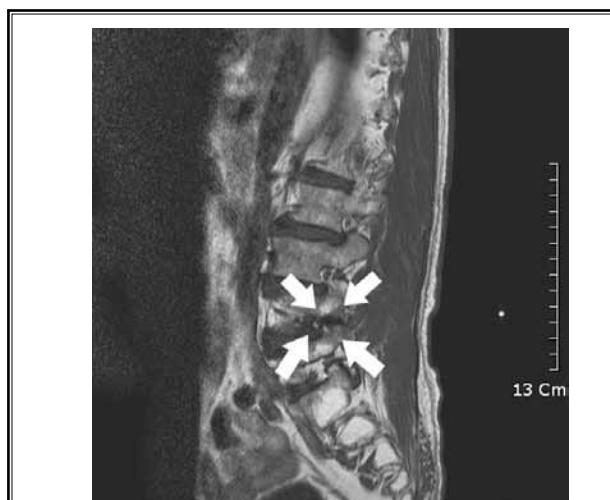

Fig. 2. Grade 3 foraminal stenosis: T1-weighted sagittal image of 76-year-old woman with right lower extremity pain shows compressed right L4-L5 nerve root (arrows).

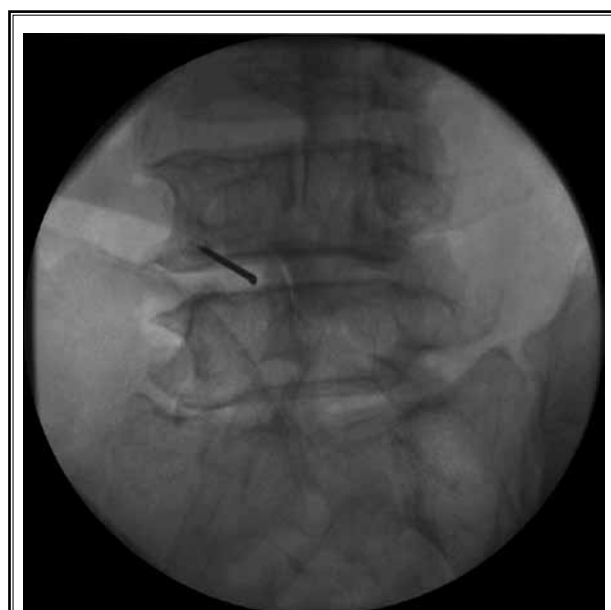

Fig. 3. Advancement of RK epidural needle toward superior articular process.

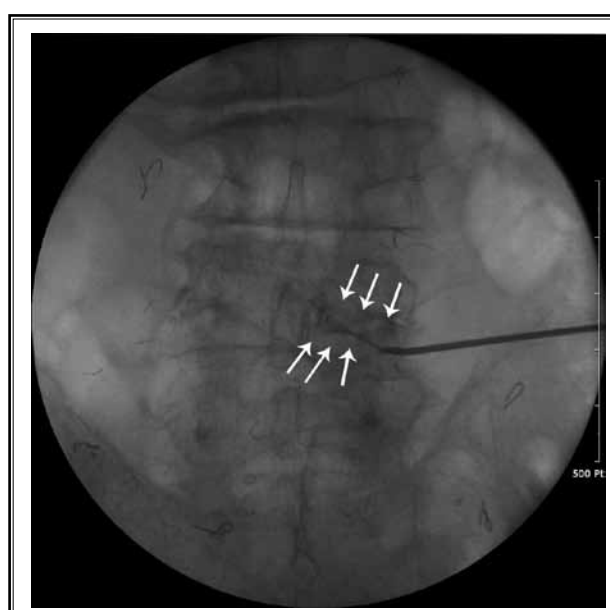


Fig. 4. Advancement of Racz catheter through RK epidural needle at right L4 intervertebral foramen with catheter placed in epidural space (anteroposterior view)

site of pathology, as determined by MRI. Adhesiolysis was then carried out with active manipulation, and the desired intraforaminal positioning of the catheter was achieved (Fig. 4). Given satisfactory catheter placement, contrast medium (one mL at minimum) was injected (Fig. 5). With no subarachnoid, intravascular, or other extra-epidural filling but satisfactory filling of the epidural

and targeted regions, 5 mL of 0.2% preservative-free ropivacaine containing 1,500 units of hyaluronidase and 40 mg of triamcinolone was injected (Figs 6A-C).

One hour following the procedure, 10% sodium chloride solution (6 mL) was given epidurally over a 30 minute period in the recovery room (with monitoring). The intravenous line and epidural catheter were then

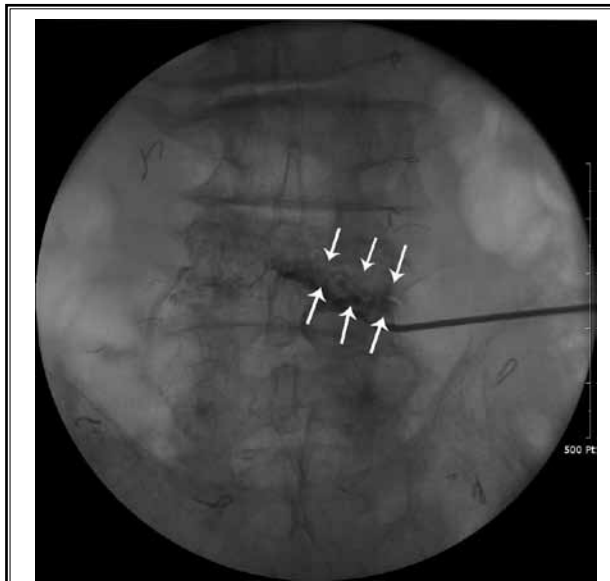


Fig 5. Spread of contrast at right L4 nerve root after PTEA (anteroposterior view).

removed and the patient was discharged, provided all parameters were satisfactory. The first follow-up visit was 2 weeks later. Meanwhile, all patients were treated with NSAIDs and muscle relaxants. Nonresponders were given opioid or nonopioid analgesics after the first follow-up exam. For the duration of follow-up, no caudal, interlaminar, or transforaminal epidural steroid injections were administered.

Outcomes were measured at 2 weeks and at 3 months post-PTFA, using a 0 to 5-point patient satisfaction scale to gauge pain status (no pain, little pain, moderate pain, bad pain, very bad pain, almost unbearable pain). To analyze pain relief by grade of LFSS, we stratified patients into 2 groups: those who reported improvement (no pain, little pain, moderate pain) and those who did not (bad pain, very bad pain, or almost unbearable pain).

### Statistical Analysis

The relationship between pain relief and grade of LFSS was evaluated by the Cochran-Mantel-Haenszel

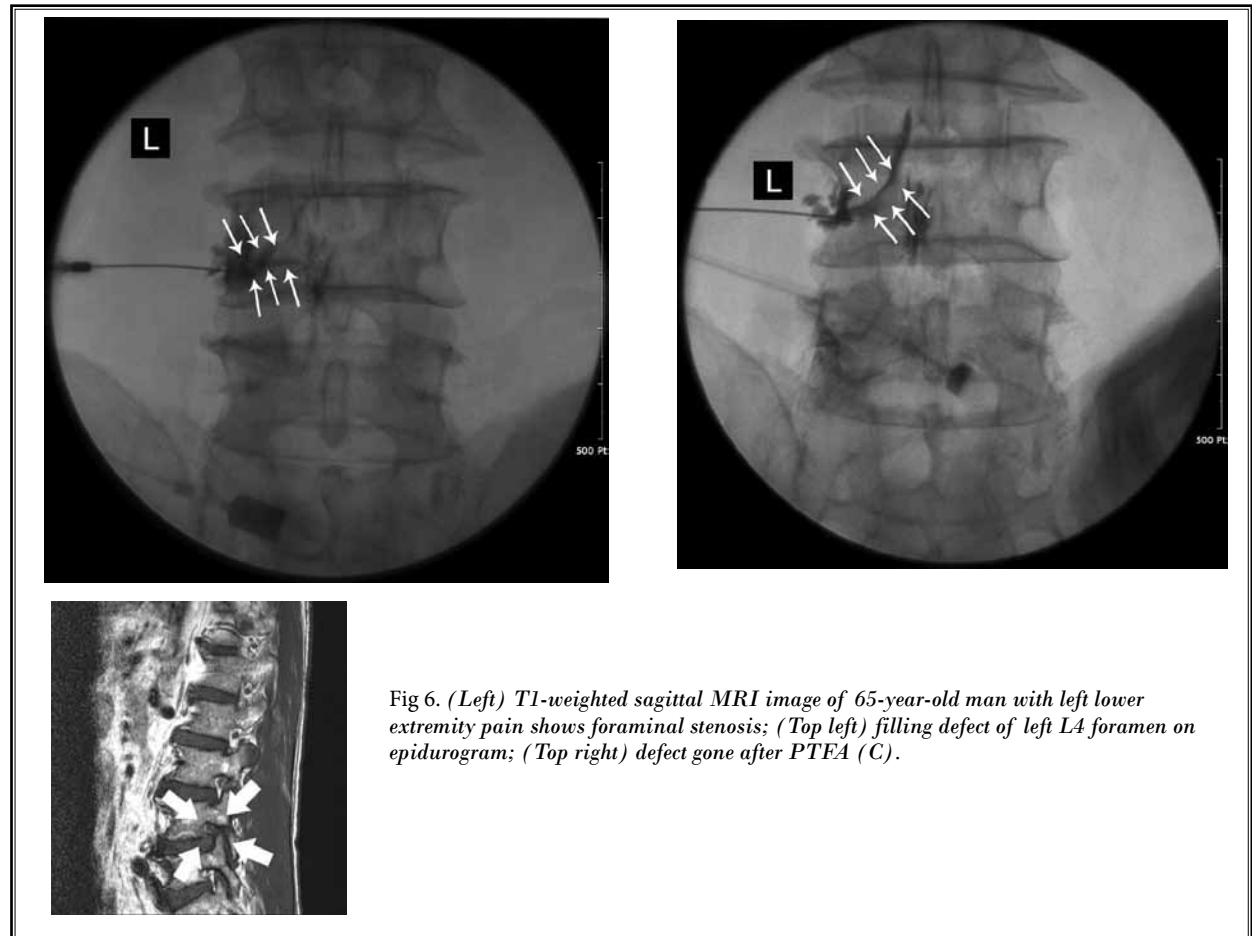


Fig 6. (Left) T1-weighted sagittal MRI image of 65-year-old man with left lower extremity pain shows foraminal stenosis; (Top left) filling defect of left L4 foramen on epidurogram; (Top right) defect gone after PTEA (C).

test. A *P* value  $\leq 0.05$  was considered statistically significant.

## RESULTS

The 35 patients studied (16 men, 19 women) ranged in age from 34-85 years, with a mean age of 65.4 years. Twenty patients had Grade 2 spinal stenosis and 15 patients had Grade 3 spinal stenosis (Table 1). Procedural levels and sites are detailed in Table 2. The L4-5 intervertebral foramen was the most frequently involved.

Improvement (defined as either no pain, little pain, or moderate pain) was observed in 25 patients (74.1%) at 2-week follow-up and 22 patients (62.8%) at 3-month follow-up (Table 3). One patient with severe pain underwent surgery.

At 2 weeks posttreatment, 56% of patients who showed improvement had Grade 3 stenosis, whereas only 10% of those failing to improve had Grade 3. In patients who improved, the percentage with Grade 3 stenosis was significantly higher than the percentage with Grade 2. Interestingly, the increments of pain relief paralleled Grade 3 patient percentages (Table 4). At 3 months, however, no statistically significant correlation between pain relief and grade of LFSS was evident (Table 5).

## DISCUSSION

We have demonstrated a reduction in pain of 62% of LFSS patients who had LFSS 3 months after PTFA,

with no apparent correlation between pain relief and severity of LFSS in this time frame.

In LFSS, the characteristic narrowing of the bony foramen causes mechanical compression of spinal nerve root. This is a dynamic mechanical compression of the nerve root sheath, manifested as neural hyperemia, venous congestion, and edema (3). Reports have indicated

Table 1. The number of patients according to grade of lumbar neuroforaminal stenosis (N=35).

| Grade (N=35) | Frequency | Percentage |
|--------------|-----------|------------|
| 1            | 0         | 0          |
| 2            | 20        | 57.1       |
| 3            | 15        | 42.9       |

Table 2. The procedure site and levels

| N=35                     | Frequency | %     |
|--------------------------|-----------|-------|
| Right                    | 14        | 40.0% |
| Left                     | 21        | 60.0% |
| Involved level (foramen) |           |       |
| L4-5                     | 15        | 42.9  |
| L5-S1                    | 11        | 31.4  |
| L4-5, L5-S1              | 4         | 11.4  |
| L3-4, L4-5               | 3         | 8.6   |
| L5-S1, S1                | 1         | 2.9   |
| L2-3, L3-4, L4-5         | 1         | 2.9   |

Table 3. Response after percutaneous adhesiolysis depend on the 5-point patient satisfaction scale.

| Response      | Pre-treatment | 2 weeks after procedure | 3 months after procedure |
|---------------|---------------|-------------------------|--------------------------|
| Little pain   |               | 11 (31.4%)              | 10 (28.6%)               |
| Moderate pain | 3 (8.6%)      | 14 (40.0%)              | 12 (34.3%)               |
| Bad pain      | 15 (42.8%)    | 3 (8.6%)                | 2 (5.7%)                 |
| Very bad pain | 17(48.6%)     | 7 (20.0%)               | 10 (28.6%)               |
| Surgery       |               |                         | 1 (2.9%)                 |
| Total         | 35 (100%)     | 35 (100%)               | 35 (100%)                |

Table 4. Comparison of grade of LFSS between patients with improvement and no improvement at 2 weeks follow-up

| Response (N=35)    | Grade |    | % of Grade 3 | P      |
|--------------------|-------|----|--------------|--------|
|                    | 2     | 3  |              |        |
| Improvement (n=25) | 11    | 14 | 56.0         | 0.0143 |
| No improved (n=10) | 9     | 1  | 10.0         |        |

Table 5. Comparison of grade of LFSS between patients with improvement and no improvement at 3 months follow-up

| Response (N=34)*   | Grade |    | % of Grade 3 | P      |
|--------------------|-------|----|--------------|--------|
|                    | 2     | 3  |              |        |
| Improvement (n=22) | 11    | 11 | 50.0         | 0.3568 |
| No improve (n=12)  | 8     | 4  | 33.3         |        |

\* Except one patient due to operation.

that percutaneous epidural adhesiolysis is an effective method for treating degenerative central lumbar stenosis (13,17,19). In a study by Park et al (20), 66% of patients achieved enduring pain relief at 6 months following the procedure. Its benefits are attributable to dissolution of adhesions, enabling various drugs (local anesthetics, steroids, and hypertonic sodium chloride solution) to target affected sites, although current knowledge of managing the pain due to spinal stenosis is limited (8).

Either the Kambin triangle or a subpedicular approach may be used for transforaminal epidural access. Park et al (24) reported the effectiveness of the 2 different approaches. There is a smaller chance of spinal nerve pricking using the Kambin triangle approach (25). Unfortunately, the literature offers no consensus on methodology for transforaminal catheter placement.

At the close of this study, pain relief after PTFA and severity of LFSS showed no correlation. Our expectation was that those patients with a higher degree of severity of LFSS would have a smaller reduction of their pain. Instead, we found a higher ratio of Grade 3 LFSS among those patients with subjective improvements at 2-week follow-up. However, the pathophysiology of lumbar stenosis admittedly is complex and although the inflammatory effects of mechanical nerve root compression are considerable, they are not sole determinants

(6). Dynamic foraminal stenosis has been reported as a contributing element (26). Hence, uniplanar spinal canal dimensions may not fully reflect the pathology of spinal stenosis (22). Furthermore, the inconsistencies between symptoms and the degree of spinal canal stenosis may be explained by the use of static images to assess what is actually a dynamic process (5). Finally, other features, including multiple site compression and/or cephalad/caudad extension of compression may affect presenting symptoms (or lack thereof) in spinal stenosis (22).

### LIMITATIONS

There are several limitations to the present study. Aside from the small sampling and brief follow-up interval, the procedural outcomes were measured subjectively as patient pain scores. Alternative endpoints of treatment, such as functional status, medication requirement, or psychological effects, were not addressed.

### CONCLUSION

PTFA is thought to be effective for the treatment of LFSS in patients refractory to conventional remedies, although therapeutic response and grade of LFSS failed to correlate..

### REFERENCES

- Hasegawa T, An HS, Haughton VM, Nowicki BH. Lumbar foraminal stenosis: Critical heights of the intervertebral discs and foramina. A cryomicrotome study in cadavera. *J Bone and Joint Surgery* 1995; 77:32-38.
- Jenis LG, An HS. Spine update. Lumbar foraminal stenosis. *Spine* 2000; 25:389-394.
- Botwin KP, Gruber RD. Lumbar spinal stenosis: Anatomy and pathogenesis. *Phys Med Rehabil Clin N Am* 2003; 14:1-15.
- Simotas AC, Dorey FJ, Hansraj KK, Cammisa F, Jr. Nonoperative treatment for lumbar spinal stenosis. Clinical and outcome results and a 3-year survivorship analysis. *Spine (Phila Pa 1976)* 2000; 25:197-203; discussions 204.
- Sirvanci M, Bhatia M, Ganiyusufoglu KA, Duran C, Tezer M, Ozturk C, Aydogan M, Hamzaoglu A. Degenerative lumbar spinal stenosis: Correlation with Oswestry Disability Index and MR imaging. *Eur Spine J* 2008; 17:679-685.
- Arbit E, Pannullo S. Lumbar stenosis: A clinical review. *Clin Orthop Relat Res* 2001; 384:137-143.
- Spivak JM. Degenerative lumbar spinal stenosis. *J Bone Joint Surg Am* 1998; 80:1053-1066.
- Boswell MV, Trescot AM, Datta S, Schultz DM, Hansen HC, Abdi S, Sehgal N, Shah RV, Singh V, Benyamin RM, Patel VB, Buenaventura RM, Colson JD, Cordner HJ, Epter RS, Jasper JF, Dunbar EE, Atluri SL, Bowman RC, Deer TR, Swicegood JR, Staats PS, Smith HS, Burton AW, Kloth DS, Giordano J, Manchikanti L. Interventional techniques: Evidence-based practice guidelines in the management of chronic spinal pain. *Pain Physician* 2007; 10:7-111.
- Vanderlinden RG. Subarticular entrapment of the dorsal root ganglion as a cause of sciatic pain. *Spine (Phila Pa 1976)* 1984; 9:19-22.
- Koc Z, Ozcakir S, Sivrioglu K, Gurbet A, Kucukoglu S. Effectiveness of physical therapy and epidural steroid injections in lumbar spinal stenosis. *Spine (Phila Pa 1976)* 2009; 34:985-989.
- Delpont EG, Cucuzzella AR, Marley JK, Pruitt CM, Fisher JR. Treatment of lumbar spinal stenosis with epidural steroid injections: A retrospective outcome study. *Arch Phys Med Rehabil* 2004; 85:479-484.
- Harrast MA. Epidural steroid injections for lumbar spinal stenosis. *Curr Rev Musculoskelet Med* 2008; 1:32-38.
- Manchikanti L, Pampati V, Fellows B, Rivera JJ, Damron KS, Beyer C, Cash KA. Effectiveness of percutaneous adhesiolysis with hypertonic saline neurolysis in refractory spinal stenosis. *Pain Physician* 2001; 4:366-373.
- Cooper G, Lutz GE, Boachie-Adjei O, Lin J. Effectiveness of transforaminal epidural steroid injections in patients with degenerative lumbar scoliotic stenosis and radiculopathy. *Pain Physician* 2004; 7:311-317.
- Botwin KP, Gruber RD, Bouchlas CG, Torres-Ramos FM, Sanelli JT, Freeman

- ED, Slaten WK, Rao S. Fluoroscopically guided lumbar transformational epidural steroid injections in degenerative lumbar stenosis: An outcome study. *Am J Phys Med Rehabil* 2002; 81:898-905.
16. Epter RS, Helm S, 2nd, Hayek SM, Benyamin RM, Smith HS, Abdi S. Systematic review of percutaneous adhesiolysis and management of chronic low back pain in post lumbar surgery syndrome. *Pain Physician* 2009; 12:361-378.
  17. Manchikanti L, Saini B, Singh V. Spinal endoscopy and lysis of epidural adhesions in the management of chronic low back pain. *Pain Physician* 2001; 4:240-265.
  18. Trescot AM, Chopra P, Abdi S, Datta S, Schultz DM. Systematic review of effectiveness and complications of adhesiolysis in the management of chronic spinal pain: An update. *Pain Physician* 2007; 10:129-146.
  19. Manchikanti L, Cash KA, McManus CD, Pampati V, Singh V, Benyamin R. The preliminary results of a comparative effectiveness evaluation of adhesiolysis and caudal epidural injections in managing chronic low back pain secondary to spinal stenosis: A randomized, equivalence controlled trial. *Pain Physician* 2009; 12:E341-E54.
  20. Park CH, Lee SH, Jung JY. Dural sac cross-sectional area does not correlate with efficacy of percutaneous adhesiolysis in single level lumbar spinal stenosis. *Pain Physician* 2011; 14:377-382.
  21. Athiviraham A, Yen D, Scott C, Soboleski D. Clinical correlation of radiological spinal stenosis after standardization for vertebral body size. *Clin Radiol* 2007; 62:776-780.
  22. Campbell MJ, Carreon LY, Glassman SD, McGinnis MD, Elmlinger BS. Correlation of spinal canal dimensions to efficacy of epidural steroid injection in spinal stenosis. *J Spinal Disord Tech* 2007; 20:168-171.
  23. Lee S, Lee JW, Yeom JS, Kim KJ, Kim HJ, Chung SK, Kang HS. A practical MRI grading system for lumbar foraminal stenosis. *AJR* 2010; 194:1095-1098.
  24. Park CH, Lee SH, Park HS. Lumbar retrodiscal versus post-ganglionic transforaminal epidural steroid injection for the treatment of lumbar intervertebral disc herniations. *Pain Physician* 2011; 14:353-360.
  25. Park JW, Nam HS, Cho SK, Jung HJ, Lee BJ, Park Y. Kambin's triangle approach of lumbar transforaminal epidural injection with spinal stenosis. *Annals Rehab Med* 2011; 35:833-843.
  26. Inufusa A, An HS, Lim TH, Hasegawa T, Haughton VM, Nowicki BH. Anatomic changes of the spinal canal and intervertebral foramen associated with flexion-extension movement. *Spine (Phila Pa 1976)* 1996; 21:2412-2420.

