

Case Report



Spinal Cord Stimulation for Radicular Pain Following Retained Bullet in the Spinal Canal

John C. Keel, MD^{1,2}, Mary E. Lau, BS¹, and Padma Gulur, MD^{1,2}

From: ¹Massachusetts General Hospital; Boston, MA; and ²Harvard Medical School, Boston, MA.

Dr. Keel is a physiatrist at Harvard Medical School and the Medical Director of the Spine Center at Beth Israel Deaconess, in Boston, MA. Ms. Lau is with Massachusetts General Hospital, Boston, MA. Dr. Gulur is with the Dept of Anesthesia, Critical Care and Pain Medicine, Massachusetts General Hospital, Boston, MA; and Assistant Professor at Harvard Medical School, Boston, MA.

Address Correspondence:
Padma Gulur, MD
Dept of Anesthesia, Critical Care and Pain Medicine
Massachusetts General Hospital
15 Parkman Street, WACC330
Boston, MA 02114
E-mail: pgulur@yahoo.com

Disclaimer: There was no external funding in the preparation of this manuscript.

Conflict of interest: None.

Manuscript received: 11-07-12
Accepted for publication: 12-03-12

Free full manuscript:
www.painphysicianjournal.com

We are reporting on the implantation of a spinal cord stimulator to treat intractable radicular pain following a retained bullet fragment in the spinal canal. Such retained fragments are associated with risks including pain, neurological deficit, infection, toxic effects, and migration. Our patient was a young man with radicular pain and history of a gunshot entering the abdomen. Computed tomography of the spine had revealed a nearly complete bullet in the right paracentral canal at L4, partially extending into the lateral recess. He presented 17 months after his injury with gradually worsening pain and parasthesias radiating from the back to the whole right leg and foot. There was no weakness. As the patient had failed conservative therapy, procedural options were considered. In this case, the potential benefits of epidural steroid injection by any approach might not have outweighed risks of infection, related to foreign body and local steroid, or possible migration due to mechanical forces during injection. As he may well need repeated epidural steroid injections to manage his pain, this increases his risk for infection. A percutaneous trial spinal cord stimulation lead was placed, with epidural entry well away from the bullet. After good results, a permanent system was implanted. There was no evidence of infection or migration, and excellent pain relief was achieved. Bullets and other foreign bodies retained in the spinal canal can cause progressive neurologic symptoms through reactive tissue formation and compression. Spinal cord stimulation can relieve radicular pain while avoiding risks associated with altering the location of the offending foreign body.

Key words: Spinal cord stimulation, radicular pain, retained bullet, gunshot wound, spinal canal, spinal injury, lumbar spine

Pain Physician 2013; 16:E103-E106

Gunshot wounds in the vicinity of the spinal canal can result in chronic pain from several mechanisms such as spinal/nerve root transection, shockwave injury, syringomyelia, arachnoiditis, compression of nerve roots by a retained fragment, or compression by reactive tissue formation around a retained fragment (1). Retained bullet fragments that result from gunshot wounds often require no intervention, including those in the spinal canal, even if they cause pain.

Specifically, surgical removal of bullet fragments from the spinal canal may not result in alleviation of pain (2). Attempts to surgically remove the foreign body may result in infection, additional injury, or migration. Radicular pain caused by a retained bullet fragment may be challenging to treat, as the offending foreign body is likely to persist unchanged in spite of physical or medical treatments, and certain procedures for pain may be relatively contraindicated. We are reporting on the implantation of a spinal cord stimulator

to treat intractable radicular pain following a retained near-complete bullet in the lumbar spinal canal.

CASE REPORT

A 22-year-old man was referred to the pain clinic to be evaluated for interventional procedures to help with radicular pain in his right leg. The patient has a history of gunshot wounds to the abdomen – 3 in the anterior left flank and one in the posterior left flank – and currently has an inextricable bullet fragment lodged in the spinal canal at approximately the L4 level. Since his injury 17 months ago, the patient has experienced gradually worsening pain and paresthesias along the inner aspect of the upper part of the right leg and on the outer aspect of the plantar surface of the right foot, corresponding to L4-5 and S1 dermatomes.

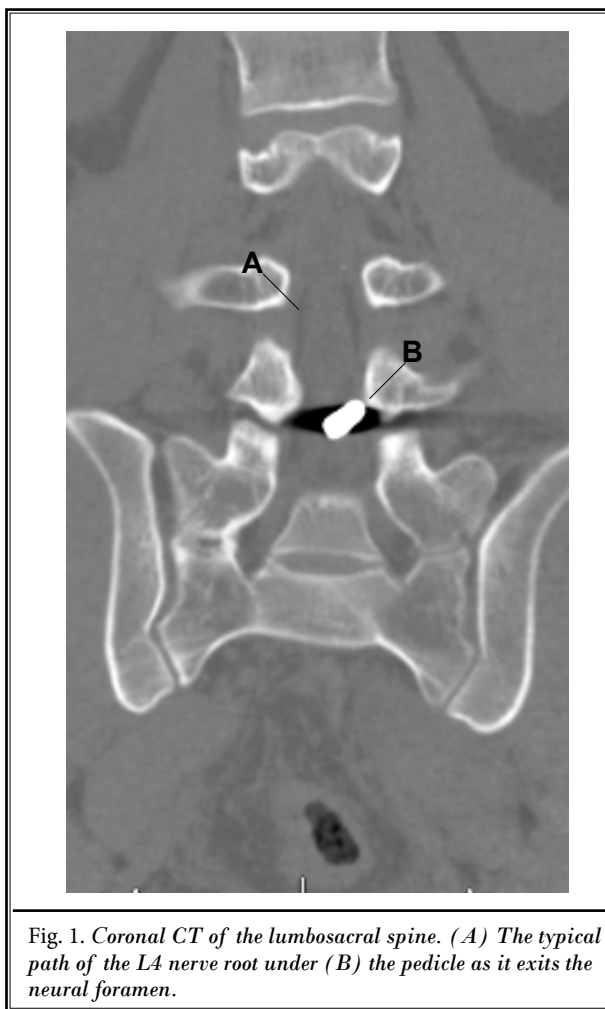


Fig. 1. Coronal CT of the lumbosacral spine. (A) The typical path of the L4 nerve root under (B) the pedicle as it exits the neural foramen.

Attempts at conservative treatment such as physical therapy were unsuccessful and medication trials with gabapentin were discontinued due to side effects. At this point, interventional options were considered. Upon discussion with his radiologist, it was agreed that a spinal cord stimulator would be a better option than an epidural steroid injection because the retained foreign body is in the area of suspected pathology. We also spoke with an infectious disease expert who opined that one epidural steroid injection may not cure his pain and repetitive injections may be necessary. However, multiple injections may increase his risk of infection given the retained foreign body and repeated steroid exposure.

The patient agreed with the recommendation and a spinal cord stimulator trial was scheduled. After obtaining informed consent, a 25-gauge, 1.5 inch needle of 1% lidocaine was injected subcutaneously over the entry site and the T12-L1 interlaminar space was identified under fluoroscopic guidance (Fig. 1). Entering the skin at the surface mark corresponding with the left pedicle of the level below, a 15-gauge epidural needle was inserted and advanced cephalad and medial toward the epidural space, by means of the loss-of-resistance technique. A single Advanced Neuromodulation System (Plano, TX) lead was introduced into the epidural space and advanced to the T9 vertebral body. The patient reported adequate coverage of the painful area during the test stimulation. The needle was then withdrawn under fluoroscopic guidance so that the stimulator lead remained in the same position. The lead was secured to the skin and the patient continued to report adequate stimulation coverage upon discharge. Upon returning for removal 2 days later, the patient reported > 90% pain relief.

Following positive results from the trial, the patient decided to proceed with permanent implantation of the spinal cord stimulator. The stimulator was implanted in the operating room 2 weeks post-trial. After obtaining written informed consent, the T12-L1 interlaminar space was identified using fluoroscopy. The needle was inserted to the left pedicle of the level below and the area was infiltrated with 10 mL of 1% lidocaine with epinephrine. As with the trial, a needle was inserted and advanced cephalad and medial toward the epidural space by means of the loss-of-resistance technique. An Octrode™ (Advanced Neuromodulation System, Inc., Plano, Texas) spinal cord stimulator lead was placed through the needle under live fluoroscopy

and advanced to the level of the T9 vertebral body in the midline (Fig. 2). Lead stimulation testing was performed and adequate coverage of the pain areas was obtained.

A longitudinal incision was made at the needle entry site and blunt dissection was made down to the fascia. The system was anchored to the fascia with an anchoring system and a series of sutures. The pulse generator site was then implanted in an area of the right buttock. A tunneling device was used and a tunnel was created under the skin from the lumbar needle insertion site to the pocket in which the pulse generator was implanted (Fig. 3).

The patient continued to report adequate pain control in follow-up visits up to 2 months post-implant.

LITERATURE REVIEW

A search on PubMed with the keywords retained bullet, spinal canal, gunshot wound, and spinal cord stimulation produced limited results. The majority of the articles stated that bullets retained in the spinal canal are considered stable and generally do not require any intervention (2,3). However, new onset or progressive deterioration of neurological conditions may warrant surgical removal (3). Short of removing the bullet itself, no articles were found using alternative treatment options such as steroid injections or spinal cord stimulators.

DISCUSSION

Retained bullet fragments in the spinal canal can be associated with several chronic complications. Pain, neurological deficit, infection, toxic effects, and migration have been described. Neuropathic pain can result from spinal cord or nerve root transection or shockwave injury, syringomyelia, arachnoiditis, direct compression of nerve roots by the retained fragment, or compression by reactive tissue formation around the foreign body (1). A retained fragment can remain in the spinal canal without intervention, but cauda equina or progressive motor deficit may be indications for surgery.

Surgical removal of bullet fragments carries great risks, and may not lead to improved pain or recovery of sensory function (4). One of the risks that must be considered is the possibility of migration of the bullet which could result in exacerbation of symptoms or the neurologic condition. Migration of bullet fragments in the spinal canal is considered a rare phenomenon, but several cases have been reported. Caudal migration of bullet fragments can cause compression and cauda equina syndrome. In our patient's case, there was no historical evidence of migration or history of markedly worsening symptoms.

Short of removing the retained foreign body, treatment options in the event that conservative options are unsuccessful include steroid injections or

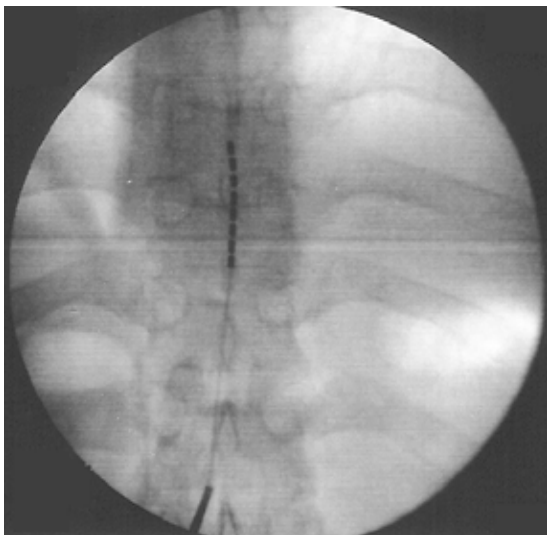


Fig. 2. (A) Octrode lead in the epidural space at T9, and (B) interlaminar position of the introducer needle.

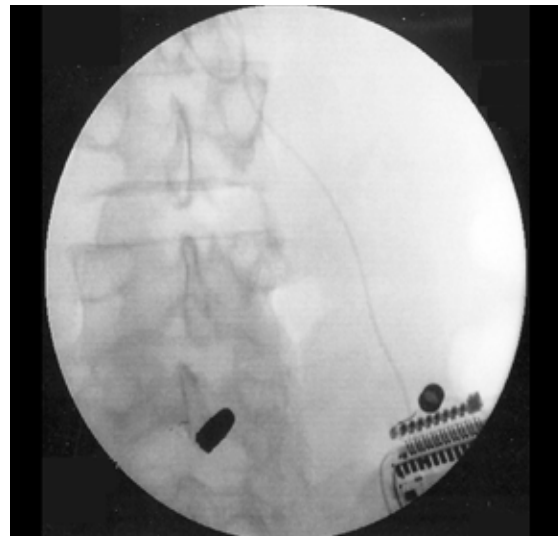


Fig. 3. (A) Implantable pulse generator and (B) lead, heading to epidural entry site well away from the retained bullet.

spinal cord stimulator implants. Since in all likelihood, the patient would need multiple epidural steroid injections over the years to control his pain, our infectious disease specialist concluded epidural steroid injections would lead to an increased infection risk. The spinal cord stimulator was the preferred method of treatment because the device could be introduced at a level away from the retained foreign body and would not affect the ability the patient's body to fight infection as would a steroid.

CONCLUSION

This is the first reported case of successful spinal cord stimulation treatment in a patient with a near-complete bullet retained in the spinal canal. Bullets and other foreign bodies retained in the spinal canal

can cause progressive neurologic symptoms through reactive tissue formation and compression. The progressive pain reported by our patient may have resulted from this mechanism. It is significant that his symptoms and exam findings corresponded to a radicular pain pattern with intact nerves, rather than central or deafferentation pain, as spinal cord stimulation is more likely to be beneficial for radicular pain. This case suggests that spinal cord stimulation may be a safe and effective treatment option for radicular pain following a retained bullet in the spinal canal when bullet extraction and epidural steroid injections cannot be done safely. Spinal cord stimulation can relieve radicular pain while avoiding risks associated with altering the location of the offending foreign body or increasing risk of infection.

REFERENCES

1. Kuijlen JM, Herpers MJ, Beuls EA. Neurogenic claudication, a delayed complication of a retained bullet. *Spine* 1997; 22:910-914.
2. Waters RL, Sie IH. Spinal cord injuries from gunshot wounds to the spine. *Clinical Orthopaedics & Related Research* 2003; 408:120-125.
3. Yoshida GM, Garland D, Waters RL. Gunshot wounds to the spine. *Orthop Clin North Am* 1995; 26:109-116.
4. Waters RL, Adkins RH. The effects of removal of bullet fragments retained in the spinal canal: A collaborative study by the National Spinal Cord Injury Model Systems. *Spine (Phila Pa)* 1991; 16:934-939.