

Systematic Review

The Long-Term Incidence of Subsequent Vertebral Body Fracture After Vertebral Augmentation Therapy: A Systematic Review and Meta-Analysis

Jun Zou MD, PhD; Xin Mei MD; Xuesong Zhu MD, PhD; Qin Shi MD, PhD;
and Huilin Yang MD, PhD

From: Department of Orthopaedic Surgery, The First Affiliated Hospital of Soochow University, Suzhou, Jiangsu 215006, China

Address correspondence: Huilin Yang, MD, PhD
Chairman & Professor
Department of Orthopaedic Surgery
The First Affiliated Hospital of Soochow University
188 Shizi St.
Suzhou, Jiangsu 215006, China
E-mail: hlyang@suda.edu.cn

Disclaimer: Supported by National Natural Science Foundation of China (11072165)

Conflict of interest: None.

Manuscript received: 02/23/2012
Revised manuscript received: 04/05/2012
Accepted for publication: 04/10/2012

Free full manuscript: www.painphysicianjournal.com

Background: Vertebroplasty and kyphoplasty have recently been used to treat painful osteoporotic compression fractures. Early clinical results have been encouraging, but very little is known about the consequences of augmentation with cement for adjacent, unaugmented levels.

Objective: This study performed a systemic review of the studies concerning whether the incidence of subsequent vertebral body fracture after vertebral augmentation therapy would be increased long-term.

Study Design: A meta-analysis of randomized controlled trials was performed comparing the long-term incidence of subsequent vertebral body fracture between vertebral augmentation surgeries like vertebroplasty and kyphoplasty and conventional nonsurgical management.

Setting: The MEDLINE, EMBASE, ISI Web of Science and Cochrane Library databases and abstracts published in annual proceedings were systematically searched for evidence.

Methods: Relevant reports were reviewed by 2 reviewers independently and the references from these reports were searched for additional trials, using guidelines set by QUOROM statement criteria.

Results: Pooled results from 2 randomized controlled trials showed no significant increase of the secondary fracture rate after vertebral augmentation therapy compared with that of conventional treatment ($P = 0.07$). Few large-sample randomized controlled trials were specifically performed to investigate new fractures as an outcome of vertebroplasty or kyphoplasty.

Limitations: There were few data sources from which to extract abstracted data or published studies. There were only 2 randomized controlled trials that met criteria.

Conclusions: Although vertebral augmentation therapies, such as vertebroplasty and kyphoplasty, have been widely used in clinics to treat patients' back pain caused by vertebral compression fractures due to osteoporosis, no evidence shows that they can increase the fracture of adjacent vertebral bodies.

Key words: Vertebroplasty, kyphoplasty, subsequent vertebral fracture, systemic review, meta analysis.

Pain Physician 2012; 15:E515-E522

Vertebroplasty is an effective surgery, proven by multiple studies, for relieving or decreasing pain and has become an emerging choice for clinical vertebral body compression fractures (1-8). Vertebroplasty has recently been used to treat painful

osteoporotic compression fractures. Kyphoplasty includes an additional step. Prior to injecting the cement-like material, a special balloon is inserted and gently inflated inside the fractured vertebra. The goal of this step is to restore height to the bone, thus

reducing deformity (9-18). Most patients return to their normal daily activities after either procedure. Early clinical results have been encouraging, but very little is known about the consequences of augmentation with cement for adjacent, unaugmented levels.

However, vertebroplasty and kyphoplasty are associated with some risks. Some of these risks are procedure-related risks, whereas some are postprocedural. One of the most important postprocedural risks is related to vertebral body augmentation. An excessive injection of cement may cause some biomechanical changes, including endplate necrosis; leakage into the disc space, spinal canal, and vascular area; increased stiffness of the vertebral body; and increased stress on the adjacent level vertebrae, which may cause a new fracture or re-fracture. Therefore, this study performed a systemic review of the studies concerning whether vertebral augmentation would increase re-fracture occurrence due to a change in the biomechanical environment.

METHODS

The data

A total of 836 abstracts were identified. Of these, 64 studies met the inclusion criteria. Patients were required to have at least a 15% loss in vertebral body height (anterior, median, or posterior) as assessed by X-ray imaging. The pain related to the fractured vertebrae is the more prevalent{more prevalent than what?}. They must have had more than 3 months life expectancy. Their blood platelets rate must have been more than or equal to 50,000/mm³ within the week before vertebroplasty (after a correct blood transfusion). The patients must have signed a consent form. Published randomized controlled trials were eligible for this meta-analysis. Published abstracts were included, but unpublished studies were also sought. Studies published in any language were also eligible if they fulfilled the inclusion criteria. No authors were contacted for clarification or verification of patient data.

Search strategy for identification of studies

Medline and manual searches were done (completed independently and in duplicate) to identify all published manuscripts, abstracts, and randomized controlled trials (RCTs) comparing the incidence of new fractures between vertebral augmented therapies and conventional nonsurgical management.

The Medline search was done on PubMed covering from 1966 through 2010 with no language re-

strictions. Search terms included: "kyphoplasty" or "vertebroplasty" or "cementoplasty" or "vertebral augmentation" and "refract*" or "secondary fract*" or "new" or "worsening" and "incident" or "adjacent" and "convention*" or "optimal pain medication". The second search was done through the Cochrane Library to identify randomized trials published from January 1998 through July 2010, using MeSH headings ("kyphoplasty" or "vertebroplasty" and "spinal fracture", ex-lode Clinical Trials, clinical trial {publication type}) and text words ("kyphoplasty" or "vertebroplasty" or "cementoplasty" and "refraction" or "refractory" or "refracture" or "new" or "worsening" and "incident" or "adjacent" and "convention*") without language restrictions. All the searched abstracts were screened for relevance. Manual searches were done by reviewing articles and abstracts cited in the reference lists of identified RCTs, by reviewing the first author's article, abstract file, from reference lists of retrieved papers, textbooks and review articles. Also, abstracts published in the Proceedings of the OSTEOPOROSIS INTERNATIONAL (through 2000) were systematically searched for evidence relevant to this Meta analysis. The selection of studies for inclusion was carried out independently by two of the authors (X Mei & X Zhu). Each study was evaluated for quality using the scale of 0 to 5 proposed by Jadad (19). If reviewers disagreed on the quality scores, discrepancies were identified and a consensus was reached. Trial data abstraction was also done independently and in duplicate, but abstractors were not blinded to the trials' authors or institution. Any discrepancies in data abstraction were examined further and resolved by consensus.

Analysis of the review

The data analyses were made with RevMan Version 5.0.2 provided by The Cochrane Collaboration. All analyses were carried out on an intention-to-treat basis; that is, all patients randomly assigned to a treatment group were included in the analyses according to the assigned treatment, irrespective of whether they received the treatment or were excluded from analysis by the investigators. For categorical variables, weighted risk ratios and their 95% confidence interval (CI) were calculated using RevMan 5.0.2 software according to the Peto method. Results were tested for heterogeneity at a significance level of $P < 0.05$ according to the methods outlined. A fixed effects model was used if there was no evidence of heterogeneity between studies; if there was evidence of heterogeneity, a random

effects model was used for the meta-analysis. The odds ratio (OR) and 95% CI were calculated for each trial and presented in a Forrest plot.

Publication bias is a common concern in meta-analyses. It is related to the tendency of journals to favor publishing large, positive studies. We chose a commonly used method for detecting publication bias, which is a graphical plot of estimates of the ORs from the individual studies versus the inverse of their variances, which is commonly referred to as a "funnel plot." An asymmetry in the funnel would be expected if there was publication bias, with smaller studies tending to show larger ORs, because small studies with no significant statistical results would be less likely to be reported.

RESULTS

The 2 trial assessors agreed on the selection of 4 clinical trials relevant to our study (20-23). The QUOROM flow diagram illustrates the main reasons for trial exclusion (Fig. 1). One short-term RCT was excluded, and another one was excluded due to its not being an experimental study. Only 2 trials, a prospective observational study and a multi-center RCT, were chosen for further quality analysis and review.

Description of studies

The designs of both included studies are summarized in Tables 1 and 2. Both trials enrolled patients with vertebral compression fractures (VCFs). Patients

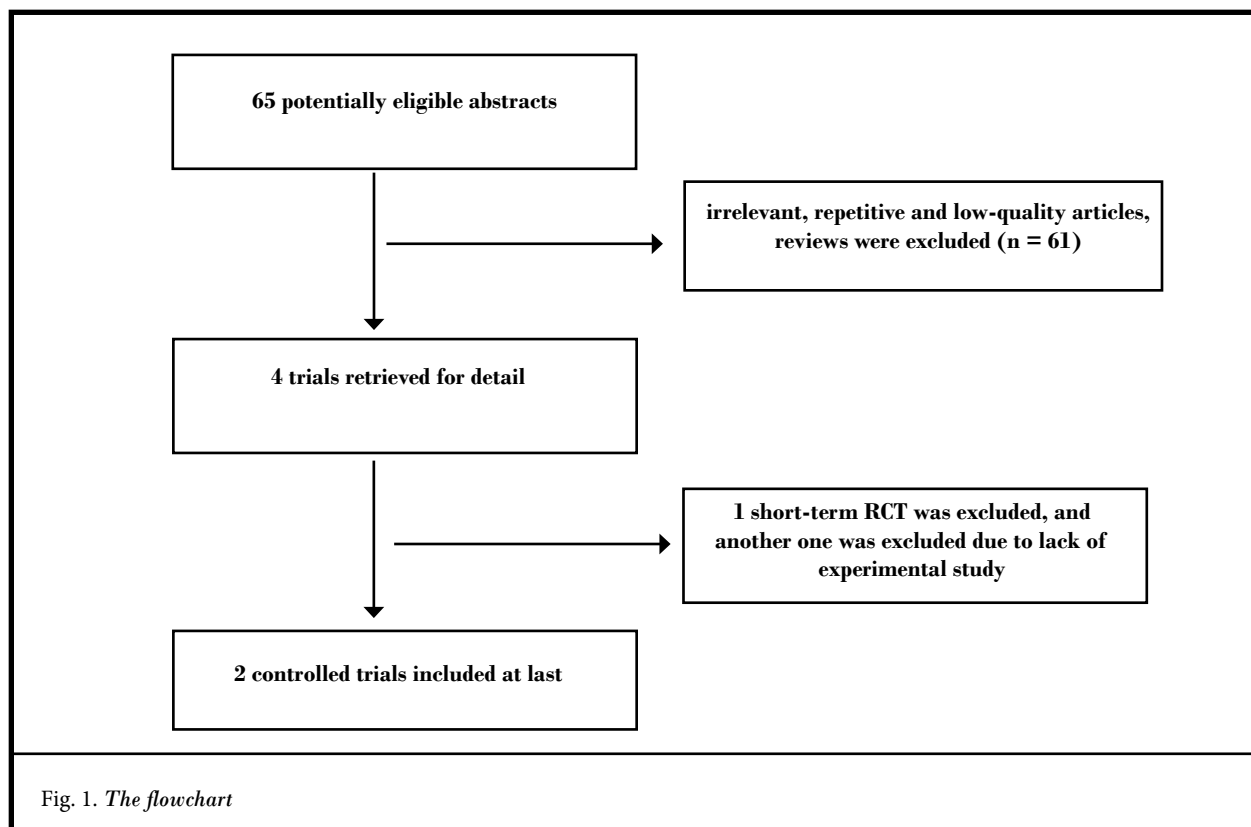


Table 1. Summary of patient characteristics from the found trials

Study	Case no.	M/F ratio	Mean age	Follow-up
Wardlaw 2009[23]	300	68/232	73.2	12 months
Thillainadesan 2010[20]	34	10/24	78	29 months

Table 2. Quality analysis on included trials

Study	Randomization	Concellment	Loss	Quality
Wardlaw 2009[23]	Computer randomization	unclear	no	A
Thillainadesan 2010[20]	unclear	unclear	no	B

could have painful, acute or subacute, osteoporotic/osteolytic metastatic/multiple myeloma VCFs. In addition, patients were required to have at least a 15% loss of vertebral body height (anterior, median, or posterior) as assessed by X-ray imaging. In the Thillainadesan (20) study, vertebroplasty was chosen as the experimental procedure, while in the Wardlaw (23) trial, balloon kyphoplasty was performed. New or worsening VCFs were treated as the outcomes in both included studies.

Methodological Quality of Included Studies

Each published randomized trial reported was assessed for quality using the validated scale developed by Jadad et al (19). All the studies included were randomized. All studies reported the randomization procedure. The quality scores of included studies are summarized in the table of characteristics in Table 2.

Long-term Refracture Ratio

Both studies reported secondary vertebral compression fractures as one of the outcomes. Altogether, the analysis included 2 trials with 334 patients. The overall long-term refracture ratio was 12.57% for the experimental group (42/334) compared to 7.78% in the conventional group (26/334). The test for heterogeneity was not statistically significant with a P value of 0.32, which indicates that the pooling of the data was valid. The overall odds ratio confidence interval ranged from 0.97 to 2.89 with no significant difference (P = 0.07).

There was no significant difference in the long-term fracture rate in either study (Fig. 2) (10,13).

Evaluation of publication bias

The funnel plot of the log ORs versus the inverse of their variances of the individual studies is displayed in Fig. 3. The plot formed a very distinct funnel shape with the log ORs evenly distributed around the meta-analysis OR regardless of the study variance. Therefore, there was no indication of an asymmetry in the study findings by the variance or size of the studies and, thus, little evidence for publication bias.

DISCUSSION

Vertebral augmentation procedures have become enormously popular in the United States and abroad for treating painful osteoporotic VCFs. This minimally invasive procedure avoids or mitigates the direct and indirect adverse effects of pharmacologic and conventional pain treatment modalities while providing pain relief and improved function in an expedited fashion. Vertebral augmentation procedures include percutaneous vertebroplasty, the injection of bone cement directly into a fractured vertebral body, and balloon kyphoplasty, in which an inflatable bone tamp is employed to create a cavity in the bone prior to cement injection. These procedures are performed on fractures of thoracolumbar vertebrae and the sacral vertebrae (sacroplasty) (24-28). Until recently, the efficacy of vertebral augmentation

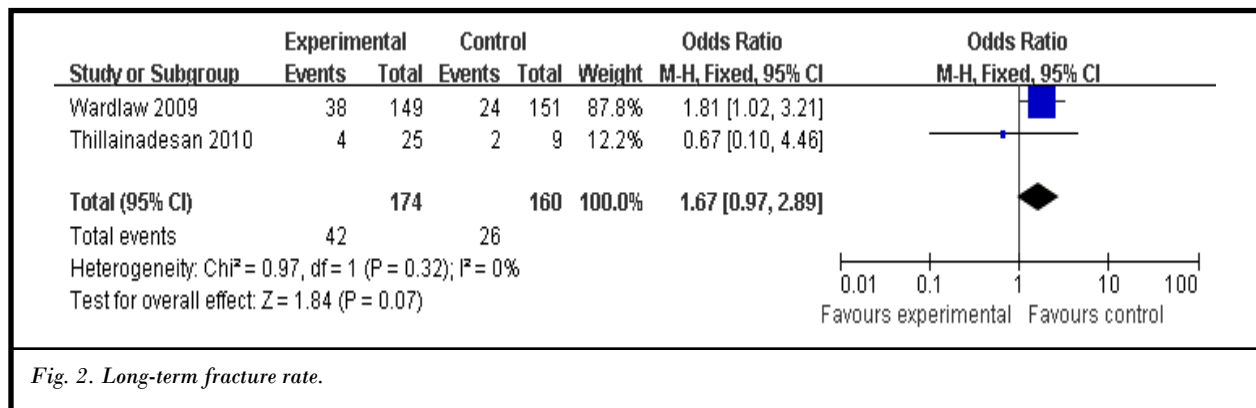


Fig. 2. Long-term fracture rate.

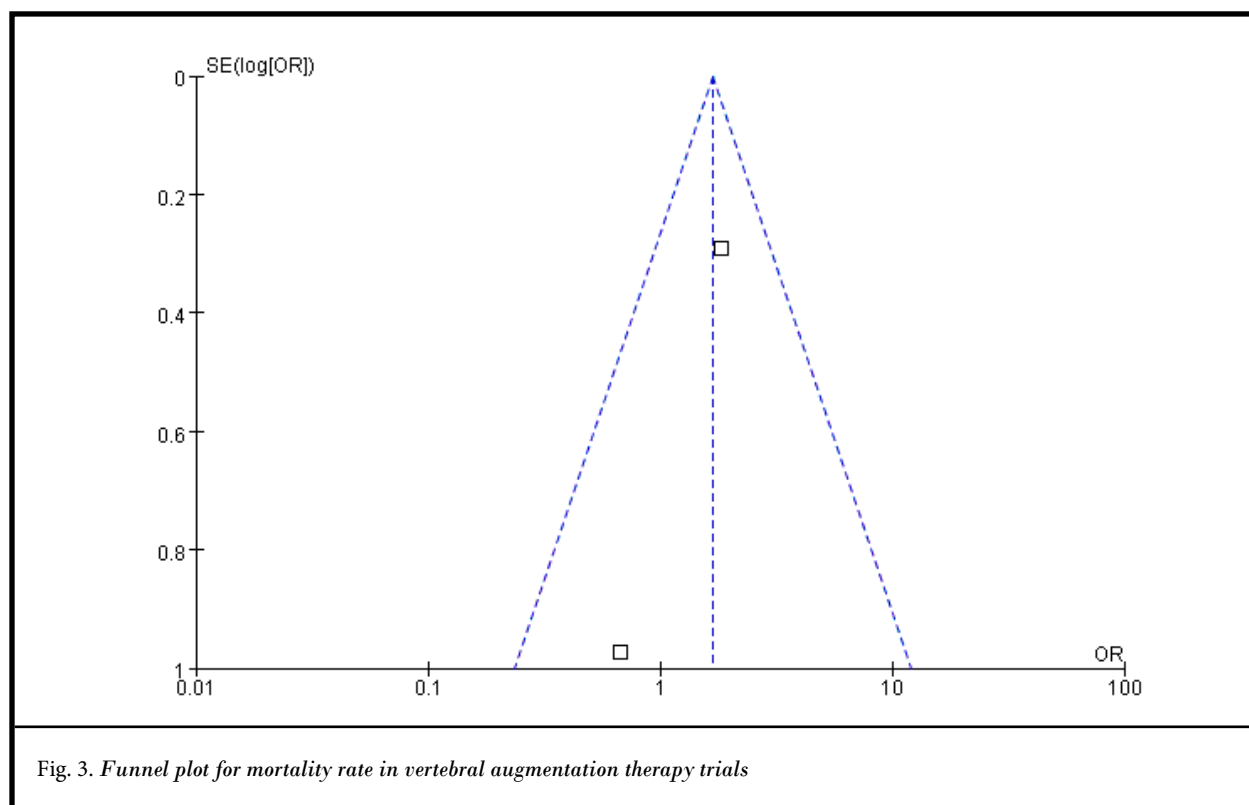


Fig. 3. Funnel plot for mortality rate in vertebral augmentation therapy trials

procedures had been supported in numerous case reports, case series, and nonrandomized trials. Practitioners valued the procedures, and patients seemed to prefer the active intervention as opposed to medical therapy. However, the level of evidence of these early reports was fair to poor because of the lack of randomized controlled trials. Recent prospective, randomized, and controlled trials have done little to confirm or deny the efficacy of the techniques. In general, they have found percutaneous vertebroplasty or balloon kyphoplasty either beneficial, or not any different when compared to conservative therapy with regards to primary (pain and disability) and secondary outcome indexes (quality of life, analgesic usage, secondary vertebral re-fracture, etc.) (29-33).

The biomechanical effects of vertebral fracture and subsequent vertebral augmentation therapy are topics for continued investigation. However, altered biomechanical stresses after treatment may affect the risk of adjacent fracture in an osteoporotic patient. The patients successfully treated with augmentation often return with new pain caused by a new vertebral body fracture. The new fractures often are adjacent to the vertebral bodies that were initially treated (34-35). Wil-

son et al (36) studied the effect of cement augmentation of wedge-fractured vertebral bodies on spine segment compliance in 16 cadaver specimens. The results showed that augmentation could reduce spine segment compliance significantly. It significantly reduced the neutral compliance and the full-load compliance in flexion/extension. Augmentation also significantly reduced the neutral compliance and the full-load compliance in lateral bending (36).

The biomaterials like polymethyl methacrylate cement used in these procedures may have an important effect on load transfer and disc mechanics, and therefore, the variables of cement volume, formulation, and distribution should also be evaluated (37-38). Liebschner et al (39) developed an experimentally calibrated, anatomically accurate finite-element model of an elderly L1 vertebral body for investigating volume and distribution of bone cement on stiffness recovery. Their results demonstrated that the greater filling can result in a substantial increase in stiffness beyond the intact level (39). It is the cement that is thought to transfer a greater proportion of the load through the central augmented trabeculae structure than would occur naturally, causing an altered load distribution within the spinal

segment. The increased mechanical pressure, especially pertinent for patients who increase their daily physical activities as their back pain decreases after augmentation, also placed additional stress on the vertebral bodies (40). Therefore, more and more clinicians believe the stiffening of the treated vertebra might put adjacent vertebrae at higher risk of subsequent fracture or degenerative change.

However, little clinical information is currently available on this topic. In this study, in order to investigate the outcome of a new fracture secondary to vertebral augmentation, we studied the long-term rather than short-term outcome, a period extended to 12 months. It is reported that the median time before re-fracture for patients treated with percutaneous vertebroplasty was 4.5 months (95% CI 1.4-9.3 months); for patients treated with ROPE{this needs to be identified as an exercise program} only, 60.4 months (95% CI, 27.6 months-upper limit undefined); and for patients treated with PVP-ROPE, 20.4 months (95% CI, 2.8 months-upper limit undefined) ($P < .001$) (41). The greater the anterior vertebral height obtained from vertebroplasty, the greater the risk of re-fracture occurring ($P < 0.01$). Gas-containing vertebrae were also prone to re-fracture after the procedure ($P = 0.01$). Anti-osteoporotic treatment was of borderline significance between re-fractured and non-refractured vertebrae ($P = 0.07$). Only restoration of anterior vertebral height was positively associated with re-fracture during the follow-ups ($P < 0.01$) (42).

These results indicate that there was no significant difference in the re-fracture ratio after vertebroplasty and kyphoplasty when comparing them to conventional nonsurgical management. The adjacent vertebral body fractures might be related to the natural progression of osteoporosis (40,43). Villarraga et al (44) presented a validated 2 functional spinal unit T12–L2 finite element model with a simulated kyphoplasty augmentation in L1 to predict stresses and strains within the bone cement and bone of the treated and adjacent untreated vertebral bodies. Their findings suggested that changes in stresses and strains in levels adjacent to a kyphoplas-

ty-treated level are minimal. Furthermore, the stress and strain levels found in the treated levels are less than injury tolerance limits of cancellous and cortical bone (44). A retrospective clinical study of patients with at least one vertebral compression fracture conducted by Harrop et al (45), however, suggested that of 17 patients may be adjacent and 7 patients may be remote to the index fracture. The results showed that adjacent untreated vertebral bodies did not undergo immediate biomechanical changes arising from augmentation (45). Therefore, the presence of bone cement following the augmentation, we think, will not substantially alter the overall load transfer and stresses within that vertebral body and within the adjacent vertebral bodies; subsequent adjacent level fractures may be related to the underlying etiology (weakening of the bone) rather than the surgical intervention.

Limitations

One limitation in our study is there were few data sources from which to extract abstracted data or published studies. Therefore, we should interpret the results with care, especially for a positive result. Although the risk of publication bias exists in any meta-analysis, whether based on individual patient data or not, we feel that this was not an important aspect of our study, as many positive and negative trials were included in the analysis. The presence and rate of re-fracture could not be determined by follow-up phone interview. The authors of those studies fail to address any investigation as to subsequent spine pain in the percutaneous vertebroplasty group. Only patients who had fractures of an uncertain age were required to have imaging with MRI or bone scan.

CONCLUSION

The results of this meta-analysis indicate that there was no significant difference in the re-fracture ratio after vertebroplasty and kyphoplasty{compared to what? You indicate what earlier, do it here too}. The mechanism for the new fractures is most likely secondary to the underlying degree of osteoporosis.

REFERENCES

1. Hao J, Hu Z. Percutaneous cement vertebroplasty in the treatment of symptomatic vertebral hemangiomas. *Pain Physician* 2012; 15:43-49.
2. Rad AE, Kallmes DF. Correlation between preoperative pain duration and percutaneous vertebroplasty outcome. *AJNR Am J Neuroradiol* 2011; 32: 1842-1845.
3. Lai PL, Tai CL, Chen LH, Nien NY. Cement leakage causes potential thermal injury in vertebroplasty. *BMC Musculoskelet Disord* 2011; 12:116.
4. Miller FG, Kallmes DF, Buchbinder R. Vertebroplasty and the placebo response. *Radiology* 2011; 259:621-625.
5. Sonmez E, Yilmaz C, Caner H. Development of lumbar disc herniation following percutaneous vertebroplasty. *Spine* 2010; 35:E93-95.
6. Erkan S, Wu C, Mehbod AA, Cho W, Transfeldt EE. Biomechanical comparison of transpedicular versus extrapedicular vertebroplasty using polymethylmethacrylate. *J Spinal Disord Tech* 2010; 23:180-185.
7. Gray DT, Hollingworth W, Onwudiwe N, Jarvik JG. Costs and state-specific rates of thoracic and lumbar vertebroplasty, 2001-2005. *Spine* 2008; 33: 1905-1912.
8. Marden FA, Putman CM. Cement-embolic stroke associated with vertebroplasty. *AJNR Am J Neuroradiol* 2008; 29:1986-1988.
9. Lim BG, Lee JY, Lee MK, Lee DK, Kim JS, Choi SS. Kyphoplasty for the treatment of vertebral compression fractures in a cancer patient with neurological deficits and anterior vertebral wall destruction. *Pain Physician* 2011; 14:539-544.
10. Fritzell P, Ohlin A, Borgström F. Cost-effectiveness of balloon kyphoplasty versus standard medical treatment in patients with osteoporotic vertebral compression fracture: A Swedish multicenter randomized controlled trial with 2-year follow-up. *Spine* 2011; 36:2243-2251.
11. Goz V, Koehler SM, Egorova NN, Moskowitz AJ, Guillerme SA, Hecht AC, Qureshi SA. Kyphoplasty and vertebroplasty: Trends in use in ambulatory and inpatient settings. *Spine J* 2011; 11:737-744.
12. Tatsumi RL, Ching AC, Byrd GD, Hiratzka JR, Threlkeld JE, Hart RA. Predictors and prevalence of patients undergoing additional kyphoplasty procedures after an initial kyphoplasty procedure. *Spine J* 2010; 10:979-986.
13. Yan D, Duan L, Li J, Soo C, Zhu H, Zhang Z. Comparative study of percutaneous vertebroplasty and kyphoplasty in the treatment of osteoporotic vertebral compression fractures. *Arch Orthop Trauma Surg* 2011; 131:645-650.
14. Hiwatashi A, Westesson PL, Yoshiura T, Noguchi T, Togao O, Yamashita K, Kamano H, Honda H. Kyphoplasty and vertebroplasty produce the same degree of height restoration. *AJNR Am J Neuroradiol* 2009; 30:669-673.
15. Papadopoulos EC, Edobor-Osula F, Gardner MJ, Shindle MK, Lane JM. Unipedicular balloon kyphoplasty for the treatment of osteoporotic vertebral compression fractures: Early results. *J Spinal Disord Tech* 2008; 21:589-596.
16. Kosmopoulos V, Keller TS, Schizas C. Early stage disc degeneration does not have an appreciable affect on stiffness and load transfer following vertebroplasty and kyphoplasty. *Eur Spine J* 2009; 18:59-68.
17. Mudano AS, Bian J, Cope JU, Curtis JR, Gross TP, Allison JJ, Kim Y, Briggs D, Melton ME, Xi J, Saag KG. Vertebroplasty and kyphoplasty are associated with an increased risk of secondary vertebral compression fractures: A population-based cohort study. *Osteoporos Int* 2009; 20:819-826.
18. Pflugmacher R, Taylor R, Agarwal A, Melcher I, Disch A, Haas NP, Klostermann C. Balloon kyphoplasty in the treatment of metastatic disease of the spine: A 2-year prospective evaluation. *Eur Spine J* 2008; 17:1042-1048.
19. Jadad AR, Moore RA, Carroll D: Assessing the quality of reports of randomized clinical trials: Is blinding necessary? *Control Clin Trials* 1996; 7:1-12.
20. Thillainadesan J, Schlaphoff G, Gibson KA, Hassett GM, McNeil HP. Long-term outcomes of vertebroplasty for osteoporotic compression fractures. *J Med Imaging Radiat Oncol* 2010; 54:307-314.
21. Syed MI, Patel NA, Jan S, Shaikh A, Grunden B, Morar K. Symptomatic re-fractures after vertebroplasty in patients with steroid-induced osteoporosis. *AJNR Am J Neuroradiol* 2006; 27:1938-1943.
22. Voormolen MH, Mali WP, Lohle PN, Fransen H, Lampmann LE, van der Graaf Y, Juttman JR, Janssens X, Verhaar HJ. Percutaneous vertebroplasty compared with optimal pain medication treatment: Short-term clinical outcome of patients with subacute or chronic painful osteoporotic vertebral compression fractures. The VERTOS Study. *AJNR Am J Neuroradiol* 2007; 28:555-560.
23. Wardlaw D, Cummings SR, Van Meirhaeghe J, Bastian L, Tillman JB, Ranstam J, Eastell R, Shabe P, Talmadge K, Boonen S. Efficacy and safety of balloon kyphoplasty compared with non-surgical care for vertebral compression fracture (FREE): A randomised controlled trial. *Lancet* 2009; 373:1016-1024.
24. Papanastassiou ID, Setzer M, Eleraky M, Baaj AA, Nam T, Binitie O, Katsares K, Cheong D, Vrionis FD. Minimally invasive sacroiliac fixation in oncologic patients with sacral insufficiency fractures using a fluoroscopy-based navigation system. *J Spinal Disord Tech* 2011; 24:76-82.
25. Kang SE, Lee JW, Kim JH, Park KW, Yeom JS, Kang HS. Percutaneous sacroplasty with the use of C-arm flat-panel detector CT: Technical feasibility and clinical outcome. *Skeletal Radiol* 2011; 40:453-460.
26. Douis H, James SL. CT-guided sacroplasty for the treatment of zone II sacral insufficiency fractures. *Clin Radiol* 2009; 64:1037-1040.
27. Bayley E, Srinivas S, Boszczyk BM. Clinical outcomes of sacroplasty in sacral insufficiency fractures: A review of the literature. *Eur Spine J* 2009; 18: 1266-1271.
28. Betts A. Vertebroplasty of the first sacral vertebra. *Pain Physician* 2009; 12: 651-657.
29. Figueiredo N, Rotta R, Cavicchioli A, Gonsales D, Casulari LA. Kyphoplasty versus percutaneous vertebroplasty using the traditional and the new side-opening cannula for osteoporotic vertebral fracture. *J Neurosurg Sci* 2011; 55:365-370.
30. Hirsch AE, Jha RM, Yoo AJ, Saxena A, Ozonoff A, Growney MJ, Hirsch JA. The use of vertebral augmentation and external beam radiation therapy in the multimodal management of malignant vertebral compression fractures. *Pain Physician* 2011; 14:447-458.

31. Boonen S, Wahl DA, Nauroy L, Brandi ML, Bouxsein ML, Goldhahn J, Lewiecki EM, Lyritis GP, Marsh D, Obrant K, Silverman S, Siris E, Akesson K; CSA Fracture Working Group of International Osteoporosis Foundation. Balloon kyphoplasty and vertebroplasty in the management of vertebral compression fractures. *Osteoporos Int* 2011; 22:2915-2934.
32. Klezl Z, Majeed H, Bommireddy R, John J. Early results after vertebral body stenting for fractures of the anterior column of the thoracolumbar spine. *Injury* 2011; 42:1038-1042.
33. Esses SI, McGuire R, Jenkins J, Finkelstein J, Woodard E, Watters WC 3rd, Goldberg MJ, Keith M, Turkelson CM, Wies JL, Sluka P, Boyer KM, Hitchcock K. The treatment of symptomatic osteoporotic spinal compression fractures. *J Am Acad Orthop Surg* 2011; 19:176-182.
34. Jensen ME, Evans AJ, Mathis JM, Kallmes DF, Cloft HJ, Dion JE. Percutaneous polymethylmethacrylate vertebroplasty in the treatment of osteoporotic vertebral body compression fractures: Technical aspects. *AJNR Am J Neuroradiol* 1997; 18:1897-1904.
35. Deramond H, Depriester C, Galibert P, Le Gars D. Percutaneous vertebroplasty with polymethylmethacrylate: Technique, indications, and results. *Radiol Clin North Am* 1998; 36:533-546.
36. Wilson DR, Myers ER, Mathis JM, Scribner RM, Conta JA, Reiley MA, Talmadge KD, Hayes WC. Effect of augmentation on the mechanics of vertebral wedge fractures. *Spine* 2000; 25:158-165.
37. Hadley C, Awan OA, Zoarski GH. Biomechanics of vertebral bone augmentation. *Neuroimaging Clin N Am* 2010; 20:159-167.
38. Graham J, Ahn C, Hai N, Buch BD. Effect of bone density on vertebral strength and stiffness after percutaneous vertebroplasty. *Spine* 2007; 32: E505-511.
39. Liebschner MA, Rosenberg WS, Keaveny TM. Effects of bone cement volume and distribution on vertebral stiffness after vertebroplasty. *Spine* 2001; 26:1547-1554.
40. Lin EP, Ekholm S, Hiwatashi A, Westesson PL. Vertebroplasty: Cement leakage into the disc increases the risk of new fracture of adjacent vertebral body. *AJNR Am J Neuroradiol* 2004; 25:175-180.
41. Huntton EA, Schmidt CK, Sinaki M. Significantly fewer refractures after vertebroplasty in patients who engage in back-extensor-strengthening exercises. *Mayo Clin Proc* 2008; 83:54-57.
42. Lin WC, Lee YC, Lee CH, Kuo YL, Cheng YF, Lui CC, Cheng TT. Refractures in cemented vertebrae after percutaneous vertebroplasty: A retrospective analysis. *Eur Spine J* 2008; 17:592-599.
43. Syed MI, Patel NA, Jan S, Harron MS, Morar K, Shaikh A. Intradiskal extravasation with low-volume cement filling in percutaneous vertebroplasty. *AJNR Am J Neuroradiol* 2005; 26:2397-2401.
44. Villarraga ML, Bellezza AJ, Harrigan TP, Crompton PA, Kurtz SM, Edidin AA. The biomechanical effects of kyphoplasty on treated and adjacent nontreated vertebral bodies. *J Spinal Disord Tech* 2005; 18:84-91.
45. Harrop J, Bronco P, Reinhardt MK. Incidence of remote and adjacent fractures after kyphoplasty. *Proceedings of the North American Spine Society*, Montreal, Quebec, Canada, 2002.