

Case Report

Acute Cauda Equina Syndrome Secondary to a Lumbar Synovial Cyst

Jeffery J. Muir, MD¹, Matthew J. Pingree, MD², and Susan M. Moeschler, MD²

From: ¹Pain Management, Dartmouth-Hitchcock Medical Center, Lebanon, NH; ²Division of Pain Medicine, Department of Anesthesiology, Mayo Clinic, Rochester, MN

Address Correspondence: Jeffery J. Muir, MD
Pain Management
Dartmouth-Hitchcock Medical Center
One Medical Center Drive
Lebanon, NH 03756

E-mail: Jeffery.J.Muir@hitchcock.org

Disclaimer: There was no external funding in the preparation of this manuscript.

Conflict of interest: None.

Manuscript received: 01/30/2012

Revised manuscript received: 03/29/2012

Accepted for publication: 05/03/2012

Free full manuscript: www.painphysicianjournal.com

Cauda equina syndrome is a well described state of neurologic compromise due to lumbosacral root compression. In most cases, it is due to a herniated disc, tumor, infection, or hematoma. We report a case of rapid lumbar synovial cyst expansion leading to acute cauda equina syndrome and compare it to similar cases in the literature.

The patient is a 49-year-old woman with a history of chronic low back pain who developed cauda equina syndrome. Serial lumbar magnetic resonance imaging studies demonstrated a significant increase in the size of a lumbar synovial cyst over a 2 week interval. After an unsuccessful attempt to relieve her acute symptoms with computed tomography-guided cyst aspiration, an L4-5 posterior spinal decompression with excision of the synovial cyst was performed.

Postoperatively the patient's perineal numbness, bladder incontinence, and associated pain complaints resolved. The only residual symptom at one month follow-up was continued numbness in the right lower limb in an L5 distribution.

This report adds to 6 other well described similar cases found in the literature by illustrating several important points. First, a lumbar synovial cyst is a rare but possible cause of acute cauda equina syndrome. Second, magnetic resonance imaging is the test of choice to diagnose and characterize lumbar synovial cysts; serial imaging can detect fluctuations in cyst size. Third, percutaneous treatment of lumbar synovial cysts is variable in efficacy and proved to be unsuccessful in our patient. Finally, surgical management has shown high success rates for symptomatic cysts. Specifically, in the setting of acute cauda equina syndrome secondary to a lumbar synovial cyst, urgent surgical decompression has led to resolution of neurologic symptoms in most reported cases.

A lumbar synovial cyst is an uncommon cause of acute cauda equina syndrome. Prompt diagnosis and treatment may lead to reduced morbidity associated with this condition.

Key words: Acute pain, cauda equina syndrome, lumbar, polyradiculopathy, synovial cyst, zygapophyseal joint

Pain Physician 2012; 15:435-440

Cauda equina syndrome is a well described state of neurologic compromise due to lumbosacral root compression. If left untreated it can cause permanent bowel, bladder, and sexual dysfunction as well as lower limb sensory and motor deficits. It is most often caused by mass effect from a herniated disc, tumor, infection, stenosis, or hematoma (1). Rarely, cauda equina syndrome may be caused by a lumbar synovial

cyst (LSC) compressing the nerve roots of the cauda equina. Herein, we report a case of rapid LSC expansion leading to acute cauda equina syndrome and review similar cases reported in the literature. For the purposes of this paper, the term "acute" refers to symptomatic onset of cauda equina syndrome within 2 weeks or less as opposed to "subacute" or "chronic," which would come on more gradually over a longer time period.

CASE REPORT

A 49-year-old obese woman with a 10 year history of chronic back pain presented to a pain clinic due to exacerbation of low back pain with radiating features into the right leg greater than the left leg. Her symptoms began after lifting a heavy object at work. Neurologic examination was essentially normal. Lumbar spine x-rays showed degenerative facet hypertrophy with normal spine alignment and no evidence of spondylolysis or spondylolisthesis. Magnetic resonance imaging (MRI) of the lumbar spine revealed interval progression of degenerative facet arthritis with increased fluid in the right L4-5 facet joint; a small cyst in the dorsal epidural space just right of midline appeared to communicate with this joint via a subligamentous defect in the ligamentum flavum (Figs. 1A and 1B). The patient subsequently underwent a fluoroscopically guided right L4 transforaminal injection and right L4-5 facet injection after an unsuccessful joint aspiration attempt. These interventions provided her with approximately 24 hours of pain relief before returning to her baseline pain level.

Five days after the procedure, the patient contacted the pain clinic by telephone complaining of increasing pain in the right lower limb with associated

numbness laterally. She denied any focal weakness, or bowel/bladder changes. Medications were provided for pain management. Shortly thereafter, electromyography was performed to help identify if any subacute or chronic neurogenic changes were present that corresponded to her symptoms; the electrodiagnostic results were normal. A spine surgery consultation was then scheduled.

One week later the patient presented to the emergency department in the late afternoon after experiencing increasingly severe low back and lower limb pain with associated numbness and paresthesias, saddle anesthesia, and urinary incontinence that developed over the course of the day. Her pain ranged from a 6/10 to 10/10 in intensity and localized to the right greater than left low back; it radiated predominately down the posterior right leg and was of a burning, shock-like quality. The pain was aggravated with walking as well as prolonged sitting or standing. There were no alleviating factors. The numbness she reported included the lateral aspect of the right lower leg with new numbness along the lateral aspect of her left thigh. There was no focal weakness, but she noted difficulty walking up stairs and a subjective sense of right lower limb heaviness. The saddle anesthesia was described as new

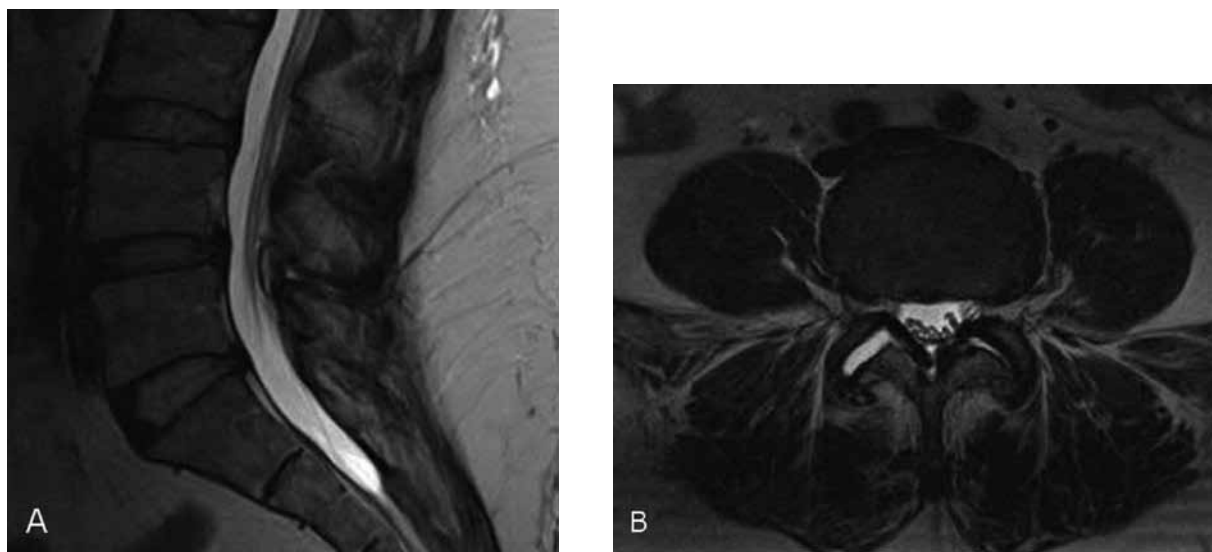


Fig. 1. T2-weighted lumbar MRI. (A) Sagittal view—small cyst appreciated along the dorsal epidural space at the L4-5 level. (B) Axial view—increased fluid in the right L4-5 facet with subtle apparent connection with dorsal epidural space via a defect in the ligamentum flavum.

numbness in the perineal region on the right more than left side. She experienced urinary incontinence without associated retention. Bowel function was normal.

Physical examination revealed moderate tenderness to palpation over the right greater than left low back and upper gluteal region. Weakness was limited to some distal L5-S1 innervated muscles, namely the bilateral toe extensors and right peronei muscles (graded 4/5 in strength). There was decreased sensation to pinprick and light touch in the perineal and medial buttock region—more so on the right. Deep tendon reflexes were diminished at the ankles but otherwise normal. Rectal tone was present but decreased, while the anal reflex was absent. The straight leg raise test was positive at 15 degrees on the right and 30 degrees on the left. The FABER test was negative.

A repeat MRI of the lumbar spine revealed a dorsal epidural cyst measuring 0.4 x 0.6 x 1.0 cm at the L4-5 level, which had increased in size compared to the prior study 2 weeks earlier and was now causing moderate central spinal canal narrowing (Figs. 2A and 2B). The cyst was isointense compared to cerebrospinal fluid. A fluid tract connecting the cyst to the right facet joint was not appreciable; however, a moderate amount of fluid was present in the right facet joint.

The patient was admitted to the Neurology service for close observation and computed tomography (CT)-guided cyst aspiration was attempted soon thereafter. Approximately 2 mL of fluid was withdrawn from the right facet joint and 1.5 mL from the cyst in the epidural space. During the procedure contrast medium flowed from the facet to the cyst, confirming continuity between these structures (Fig. 3). Unfortunately, the patient experienced increased pain and numbness after the procedure. A repeat neurologic exam revealed more pronounced pin prick and light touch deficits in the perineal region and new sensory deficits in the buttocks and posterolateral lower limbs bilaterally. Rectal tone was further decreased. The remainder of the exam was unchanged. The patient was monitored closely with hourly neurologic checks and remained stable. Approximately 36 hours after presenting to the emergency department, the patient underwent an urgent L4 laminectomy, ligamentum flavum resection, L4-5 joint capsule removal, and cyst excision. Pathologic examination confirmed the cyst to be benign and synovial in origin.

The patient experienced resolution of the perineal numbness, bladder incontinence, and pain complaints within approximately 12 hours postoperatively. At one

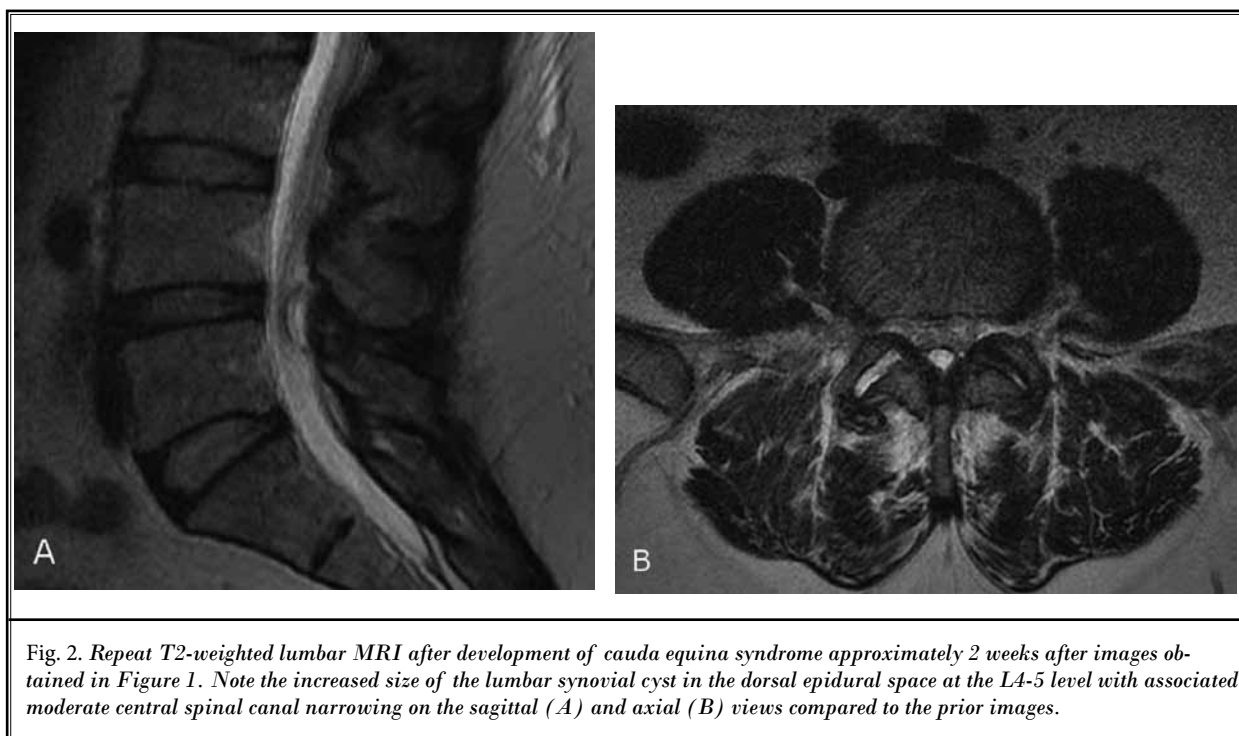

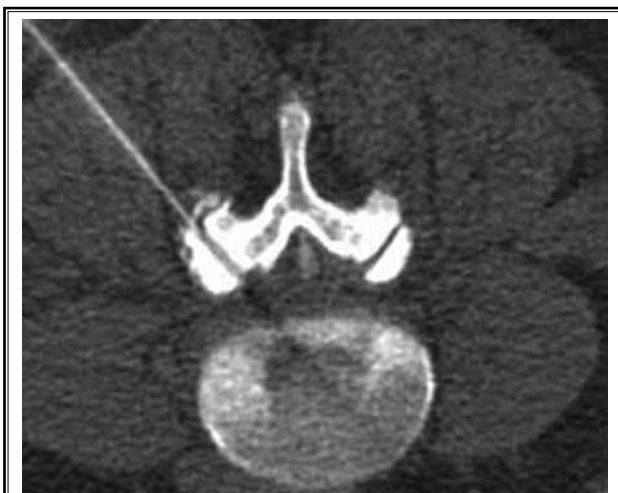


Fig. 3. CT-guided aspiration of the right L4-5 facet joint. Note contrast is seen in the dorsal epidural cyst, confirming a connection exists with the facet joint.

month follow-up, her only residual symptom was some continued numbness in the right lower limb in the L5 distribution.

Discussion

This case report describes a patient who developed cauda equina syndrome due to rapid expansion of an LSC. LSCs have become increasingly recognized in the literature as an uncommon cause of low back pain and lumbosacral neurologic problems. Axial synovial cysts can occur in cervical and thoracic segments, but are most commonly found in the lumbar spine (2-4). The prevalence of LSCs is highest in the seventh decade and a slight female predominance is reported (5). As was the case with our patient, LSCs most frequently occur at the L4-5 level. The next most frequent level is L5-S1 followed by L3-4 and L2-3, respectively (6). LSCs are thought to be caused by protrusion and expansion of the synovial membrane from degenerative facet joints due to segmental instability or trauma, which explains their association with conditions such as osteoarthritis and spondylolisthesis (5,7). Although these cysts can be classified as synovial (synovium lining) or ganglion (nonsynovium connective tissue lining) types based on histology, the distinction is not clinically relevant as the presentation, treatment, and outcomes are similar. When evaluating a patient such as ours with an extra-axial cystic structure in the posterior spinal canal, it is important to note a broad differential exists, including LSCs, migrated herniated disk fragments, infectious

cysts, arachnoid cysts, schwannomas, Tarlov cysts, cystic bone lesions, and interspinous bursae secondary to Baastrup disease (8,9).

Patients with symptomatic LSCs typically present with sciatica or neurogenic claudication but in some cases cauda equina syndrome may develop. Lyons et al (3) reported variants of cauda equina syndrome in 13% of 194 patients surgically treated for LSCs. However, a detailed description of these patients was not included. A search of the literature using PubMed and Google revealed 6 well described cases of acute cauda equina syndrome secondary to LSCs (Table 1). Three of these were caused by unilateral hemorrhagic cysts (10-12), one occurred in a patient with bilateral L4-5 juxtafacet cysts who was placed in the lithotomy position for a urologic surgery (13), another was due to a large L2-3 cyst that developed in a patient with chronic central canal stenosis and spondylolisthesis (14), and the last happened spontaneously in the setting of bilateral juxtafacet cysts (15). Each of these patients experienced lower limb motor and sensory changes in addition to bladder and/or bowel dysfunction. Saddle anesthesia was reported in one of the cases.

Because clinical symptoms and signs are nonspecific in detecting the underlying cause of cauda equina syndrome, diagnostic imaging is of great value. MRI is the investigation of choice for diagnosis and characterization of LSCs. Our case illustrates several important MRI findings regarding these cysts. First, LSCs are typically isointense compared to cerebrospinal fluid on T1- and T2-weighted sequences. However, if additional contents such as blood or protein are contained within the cyst, then deviation from this signal intensity will occur (16). More detailed descriptions of specific MRI signal changes with respect to LSCs and other spine entities have previously been published in the literature (16,17). Our patient's LSC was isointense compared to cerebrospinal fluid and, thus, nonhemorrhagic; this was confirmed upon pathologic examination. Second, although the appearance of a clearly defined stalk is often not appreciated on MRI, all synovial juxtafacet cysts are joint derived (7). An obvious stalk was not appreciable on our patient's MRI after development of cauda equina syndrome (Figs. 2A and 2B), but the study from 2 weeks earlier showed a defect in the ligamentum flavum with fluid tracking subligamentously from the right L4-5 facet joint (Fig. 1B). Confirmation of this connection was observed during CT-guided aspiration as contrast medium flowed from the joint to cyst (Fig. 3). Finally, as previously reported by Bozzao et al (18),

Table 1. *Acute cauda equina syndrome cases due to lumbar synovial cysts reported in the literature*

Author(s)	Year	Cause	Age/Sex	Symptoms	Treatment	Follow-up
Brown et al. (10)	2005	Hemorrhagic L4-5 cyst	68/M	2-3 months of difficulty walking/standing; 1 week of worsened bilateral sciatica, increased back pain, bilateral leg weakness, and urinary dysfunction.	Surgical decompression	2 years; full recovery
Wait et al. (11)	2005	Hemorrhagic L3-4 cyst	69/M	8 months of right sciatica; 2 weeks of worsened right radicular symptoms; 3 days of voiding difficulty	Surgical decompression	4 months; full recovery
Rahimzadah (12)	2011	Hemorrhagic L4-5 cyst	67/F	Chronic low back pain and radicular symptoms; exacerbation of pain symptoms and voiding difficulty/incontinence over 1 week	Surgical decompression	1 month; full recovery
Wills et al. (13)	2004	Lithotomy position during surgery; L3-4 cyst	70/M	Lower limb weakness and decreased sensation on POD1; Hypotonic bladder and retention on POD6	Surgical decompression	Several months; full recovery
Shaw et al. (14)	2004	Idiopathic L2-3 cyst	63/F	3 weeks of back and leg pain; 1 week of progressive bladder and bowel incontinence, saddle anesthesia, and leg weakness	Surgical decompression	6 months; full recovery
Kim et al. (15)	2005	Idiopathic bilateral L4-5 cysts	62/F	3 months of low back pain and radicular symptoms.; 1 day of weakness and numbness in L5 distribution and voiding difficulty	Surgical decompression	2 weeks; continued voiding difficulties

fluctuations in cyst size can be documented on serial MRI studies. Significant cyst expansion was clearly identified in our patient after comparing MRI studies before and after the development of cauda equina syndrome.

Treatment for LSCs includes both nonsurgical and surgical approaches with the latter resulting in higher success rates. Percutaneous interventions, including cyst aspiration, injection, and/or rupture, are the most studied nonsurgical treatments in the literature. Although outcomes are variable with success rates ranging from 20% to 75% with percutaneous interventions, in general, approximately 50% of patients gain significant relief from this treatment when using surgery as a definitive endpoint (19). In the largest clinical series of nonoperative LSC treatment, Martha et al (20) reported a 46% success rate in 101 patients after percutaneous facet joint injection and attempted cyst rupture. As previously mentioned, surgery is quite successful at treating LSCs. Lyons et al (3) reported outcomes of 147 patients surgically treated for symptomatic LSCs. Results 6 months or longer after surgery were good to excellent in 91% with the vast majority experiencing improved motor and sensory function.

All 6 previously reported cases of acute cauda equina syndrome secondary to LSCs were treated surgically with full recovery in 5 out of the 6 patients; one pa-

tient continued to experience bladder dysfunction. Our patient initially presented with sciatica and underwent fluoroscopically guided LSC aspiration and steroid injection without lasting pain relief. Two weeks later, she developed acute cauda equina syndrome and CT-guided aspiration was attempted without improvement of her symptoms. Subsequently, surgical decompression was performed and resulted in nearly full neurologic recovery similar to the prior case report outcomes. The exact cause for the patient's rapid LSC expansion is unknown; however, a possible explanation is the initial fluoroscopic facet injection compromised the structural integrity of the cyst, allowing it to quickly expand along the path of least resistance into the epidural space and compress the cauda equina.

CONCLUSION

In summary, LSCs are a rare but possible cause of acute cauda equina syndrome. MRI is the imaging test of choice to diagnose and characterized LSCs; serial imaging can detect fluctuations in cyst size. Although percutaneous intervention may be attempted, results are quite variable and inconsistent. Prompt surgical treatment has led to resolution of neurologic deficits in patients presenting with acute cauda equina syndrome secondary to LSCs.

REFERENCES

1. Fraser S, Roberts L, Murphy E. Cauda equina syndrome: a literature review of its definition and clinical presentation. *Arch Phys Med Rehabil* 2009; 90:1964-1968.
2. Costa F, Menghetti C, Cardia A, Fornari M, Ortolina A. Cervical synovial cyst: case report and review of literature. *Eur Spine J* 2010; 19 Suppl 2:S100-102.
3. Lyons MK, Atkinson JL, Wharen RE, Deen HG, Zimmerman RS, Lemens SM. Surgical evaluation and management of lumbar synovial cysts: The Mayo Clinic experience. *J Neurosurg* 2000; 93:53-57.
4. Merkle M, Psaras T, Tatagiba M, Danz S, Schmidt F. Synovial cyst of the thoracic spine causing myelopathy. *Spine (Phila Pa 1976)* 2009; 34:E199-E201.
5. Boviatsis EJ, Stavrinou LC, Kouyialis AT, Gavra MM, Stavrinou PC, Themistokleous M, Selviaridis P, Sakas DE. Spinal synovial cysts: Pathogenesis, diagnosis and surgical treatment in a series of seven cases and literature review. *Eur Spine J* 2008; 17:831-837.
6. Epstein NE. Lumbar synovial cysts: A review of diagnosis, surgical management, and outcome assessment. *J Spinal Disord Tech* 2004; 17:321-325.
7. Spinner RJ, Hebert-Blouin MN, Maus TP, Atkinson JL, Desy NM, Amrami KK. Evidence that atypical juxtafacet cysts are joint derived. *J Neurosurg Spine* 2010; 12:96-102.
8. Chen CK, Yeh L, Resnick D, Lai PH, Liang HL, Pan HB, Yang CF. Intraspinous posterior epidural cysts associated with Bastrup's disease: Report of 10 patients. *AJR Am J Roentgenol* 2004; 182:191-194.
9. Mahallati H, Wallace CJ, Hunter KM, Bilbao JM, Clark AW. MR imaging of a hemorrhagic and granulomatous cyst of the ligamentum flavum with pathologic correlation. *AJNR Am J Neuroradiol* 1999; 20:1166-1168.
10. Brown C, Stambough JL. Epidural hematoma secondary to a rupture of a synovial cyst. *Spine J* 2005; 5:446-450.
11. Wait SD, Jones FD, Lonser RR, Lee KS. Symptomatic epidural hematoma caused by lumbar synovial cyst rupture: Report of two cases and review of the literature. *Neurosurgery* 2005; 56:E1157; discussion E1157.
12. Rahimizadeh A. Bleeding in a lumbar juxtafacet cyst with cauda equina syndrome: Report of a case and review of the literature. *World Spinal Column Journal* 2011; 2:46-51.
13. Wills JH, Wiesel S, Abram SE, Rupp FW. Synovial cysts and the lithotomy position causing cauda equina syndrome. *Reg Anesth Pain Med* 2004; 29:234-236.
14. Shaw M, Birch N. Facet joint cysts causing cauda equina compression. *J Spinal Disord Tech* 2004; 17:442-445.
15. Kim SW, Lee SM. Cauda equina syndrome caused by bilateral facet cyst accompanying spinal stenosis. *J Korean Neurosurg Soc* 2004; 37:76-78.
16. Khalatbari K, Ansari H. MRI of degenerative cysts of the lumbar spine. *Clin Radiol* 2008; 63:322-328.
17. Marichal DA, Bertozzi JC, Rehtine G, Murtagh FR. Case 101: Lumbar facet synovial cyst. *Radiology* 2006; 241:618-621.
18. Bozzao A, Floris R, Fraioli C, Ticca L, Simonetti G. "Relapsing-remitting" bilateral synovial cysts of the lumbar spine. A case report. *Neuroradiology* 2001; 43:1076-1078.
19. Shah RV, Lutz GE. Lumbar intraspinal synovial cysts: Conservative management and review of the world's literature. *Spine J* 2003; 3:479-488.
20. Martha JF, Swaim B, Wang DA, Kim DH, Hill J, Bode R, Schwartz CE. Outcome of percutaneous rupture of lumbar synovial cysts: A case series of 101 patients. *Spine J* 2009; 9:899-904.