

Retrospective Study

Radiofrequency Neurolysis Versus Local Nerve Infiltration in 42 Patients with Refractory Chronic Inguinal Neuralgia

Adrian Kastler, MD^{1,3}, Sebastien Aubry, MD, PhD^{2,3}, Veronique Piccand, MD⁴,
Georges Hadjidekov, MD², Florence Tiberghien, MD⁴, and Bruno Kastler, MD, PhD^{2,3}

From: ¹Radiology Department
CHU Gabriel Montpied,
Clermont-Ferrand, France;
²Interventional Pain
Management Unit, CHU Jean
Minjoz, Besançon, France;
³US Laboratory, IFR 133 UA
4268 Franche Comté Univerity
Besançon, France; ⁴Pain
Evaluation and Treatment
Unit, CHU Jean Minjoz,
Besançon, France.

Address correspondence:
Adrian Kastler, MD
Hôpital Jean Minjoz
CHU Besançon
Bvd Fleming
25000 Besançon, France
E-mail: adriankastler@gmail.
com

Disclaimer: There was
no external funding in
the preparation of this
manuscript.

Conflict of interest: None.

Manuscript received:
05/31/2011
Revised manuscript received:
01/07/2012
Accepted for publication:
02/09/2012

Free full manuscript:
www.painphysicianjournal.
com

Background: Chronic inguinal neuralgia involving ilioinguinal and iliohypogastric nerves is a frequent complication of surgical procedures involving a lower abdominal incision such as hernia repair, appendicitis surgery, or cesarean sections. Chronic inguinal neuralgia is a very painful condition and diagnosis can be challenging as it is an overlooked impairment. Existing specific treatments are inefficient and often fail.

Objective: The purposes of this study are to describe, evaluate, and compare ilioinguinal and iliohypogastric radiofrequency neurolysis (RFN) and local injection.

Study Design: Retrospective comparison cohort study from 2005 to 2011.

Setting: A single center, Academic Interventional Pain Management Unit

Methods: Forty-two patients suffering from chronic inguinal pain refractory to specific medication were included. A total of 18 RFN procedures (14 patients) and 28 injections (28 patients) were performed. Pain was assessed in both groups using Visual Analog Scale (VAS) scores (0-10) measured immediately before and after the procedure and at one, 3, 6, 9, and 12 months after the procedure. Mean duration of pain prior to the procedure and mean duration of pain relief were noted. Moreover, mean maximum early pain relief was assessed. All procedures were ambulatory under computed tomography (CT) guidance. Injections contained 1.5 mL of cortivazol and 3 mL of lidocaine-ropivacaine (30%-70%). Radiofrequency neurolysis was performed using a Neurotherm RF Generator. In both cases, 22-gauge needles were used. After needle retrieval, control slices were taken and the patient was supervised for 30 minutes at the CT unit.

Results: The mean age in both groups was 48.7 years. Forty-two patients (97.6%) presented postsurgical inguinal pain, 62% of which occurred after hernia repair. All included patients had undergone previously unsuccessful pain therapies. Mean VAS scores were 7.72 in the RF group and 7.46 in the infiltration group. Maximum early pain relief did not statistically differ (77% in the RFN group and 81.5% in the injection group). Mean duration of pain relief was statistically significant ($P = .005$) in the RF group (12.5 months) compared to the infiltration group (1.6 months). Mean VAS scores during the year following the procedure were all significantly in favor of radiofrequency neurolysis management.

Limitations: Those inherent to small study samples and retrospective studies.

Conclusion: Radiofrequency neurolysis appears to be significantly more effective than local nerve infiltrations. It is a safe and effective treatment for chronic inguinal pain. Local steroid injection along with local injection of anesthetics should be used as a confirmation of ilioinguinal neuropathy before performing radiofrequency neurolysis.

Key words: Radiofrequency, Ilioinguinal, Iliohypogastric, neuropathy, infiltration, computed tomography guidance.

Pain Physician 2012; 15:237-244

Chronic inguinal neuralgia involving ilioinguinal and iliohypogastric nerves is a very painful condition with a high socioeconomic impact (1-4). It is a well-known complication of surgical procedures involving a lower abdominal incision (1,2,5,6). The diagnosis of these neuralgias can be challenging and existing conservative treatments often fail. Ilioinguinal and iliohypogastric nerve blocks are well described in the literature and are often used in pediatric surgery (7). Local infiltration of anesthetics and steroids is widely used in pain management and has been described in this indication with satisfactory results (8). Moreover, radiofrequency neurolysis (RFN) has become a common procedure in interventional pain management. We therefore studied the efficacy, safety, and feasibility of both local nerve infiltration and RFN for the management of chronic ilioinguinal and iliohypogastric pain. The purposes of this study are to describe, evaluate, and compare these 2 treatments.

METHODS

Forty-two patients suffering from chronic inguinal pain were included in this single center retrospective study from 2005 to 2011. Only patients who had failed specific neuropathic oral therapy were included in the study. The same treatment algorithm was always followed prior to the procedure: antiepileptic drug therapy was the first line treatment; in case of failure, tricyclic antidepressant therapy was introduced. In case of failure of either treatments, a combination of both

was tried. In some cases, topical antineuralgics were used. Local Institutional Review Board approval was obtained. The data were collected from patients' medical records and included information on demographics, clinical, and pain management history.

Pain

Pain was assessed using Visual Analog Scale scores (0-10) measured immediately before and after the procedure and at one, 3, 6, 9 and 12 month follow-up examinations. Mean maximum early pain relief and mean duration of pain prior to the procedure were assessed in both groups. Pain was defined as chronic when it lasted for at least 6 months. A score of less than 2 was graded as mild pain, a score between 2 and 5 was graded as moderate pain, and a score above 5 was graded as severe pain (9). Pain distribution and etiology were also noted.

Procedure

All procedures were accomplished on an outpatient basis by one of several authors (AK, SA, BK) with computed tomography (CT) guidance (Philips Brilliance CT 64-channel scanner, Eindhoven, The Netherlands, and Siemens Somatom Sensation CT 64-channel scanner, Erlangen, Germany). An initial planning CT was performed at the level of the anterior superior iliac spine and the target was located between the transverse abdominal muscle and the lesser oblique muscle (Fig. 1). After accurate marking of the skin, local subcu-

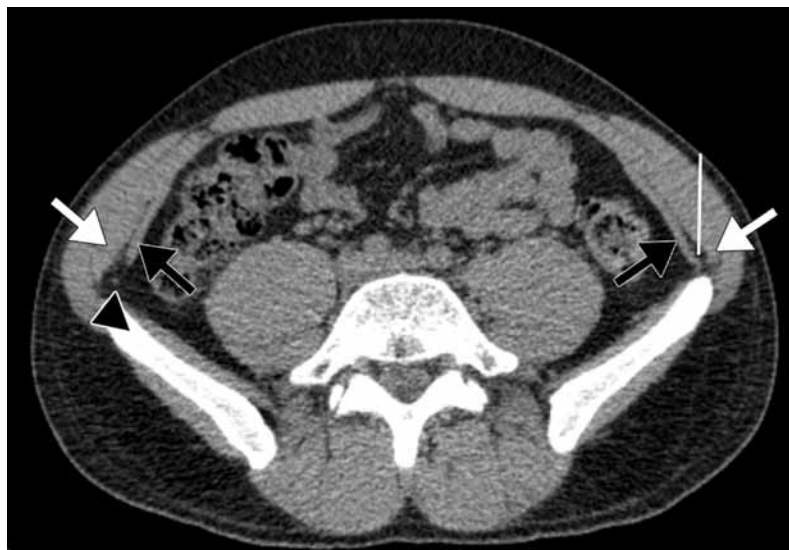

Fig. 1. Planning axial CT scan showing target location prior to needle insertion. Black arrow : transverse abdominal muscle. White arrows : internal oblique muscle. Arrowhead: ilioinguinal-iliohypogastric nerves

taneous infiltration of lidocaine hydrochloride 1% was performed at the defined skin entry point. A safe step-by-step progression of the needle (22-gauge) was performed under CT guidance until the needle tip artifact was located at the defined target (Fig. 2).

For steroid injection, diluted iodinated contrast media was injected first in order to control accurate needle positioning. Once the contrast media diffused between the transverse abdominal muscle and the lesser oblique muscle (Fig. 3), a mixture of fast and slow

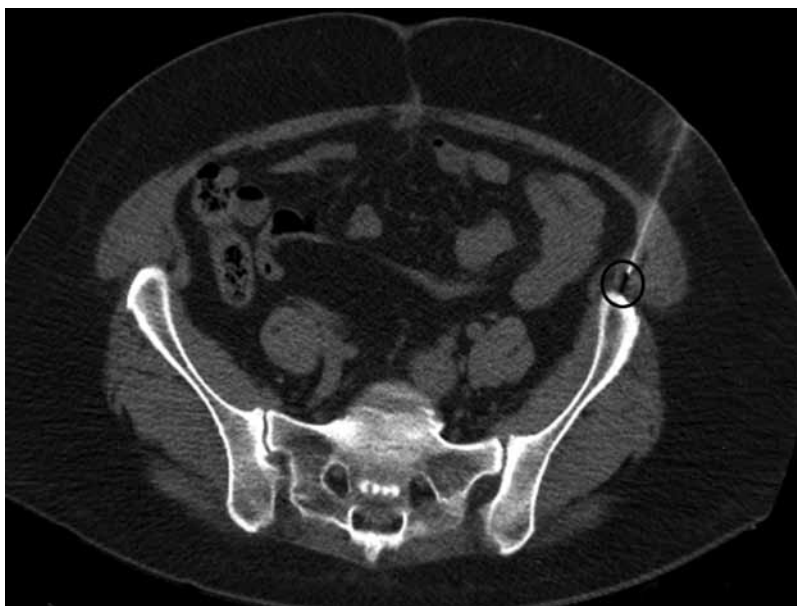

Fig. 2. CT slice showing needle tip artifact (black circle) at defined target.

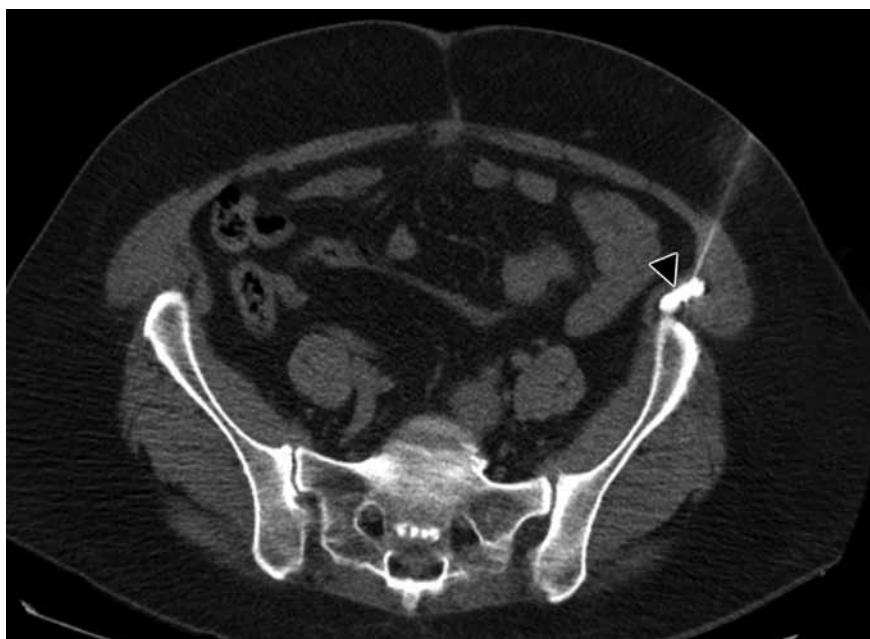

Fig. 3. CT slice after injection of contrast media (arrowhead) at defined target.

acting anesthetic (1 mL lidocaine hydrochloride 1% and 2 mL ropivacaine chlorhydrate were injected followed by 1.5 mL of cortivazol [3.75 mg]).

One of 2 radiofrequency (RF) generators was used for RFN (RF 3FG, Radionics, Burlington, NJ and NT1100 RF Generator Neurotherm, Wilmington, MA). Once the RF needle tip artifact was located at the defined target (Fig. 2) (22-gauge, 50-100 mm, 5 mm exposed tip), stimulation mode was used to obtain the exact needle position immediately adjacent to the nerve. The needle orientation could be modified until the patient described a tingling sensation in the painful territory. This was considered as a technical success for the needle positioning. One mL of lidocaine hydrochloride 1% was then injected before RFN was started. Three 90 second RF cycles were performed in lesion mode at 70°C, 80°C, and 90°C. After needle retrieval, a control axial CT scan was performed and the patient was supervised for 30 minutes at the CT Unit.

RESULTS

Patients

A total of 42 patients were included in our study: 14 in the RFN group and 28 in the infiltration group. The mean age in the whole population was 48.7 years: 43.9 years in the RFN group and 49.5 years in the infiltration group. All but one patient (97.6%) presented with postsurgical-induced chronic inguinal pain and 62% of patients presented with pain after hernia repair. The etiologies of inguinal neuralgia are detailed in Table 1. The local pain management unit referred 90% of the patients, surgeons referred 7%, and general practitioners referred 2.5%.

Three patients in the RF group benefited from repeated RFN because of satisfactory initial results (2 RFN in 2 patients and 3 RFN in one patient). As a result, 18

RFN procedures and 28 local nerve infiltrations were performed. The mean duration of the RFN procedures was 25.4 minutes (range 19 - 33 minutes). No side effects were noted.

Pain

The patients' description of pain included electric sensation (85%), hypoesthesia (32%), allodynia (14%), stabbing (24%) or irritation (10%). In 62% of cases, pain consisted of paroxysmal attacks of short, sharp pain superimposed on a dull background of pain that was responsible for multiple nights of interrupted sleep. Painful regions, as shown in Fig. 4, were the lateral cutaneous branch of the iliohypogastric nerve, 11 cases; inguinal region, 13 cases; scrotal region, 6 cases; lateral cutaneous branch and inguinal regions, 7 cases; and inguinal and scrotal regions, 5 cases.

Pain was present for an average of 2.8 years (range 2 – 5 years) prior to the initial procedure with a mean VAS score of 7.6/10 and was therefore classified as severe. Mean VAS scores were 7.72 in the RF group and 7.46 in the infiltration group. Immediate pain relief was

Table 1. *Etiologies of inguinal neuralgia.*

ETIOLOGY	PATIENTS
Hernia Repair	19 (46.4%)
Multiple Hernia Repair	6 (14.3%)
Testicular Surgery	5 (12.2%)
Gynecological Surgery	5 (12.2%)
Appendicitis Surgery	3 (7.3%)
Other Surgery	2 (4.9%)
Testicular and Hernia Surgery	1 (2.4%)
Trauma	1 (2.4%)

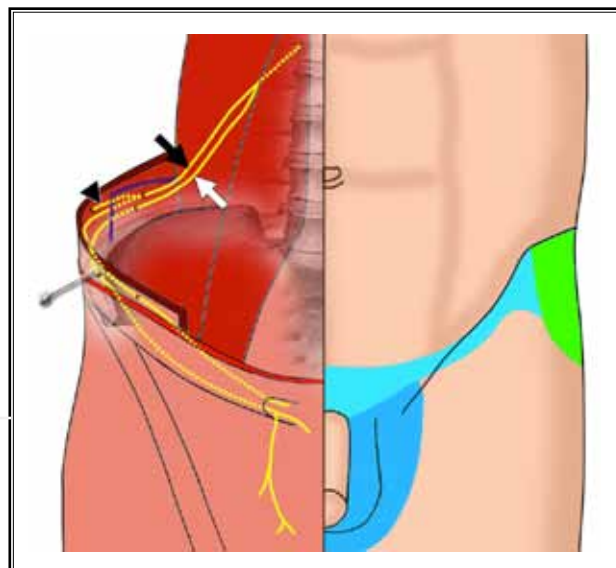


Fig. 4. *Anatomical routes of both ilioinguinal (white arrow) and iliohypogastric (black arrow) nerves and their regions of distribution.*

Blue: Common to both nerves

** Light : Inguinal region*

** Dark : Scrotal region*

Green: Lateral cutaneous branch (black arrowhead) of iliohypogastric nerve distributing in upper and lateral part of thigh.

≥ 95% in all patients, thereby confirming the diagnosis. Technical success rate was 100%. Mean maximum early pain relief did not statistically differ between the 2 techniques (RF group, 77%; infiltration group, 81.5%; $P = 0.54$).

In the RF group, mean duration of pain relief (12.5 months) was significantly higher ($P = 0.005$) than in the infiltration group (1.6 months). VAS scores at one, 3, 6, 9, and 12 month follow-up examinations were statistically inferior for those in the infiltration group (Table 2). The evolution of mean VAS scores is represented in

Fig. 5 for both groups. Two patients treated with RFN had long-term (> 36 months) pain relief and treatment was therefore considered definitive. We report only one failure of RFN, lasting for 15 days. Important pain reduction (≥ 80%) was obtained in 72% of RFN procedures (13/18) at 6 months follow-up and in 44% of cases at 12 months (8/18).

In the infiltration group, mean duration of pain relief was 1.6 months and ranged from 3 hours to 12 months. We report 7 cases of pain relief lasting for one day or less.

Table 2. VAS scores at one, 3, 6, 9 and 12 months

	Mean VAS Scores (/10)						Mean duration (months)	Mean Maximum Early Pain Relief
	Before procedure	M1	M3	M6	M9	M12		
RF Group	7.72	1.4	1.6	1.7	4.0	4.8	12.5	77%
Infiltration Group	7.46	4.8	6.1	6.5	6.9	6.9	1.6	81.5%
t-test	$P = 0.273$	$P < 0.001$	$P < 0.001$	$P < 0.001$	$P = 0.004$	$P = 0.021$	$P = 0.005$	$P = 0.54$

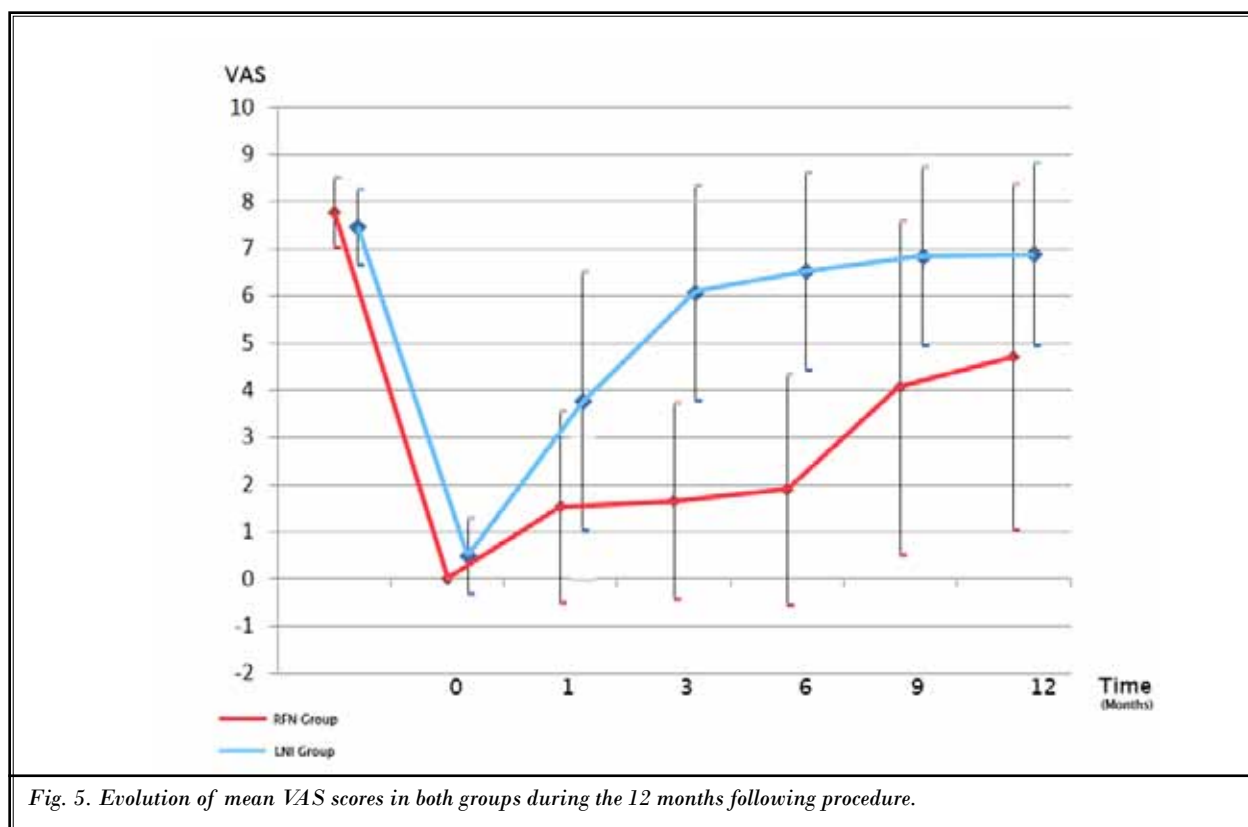


Fig. 5. Evolution of mean VAS scores in both groups during the 12 months following procedure.

DISCUSSION

Our study showed significantly longer lasting pain relief after RFN compared to local nerve infiltration in patients with refractory inguinal neuralgia. Indeed, a mean pain reduction of 12.5 months was obtained with a mean maximum early pain relief of 77%. Only one patient was a failure in the RFN group. This patient was the first to undergo RFN in our center, and we therefore think that the failure of this RFN is partly explained by our lack of expertise in this first procedure. A previous study showed satisfactory pain reduction in 75% of patients treated with 4 to 5 repeated local infiltrations (8). However, no details were given about long-term results. Moreover, satisfactory long-term results were obtained in all but one patient with one minimally invasive procedure. Even though mean pain relief duration after local infiltration (1.6 months) appeared significantly inferior to RFN in our study, it remains useful as a block test for diagnosis and may furthermore induce beneficial short- to mid-term pain relief (up to 12 months). We therefore always perform a diagnostic block with a local infiltration of steroids prior to RFN in our institution to establish the diagnosis and rule out central pain. Patients are re-evaluated and RFN is performed in case of pain recurrence only after a positive initial diagnostic block test.

Anatomical knowledge of the ilioinguinal and iliohypogastric nerves is a necessary condition to successful image-guided inguinal RFN or infiltrations (Fig. 5). Both the ilioinguinal and iliohypogastric nerves arise from the L1 root (common trunk in 35% of cases). Their course is quite similar. They descend on the quadratus lumborum muscle along the parietal peritoneum, perforate the transverse abdominal muscle, and course between the transverse abdominal muscle on the inside and the lesser oblique on the outside at the level of the anterior superior iliac spine. The iliohypogastric nerve has a branch called the lateral cutaneous branch at this level that distributes in the upper lateral part of the thigh. Both the ilioinguinal and iliohypogastric nerves then pass along the inguinal canal to become subcutaneous in their territories of distribution (inguinal, groin, scrotal region, and upper medial part of the thigh). Numerous anatomical variants are described in the literature (up to 60%) (10,11) but these variations mainly concern the penetrating site of the muscle layers (12). The distributions of the 2 nerves are quite constant and overlapping.

Because of the superficial nature of these nerves, they are often injured in surgical procedures involving a

lower abdominal incision. Our study showed that 97.5% of the included patients had postsurgical inguinal neuralgia and that 62% followed hernia repair. Reports of inguinal neuralgia rates from open mesh hernia surgery range from 10% to 25%, especially when a Pfannenstiel incision is performed (1,2,5). Five patients (12.2%) {this percentage would be based on 41 patients, not 42} in this study presented postgynecological surgery neuralgia. The literature reports complication rates of 1.8% especially after caesarian section (6). Other nonsurgical etiologies are described in the literature: local compression mechanisms secondary to tight clothing (e.g., belts and weapon holsters), obesity (13) and pregnancy. Chronic inguinal pain is also described secondary to muscular trauma or tears of the lower abdominal muscles in athletes (14,15). Finally, lumbar spinal disorders by compression mechanisms at the emerging L1 root are also described in inguinal neuropathic pain. In our study only one patient presented nonsurgical inguinal neuropathy (posttraumatic).

Existing treatments for inguinal neuralgia are quite limited and have fair results at best. Specific oral medications, including anti-inflammatory and neuropathic treatments, are faced with the difficulties of neuropathic pain management, which is a common problem in medical care (16).

Blockades of these nerves are commonly performed in pediatric surgery (7). It is established that the use of imaging guided techniques has increased the success rate of ilioinguinal and iliohypogastric nerve blocks (7,17,18). This is particularly true with RF procedures, as precise needle location immediately adjacent to the nerve is mandatory to ensure the success of the procedure. Indeed, the thermoablation radius at the tip of the needle is quite small (1-2 mm) (19,20) and therefore the conventional blind technique used in nerve blockades is insufficient (17). In our study we used CT guidance because of the experience and expertise acquired with this guidance technique in our unit. However, we think that both local nerve infiltrations and RFN could also be completed under ultrasound guidance (Fig. 6), as is the case with inguinal blockades (7,17,18). Recent interventional pain management techniques include cryoablation and RFN. Cryoablation seems promising but only a few studies exist in the literature (13,21) and no information on long-term results is available. RFN has become a specialized technique commonly used in interventional pain management but to our knowledge has never been described for this indication with im-

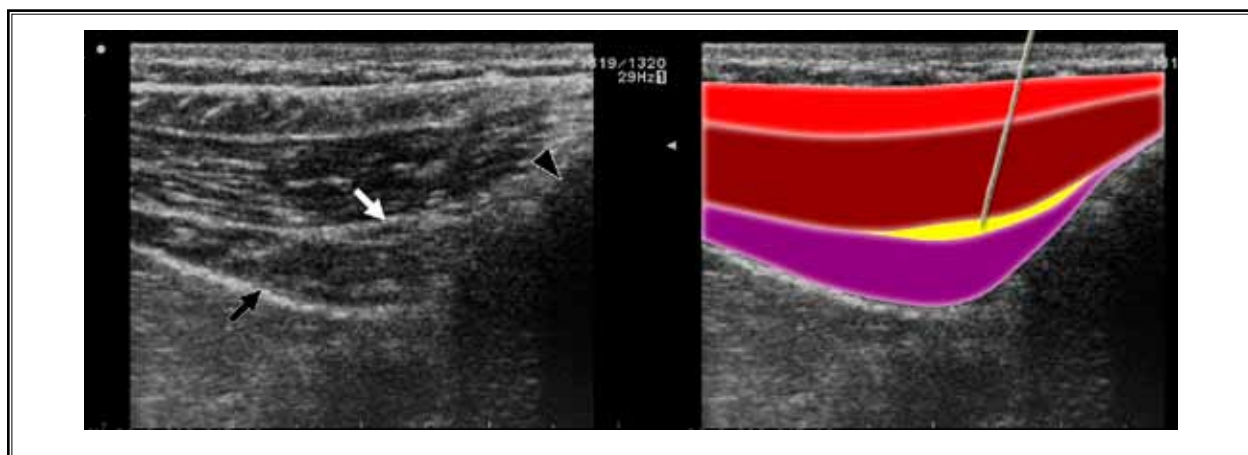


Fig. 6. Ultrasound picture taken at level of anterior superior iliac spine (black arrow head) showing the 3 layers of abdominal wall. Blue: External oblique muscle . Green: Internal oblique Muscle. Pink: Transverse abdominal muscle. Peritoneum appears as a hyperechoic ligne (black arrow). Ilioinguinal and iliohypogastric nerves (white arrow) are seen between internal oblique and transverse abdominal muscles. Hypothetic needle pathway is shown on figure to the right.

aging guidance. A case report describing RF management of inguinal neuralgia showed satisfactory results at the 3-month follow-up examination (22). Another study that included 5 cases of RFN at the L1 origin of the nerve reported satisfactory results, lasting from 4 to 5 months (23). In these reports, no imaging guidance techniques were used; follow-up was quite limited (3 to 5 months) and only a few patients were included (5 at best).

Peripheral nerve stimulation methods (TENS, spinal cord stimulation) seem to have poor long-term efficacy due to stimulation desensitization (24,25).

Finally, surgical management of inguinal neuralgia includes both division of the nerve during hernia repair and re-operative neurectomy. There seems to be no consensus on whether or not the nerve should be resected during surgical procedures, as some studies report significant pain reduction (26-28) whereas others report no improvement after intraoperative nerve division (29-31). These conflicting results are partly ex-

plained by anatomical variability which makes it difficult for surgeons to identify ilioinguinal and iliohypogastric nerves (32). On the other hand, re-operative neurectomy seem to have satisfactory results (60% to 80% success rates) (33,34), but it remains an invasive technique not easily accessible for patients since it requires referral to specific surgeons. The limitations of our study are those inherent to small study samples and retrospective studies.

CONCLUSION

Our study showed excellent technical success rates and similar important early pain intensity reduction in both groups. However, RFN showed significantly longer lasting pain relief compared to local infiltration. Local nerve infiltration may, however, still be performed prior to RFN in order to confirm an accurate inguinal neuralgia diagnosis. RFN should be considered as an alternative treatment to surgery for the management of inguinal neuralgia.

REFERENCES

- O'Dwyer PJ, Alani A, McConnachie A. Groin hernia repair: Postherniorrhaphy pain. *World J Surg* 2005; 29:1062-1065.
- Hindmarsh AC, Cheong E, Lewis MP, Rhodes M. Attendance at a pain clinic with severe chronic pain after open and laparoscopic inguinal hernia repairs. *Br J Surg* 2003; 90:1152-1154.
- Poobalan AS, Bruce J, King PM, Chambers WA, Krukowski ZH, Smith WC. Chronic pain and quality of life following open inguinal hernia repair. *Br J Surg* 2001; 88:1122-1126.
- Kalliomaki ML, Meyerson J, Gunnarsson U, Gordh T, Sandblom G. Long-term pain after inguinal hernia repair in a population-based cohort; risk factors and interference with daily activities. *Eur J Pain* 2008; 12:214-225.
- Aasvang E, Kehlet H. Chronic postoperative pain: The case of inguinal herniorrhaphy. *Br J Anaesth* 2005; 95:69-76.
- Bohrer JC, Walters MD, Park A, Polston D, Barber MD. Pelvic nerve injury following gynecologic surgery: A prospective cohort study. *Am J Obstet Gynecol* 2009; 201: 531 e1-7.
- van Schoor AN, Boon JM, Bosenberg AT, Abrahams PH, Meiring JH. Anatomical considerations of the pediatric ilioinguinal/iliohypogastric nerve block. *Paediatr Anaesth* 2005; 15:371-377.
- Palumbo P, Minicucci A, Nasti AG, Simonelli I, Vietri F, Angelici AM. Treatment for persistent chronic neuralgia after inguinal hernioplasty. *Hernia* 2007; 11:527-531.
- Collins SL, Moore RA, McQuay HJ. The visual analogue pain intensity scale: What is moderate pain in millimetres? *Pain* 1997; 72:95-97.
- al-dabbagh AK. Anatomical variations of the inguinal nerves and risks of injury in 110 hernia repairs. *Surg Radiol Anat* 2002; 24:102-107.
- Rab M, Ebmer J, Dellon AL. Anatomic variability of the ilioinguinal and genitofemoral nerve: implications for the treatment of groin pain. *Plast Reconstr Surg* 2001; 108:1618-1623.
- Whiteside JL, Barber MD, Walters MD, Falcone T. Anatomy of ilioinguinal and iliohypogastric nerves in relation to trochanter placement and low transverse incisions. *Am J Obstet Gynecol* 2003; 189:1574-1578.
- Trescot AM. Cryoanalgesia in interventional pain management. *Pain Physician* 2003; 6:345-360.
- Jansen JA, Mens JM, Backx FJ, Kolfshoten N, Stam HJ. Treatment of long-standing groin pain in athletes: A systematic review. *Scand J Med Sci Sports* 2008; 18:263-274.
- Brown RA, Mascia A, Kinnear DG, Lacroix V, Feldman L, Mulder DS. An 18-year review of sports groin injuries in the elite hockey player: Clinical presentation, new diagnostic imaging, treatment, and results. *Clin J Sport Med* 2008; 18:221-226.
- Baron R, Binder A, Wasner G. Neuropathic pain: Diagnosis, pathophysiological mechanisms, and treatment. *Lancet Neurol* 2010; 9:807-819.
- Randhawa K, Soumian S, Kyi M, Khaira H. Sonographic assessment of the conventional 'blind' ilioinguinal block. *Can J Anaesth* 2010; 57:94-95.
- Gofeld M, Christakis M. Sonographically guided ilioinguinal nerve block. *J Ultrasound Med* 2006; 25:1571-1575.
- Bogduk N, Macintosh J, Marsland A. Technical limitations to the efficacy of radiofrequency neurotomy for spinal pain. *Neurosurgery* 1987; 20:529-535.
- Cosman ER, Rittman WJ, Nashold BS, Makachinas TT. Radiofrequency lesion generation and its effect on tissue impedance. *Appl Neurophysiol* 1988; 51:230-242.
- Campos NA, Chiles JH, Plunkett AR. Ultrasound-guided cryoablation of genitofemoral nerve for chronic inguinal pain. *Pain Physician* 2009; 12:997-1000.
- Mitra R, Zeighami A, Mackey S. Pulsed radiofrequency for the treatment of chronic ilioinguinal neuropathy. *Hernia* 2007; 11:369-371.
- Rozen D, Ahn J. Pulsed radiofrequency for the treatment of ilioinguinal neuralgia after inguinal herniorrhaphy. *Mt Sinai J Med* 2006; 73:716-718.
- Paicius RM, Bernstein CA, Lempert-Cohen C. Peripheral nerve field stimulation in chronic abdominal pain. *Pain Physician* 2006; 9:261-266.
- Alo KM, Holsheimer J. New trends in neuromodulation for the management of neuropathic pain. *Neurosurgery* 2002; 50:690-703; discussion 703-704.
- Dittrick GW, Ridl K, Kuhn JA, McCarty TM. Routine ilioinguinal nerve excision in inguinal hernia repairs. *Am J Surg* 2004; 188:736-740.
- Mui WL, Ng CS, Fung TM, Cheung FK, Wong CM, Ma TH, Bn MY, Ng EK. Prophylactic ilioinguinal neurectomy in open inguinal hernia repair: A double-blind randomized controlled trial. *Ann Surg* 2006; 244:27-33.
- Malekpour F, Mirhashemi SH, Hajinasrolah E, Salehi N, Khoshkar A, Kolahi AA. Ilioinguinal nerve excision in open mesh repair of inguinal hernia--results of a randomized clinical trial: Simple solution for a difficult problem? *Am J Surg* 2008; 195:735-740.
- Ravichandran D, Kalambe BG, Pain JA. Pilot randomized controlled study of preservation or division of ilioinguinal nerve in open mesh repair of inguinal hernia. *Br J Surg* 2000; 87:1166-1167.
- Picchio M, Palimento D, Attanasio U, Matarazzo PF, Bambini C, Caliendo A. Randomized controlled trial of preservation or elective division of ilioinguinal nerve on open inguinal hernia repair with polypropylene mesh. *Arch Surg* 2004; 139:755-758; discussion 59.
- Bartlett DC, Porter C, Kingsnorth AN. A pragmatic approach to cutaneous nerve division during open inguinal hernia repair. *Hernia* 2007; 11:243-246.
- Mandelkow H, Loeweneck H. The iliohypogastric and ilioinguinal nerves. Distribution in the abdominal wall, danger areas in surgical incisions in the inguinal and pubic regions and reflected visceral pain in their dermatomes. *Surg Radiol Anat* 1988; 10:145-149.
- Heise CP, Starling JR. Mesh inguinaldynia: A new clinical syndrome after inguinal herniorrhaphy? *J Am Coll Surg* 1998; 187:514-518.
- Vuilleumier H, Hubner M, Demartines N. Neuropathy after herniorrhaphy: Indication for surgical treatment and outcome. *World J Surg* 2009; 33:841-845.