

Observational Study

The Use of Vertebral Augmentation and External Beam Radiation Therapy in the Multimodal Management of Malignant Vertebral Compression Fractures

Ariel E. Hirsch, MD¹, Ruchira M. Jha, MD¹, Albert J. Yoo, MD¹, Akriti Saxena, BS²,
Al Ozonoff, PhD³, Marion J. Growney, MD¹, and Joshua A. Hirsch, MD¹

From: ¹Massachusetts General Hospital, Boston, MA; ²Tufts University School of Medicine, Boston, MA; ³Children's Hospital, Boston, MA

Dr. Ariel Hirsch is with the Department of Radiation Oncology, Boston University Medical Center, Massachusetts General Hospital, Boston, MA. Dr. Jha is with the Department of Neurology, Massachusetts General Hospital, Boston, MA. Dr. Yoo, Dr. Growney and Dr. Joshua Hirsch are with the Department of Radiology, Division of Interventional Neuroradiology, Massachusetts General Hospital, Boston, MA. Dr. Saxena is with Tufts University School of Medicine, Boston, MA. Dr. Ozonoff is with the Clinical Research Program at Children's Hospital, Boston, MA.

Address correspondence:
Ariel E. Hirsch, MD
Department of Radiation Oncology,
Boston University Medical Center
Massachusetts General Hospital
830 Harrison Avenue
Moakley Building –LL
Boston, MA 02118
E-mail: Ariel.hirsch@bmc.org

Disclaimer: There was no external funding in the preparation of this manuscript.
Conflict of interest: Joshua Hirsch is a consultant and minor shareholder for Cardinal Healthcare and Medtronic.

Manuscript received: 09/16/2010
Revised manuscript received: 05/12/2011
Accepted for publication: 05/18/2011

Free full manuscript:
www.painphysicianjournal.com

Background: Vertebral augmentation (VA) techniques such as vertebroplasty and kyphoplasty are increasingly performed minimally invasive procedures for osteoporotic or malignant compression fractures (MCFs) and involve injection of polymethylmethacrylate (PMMA) cement directly into a compressed vertebral body.

Objective: This article will evaluate the efficacy of VA in relieving fracture-related pain. We also intend to identify procedural and clinical variables that could potentially influence outcomes in this population. In the subset of patients with cancer who received both external beam radiation therapy (EBRT) and VA, we will assess the impact of the treatment sequence on pain outcomes.

Study Design: We performed a retrospective analysis of 201 cases of patients with cancer and MCFs who underwent one or more vertebral augmentation procedures at our institution between 2003 and 2009. The majority of cancers represented were multiple myeloma, metastatic lung cancer, and metastatic breast cancer. The primary outcome measure was pain relief, as measured by the Visual Analog Scale and a 4-point pain scale.

Setting: We present an institutional experience at an academic medical center of 201 cases of MCFs.

Methods: We compiled an institutional database of vertebroplasty and kyphoplasty cases using paper and electronic medical records. Our data collection methodology has been previously reported and includes variables such as procedure dates, gender, age, type of malignancy, fracture etiology, history of cancer treatment, type of procedure performed, vertebral level treated, the number of levels treated per procedure, complications, and follow-up information on pain response. The updated dataset incorporates new variables including information on pain medications and standardized questionnaires such as the Visual Analog Scale (VAS) for pain and the Roland Morris Disability Questionnaire (RMDQ).

Results: In the 201 cases of MCFs, a total of 316 vertebral levels were treated with either vertebroplasty or kyphoplasty. Follow-up data on pain relief was available for 190 out of 201 cases (95%). Among this subgroup, 168 cases (88%) with MCFs responded. Thirty-nine percent (39%) of the time patients experienced complete pain resolution. In only 4% of cases did patients report worsening of their fracture-related pain post-procedure. There was no difference in pain outcomes with regard to sequencing of EBRT and VA.

Limitations: One of the limitations of our analysis is that it did not evaluate the effect of pain improvement or resolution before and after EBRT alone and on activities of daily living in the majority of patients. However, one of the main goals of this analysis is to address previous limitations. We attempt to standardize outcome measures by using the Visual Analog Scale (VAS) for pain and the Roland Morris Disability Questionnaire (RMDQ).

Conclusion: A multimodality approach for the management of MCFs includes VA procedures. The majority of patients with MCFs have excellent palliation with this approach. In patients who receive both EBRT and VA, the sequence in which they are given does not affect pain improvement outcomes.

Key words: malignant compression fractures, palliation, vertebroplasty, radiation therapy

Pain Physician 2011; 14:447-458

The skeletal system follows the lung and liver as the most common site of cancer metastases (1,2). Within the skeletal system, the vertebral column is the most common site for bone metastases, affecting up to 70% of patients with cancer, followed by the pelvis, femur/hip and skull (2). Regarding specific locations in the spinal column, 60-80% of metastatic vertebral lesions involve the thoracic spine, 15-30% involve the lumbar spine, and less than 10% affect the cervical spine (1). Bony metastases gradually weaken the structural integrity of the vertebral bone through osteoblastic and/or, more commonly, osteoclastic activity, and can eventually result in collapse of the vertebral body, leading to a vertebral compression fracture (VCF) (3,4). Osteolytic lesions and the resulting bone degradation have a higher risk of VCFs than osteoblastic lesions (5,6). VCFs occur in up to 90% of patients with multiple myeloma (7), and in up to 30% of patients with bone metastases from other cancers, most frequently breast, lung, and thyroid cancer (8,9).

Symptomatic VCFs usually result in focal or laterally radiating back pain which can be debilitating and result in decreased physical activity and increased morbidity (10). Conservative treatment of malignant VCFs includes bed rest, orthotic braces, nonsteroidal anti-inflammatory drugs (NSAIDs), and opioid medications. The challenge is that such options can result in further immobilization which may cause accelerated bone resorption and an increased risk of a new fracture, pneumonia, deep venous thrombosis, and decubitus ulcers, and may not adequately address chronic pain (11-13). It is thought that injecting polymethylmethacrylate (PMMA) into a vertebral body causes necrosis and thermal damage to the tumor through a hardening process of the bony cavity. This stabilizes the fracture and provides analgesia simultaneously. Percutaneous vertebral augmentation is increasingly used as aggressive management for pain relief in addition to chemotherapy (depending on the primary tumor histology), surgery, and external beam radiation therapy (EBRT) (8,11,14-16).

Vertebral augmentation (VA) is a generic term that is used to describe a number of minimally invasive spine treatments, including vertebroplasty and kyphoplasty that deliver PMMA bone cement into the fractured vertebral body via percutaneous needles (17-22). There are a number of studies that have shown that vertebroplasty and kyphoplasty are rapid, safe, durable and effective palliative treatments for metastatic VCFs and interest in these procedures has been increasing

(3,15,16,21-37).

There are few absolute contraindications to vertebral augmentation. Several studies report pain relief of greater than 75% in patients with metastases (16,33,38,39). Relative contraindications include epidural extension of bone metastases, cord impingement, and osteoblastic metastasis; however, percutaneous vertebroplasty performed by an experienced physician has been shown to be safe and may benefit the patient even if the pain relief is less than that seen in a simple osteoporotic fracture (38). Radiotherapy can provide pain relief in 75% of patients but can take up to 2 weeks before pain relief is experienced depending on the radiosensitivity of the tumor (40).

Other more recent randomized controlled trials question the efficacy of vertebral augmentation in alleviating noncancerous fracture-related pain and disability (41,42). In this analysis, we present an institutional experience at an academic medical center of 201 cases of malignant compression fractures (MCFs), i.e., VCFs with documented metastatic disease in the vertebral bodies, to evaluate the efficacy of vertebroplasty and kyphoplasty in relieving pain from these fractures. Jha et al (35,43) have previously discussed successful pain relief in both malignant and osteoporotic compression fractures in a smaller subset of patients belonging to this database. We would like to further our analysis by looking at the data more critically, i.e., assessing pain resolution in the context of opioid use and using a more standardized approach for the primary outcomes: pain (Visual Analog Scale) and disability (Roland Morris Disability Questionnaire). In the subset of patients with cancer who received both EBRT and VA, we determined the effect of the treatment sequence on pain outcomes.

METHODS

Data Collection

We compiled an institutional database of 201 vertebroplasty and kyphoplasty cases performed between May 2003 and June 2009. Our data collection methodology and analysis of initial cases has been previously reported. We identified additional cases with MCFs yielding a total of 201 cases. During these procedures, 316 vertebral levels were treated with vertebral augmentation. In 57 cases, patients also received a course of palliative EBRT to the spine.

We collected data on procedure dates, gender, age, type of malignancy, fracture etiology, history of cancer treatment (including time and dose of radiation

therapy wherever applicable), pain medications, type of procedure performed (vertebroplasty, kyphoplasty), vertebral level treated (thoracic, lumbar), the number of levels treated per procedure, procedural notes (complications), and follow up information (dates and outcomes) including the Visual Analog Scale (VAS) for pain and the Roland Morris Disability Questionnaire (RMDQ).

All data were obtained through paper and electronic medical records. The retrospective study was institutional review board-approved, and data collection and analyses were conducted in accordance with Health Insurance Portability and Accountability Act guidelines.

Outcome measures

The primary outcome measures were pain relief experienced after the VA procedure, disability improvement, and reduction in pain medications. This information was collected from our institutional electronic medical records and patient charts for VAS and RMDQ scores. The time of patient follow-up in relation to the procedure was also noted.

The preferred measure of documenting pain was the standard VAS pain scale. If this information was unavailable, as was common in procedures performed before 2007, 2 additional outcome measures were used as described and implemented by Jha et al (35). As previously reported, the first was a dichotomized system that categorized patients as “responders” (those who experienced improved or resolved pain after the procedure) versus “non-responders” (those who had no change or worsening of pain after the procedure). The second outcome measure built upon the dichotomized system and further stratified patients on a 4-level pain scale. This pain scale categorized patients by those who experienced resolution of VCF-related pain (level 1), improvement in fracture-related pain (level 2), no change in pain (level 3), and worsening of pain (level 4) after the procedure. Disability improvement was also quantified using RMDQ on a scale of 0-24 points when available.

A pain medication score for each case was calculated pre- and post-procedure according to the following 5-point scale: 0 = no medications, 1 = NSAIDs and over-the-counter drugs, 2 = short-acting opioids, 3 = long-acting opioids, 4 = pump, patch, or IV medication.

Statistical Analyses

Variables analyzed included gender (male or female), age, age category by decade, type of procedure performed per case (vertebroplasty, kyphoplasty, both), vertebral region treated per case (thoracic, lumbar,

both), number of vertebral levels treated per case, treatment with EBRT, sequence of EBRT in relation to the VA procedure, pain relief, disability improvement, and pain medications. Descriptive statistics included mean, median, standard deviation, and range for continuous and ordinal variables, or frequencies and percentages for nominal variables.

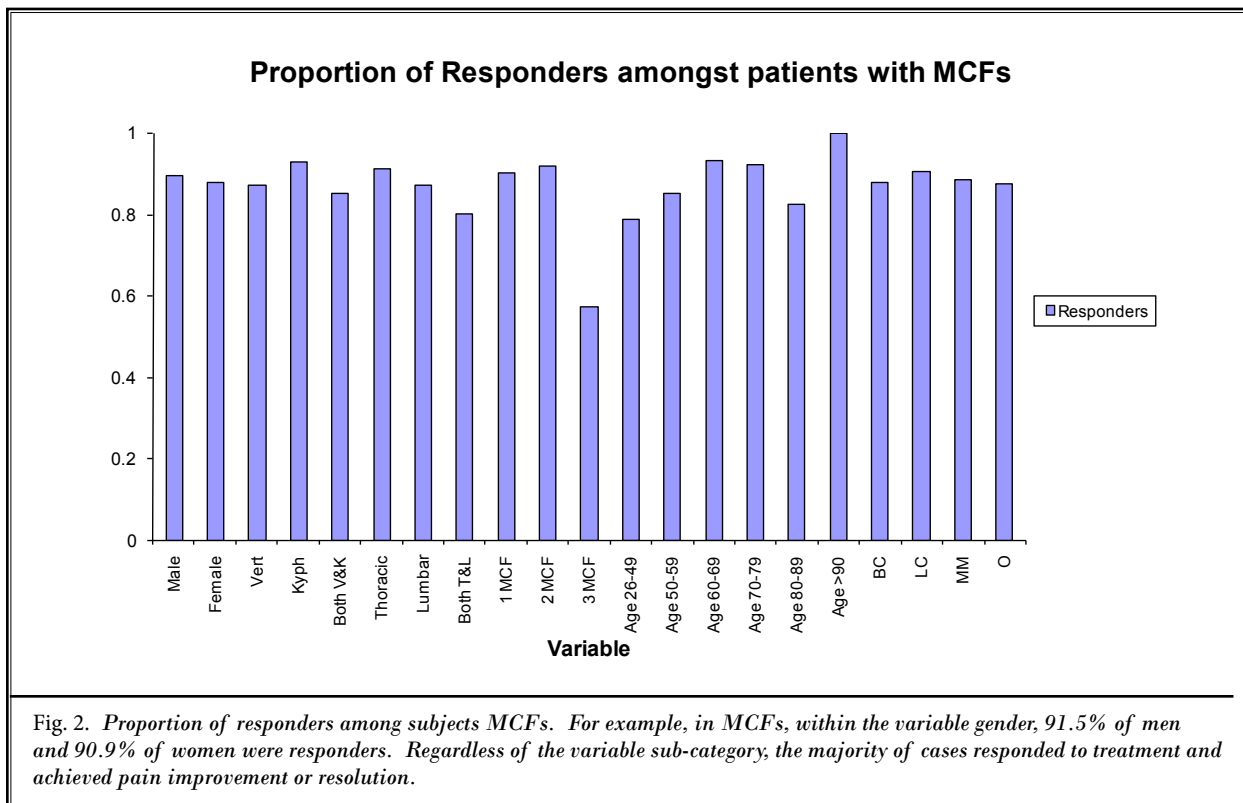
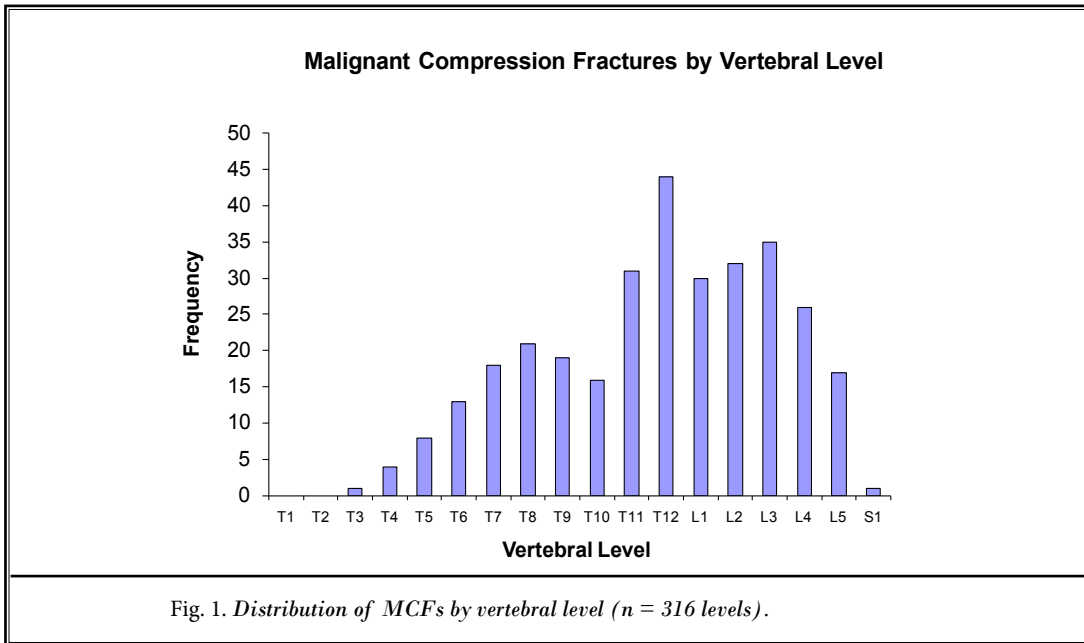
Logistic regression models were used to estimate association of outcome with each variable of interest, using positive response as the binary outcome. A multiple logistic regression was selected using a forward stepwise selection procedure with entry criterion $P < 0.10$. Independent sample t-tests and the rank sum test were used to compare means (respectively medians) of continuous or ordinal outcomes between groups. For data that were paired via pre- versus post-procedure, the signed rank test was used to compare median change in pain relief (VAS) and disability (RMDQ); similarly McNemar's test was used to compare change in pain medication use. All hypothesis tests were 2-tailed with significance level 0.05, and analyses were conducted using SAS v9.1 (SAS Institute, Cary, NC) and MedCalc v11.0 (MedCalc Software, Mariakerke, Belgium).

RESULTS

Two hundred one cases of MCFs comprising a total of 316 vertebral levels were treated with either vertebroplasty or kyphoplasty. As observed previously, the majority of compression fractures occurred at the thoracolumbar junction, with T11-L3 accounting for 54.4% of all treated levels (Fig. 1). The distribution of compression fractures by type of cancer show that 68% of documented MCFs had multiple myeloma, breast cancer, or lung cancer. This particular variable in part reflects somewhat unique institutional referral patterns. Unlike osteoporotic compression fractures, in patients with cancer there was a fairly even distribution of MCFs between male and female patients (Fig. 2). None of the patients required re-treatment of the same vertebral level. There were no procedural complications in this cohort of patients.

Eighty-eight percent (88%) of MCFs were responders. The distribution of responders by subgroup is shown in Fig 2. Thirty-nine percent (39%) of cases with MCFs experienced complete pain resolution. In only 4% of cases did patients report worsening of their fracture-related pain post-procedure. Follow-up time ranged from one week to more than one year, with most patients following up within 6 months.

Eighteen cases had confirmed VAS scores both



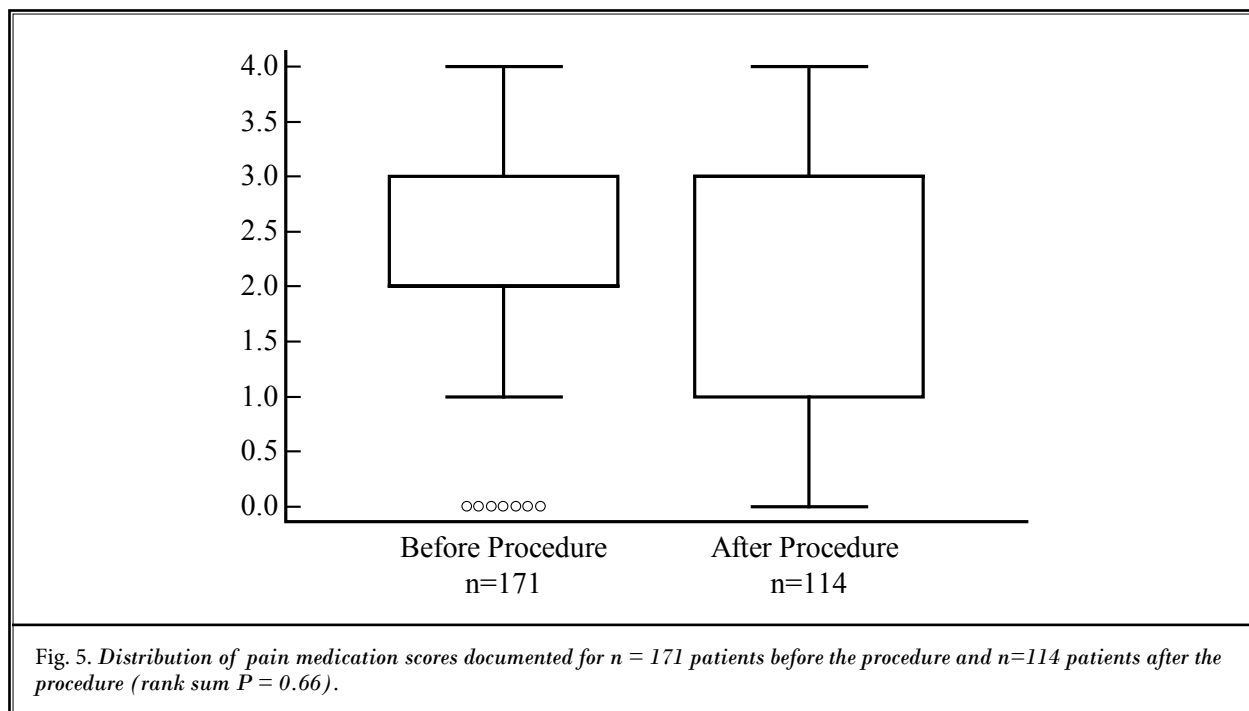


Fig. 5. Distribution of pain medication scores documented for $n = 171$ patients before the procedure and $n=114$ patients after the procedure (rank sum $P = 0.66$).

Pain medications were documented for 171 (85%) cases before the procedure and 114 cases (57%) post procedure. (Fig. 5) There was no significant change in score (Mann-Whitney $P = 0.66$). However, for the subgroup of cases with confirmed medications both pre and post-procedure, there was a trend towards non-opioid medications (McNemar $P = 0.07$) (Fig. 6).

Fifty-seven cases with MCFs were also treated with EBRT, 49 of 57 (86%) received EBRT before VA and 8 of 57 (14%) received EBRT after VA. (Fig 7). Follow-up data were available for 52 of 57 cases (91%) and the difference in distribution of pain outcomes between groups defined by timing of radiation therapy relative to vertebral augmentation (Fig 8) was not statistically significant (Fisher $P = 0.16$). In 4 cases, patients who received EBRT before VA had no change in pain symptoms, and another 2 patients reported that the pain was worse.

Responders versus non-responders

In patients with MCFs, each 10-year increase in age resulted in higher odds of positive response (odds ratio [OR] 1.46, $P = 0.10$). No other variables had a statistically significant effect on the odds of positive response (Fig 2).

Pain improvement versus pain resolution

Eighty-eight percent of the time, patients with

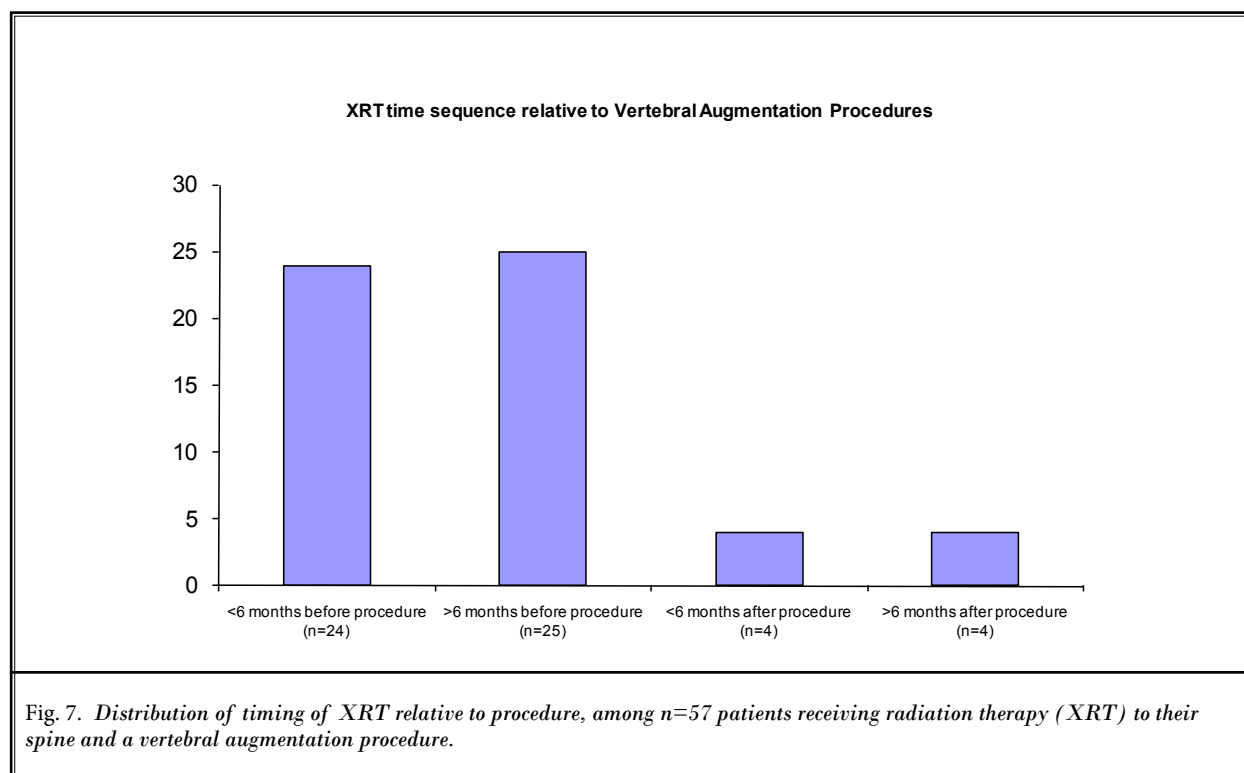
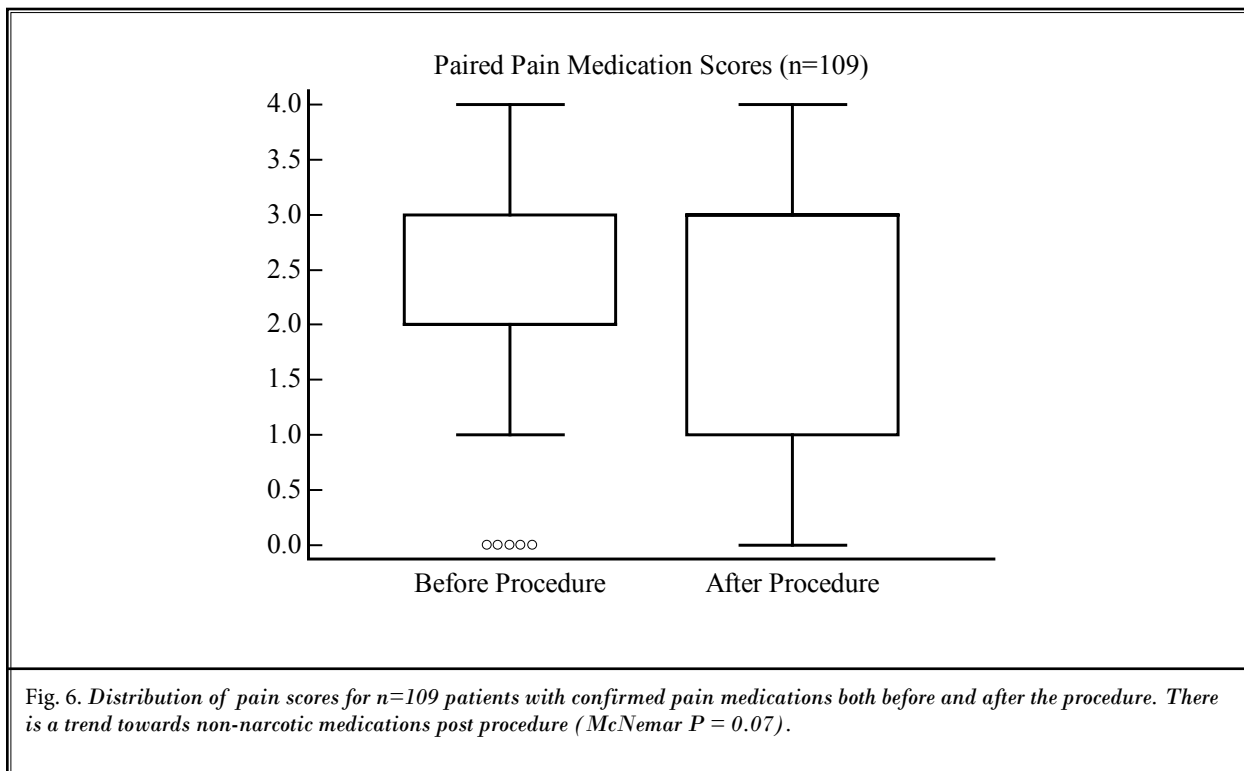
MCFs were responders (Fig. 2) and we further categorized this group into complete pain resolution (39%) versus those who reported improvement in pain post-procedure, but still had intermittent residual discomfort (61%).

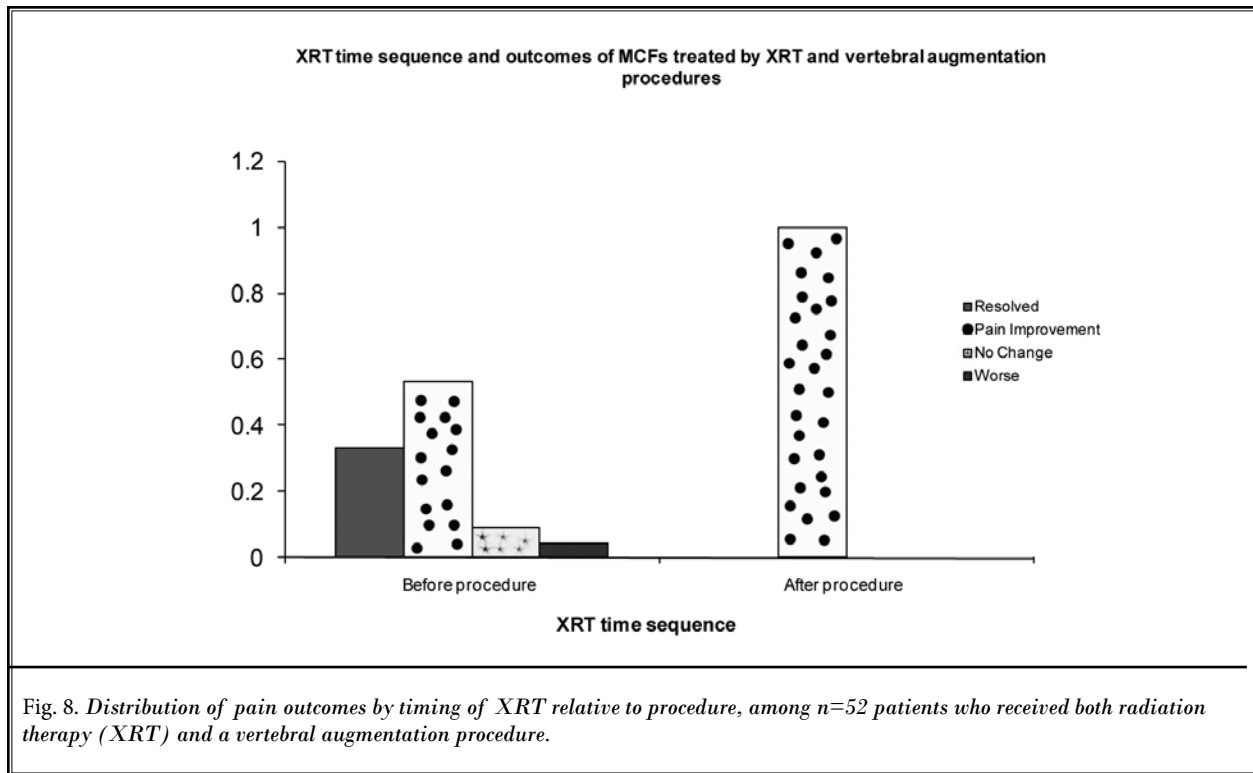
In patients with MCFs, the odds of pain resolution was higher in patients with lung cancer (OR 3.33, $P = 0.06$) and multiple myeloma (OR 2.51, $P = 0.12$).

DISCUSSION

Compression fractures are a major cause of malignant bone pain and decreased quality of life. Symptoms may eventually progress to include neurologic dysfunction including motor weakness, sensory loss, or loss of sphincter control (8). Given the debilitating nature of the pain and morbidity caused by MCFs, coupled with an improvement in survival of patients with cancer and a demographic shift toward a more elderly population (44,45), it is becoming increasingly important to address issues of pain control, neurological compromise, and functional support in the management of these patients.

This retrospective analysis evaluated pain outcomes in 201 cancer cases treated with vertebroplasty and/or kyphoplasty for MCFs. After having increased the number of cases from our previous dataset, reported by Jha





et al (43), this is now one of the largest reported series assessing these outcomes in MCFs. The vast majority of patients with MCFs were responders to VA treatment and experienced either improvement or resolution of their pain symptoms.

There were certain patient characteristics that influenced pain outcomes in a statistically significant manner. Jha et al (35) had reported that age was a statistically significant predictor of response to treatment where older patients had an increasing likelihood to respond to treatment. However, our analysis, both univariate and multivariate, suggests only a trend towards positive response among older patients but no statistically significant result ($P = 0.10$). The type of cancer did not significantly influence response to treatment. Within each cancer diagnosis, greater than 87% of patients reported a positive response to treatment. Cancer type was associated with pain improvement versus resolution (Table 4), although this association was not significant. Patients were less likely to experience complete pain resolution with lung cancer ($P = 0.06$) or multiple myeloma ($P = 0.12$). We hypothesize that patients with multiple myeloma or lung cancer tend to be in poorer health with a higher occurrence of comorbidities. These patients also have

an overall poorer prognosis compared to patients with some other cancers analyzed in this study, e.g., breast cancer (46-48). We studied pain relief in patients who received successive EBRT; however, the differential use of bisphosphonates on outcomes of vertebral augmentation in different types of cancers has not been examined and would be an interesting avenue for future research.

MCFs have been treated with a variety of palliative techniques, including chemotherapy and EBRT, depending on the histology and volume of the disease (10,49). Surgery, on the other hand, is commonly reserved for patients with impending or actual neurologic dysfunction. While these treatments might be effective, they are associated with limitations, including longer response time (2 weeks or longer), weakening of underlying bone after shrinkage of the space-occupying lesion, and variable ability to address the underlying mechanical abnormality of the compressed bone. Furthermore, radiotherapy is not sustainable in the long run as radiation dose is limited by spinal tolerance. In contrast, VA works quickly by providing structural support via the placement of cement, resulting in nearly immediate pain relief. This minimally invasive approach also reduces mor-

bility by minimizing damage to normal tissue and by speeding up recovery times compared to conventional surgeries. In the event that VA is performed prior to EBRT, it is thought that the cement (PMMA) has a cytotoxic and thermal effect on tumor cells. The clinical benefit of VA in patients with cancer has led to early reports of extra-vertebral approaches with promising results seen in the acetabulum and other extra-vertebral sites (50,51).

Palliation of MCFs requires mechanical stabilization of the spine in addition to treatment of the tumor within the vertebral body (44), both of which can be achieved by a combination treatment of EBRT with VA (49). A recent paper by Gerszten et al (52) suggests that a combination of transpedicular cavitation, cement augmentation, and focal radiosurgery provided long-term pain improvement and radiographic tumor control. Other randomized controlled trials (RCTs) have also demonstrated that surgery plus postoperative radiotherapy is more effective in treating spinal cord compression as a result of metastatic cancer than radiotherapy alone, enabling more patients to walk and for a longer period of time (53). Treating these patients with EBRT first allows for tumor shrinkage and may enable these patients to become candidates for VA if surgical decompression is initially contraindicated. Tumor shrinkage prior to VA also reduces the risk of tumor dissemination during pressurized cement injection. In our dataset, the timing of EBRT, either before or after VA, did not significantly impact outcomes of these procedures.

Alternative radiation modalities in combination with VA including spinal radiosurgery, intracavitary samarium, radioisotopes, or plasma-radiation radiofrequency ablation have been reported with promising results (54-57).

While vertebral augmentation is the standard treatment for compression fractures, recent multi-institutional RCTs demonstrated equivalence of vertebroplasty with a sham procedure in terms of pain and pain-related disability (41,42). However, neither Buchbinder et al (42) nor data from the INVEST trial (41) included patients with MCF and as discussed above, the treatment goal for MCFs is quite different from that of osteoporotic compression fractures. The cohort study by Jha et al (43) clearly delineates the importance and effectiveness of VAs as part of a multidisciplinary approach to treating MCFs.

The major limitation of our study is that it is a retrospective analysis of patients with cancer undergoing

vertebral augmentation procedures. It is well known that it is not only impossible, but unethical to perform a randomized, double-blind placebo-controlled trial of vertebral augmentation in malignant vertebral compression fractures. Thus, most of the data is derived from observational studies for such therapy and conditions. Thus, observational studies are of importance in all conditions except when there is overwhelming data available to randomized trials and systematic reviews of randomized trials (58-61). Even then, modern medicine while paying only lip service to observational studies, continues to describe the importance of observational studies and their legitimate role in evidence-based medicine (62-71). Thus, we believe that the study is appropriate in the format presented to provide evidence in managing malignant vertebral compression fractures.

One of the other limitations of our analysis is that it did not evaluate the effect of pain improvement or resolution pre- and post-EBRT alone. It is difficult to delineate whether patients benefited from EBRT, vertebral augmentation, or both. Collecting pain scores at 3 separate time points (before EBRT, after EBRT, and after subsequent vertebral augmentation) would help us document a sequential improvement in pain relief.

Another main goal of this paper was to address previous limitations. We attempted to be as comprehensive as possible in standardizing outcome measures by relying little on the tailored 4-point pain scale and more on VAS scales and RMDQ questionnaires. If the VAS and RMDQ scores were not documented online, care was taken to follow up with paper charts. Unfortunately, scores pre- and post-augmentation were available for only 18 patients, but in this subset pain and disability improvement was significant (signed rank $P = 0.0001$ and $P = 0.02$ respectively). In addition, we collected data on each patient's pain medications as this can significantly alter their perception of pain. There was a trend toward non-opioid medications, further supporting the palliative goal of vertebral augmentation procedures.

CONCLUSION

This analysis corroborates that VA provides effective pain relief and disability improvement for symptomatic MCFs in the majority of patients. Based on these results, as well as the safety of this procedure and faster recovery times compared to conventional surgeries, we believe that VA is an integral part of treatment offered to patients with cancer who have MCFs. It not

only helps to alleviate pain, but also addresses the underlying cause and stabilizes the fracture. Longer-term palliation is best achieved using a multimodal approach of augmentation and radiotherapy. Further large prospective studies and randomized controlled trials are warranted to support the safety and efficacy of these procedures in relieving pain and improving the quality

of life in patients with cancer who have documented MCFs.

ACKNOWLEDGMENTS

We would like to thank the editorial board of *Pain Physician* for review and constructive criticism in improving the manuscript.

REFERENCES

- Coleman RE. Metastatic bone disease: Clinical features, pathophysiology and treatment strategies. *Cancer Treat Rev* 2001; 27:165-176.
- Aaron AD. The management of cancer metastatic to bone. *JAMA* 1994; 272:1206-1209.
- Coumans JV, Reinhardt MK, Lieberman IH. Kyphoplasty for vertebral compression fractures: 1-year clinical outcomes from a prospective study. *J Neurosurg* 2003; 99:44-50.
- Lipton A. Future treatment of bone metastases. *Clin Cancer Res* 2006; 12:6305-6308.
- Siemionow K, Lieberman IH. Vertebral augmentation in osteoporosis and bone metastasis. *Curr Opin Support Palliat Care* 2007; 1:323-327.
- Ahn H, Mousavi P, Roth S, Reidy D, Finkelstein J, Whyne C. Stability of the metastatic spine pre and post vertebroplasty. *J Spinal Disord Tech* 2006; 19:178-182.
- Roodman GD. Skeletal imaging and management of bone disease. *Hematology Am Soc Hematol Educ Program* 2008; 2008:313-319.
- Bartels RH, van der Linden YM, van der Graaf WT. Spinal extradural metastasis: Review of current treatment options. *CA Cancer J Clin* 2008; 58:245-259.
- Paterson AH, Ernst DS, Powles TJ, Ashley S, McCloskey EV, Kanis JA. Treatment of skeletal disease in breast cancer with clodronate. *Bone* 1991; 12:S25-S30.
- Mercadante S. Malignant bone pain: Pathophysiology and treatment. *Pain* 1997; 69:1-18.
- Layton KF, Thielen KR, Koch CA, Lutmer PH, Lane JJ, Wald JT, Kallmes DF. Vertebroplasty, first 1000 levels of a single center: Evaluation of the outcomes and complications. *AJNR Am J Neuroradiol* 2007; 28:683-689.
- Lindsay R, Silverman SL, Cooper C, Hanley DA, Barton I, Broy SB, Licata A, Benhamou L, Geusens P, Flowers K, Stracke H, Seeman E. Risk of new vertebral fracture in the year following a fracture. *JAMA* 2001; 285:320-323.
- Papaioannou A, Watts NB, Kendler DL, Yuen CK, Adachi JD, Ferko N. Diagnosis and management of vertebral fractures in elderly adults. *Am J Med* 2002; 113:220-228.
- Jensen ME, McGraw JK, Cardella JF, Hirsch JA. Position statement on percutaneous vertebral augmentation: A consensus statement developed by the American Society of Interventional and Therapeutic Neuroradiology, Society of Interventional Radiology, American Association of Neurological Surgeons/Congress of Neurological Surgeons, and American Society of Spine Radiology. *AJNR Am J Neuroradiol* 2007; 28:1439-1443.
- Pizzoli AL, Brivio LR, Caudana R, Vittorini E. Percutaneous CT-guided vertebroplasty in the management of osteoporotic fractures and dorsolumbar metastases. *Orthop Clin North Am* 2009; 40:449-458, vii.
- Georgy BA. Bone cement deposition patterns with plasma-mediated radiofrequency ablation and cement augmentation for advanced metastatic spine lesions. *AJNR Am J Neuroradiol* 2009; 30:1197-1202.
- Powell MF, DiNobile D, Reddy AS. C-arm fluoroscopic cone beam ct for guidance of minimally invasive spine interventions. *Pain Physician* 2010; 13:51-59.
- Jones JO, Bruel BM, VattamSR. Management of painful vertebral hemangiomas with kyphoplasty: A report of two cases and a literature review. *Pain Physician* 2009; 12:E297-E303.
- Betts A. Vertebroplasty of the first sacral vertebra. *Pain Physician* 2009; 12:651-657.
- Frey ME. Redo kyphoplasty with vertebroplasty technique: A case report and review of the literature. *Pain Physician* 2009; 12:645-649.
- Masala S, Lunardi P, Fiori R, Liccardo G, Massari F, Ursone A, Simonetti G. Vertebroplasty and kyphoplasty in the treatment of malignant vertebral fractures. *J Chemother* 2004; 16:30-33.
- Pitton MB, Herber S, Koch U, Oberholzer K, Drees P, Duber C. CT-guided vertebroplasty: Analysis of technical results, extraosseous cement leakages, and complications in 500 procedures. *Eur Radiol* 2008; 18:2568-2578.
- Alvarez L, Perez-Higueras A, Quinones D, Calvo E, Rossi RE. Vertebroplasty in the treatment of vertebral tumors: Postprocedural outcome and quality of life. *Eur Spine J* 2003; 12:356-360.
- Barr JD, Barr MS, Lemley TJ, McCann RM. Percutaneous vertebroplasty for pain relief and spinal stabilization. *Spine* 2000; 25:923-928.
- Stallmeyer MJ, Zoarski GH, Obuchowski AM. Optimizing patient selection in percutaneous vertebroplasty. *J Vasc Interv Radiol* 2003; 14:683-696.
- Cohen JE, Lylyk P, Ceratto R, Kaplan L, Umanskyt F, Gomori JM. Percutaneous vertebroplasty: Technique and results in 192 procedures. *Neurol Res* 2004; 26:41-49.
- Cotten A, Dewatre F, Cortet B, Assaker R, Leblond D, Duquesnoy B, Chastanet P, Clarisse J. Percutaneous vertebroplasty for osteolytic metastases and myeloma: Effects of the percentage of lesion filling and the leakage of methyl methacrylate at clinical follow-up. *Radiology* 1996; 200:525-530.
- Diamond TH, Hartwell T, Clarke W, Manoharan A. Percutaneous vertebroplasty for acute vertebral body fracture and deformity in multiple myeloma: A short report. *Br J Haematol* 2004;

- 124:485-487.
29. Lieberman IH, Dudeney S, Reinhardt MK, Bell G. Initial outcome and efficacy of "kyphoplasty" in the treatment of painful osteoporotic vertebral compression fractures. *Spine* 2001; 26:1631-1638.
 30. Fourney DR, Schomer DF, Nader R, Chlan-Fourney J, Suki D, Ahrar K, Rhines LD, Gokaslan ZL. Percutaneous vertebroplasty and kyphoplasty for painful vertebral body fractures in cancer patients. *J Neurosurg* 2003; 98:21-30.
 31. Martin JB, Wetzel SG, Seium Y, Dietrich PY, Somon T, Gailloud P, Payer M, Kelekis A, Ruefenacht DA. Percutaneous vertebroplasty in metastatic disease: transpedicular access and treatment of lysed pedicles--initial experience. *Radiology* 2003; 229:593-597.
 32. Shimony JS, Gilula LA, Zeller AJ, Brown DB. Percutaneous vertebroplasty for malignant compression fractures with epidural involvement. *Radiology* 2004; 232:846-853.
 33. Weill A, Chiras J, Simon JM, Rose M, Sola-Martinez T, Enkaoua E. Spinal metastases: Indications for and results of percutaneous injection of acrylic surgical cement. *Radiology* 1996; 199:241-247.
 34. Anselmetti GC, Corgnier A, Debernardi F, Regge D. Treatment of painful compression vertebral fractures with vertebroplasty: Results and complications. *Radiol Med* 2005; 110:262-272.
 35. Jha RM, Yoo AJ, Hirsch AE, Growney M, Hirsch JA. Predictors of successful palliation of compression fractures with vertebral augmentation: Single-center experience of 525 cases. *J Vasc Interv Radiol* 2009; 20:760-768.
 36. Lee B, Franklin I, Lewis JS, Coombes RC, Leonard R, Gishen P, Stebbing J. The efficacy of percutaneous vertebroplasty for vertebral metastases associated with solid malignancies. *Eur J Cancer* 2009; 45:1597-1602.
 37. Pflugmacher R, Taylor R, Agarwal A, Melcher I, Disch A, Haas NP, Klostertmann C. Balloon kyphoplasty in the treatment of metastatic disease of the spine: A 2-year prospective evaluation. *Eur Spine J* 2008; 17:1042-1048.
 38. Guglielmi G, Andreula C, Muto M, Gilula LA. Percutaneous vertebroplasty: Indications, contraindications, technique, and complications. *Acta Radiol* 2005; 46:256-268.
 39. Evans AJ, Jensen ME, Kip KE, DeNardo AJ, Lawler GJ, Negin GA, Remley KB, Boutin SM, Dunnagan SA. Vertebral compression fractures: Pain reduction and improvement in functional mobility after percutaneous polymethylmethacrylate vertebroplasty retrospective report of 245 cases. *Radiology* 2003; 226:366-372.
 40. Lievens Y, Kesteloot K, Rijnders A, Kutcher G, Van den Bogaert W. Differences in palliative radiotherapy for bone metastases within Western European countries. *Radiother Oncol* 2000; 56:297-303.
 41. Kallmes DF, Comstock BA, Heagerty PJ, Turner JA, Wilson DJ, Diamond TH, Edwards R, Gray LA, Stout L, Owen S, Hollingsworth W, Ghdoke B, Annesley-Williams DJ, Ralston SH, Jarvik JG. A randomized trial of vertebroplasty for osteoporotic spinal fractures. *N Engl J Med* 2009; 361:569-579.
 42. Buchbinder R, Osborne RH, Ebeling PR, Wark JD, Mitchell P, Wriedt C, Graves S, Staples MP, Murphy B. A randomized trial of vertebroplasty for painful osteoporotic vertebral fractures. *N Engl J Med* 2009; 361:557-568.
 43. Jha RM, Hirsch AE, Yoo AJ, Ozonoff A, Growney M, Hirsch JA. Palliation of compression fractures in cancer patients by vertebral augmentation: A retrospective analysis. *J NeuroIntervent Surg* 2010; 2:221-228.
 44. Giordano SH, Buzdar AU, Smith TL, Kau SW, Yang Y, Hortobagyi GN. Is breast cancer survival improving? *Cancer* 2004; 100:44-52.
 45. Sciubba DM, Gokaslan ZL. Diagnosis and management of metastatic spine disease. *Surg Oncol* 2006; 15:141-151.
 46. Bjorkstrand B, Gahrton G. High-dose treatment with autologous stem cell transplantation in multiple myeloma: Past, present, and future. *Semin Hematol* 2007; 44:227-233.
 47. Fischer B, Arcaro A. Current status of clinical trials for small cell lung cancer. *Rev Recent Clin Trials* 2008; 3:40-61.
 48. Plunkett TA, Chrystal KF, Harper PG. Quality of life and the treatment of advanced lung cancer. *Clin Lung Cancer* 2003; 5:28-32.
 49. Hoegler D. Radiotherapy for palliation of symptoms in incurable cancer. *Curr Probl Cancer* 1997; 21:129-183.
 50. Sapkota BH, Hirsch AE, Yoo AJ, Hornicek FJ, Raskin KA, Rosenthal DI, Growney ML, Hirsch JA. Treatment of metastatic carcinoma to the hip with CT-guided percutaneous acetabuloplasty: Report of four cases. *J Vasc Interv Radiol* 2009; 20:548-552.
 51. Kamalian S, Hirsch AE, Growney ML, Raskin KA, Yoo AJ, Krag KJ, Hirsch JA. CT-guided percutaneous calcaneoplasty: A case of metastatic intraarticular calcaneus fracture. *J NeuroIntervent Surg* 2009; 1:186-188.
 52. Gerszten PC, Monaco EA 3rd. Complete percutaneous treatment of vertebral body tumors causing spinal canal compromise using a transpedicular cavitation, cement augmentation, and radiosurgical technique. *Neurosurg Focus* 2009; 27:E9.
 53. Patchell RA, Tibbs PA, Regine WF, Payne R, Saris S, Kryscio RJ, Mohiuddin M, Young B. Direct decompressive surgical resection in the treatment of spinal cord compression caused by metastatic cancer: A randomized trial. *Lancet* 2005; 366:643-648.
 54. Gerszten PC, Germanwala A, Burton SA, Welch WC, Ozhasoglu C, Vogel WJ. Combination kyphoplasty and spinal radiosurgery: A new treatment paradigm for pathological fractures. *J Neurosurg Spine* 2005; 3:296-301.
 55. Ashamalla H. MM, Cardoso E, Macedon M, Guirguis A, Weng LJ, Ali S, Mokhtar B, Ashamalla M, Panigrahi N. Phase I trial of vertebral intracavitary cement and samarium (VICS): novel technique for treatment of painful vertebral metastasis. *Int J Radiat Oncol Biol Phys* 2009; 75:836-842.
 56. Hirsch AE, Medich DC, Rosenstein BS, Martel CB, Hirsch JA. Radioisotopes and vertebral augmentation: Dosimetric analysis of a novel approach for the treatment of malignant compression fractures. *Radiother Oncol* 2008; 87:119-126.
 57. Masala S, Roselli M, Massari F, Fiori R, Ursone A, Fossile E, Laudisi A, Simonetti G. Radiofrequency heat ablation and vertebroplasty in the treatment of neoplastic vertebral body fractures. *Anticancer Res* 2004; 24:3129-3233.
 58. Manchikanti L, Hirsch JA, Smith HS. Evidence-based medicine, systematic reviews, and guidelines in interventional pain management: Part 2: Randomized controlled trials. *Pain Physician* 2008; 11:717-773.
 59. Manchikanti L, Benyamin RM, Helm S, Hirsch JA. Evidence-based medicine, systematic reviews, and guidelines in interventional pain management: Part 3: Systematic reviews and meta-analysis of

- randomized trials. *Pain Physician* 2009; 12:35-72.
60. Manchikanti L, Singh V, Smith HS, Hirsch JA. Evidence-based medicine, systematic reviews, and guidelines in interventional pain management: Part 4: Observational studies. *Pain Physician* 2009; 12:73-108.
 61. Manchikanti L, Datta S, Smith HS, Hirsch JA. Evidence-based medicine, systematic reviews, and guidelines in interventional pain management: Part 6. Systematic reviews and meta-analyses of observational studies. *Pain Physician* 2009; 12:819-850.
 62. Staal JB, de Bie RA, de Vet HC, Hildebrandt J, Nelemans P. Injection therapy for subacute and chronic low back pain: An updated Cochrane review. *Spine (Phila Pa 1976)* 2009; 34:49-59.
 63. Chou R, Huffman L. *Guideline for the Evaluation and Management of Low Back Pain: Evidence Review*. American Pain Society, Glenview, IL, 2009. www.ampainsoc.org/pub/pdf/LBPEvidRev.pdf
 64. Manchikanti L, Datta S, Derby R, Wolfer LR, Benyamin RM, Hirsch JA. A critical review of the American Pain Society clinical practice guidelines for interventional techniques: Part 1. Diagnostic interventions. *Pain Physician* 2010; 13:E141-E174.
 65. Manchikanti L, Datta S, Gupta S, Munglani R, Bryce DA, Ward SP, Benyamin RM, Sharma ML, Helm II S, Fellows B, Hirsch JA. A critical review of the American Pain Society clinical practice guidelines for interventional techniques: Part 2. Therapeutic interventions. *Pain Physician* 2010; 13:E215-E264.
 66. Manchikanti L, Falco FJE, Boswell MV, Hirsch JA. Facts, fallacies, and politics of comparative effectiveness research: Part 1. Basic considerations. *Pain Physician* 2010; 13:E23-E54.
 67. Manchikanti L, Falco FJE, Boswell MV, Hirsch JA. Facts, fallacies, and politics of comparative effectiveness research: Part 2. Implications for interventional pain management. *Pain Physician* 2010; 13:E55-E79.
 68. Sox HC, Helfand M, Grimshaw J, Dickersin K; PLoS Medicine Editors, Tovey D, Knottnerus JA, Tugwell P. Comparative effectiveness research: Challenges for medical journals. *PLoS Med* 2010; 7:e1000269.
 69. Weinstein JN. Balancing science and informed choice in decisions about vertebroplasty. *N Engl J Med* 2009; 361:619-621.
 70. Manchikanti L, Boswell MV, Singh V, Benyamin RM, Fellows B, Abdi S, Buenaventura RM, Conn A, Datta S, Derby R, Falco FJE, Erhart S, Diwan S, Hayek SM, Helm S, Parr AT, Schultz DM, Smith HS, Wolfer LR, Hirsch JA. Comprehensive evidence-based guidelines for interventional techniques in the management of chronic spinal pain. *Pain Physician* 2009; 12:699-802.
 71. Manchikanti L, Singh V, Helm S, Schultz DM, Datta S, Hirsch J. An introduction to an evidence-based approach to interventional techniques in the management of chronic spinal pain. *Pain Physician* 2009; 12:E1-E33.