

Case Report

Minimally Invasive Interventional Therapy for Tarlov Cysts Causing Symptoms of Interstitial Cystitis

James Freidenstein, MD, J. Antonio Aldrete, MD, and Timothy Ness, MD, PhD

From: University of Alabama at Birmingham, Department of Anesthesiology Division of Pain Medicine, Birmingham, AL

Address correspondence:
James Freidenstein, MD
Ambulatory Care Pain Specialists
220 Fort Sanders West Blvd
Bldg 2, Suite 200
Knoxville, TN 37922
email: freidenstein@hotmail.com

Disclaimer: There was no external funding in the preparation of this manuscript.
Conflict of interest: None.

Manuscript received: 12/16/2012
Accepted for publication: 01/30/2012

Free full manuscript:
www.painphysicianjournal.com

Background: Tarlov cysts (TC) are present in 4.6% of the population and represent a potential source of chronic pain. When present at lumbosacral levels, symptoms are classically described as perineal pain/pressure, radiculopathy, and headache. Treatment outlined to date primarily includes cyst drainage with fibrin glue sealant and surgical interventions.

Objectives: We present 2 cases in which TC presented with signs and symptomatology consistent with interstitial cystitis who were treated with caudal epidural steroid injections.

Methods: Patients with urinary bladder pain and urgency received urological workups demonstrating hallmark features of interstitial cystitis including cystoscopic evidence of glomerulations. Radiographic imaging identified TC to be present on sacral nerve roots. Since pelvic pains could represent compressive radiculopathy of sacral roots, a cautious trial of minimally invasive caudal epidural steroid injections was performed.

Results: Both patients attained nearly 100% relief of pain for a period ranging from 6 months to 2 years following low volume, targeted caudal epidural steroid injection. They continue to be followed clinically and continue to report benefit with this treatment.

Limitations: This limited case series is retrospective in nature and potential complications have been noted by others in association with TC.

Conclusions: Use of caudal epidural steroid injections proved beneficial in the treatment of pelvic pain symptomatology and so may be considered as an option in patients with identified sacral TC.

Key words: Interstitial cystitis, pelvic pain, caudal epidural steroids, Tarlov cysts.

Pain Physician 2012; 15:141-146

Tarlov cysts (TC) were previously believed to be a rare cause of chronic pain. However, radiographic imaging has identified that they are both common and often symptomatic. Common presenting symptoms when located at lumbosacral

levels have been reported to include low back pain, sciatica, coccydynia and in some cases, cauda equina syndrome (1). It has been our experience that a subset of patients may have associated pelvic pain and urinary dysfunction which can often be confused

with interstitial cystitis (IC).

Current American Urological Association guidelines indicate that the pain of IC can extend throughout the pelvis and into the urethra, vulva, vagina, and low back. Patients will have symptoms of urinary urgency and frequency. Other keys to diagnosing IC include the presence of pain for greater than 6 weeks and the lack of a readily identifiable cause for the patient's pain such as urinary tract infection, endometriosis or other pelvic pathology (2). Once secondary causes are ruled out, the patient will usually undergo urodynamic studies and medication management with drugs such as pentosan polysulfate, amitriptyline, or other antineuropathic agents. Once conservative treatments have been exhausted, interventional treatments such as cystoscopy with hydrodistention or intravesical instillation of treatment solutions may be warranted. Patients with classic IC will exhibit the presence of Hunner lesions (mucosal ulcerations) and/or glomerulations (submucosal petechial hemorrhages) on cystoscopy following hydrodistention. More aggressive treatments include neuromodulation, cyclosporine A, and intradetrusor botulinum toxin. Surgical urinary diversion or cystectomy may be attempted as a last resort (2). Current recommendations highlight the multifactorial aspect of the diagnosis of interstitial cystitis syndrome, which is symptom-based.

There are 3 general types of sacral cysts: perineural cysts, dural ectasias, and large midline cysts, which often represent meningoceles. TC are perineural cysts filled with cerebrospinal fluid and are most commonly located in the S1 to S4 region. The cyst itself is located between the endo- and perineurium at or distal to the junction of the nerve root and the dorsal root ganglion (3,4). The key difference between TC and other spinal cysts (meningeal and arachnoid diverticula) is that they contain nerve fibers and exhibit a "potential" communication with the subarachnoid space, and as such demonstrate delayed filling on CT myelography (5).

By examining magnetic resonance imaging (MRI), it has been estimated that these cysts are present in 4.6% to 9% of the population, with an estimated 10% becoming symptomatic at some point during the patient's life (6), although a study by Langdown et al (7) which examined MRIs from 3,535 patients with lumbosacral symptoms revealed the incidence to be closer to 1.5%. A recent survey of patients with symptomatic TCs demonstrated that 86.6% of respondents were women and 13.4% were men with 53.7% of respondents describing their pain as severe (8). This is consistent with Tarlov's

belief that these cysts are more often symptomatic than standard meningeal diverticuli (4). The natural history of TCs includes an asymptomatic period early in life followed by the onset of symptoms as the cyst enlarges (5). This enlargement is often accompanied by adjacent nerve root compression and sacral bone erosion.

Long describes 3 separate symptomatic presentations associated with TCs. The most common involves pelvic and perineal pain associated with radiculopathy, genitalia sensory loss, and bowel/bladder dysfunction. The second group has the above listed perineal symptoms without overt radiculopathy. A third group manifests as progressive bowel and bladder dysfunction only (9). We believe that the latter is often misdiagnosed as IC or chronic unspecified pelvic pain. It is worth noting that anecdotally, many patients with symptomatic Tarlov cysts will experience worsening of their symptoms upon standing. These cysts represent a potential space and exhibit delayed filling via computed tomography (CT) myelography (10). When the patient stands, the cysts fill with cerebrospinal fluid (CSF) causing distention and compression of the associated nerve roots. This sequestration of CSF can often result in positional cervicalgia as well, which is delayed in nature and not typical of the symptomatology exhibited by patients with a dural puncture headache.

Epidural steroid injections have been suggested as a possible treatment of symptomatic TC, but one which must be done cautiously. In a recent study by Joo et al (11), MRIs from 2,669 patients were analyzed and 46 were found to have sacral TCs. On further analysis, 21 of these 46 patients (0.8% of the total number of patients) were found to have cysts extending to at or below the third sacral vertebrae. This was identified as a possible source of inadvertent (and possibly unrecognized) dural puncture.

Mitra et al (12) described 2 patients with TC that caused radicular symptoms who responded well to conservative treatment. One patient had an L5 TC and underwent an interlaminar lumbar epidural steroid injection with near complete resolution of pain. A follow-up MRI demonstrated complete resolution of the perineural cyst. The second patient was diagnosed with a TC at the right C6 neuroforamen and demonstrated 3 months of pain relief with a course of oral steroids.

There has been little published information regarding the efficacy of caudal epidural steroid injections for the treatment of symptomatic TC. Anecdotally, some surgeons are using this as a diagnostic blockade to assess adequacy for surgical intervention. We pres-

ent 2 cases of patients with coexisting interstitial cystitis whose symptoms responded favorably to minimally invasive, low volume caudal epidural steroid injection. These patients gave permission for presentation of their health-related information by signing Health Insurance Portability and Accountability Act (HIPAA) waivers as part of procedures approved by the University of Alabama at Birmingham (UAB) Institutional Review Board for Human Studies.

CASE 1

A 66-year-old woman with a past medical history significant for transvaginal hysterectomy and urethro-
tomy originally presented with pelvic pressure and burning pain in her left vaginal region in 1990 without an antecedent event. Her pain was worse with extended periods of standing and sitting. She remained relatively stable until 2004 when her pain began to unexpectedly

worsen. She developed the new onset of urinary burning and urgency without overt incontinence. This was accompanied by clitoral hyperstimulation and intermittent right leg weakness. The patient was referred to urology for her urinary symptoms and received a diagnosis of interstitial cystitis. This was further confirmed when the patient was found to have moderate to severe glomerulations on cystoscopy and some pain relief after hydrodistention. Despite this, she continued to exhibit pelvic pressure and vaginal burning. In 2005, an MRI revealed a TC at the S2/S3 level (Fig. 1). The patient was referred to UAB Pain Medicine and underwent caudal epidural steroid injection in which the needle was advanced only a few mm through the sacral hiatus; 3 mL of 1% lidocaine and 40 mg of triamcinolone were injected (Fig. 2). She received approximately 75% pain relief for a period of nearly one year and decreased her symptoms of urinary burning and urgency associated with her diagnosis of IC. Since that time, the patient has undergone several minimally invasive caudal epidural steroid injections with similar results without adverse effects. She intermittently utilizes oral gabapentin when she has any return of symptoms.

CASE 2

A 67-year-old man with a past medical history significant for diverticulitis with subsequent colon resec-

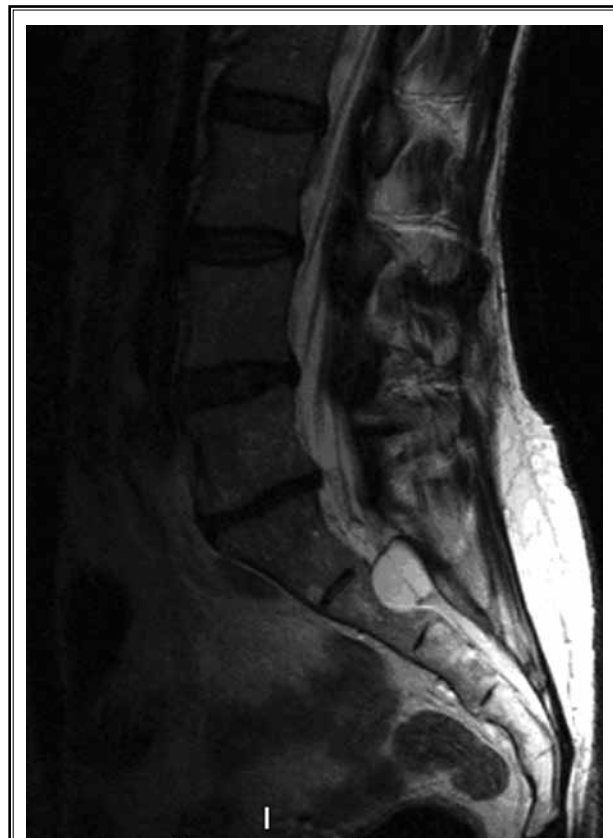


Fig. 1. Sagittal T2 MRI demonstrating large hyperintense TC at S2 with evidence of significant laminar erosion. Also seen is loss of disc height at L5/S1.

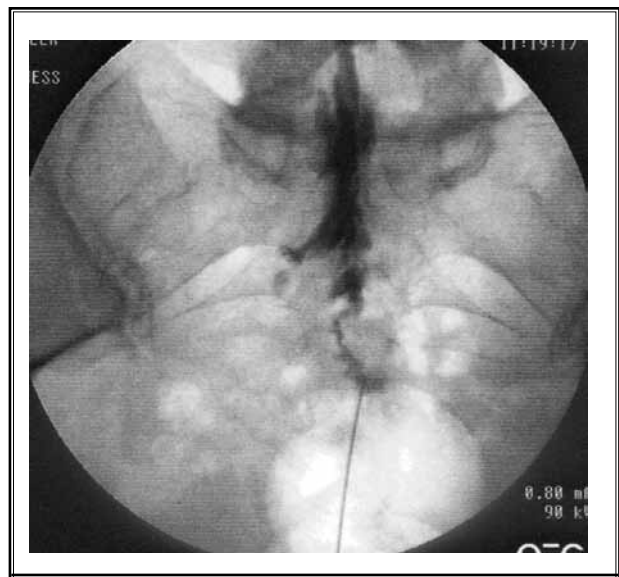


Fig. 2. Fluoroscopy image showing needle advanced a few mm through the sacral hiatus to avoid contacting TC. Note right S2 filling defect after contrast medium injection likely secondary to TC.

tion presented with urinary frequency, urgency, and pelvic pain. He was diagnosed with IC and initially responded favorably to oral pentosan sulfite treatment and intermittent bladder hydrodistentions during cystoscopy in which glomerulations were observed. Over time, he began to notice pain radiating down to his left

testicle, lower abdomen, and back. An MRI demonstrated an S2/3 TC which was believed to be contributing to his symptoms (Figs. 3 and 4). At that time, the patient was being maintained on tramadol 50 mg 3 times daily, hydrocodone-acetaminophen 10/500 3 times daily, and amitriptyline 25 mg at bedtime. He underwent a caudal epidural steroid injection in which the needle was advanced a few mm through the sacral hiatus and 3 mL of 1% lidocaine with 40 mg of triamcinolone was injected (Fig. 5). Following the injection, the patient reported greater than 75% relief of his pain for a period of nearly 6 months. The patient was able to discontinue hydrocodone entirely and now utilizes a regular dose of amitriptyline and intermittent use of tramadol. No adverse effects were noted from the intervention. Since that time, the patient has undergone 2 repeat treatments with subsequent durations of effect of greater than 6 months.

DISCUSSION

Treatment of symptomatic TC has exhibited variable success in the past. This is partly because the contribution of the cyst to symptoms is often difficult to delineate. Oftentimes, these cysts occur in conjunction with secondary pathology. In our cohort, response to hydrodistention and the presence of glomerulations

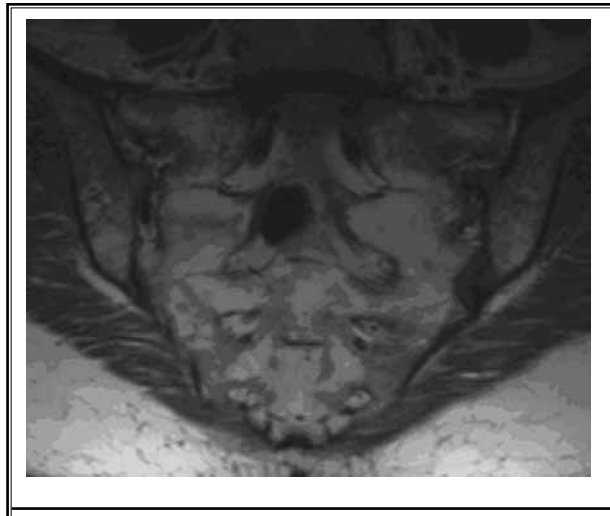


Fig. 3. Coronal T1 MRI demonstrating right-sided perineural cyst at S2

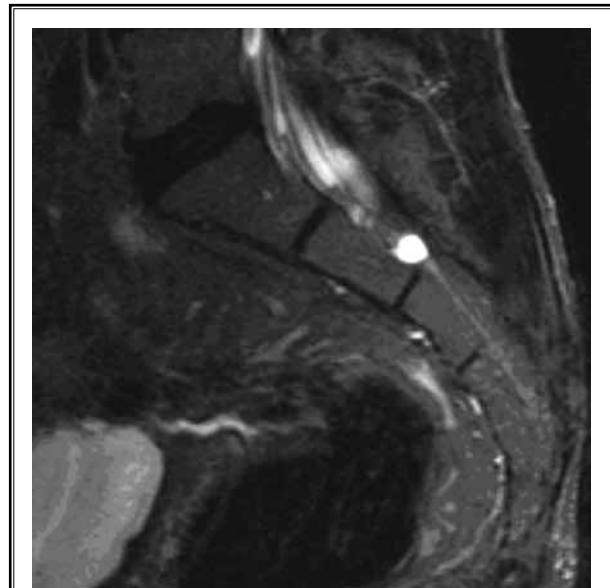


Fig. 4. Sagittal T2 MRI demonstrating hyperintense TC at the S2/3 junction with mild sacral laminar erosion.

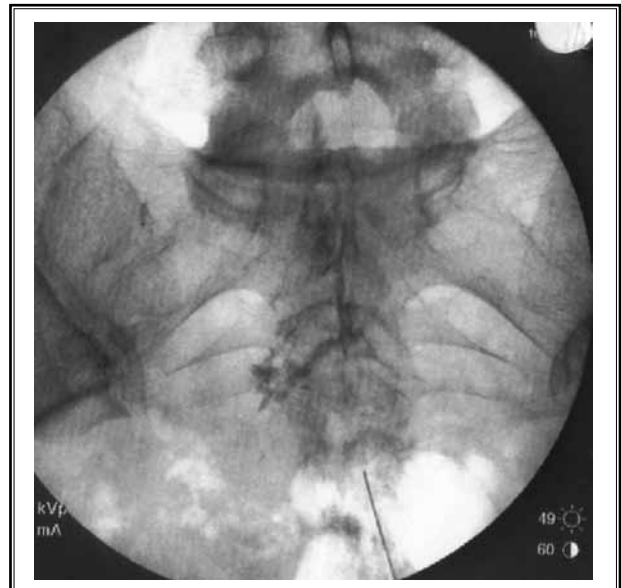


Fig. 5. Fluoroscopy image demonstrating contrast spread. Again note advancement of the needle only a few mm through the sacral hiatus to avoid contacting TC.

suggested that these patients may have had a contributing diagnosis of IC. Many chronic pain patients may present with co-existing lumbar disc herniation or radiculopathy which may further cloud the picture. This is often confounded by the current radiographic workup of lumbago with radiculopathy. Most MRI examinations do not extend to distal sacral regions where many of these cysts reside. This may result in misdiagnosis. In our patients, the dramatic response to minimally invasive caudal epidural steroid injections suggests that expansion of TC may contribute to, or overtly cause, symptoms consistent with interstitial cystitis or other urogenital pathology and should be considered in the diagnosis.

The current literature regarding the interventional/surgical treatment of symptomatic TC is limited to approaches which are aimed at permanently altering neuroanatomy. It has been found that cysts greater than 1.5 cm in diameter are more likely to be symptomatic and have been reported to respond more favorably to surgical treatment modalities (13). Other factors which have been suggested to be associated with positive surgical/interventional outcomes include the presence of radicular features and increased pain with standing and Valsalva maneuver (14,15). Multiple approaches have been attempted with varying success in the past. These include differential diagnostic blockade of associated nerve roots; diagnostic percutaneous cyst drainage; direct surgical obliteration of the cyst with or without sacral laminectomy; and CT-guided cyst aspiration; obliteration by injection of fibrin sealant; and sacral nerve root stimulation. Hiers et al (16) reported a trial in which 130 patients underwent fibrin glue injection with 75% reporting that they were satisfied with their level of relief extending out to 1-2 years. They reported that 4 patients described "substantial worsening of pain which lasted 2 to 4 weeks and then relented" with one patient exhibiting an ongoing increase in pain symptoms. They reported the same success rate in a series of 75 patients undergoing surgical intervention. Of these 75 patients, postoperative spinal leak occurred in 9%, with 50% of these requiring reoperation (16).

Voyadzis (13) reported a series of 10 patients undergoing cyst wall resection with sacral laminectomy which resulted in a 70% success rate with an average follow-up of 31.7 months. The 3 patients who did not experience significant improvement had cysts smaller than 1.5 cm in diameter without radicular pain (13). In 2007 Guo (14) {cited out of order—correct and renumber as needed} reported a series of 11 patients undergoing microsurgical cystectomy with repair of the local defect with muscle flap, Gelfoam®, and fibrin glue. Follow-up indicated that 9 of the 11 patients (82%) experienced significant relief. One patient developed worsening bladder dysfunction and the other had a persistent CSF leak (14).

Although the exact mechanism for pain relief is unknown, we hypothesize that TC may become symptomatic with cyst enlargement or trauma. It is possible that caudal epidural steroid injection will reduce cyst distention and subsequent nerve root pressure through a reduction of inflammation. However, when performing this procedure it is critical to know the exact location of the cyst, taking great care to not puncture the dura at the location of the base. In addition, low volume injectate should be used secondary to the risk of increased pressures and resultant worsening of pain with higher volumes.

CONCLUSION

TCs are being increasingly recognized as a potential source of chronic pain. Presenting symptoms often include urinary dysfunction, perineal pain/pressure and occasionally abdominal pain. These symptoms can often overlap with interstitial cystitis syndrome. Currently, little is known regarding the success of conservative treatment of TC. Percutaneous CT-guided cyst drainage is often only temporarily efficacious and can result in persistent dural leak. We present 2 patients with TC as well as a formal diagnosis of interstitial cystitis who responded favorably to low volume caudal epidural steroid injection, with relief of pelvic symptoms for 6 months or more.

REFERENCES

1. Cattaneo L, Pavesi G, Mancina D. Sural nerve abnormalities in sacral perineural (Tarlov) cysts. *J Neurol* 2001; 248:623-624.
2. Hanno P, Burks D, Clemens J, Dmochowski R, Erickson D, Fitzgerald M, Forrest J, Gordon B, Gray M, Mayer R, Newman D, Nyberg L, Payne C, Wesselmann U, Faraday M. AUA Guidelines for the Diagnosis and Treatment of Interstitial Cystitis/Bladder Pain Syndrome. *J Urology* 2011; 185:2162-2170.
3. Tarlov IM. Cyst of the sacral nerve roots: Clinical significance and pathogenesis. *Arch Neurol Psychiatry* 1952; 68:94-108.
4. Tarlov IM. Spinal perineural and meningeal cysts. *J Neurol Neurosurg Psychiatry* 1970; 33:833-843.
5. Acosta FL Jr., Quinones-Hinojosa A, Schmidt MH, Weinstein PR. Diagnosis and management of sacral Tarlov cysts: Case report and review of the literature. *Neurosurg Focus* 2003; 15:2-7.
6. Paulsen RD, Call GA, Murtagh FR. Prevalence and percutaneous drainage of cysts of the sacral nerve root sheath (Tarlov cysts). *AJNR Am J Neuroradiol* 1994; 15:293-299.
7. Langdown AJ, Grundy JRB, Birch NC. The clinical relevance of Tarlov cysts. *J Spinal Disord Tech* 2005; 18:29-33.
8. Wong RC, Manno M. An International Internet Survey of Individuals with Tarlov Cyst Disease. St. Michael's Hospital, Toronto, Ontario, Canada. 2008. www.tarlovcyst.org/index.php?option=com_content&task=view&id=77&Itemid=125
9. Donlin Long M.D. Neuroscience Consults. www.donlinlong.com/index.php?id=20
10. Khosla A, Wippold FJ. CT myelography and MR imaging of extramedullary cysts of the spinal canal in adult and pediatric patients. *AJR Am J Roentgenol* 2002; 178:201-207.
11. Joo J, Kim J, Lee J. The prevalence of anatomical variations that can cause inadvertent dural puncture when performing caudal block in Koreans: A study using magnetic resonance imaging. *Anaesthesia* 2010; 65:23-26.
12. Mitra R, Kirpalani D, Wedemeyer M. Conservative management of perineural cysts. *Spine (Phila Pa 1976)* 2008; 33:E565-568.
13. Voyadzis JM, Bhargava P, Henderson FC. Tarlov cysts: A study of 10 cases with review of the literature. *J Neurosurg* 2001; 95:25-32.
14. Guo D, Shu K, Chen R, Ke C, Zhu Y, Lei T. Microsurgical treatment of symptomatic sacral perineural cysts. *Neurosurgery* 2007; 60:1059-1066.
15. Mummaneni PV, Pitts LH, McCormack BM, Coroo JM, Weinstein PR. Microsurgical treatment of symptomatic sacral Tarlov cysts. *Neurosurgery* 2000; 47:74-79.
16. Hiers RH, Long D, North RB, Oaklander AL. Hiding in plain sight: A case of Tarlov perineural cysts. *J Pain* 2010; 11:833-837.