

Case Report

Feasibility of Combined Epicranial Temporal and Occipital Neurostimulation: Treatment of a Challenging Case of Headache

Kedar K. Deshpande, MD, and Kevin L. Wininger, BS

From: Orthopaedic & Spine Center, Columbus, OH

Dr. Deshpande is Medical Director of Orthopaedic & Spine Center, Columbus, OH.

Mr. Wininger is a Radiology Technologist and Research Director at the Orthopaedic & Spine Center, Columbus, OH.

Address correspondence: Kevin L. Wininger, BS
Orthopaedic & Spine Center
1080 Polaris Parkway # 200
Columbus, Ohio 43240
E-mail: kwininger@orthopaedicandspinecenter.com

Disclaimer: There was no external funding in the preparation of this manuscript.

Conflict of interest: Eighteen-month postimplant outcomes were presented as an abstract and poster at the 13th annual meeting of the North American Neuromodulation Society, Dec. 3-6, 2009.

Manuscript received: 09/09/2010

Revised manuscript received: 11/23/2010

Accepted for publication: 12/09/2010

Free full manuscript: www.painphysicianjournal.com

Background: Evidence of a paradigm shift towards epicranial neurostimulation treatment techniques aimed at the site of headache pain is beginning to populate the literature. This is most apparent by 2 recently published reports describing alternative approaches to peripheral nerve stimulation techniques for refractory migraine, including hemiplegic migraine.

Objectives: To contribute to the emerging literature on epicranial-based neuroaugmentative approaches which target site-specific areas of distinct, but relatively diffuse, headache pain. Specifically, we describe the feasibility of a novel neurostimulation technique: occipital nerve stimulation, combined with bilateral subcutaneous electrical stimulation over the temporal region, to treat a patient dually diagnosed with “complicated migraine” and occipital neuralgia. Integral to this report, key stimulation programming data are also presented to better distinguish the role of this form of therapy in migraine, or other headache forms, from both the clinical and biomedical perspectives.

Methods: Case presentation with literature review.

Results: At 24-month follow-up, headache onset had been reduced by more than 50%, including cessation of neurologic deficits that accompanied the patient’s migraines. No complications or adverse side effects are reported. The programming data reported here supports a proposed mechanism of action concerning stimulation of the auriculotemporal nerve distribution/anterior temporal region for management of refractory pain in migraine.

Limitations: Case presentation provides only initial assessment of treatment safety, not conclusive evidence of treatment effectiveness. Future studies which consider “follow-the-path” epicranial approaches to peripheral nerve stimulation techniques for refractory headache pain are needed to better quantify outcomes and mechanisms of action.

Conclusions: In the single case reported here, the feasibility of a novel neurostimulation technique (occipital nerve stimulation/bilateral subcutaneous temporal region stimulation) to treat headache is presented. At the 24-month follow-up, no complications (such as loss of coverage due to lead displacement or lead fracture or erosion) or adverse side effects were reported. Finally, inclusion of fundamental programming data in reports on neuroaugmentative approaches to headache care will complement initiatives in research from the clinical and biomedical communities involved in this field.

Key words: Epicranial neurostimulation technique, peripheral nerve stimulation, stimulation parameters, complicated migraine, occipital neuralgia.

Pain Physician 2011; 14:37-44

Occipital neuralgia is a paroxysmal jabbing pain in the distribution of the greater occipital or lesser occipital nerves or of the third occipital nerve, and typically occurs from the effects of irritation secondary to entrapment of a nerve along its course (1). When the associated headache is medically intractable, favorable clinical evidence exists for the use of occipital nerve stimulation (ONS) (2-7).

In contrast, "complicated migraine" is a non-standardized term associated with migraine with aura (1). In the literature the term is often used interchangeably with migraine variants, and synonymously with complex migraine and migraine accompagnée (8). Rothner (8) defined complicated migraine as "syndromes associated with episodic, transient, and reversible neurologic dysfunction such as hemiplegic migraine, basilar artery (basilar-type) migraine, ophthalmoplegic migraine, and retinal migraine." Treatment can be difficult due to the transient nature of the neurological impairments which confound pharmaceutical regimens. At the minimum, prophylactic use of acetylsalicylic acid is prudent (9,10). Conversely, triptans and the other vasoconstricting agents are contra-indicated due to risks of worsening the patient's condition, if an episode is, in fact, vasoconstrictive rather than neurologic in origin (11).

In a recently published case series, Reed et al (12) discuss ONS combined with supraorbital nerve stimulation (SONS) to manage primary headache—and one case involved the treatment of a patient with hemiplegic migraine. In addition, other headache forms have been treated by combined neurostimulation techniques. For example, occipital and craniofacial/juxta-orbital pain managed by ONS combined with SONS (13,14) or combined with infraorbital nerve stimulation (IONS) (13).

By means of an alternative neurostimulation technique for chronic migraine, Simopoulos et al (15) reported successful use of bilateral stimulation of the auriculotemporal nerve to treat refractory pain in the bilateral temporal distribution. The authors propose that stimulation influences nociceptive fibers traversing the sutures of the calvaria (citing unreliable paresthesia coverage in the trigeminal distributions associated with ONS) (15,16).

Here we discuss the feasibility of a novel neurostimulation technique in a challenging case of headache based on 24-month follow-up: ONS combined with bilateral subcutaneous stimulation over the temporal region (Fig. 1) to treat a patient dually diagnosed with complicated migraine and occipital neuralgia. It is

noted that the time-frame for this report closely parallels the treatment timelines reported by Reed et al (12) and Simopoulos et al (15). Hence, this article contributes to the emerging literature on epicranial-based neuroaugmentative approaches which target site-specific areas of distinct—but relatively diffuse—headache pain. Integral to our report, key neurostimulation programming data are also presented—to help improve our understanding of the role of this form of therapy in migraine, or other headache forms, from both the clinical and biomedical perspectives.

CASE REPORT

Our patient is a 44-year-old Caucasian woman under the care of an experienced neurology headache specialist for 8 years prior to referral to our practice. During the patient's consultation in 2007, she complained of a 28-year history of headaches which emanated from the occipital base without injury or inciting event, with an incidence rate of 4-5/week. These headaches were diagnosed as occipital neuralgia based on the International Classification of Headache Disorders-2 (1). In addition, her past medical history included absence seizures (with familial history); however, the last episode was 8 years ago, and subsequently her regimen of divalproex sodium was more recently discontinued. In 2002, a Le Fort I osteotomy was performed to correct malocclusion as opposed to treat temporomandibular joint dysfunction.

Notably, in 2004, the patient began experiencing headaches accompanied by marked phonophobia, temporary loss of vision (both eyes), slurred speech, ptosis (right eye), and hemiplegia (left leg). Not only were these headaches incapacitating, but the auras also imposed temporary but prolonged physical and communicative limitations. As a result of such symptoms, the patient's overall quality of life was negatively affected. The timing of such migraine episodes was variable with no known precipitating factors; incidence was reported as one per month with a maximum duration of headache of 72 hours. Neuroimaging and electroencephalographic studies were unremarkable, and no risk factors for atherosclerotic stroke were present. Based on symptomatology and the neurological workup, complicated migraine was added to the patient's headache profile by the referring neurologist.

Because of the characteristics of the patient's migraines, the ergot derivatives and triptans or other vasoconstricting agents were contra-indicated. Dark room

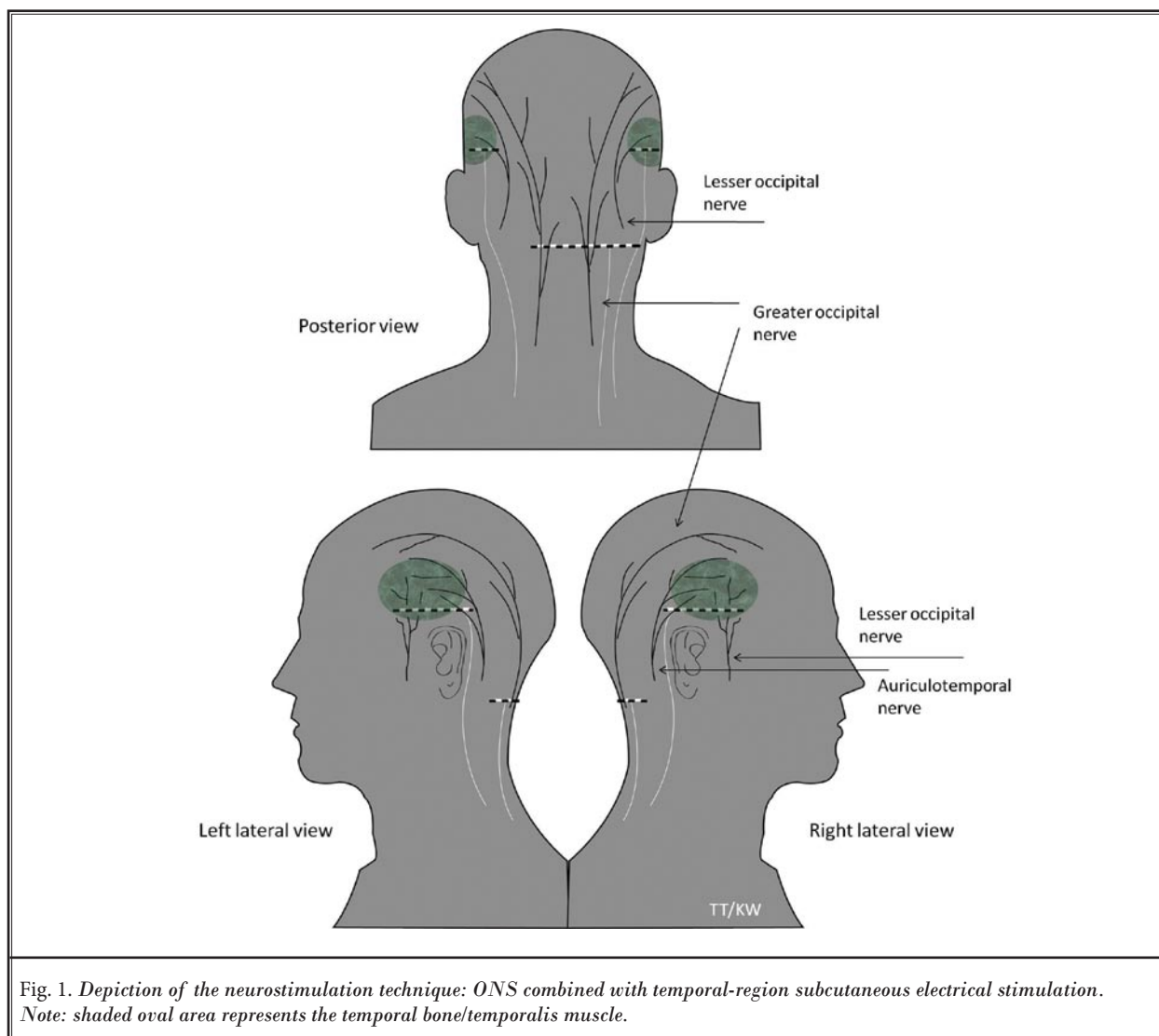


Fig. 1. Depiction of the neurostimulation technique: ONS combined with temporal-region subcutaneous electrical stimulation. Note: shaded oval area represents the temporal bone/temporalis muscle.

retreat and cold pack or moist heat applications were ineffective at aborting onset or alleviating severity. Pain management consisted of analgesics and opioids for mild to moderate onset of headaches. For severe onset, the patient either sought treatment at her local emergency department or her neurologist administered rescue medications, which consisted of acute pain and antiemetic drugs and steroids. Such treatments produced minimal abatement of her headaches. Furthermore, the duration of therapeutic greater occipital nerve blocks (and botulinum toxin injections administered at multiple sites in a halo/crown fashion to follow-the-path of her pain) was short-lived.

NEUROSTIMULATION TRIAL

At the time of our initial evaluation, the patient described her headaches with dual origins—a sharp jabbing pain at the occipital base, and a separate and distinct bilateral sensation of tightening/stabbing that encompassed the temporal and retro-orbital regions. She further qualified her headache pain as more intense on the right, but more frequent on the left. We focused on suppressing the site of headache pain (temporal and occipital regions). In January 2008, a 7-day trial of peripheral nerve stimulation was implemented with 3 wire leads (Medtronic Inc., Minneapolis, MN).

Bilaterally, one Quad lead (1x4) was subcutaneously placed superficial to the anterior border of the temporalis muscle (and over the sphenotemporal suture) to achieve stimulation over the auriculotemporal nerve distribution; and a single Standard lead (1x8) was placed from the right to apply ONS bilaterally (Fig. 2A). At follow-up the patient reported she had been headache free throughout the trialing period.

IMPLANT PROCEDURE

Subsequently, in June 2008, in accord with the patient's goals and informed consent, the described lead arrangement was implanted with one modification. We postulated that clinical benefit might be gained by expanding the available coverage over the temporal region—based on the terminal branching patterns of the trigeminal nerve (as well as the communicating branches between the auriculotemporal nerve and the lesser/greater occipital nerves) (17,18). Therefore, a Standard lead (1x8) was substituted for the Quad lead (1x4), and was placed bitemporally and subcutaneously in a horizontal fashion over the inferior border of the temporalis muscle (Fig. 2B). This intervention did not require approval from the institutional review board, and the patient tolerated the implant surgery well. Due to

the nature of the patient's migraines, it was felt unethical to leave the system turned off following implant.

It is important to also point out that 2 RestoreUltra neuropulse generators (Medtronic Inc., Minneapolis, MN,) were implanted. One generator (right gluteal pocket) accepted the ONS lead and the right temporal region lead, a second generator (left gluteal pocket) accepted the lead from the left temporal region. It was reasoned this battery configuration would 1) benefit the patient by providing dedicated power sources, and 2) permit tunneling of each lead respectively along an ipsilateral course. The latter might, in conjunction with the strain-relief loops, also help reduce the risks of displacement or lead fracture secondary to biomechanical-related strain and friction.

FOLLOW-UP

At the 24-month follow-up, no complications (such as loss of coverage due to lead displacement or lead fracture or erosion) or adverse side effects were reported. More than a 50% reduction in headache onset was reported, and notably, the patient has not experienced the neurologic deficits that defined her migraines. Finally, only one emergency department treatment was sought and the use of rescue medications has de-

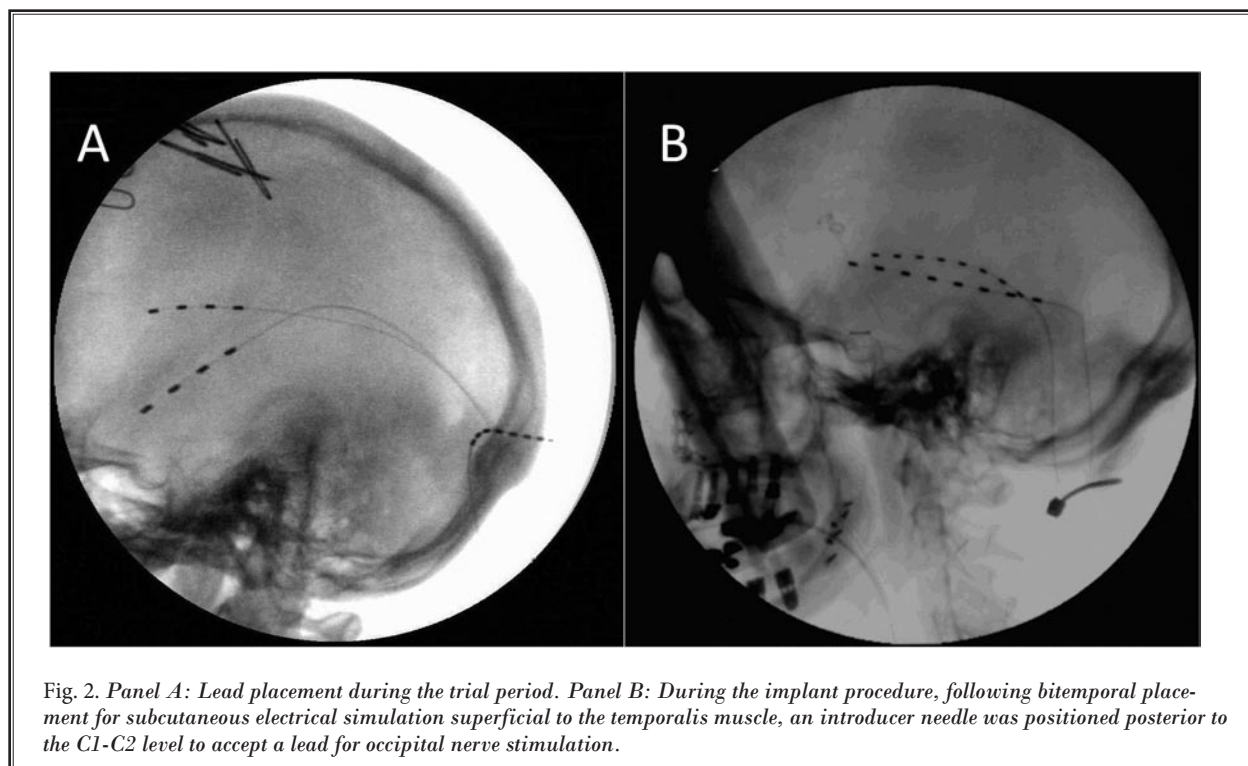


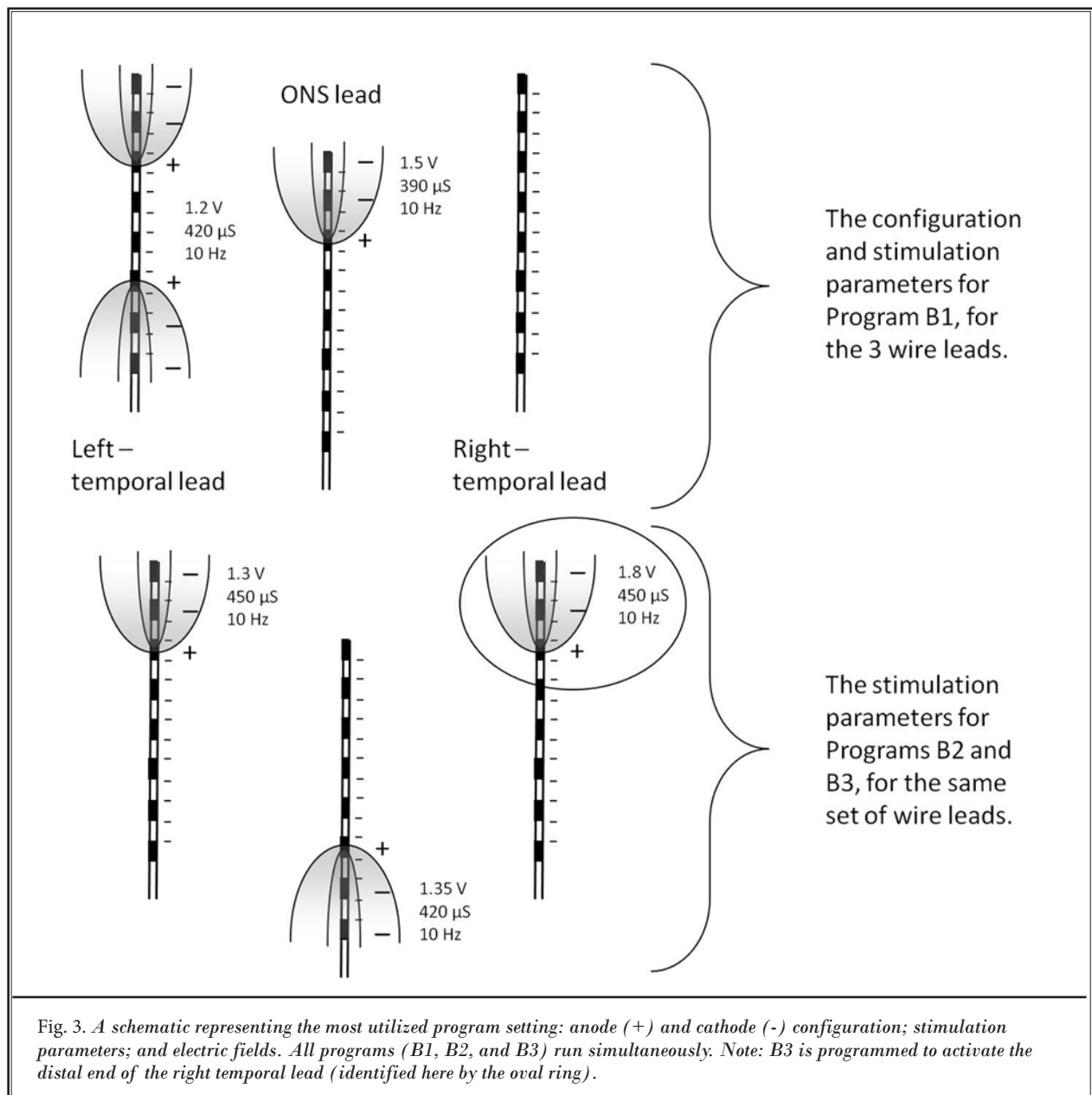
Fig. 2. Panel A: Lead placement during the trial period. Panel B: During the implant procedure, following bitemporal placement for subcutaneous electrical stimulation superficial to the temporalis muscle, an introducer needle was positioned posterior to the C1-C2 level to accept a lead for occipital nerve stimulation.

creased. Such outcomes have contributed to an overall improvement to the patient's quality of life.

Stimulation use is continuous over a 24 hour period. Both pulse rate and amplitude are controlled by the patient. Interestingly, for each of the 3 leads, the patient prefers slower "drumming" pulse rates (10 Hz), and attributes this frequency selection to providing a more satisfactory prophylactic stimulus. Figure 3 provides detailed information concerning programming and stimulation parameters.

DISCUSSION

Given the complex presentation of headache in our patient, the most notable outcome reported was cessation of the transient neurologic deficits which characterized the patient's migraines. Although a placebo effect cannot be completely excluded for the results achieved here, given the continuation of response over the follow-up period, there is probably minimal placebo effect.



THE NEUROSTIMULATION TECHNIQUE

The use and positioning of the 1x8 lead at implant relative to the 1x4 lead used during the trialing period, ideally, permits stimulation over the auriculotemporal nerve as well as both the sphenotemporal and temporo-occipital sutures (based on the employed cathode/anode configuration). The significance of this is seen in a supposition made by Simopoulos et al (15) on the possible mechanism of pain relief from stimulation over the auriculotemporal nerve distribution/anterior temporal region. Specifically, the authors make use of a theory that stimulation (and modulation) of nociceptive fibers traversing the bony sutures of the calvaria might be achieved based on the animal model (Fig. 4) (15). In our opinion, such a hypothesis appears reasonable given the limited evidence coupled with the lead placement and cathode/anode selection reported here (which might best facilitate regulation of the electric field adjacent to the suture lines).

It is noted that all patients in the Trentman et al study (16), with respect to ONS-only paresthesia coverage (which included information on neuropulse settings), were implanted with a constant-voltage generator/system, analogous to our case, with follow-up over a nearly identical period since implant. This enabled us to easily compare usage/stimulation parameters between techniques (i.e., ONS-only in contrast to the technique introduced here). Moreover, other authors have described common ONS parameters and use patterns with respect to treatment for various headache forms: Weiner and Reed (2), Popeney and Aló (19), as well as Trentman et al (20) in a pioneering report on the Bion microstimulator. Unfortunately, information about programming settings and stimulation parameters was not found in the reports on patients who received bilateral auriculotemporal nerve stimulation (15) or the combined techniques (ONS/SONS [12-14] or ONS/IONS [13]) for management of headache pain, in-

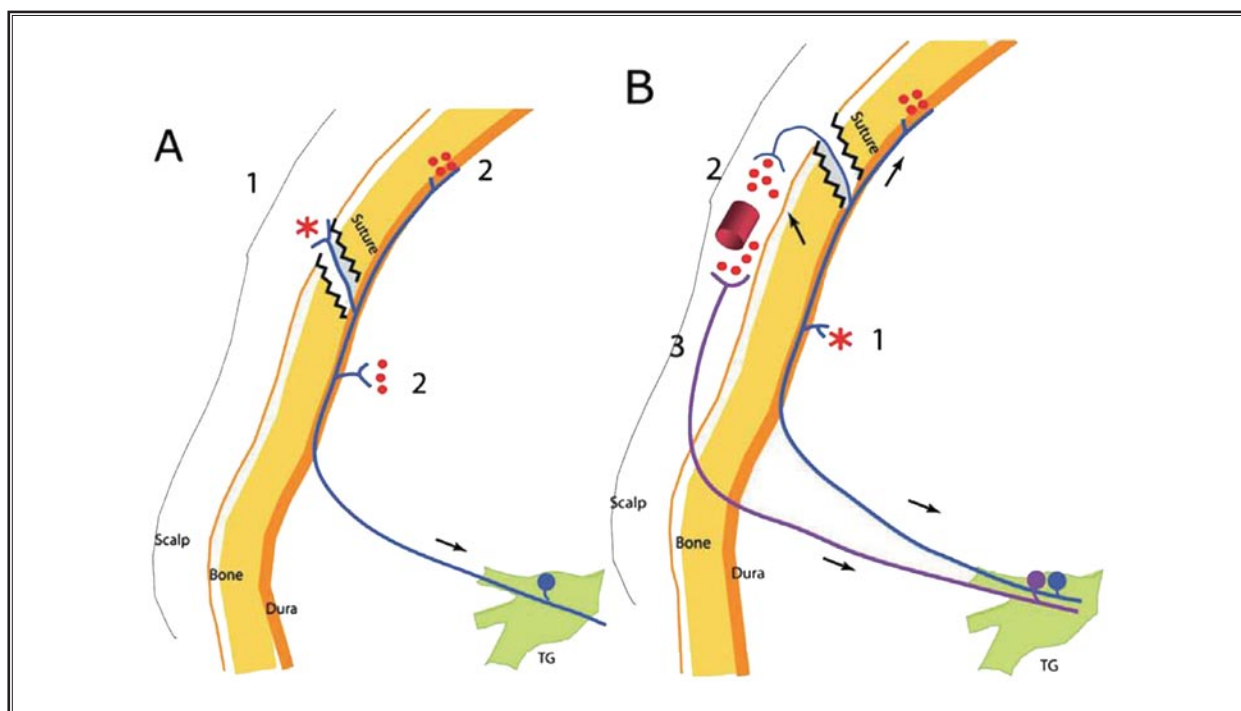


Fig. 4. (Panel A) Extracranial origin of intracranial pain – action potentials generated at extracranial collaterals of meningeal pain fibers (1) spread antidromically to collaterals that terminate inside the cranium (2). Result: local release of proinflammatory neuropeptides and activation of neighboring meningeal nociceptors (2). (Panel B) Intracranial origin of extracranial pain – action potentials generated at intracranial meningeal pain fibers (1) spread antidromically to collaterals that terminate outside the cranium (2). Result: local release of proinflammatory neuropeptides in the scalp and activation of neighboring somatic nociceptors (3). *Original site of activation. Red dots represent local release of inflammatory neuropeptides (e.g., calcitonin gene-related protein [CGRP], substance P. (Copyright permission granted by the American Headache Society [19].)

cluding migraine. In addition, in our opinion, such data is not routinely made available in the neuroaugmentative migraine literature. Therefore, presented as a quick reference for the reader, Table 1 summarizes relevant literature according to data on 1) headache form treated; 2) neurostimulation technique – stimulation system; and 3) stimulation parameters.

The inclusion of key data on neuropulse settings (programming options, cathode/anode designation, stimulation parameters) is important not only for further peripheral nerve stimulation research, but is of specific interest for clinical management and neuroaugmentative device research concerning headache (19). To this point, analysis of the neuropulse settings, with careful attention to patient preferences on the “feel” of stimulation (as reported here) and usage patterns is beneficial to advancing neurostimulation therapies, and is valuable for engineering next generation power sources (generator/battery) or modes of stimulation delivery (21).

CONCLUSION

In summary, in the single case reported here, the feasibility of a novel neurostimulation technique

(ONS/bilateral subcutaneous temporal region stimulation) to treat headache was presented. Clinical outcomes were based on 24-month follow-up. No complications or adverse events were noted. Headache onset has been decreased by more than 50%, and notably, the neurologic symptoms which accompanied the patient’s migraines ceased. Case presentation provides only initial assessment of treatment safety, not conclusive evidence of treatment effectiveness. However, our report supports the initial experiences presented by both Reed et al (12) and Simopoulos et al (15). Clearly, future studies which consider “follow-the-path” approaches to peripheral nerve stimulation techniques for refractory pain in migraine are necessary to better quantify outcomes and mechanisms of action. Finally, while parameter settings might be largely determined by individual patient preferences (i.e., the slow, “drumming” pulse rates our patient enjoys bitemporally and occipitally), from both clinical and biomedical perspectives such information is important to track as research initiatives on neurostimulation techniques are advanced, especially when new techniques are utilized.

Table 1. *Stimulation parameters.*

	Headache Form	Neurostimulation Technique – System	Pulse rate (Hz)	Amplitude (V)	Pulse-width (µS)
Deshpande et al (present report)	Complicated Migraine with Occipital Neuralgia	ONS with bilateral temporal region – constant-voltage, single channel	10	1.43	390
Simopoulos et al (15)	Migraine	Bilateral auriculotemporal nerve distribution – constant-current, single channel	Not reported	Not reported	Not reported
Reed et al (12)	Migraine (one case with Hemiplegic Migraine)	ONS/SONS – constant-current, single channel	Not reported	Not reported	Not reported
Slavin et al (13)	Craniofacial pain	ONS/SONS and ONS/IONS – constant voltage, single channel; constant-current, single channel; constant-current, multiple channel	Not reported	Not reported	Not reported
Trentman et al (20)	Cluster, Migraine, Hemicrania Continua	ONS – microstimulator – current controlled	45-60	Not reported	200-350
Trentman et al (16)	Cluster, Migraine, Hemicrania Continua	ONS – constant voltage, single channel	26-40	1.07	400
Popeney et al (19)	Transformed Migraine	ONS – constant voltage, single channel	55	3.2	400
Weiner and Reed (2)	Occipital Neuralgia	ONS – constant voltage, single channel	60-130	0.5-2	60-180

REFERENCES

1. International Headache Society. The International Classification of Headache Disorders (ICHD-2) website. ihs-classification.org/en. Accessed 1/26/2009.
2. Weiner RL, Reed KL. Peripheral neurostimulation for control of intractable occipital neuralgia. *Neuromodulation* 1999; 2:217-221.
3. Falco FJE, Berger J, Vrable A, Onyewu O, Zhu J. Cross talk: A new method for peripheral nerve stimulation. An observational report with cadaveric verification. *Pain Physician* 2009; 12:965-983.
4. Hayek SM, Jasper JF, Deer TR, Narouze SN. Occipital neurostimulation-induced muscle spasms: Implications for lead placement. *Pain Physician* 2009; 12:867-876.
5. Crawford CC, Huynh MT, Kepple A, Jonas WB. Systematic assessment of the quality of research studies of conventional and alternative treatment(s) of primary headache. *Pain Physician* 2009; 12:461-470.
6. Slavin KV, Nersesyan H, Wess C. Peripheral neurostimulation for treatment of intractable occipital neuralgia. *Neurosurgery* 2006; 58:112-119.
7. Johnstone CSH, Sundaraj R. Occipital nerve stimulation for the treatment of occipital neuralgia—eight case studies. *Neuromodulation* 2006; 9:41-47.
8. Rothner AD. Complicated migraine and migraine variants. *Curr Pain Headache Rep* 2002; 6:233-239.
9. Edmeads J. Migraine equivalents and complicated migraine. *Med Clin North Am* 1991; 75:567-578.
10. Kalendovsky Z, Austin JH. "Complicated migraine" its association with increased platelet aggregability and abnormal plasma coagulation factors. *Headache* 1975; 15:18-35.
11. Smith TR. Cardiovascular and safety concerns in using triptans in migraine patients. *Headache Q* 2001; 12:25-28.
12. Reed KL, Black SB, Banta II CJ, Will KR. Combined occipital and supraorbital neurostimulation for the treatment of chronic migraine headaches: Initial experience. *Cephalalgia*. 2010; 30:260-271.
13. Slavin KV, Colpan ME, Munawar N, Wess C, Nersesyan H. Trigeminal and occipital peripheral nerve stimulation for craniofacial pain: A single-institutional experience and review of the literature. *Neurosurg Focus* 2006; 21:E6.
14. Matharu MS, Bartsch T, Ward N, Frackowiak RSJ, Weiner R, Goadsby PJ. Central neuromodulation in chronic migraine patients with suboccipital stimulators: A PET study. *Brain* 2004; 127:220-230.
15. Simopoulos T, Bajwa Z, Lantz G, Lee S, Burstein R. Implanted auriculotemporal nerve stimulator for the treatment of refractory chronic migraine. *Headache* 2010; 50:1064-1069.
16. Trentman TL, Zimmerman RS, Seth N, Hentz JG, Dodick DW. Stimulation ranges, usage ranges, and paresthesia mapping during occipital nerve stimulation. *Neuromodulation* 2008; 11:56-61.
17. Becser N, Bovim G, Sjaastad O. Extracranial nerves in the posterior part of the head. *Spine* 1998; 23:1435-1441.
18. Kapoor V, Rothfus WE, Grahovac SZ, Kassam SZA, Horowitz MB. Refractory occipital neuralgia: Preoperative assessment with CT-guided nerve block prior to dorsal cervical rhizotomy. *AJNR Am J Neuroradiol* 2003; 24:2105-2110.
19. Popeney CA, Aló KM. C1-2-3 peripheral nerve stimulation (PNS) for the treatment of disability associated with transformed migraine. *Headache* 2003; 43:369-373.
20. Trentman TL, Rosenfeld DM, Vargas BB, Schwedt TJ, Zimmerman RS, Dodick DW. Greater occipital nerve stimulation via the Bion® microstimulator: Implantation technique and stimulation parameters. Clinical Trial NCT00205894. *Pain Physician* 2009; 12:621-628.
21. Buchser E, Thomson S. The future of spinal cord stimulation and related "neuroaugmentative" procedures. In: Simpson BA (ed) *Electrical Stimulation and the Relief of Pain. Pain Research and Clinical Management. Vol 15*. Elsevier B.V., Amsterdam, The Netherlands, 2003, p 258.