

Retrospective Review

Intramuscular Botulinum Toxin A (BtxA) in Complex Regional Pain Syndrome

Siddharth Kharkar, MD, MHS, Prakash Ambady, MD, Venkatesh Yedatore, MD, and Robert Schwartzman, MD

From: Hahnemann University Hospital, Philadelphia, PA and Drexel University College of Medicine, Philadelphia, PA.

Dr. Kharkar is Resident in Neurology, Department of Neurology, Drexel College of Medicine and Hahnemann University Hospital, Philadelphia, PA. Dr. Ambady is Resident in Neurology, Department of Neurology, Drexel College of Medicine and Hahnemann University Hospital, Philadelphia, PA.

Dr. Yedatore is a Professor in the Department of Neurology at Drexel University College of Medicine, Philadelphia, PA.

Dr. Schwartzman is Professor and Chairman of the Department of Neurology at Drexel University College of Medicine, and Hahnemann University Hospital, Philadelphia, PA.

Address correspondence:
Robert Schwartzman, MD
Drexel University College of Medicine
219 N Broad St, 7th Fl
Philadelphia, PA 19107
E-mail: Robert.Schwartzman@DrexelMed.edu

Disclaimer: There was no external funding in the preparation of this manuscript.

Conflict of interest: None.

Manuscript received: 12/07/2010
Revised manuscript received: 03/18/2011
Accepted for publication: 05/04/2011

Free full manuscript:
www.painphysicianjournal.com

Background: Pain associated with complex regional pain syndrome (CRPS) is frequently excruciating and intractable. The use of botulinum toxin for relief of CRPS-associated pain has not been well described.

Objectives: To assess whether intramuscular botulinum toxin injections cause relief of pain caused by CRPS, and to assess the risks of this treatment.

Study Design: Retrospective chart review.

Setting: Outpatient clinic.

Methods: Patients: 37 patients with spasm/dystonia in the neck and/or upper limb girdle muscles. Intervention: Electromyography-guided injection of botulinum toxin A (BtxA), 10-20 U per muscle. Total dose used was 100 U in each patient. Measurement: Local pain score on an 11 point Likert scale, 4 weeks after BtxA injections.

Results: Mean pain score decreased by 43% (8.2 ± 0.8 to 4.5 ± 1.1 , $P < 0.001$). Ninety-seven percent of the patients had significant pain relief. One patient had transient neck drop after the injections.

Limitations: This is a retrospective study; it lacks a control group and therefore the placebo effect cannot be eliminated. This study does not provide information on the efficacy of this treatment after 4 weeks.

Conclusion(s): Intramuscular injection of botulinum toxin A in the upper limb girdle muscles was beneficial for short term relief of pain caused by CRPS in this retrospective case series. The incidence of complications was low (2.7%)

Key words: Complex regional pain syndrome, botulinum toxin, spasm, dystonia

Pain Physician 2011; 14:311-316

Complex Regional Pain Syndrome (CRPS) is an incompletely understood, frequently devastating condition characterized by severe neuropathic pain. Associated features include autonomic dysregulation (increased sweating, increased temperature of the affected area, edema),

motor symptoms (weakness, tremor, dystonias), and trophic changes (e.g., loss of hair, nail changes, skin atrophy) (1,2). The exact pathophysiology of CRPS is not known. Sensitization of the nociceptive system, both peripherally and centrally, is believed to be a key pathogenic process (3). The frequently excruciating

pain is difficult to treat, and the natural history of CRPS is marked by unremitting worsening of the pain (1) .

The most widely known action of botulinum toxin A (BtxA) is its relaxing effect on skeletal muscles. BtxA is therefore widely used for the symptomatic relief of spasticity, dystonias, and other movement disorders. Recently there has been great interest in the use of BtxA for chronic pain. This interest stems from the fact that BtxA seems to have an early anti-nociceptive action that is independent of its muscle relaxing action and may be due to inhibition of central and peripheral sensitization (4-9) . It has been previously hypothesized that the anti-nociceptive action of BtxA may be beneficial in CRPS (10) .

We conducted a retrospective chart review of CRPS patients with pain and dystonia of neck and upper limb girdle muscles treated with intramuscular BtxA injections to ascertain the benefits and risks of this treatment.

METHODS

IRB Approval

This study was approved by the Institutional Review Board of the Drexel College of Medicine.

Patients

Thirty-seven patients were included in the study, of whom 35 (95%) were females. All patients in this study were initially seen in the pain clinic, and had CRPS as their primary diagnosis. All patients met the IASP criteria for CRPS (11). Of them, 26/37 (70%) had CRPS Type 1, and 11/37 (30%) had CRPS Type 2. Ten (27%) had lo-

calized CRPS predominantly involving one or both upper limbs. Twenty-seven (73%) had CRPS involving the entire body.

Patients with spasm or dystonia in the upper limb girdle muscles were referred for BtxA treatment. Based on previous literature, it was believed that patients with spasm/dystonia in the upper limb girdle muscles were most likely to benefit from BtxA treatment. These patients subsequently had electromyogram (EMG)-guided BtxA injections into these muscles.

Botulinum Injections

Patients were treated with intramuscular BtxA injections into specific upper limb girdle and neck muscles. EMG was utilized for injection of BtxA into the targeted muscles. Muscles were selected by patient complaints, hypertrophy, spasm and/or tenderness on palpation. The injecting needle also functioned as a monopolar recording electrode, and the reference electrode and ground electrode was a surface electrode placed close by. The needle was inserted into the targeted muscle using bony and soft tissue landmarks. The position of the needle in the targeted muscle was confirmed by asking the patient to activate the muscle and confirming the presence of motor unit potentials on the EMG monitor. Based on the size of the muscle, 10-20 U of BtxA were then injected through the needle. This procedure was repeated for all muscles injected. The total amount of BtxA used per patient was 100 U.

The majority of patients were injected on only one side: the right side in 15 (38 %) (15 OF 37 IS 40.54%), and the left in 17 (40 %) (17 OF 37 IS 45.94%). Eight (22 %) had bilateral injections. The specific sites of injection are listed in Table 1.

Pain Scores

Pain scores were recorded based on patient report of local pain on an 11-point Likert scale, where a score of zero meant the patient had no pain, and a score of 10 was the worst pain imaginable. Pre-treatment pain scores were collected immediately prior to the injections. Post-treatment pain scores were collected 4 weeks after the BtxA injections. None of the patients in this study had significant medication changes in the 4 weeks after BtxA injection. Patients who had significant medication changes, or had possible disease modifying treatments such as ketamine infusions, were excluded from this study. A patient was classified as "improved" if the decrease in pain scores was 2 or more. This was based on the results of a recent meta-analysis of pain

Table 1. *Muscles injected with bBotulinum toxin A.*

Muscle	Number	Percentage
1. Trapezius	37	100
2. SpleniusCapitis	37	98
3. Levator Scapulae	35	95
4. Longissimus capitus	17	46
5. Obliquus Capitis	13	35
6. Scalene	12	32
7. SemiSpinalis	12	32
8. ObliquusCapitis	13	35
9. SCM	4	11
10. Paraspinals, not specified	4	11

studies by Farrar et al (12) that demonstrated a 2 point decrease to be clinically significant.

Statistical Analysis

All statistical analysis was done using STATA 9 (Stata-Corp, College Station, TX). The student t-test was used for comparing means, the rank-sum test was used for comparing continuous variables for small samples, and the chi-square test was used for comparing proportions.

RESULTS

Pain Relief

All patients reported severe local pain at baseline, which was 8.2 ± 0.8 (range 7 to 10). The mean local pain score after the BtxA injections was 4.5 ± 1.1 (range 2 to 8). On average, there was a 43 % (range 11% to 78%) decrease in local pain scores. This difference was statistically significant ($P < 0.001$). These results are illustrated in Fig. 1.

By Farrar’s criterion (i.e., a decrease in local pain score by 2 or more points), 36/37 patients (97%) reported significant improvement in local pain.

Side-effects:

One out of the 37 patients (2.7%) developed a transient neck drop after BtxA injection. This patient required a non-invasive plastic neck brace after BtxA injections. The patient’s neck drop resolved spontaneously 2 weeks after the BtxA injection without any further complications.

None of the patients reported new onset dysphagia after the injections. No other serious sideeffects developed after the intramuscular BtxA injections.

Factors Affecting Improvement

Age, sex, extent of CRPS, CRPS type, number of extremities affected, and duration of disease were not found to affect the magnitude of pain decrease seen after BtxA injections.

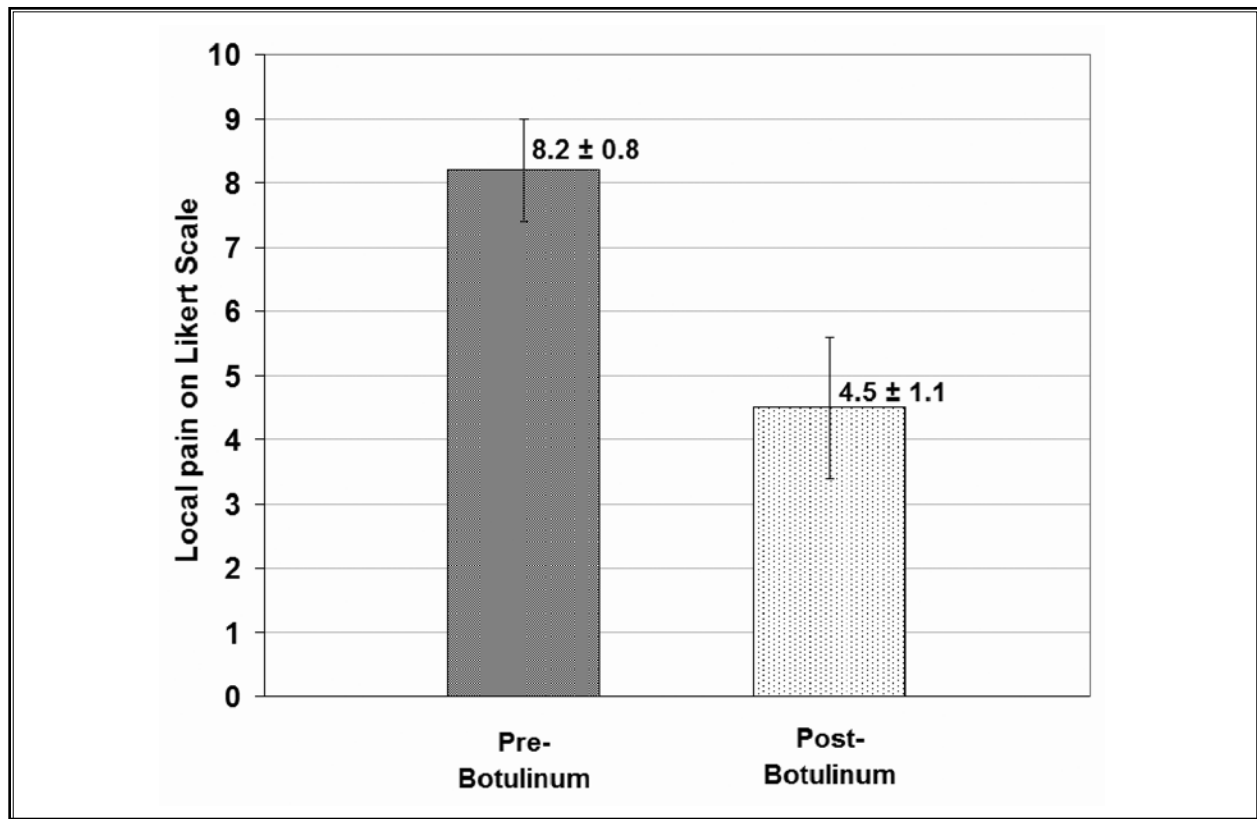


Fig. 1. Pre-BtxA and post-BtxA local pain scores>.

DISCUSSION

In this retrospective study, we found that intramuscular injection of BtxA in the upper limb girdle muscles was beneficial for short term relief of pain caused by CRPS.

Patients in this study were diagnosed with CRPS by strict application of IASP criteria by a single expert (RJS), minimizing diagnostic variability. All EMG-guided BtxA injections were administered by a single individual, who was well acquainted with the procedure. There was a 43 % decrease in local pain scores 4 weeks after intramuscular BtxA injections. The incidence of serious side-effects associated with this therapy was low (2.7%). There was no clinical prognostic marker for success of treatment. A previous study of the natural history of CRPS demonstrated little change of symptom severity after one year (1) .

In most patients, CRPS is initiated by trauma to the body, a surgical procedure, or fracture (1). The inciting event can produce neuropathic pain by peripheral and central sensitization. Peripheral sensitization lowers the threshold for nociceptor discharge by inducing changes in the receptors themselves (autosensitisation) and/or by increasing the excitability of the pain terminal membrane (heterosensitisation) (13). In CRPS, there is evidence of immune mediated inflammation, a process which is likely to be self-sustaining (3). Substance P and CGRP peptides are the vasoactive neuropeptides thought to be most active in the process of neurogenic inflammation (2,14) which may also enhance the "afferent barrage" to the dorsal root ganglia (DRG) and dorsal horn of the spinal cord. This induces central sensitization of pain transmission neurons which is pivotal to the maintenance of neuropathic pain (3,13) .

Botulinum toxin A acts by cleaving the SNAP-25 (synaptosome-associated protein of 25 kd) complex in the presynaptic terminal, which prevents formation of the SNARE (soluble N-ethyl maleimide sensitive factor-attachment protein-receptor) system. As a consequence, neurotransmitter vesicles do not fuse with the presynaptic membrane, which decreases the release of neurotransmitters at the synaptic cleft. This mechanism decreases the release of acetylcholine, CGRP, substance P and glutamate which may decrease the nociceptive fiber discharge (9,15-17).

Dystonia occurs in approximately 20% of CRPS patients (18,19). This abnormal, sustained contraction of skeletal muscles can reasonably be assumed to be a significant source of pain in CRPS patients. In the past, intrathecal baclofen and intrathecal glycine have been

evaluated for relief of CRPS associated dystonia. In larger case series, the former was found to be effective (20,21) but was associated with a high complication rate in at least one study (21); while the latter was ineffective in relieving either pain or dystonia (22). In our study, we postulate that the relief of CRPS-induced pain by intramuscular BtxA injection is multifactorial: relief of neurogenic inflammation (23-25); relaxation of dystonic muscles that may decrease the afferent nociceptive barrage from sensitised A-delta and C fibers; a distinct anti-nociceptive action which is distinct from these above-mentioned mechanisms (4-6) .

There are a significant number of clinical studies on the use of BtxA in neuropathic pain, that include two recent randomized control trials. Yuan et al (26) demonstrated in a placebo-controlled randomized trial of 18 patients that intradermal BtxA is effective in relieving painful diabetic neuropathy. Forty-four percent of patients receiving BtxA reported significant relief of pain, compared to 0% in the placebo group. Ranoux et al (6), in another placebo-controlled randomized trial of 29 patients, showed that intradermal BtxA was effective in post-herpetic neuralgia or posttraumatic/postoperative neuropathic pain. Forty percent of patients receiving BtxA reported significant improvement at the end of 2 weeks, compared to 14% of the patients who received a placebo. The relief of pain was sustained for 6 months after the initial injection. Multiple other non-randomized studies demonstrating the antinociceptive action of BtxA in neuropathic pain caused by diverse clinical conditions have been summarized (27).

In contrast, the use of BtxA for pain relief in CRPS has only been described in 5 small studies, which are summarized in Table 2.

In contrast to earlier studies of BtxA in CRPS, a recent randomized trial failed to find improvement in pain after intradermal BtxA injections (29) . The authors postulated that failure was due to the very severe/advanced nature of CRPS in their study participants, and the mode of administration of BtxA (intradermal-subcutaneous rather than intramuscular). This study was followed up quickly by the same group with a small case series describing 2 patients who were treated with intramuscular, rather than intradermal, BtxA (28) . Both patients had improvement in pain, skin discoloration and swelling, which is in agreement with the earlier study by Argoff (10).

There are several limitations of the current study. These include its retrospective nature, the lack of a control group, and the possibility of a placebo effect. The

Table 2. Previous literature on botulinum use for pain relief in complex regional pain syndrome (10,28-31)

Study	Treated CRPS patients	Controls	Treatment	Results	Comments
Safarpour 2010 (28)	2 patients. One with right hand, and the other with left hand and forearm CRPS.	None.	200 UBtxA in 4 muscles in one patient, and 240 U BtxA in 3 muscles in the second patient injected into tender "trigger points" of affected muscles.	Pain score in the local area decreased from 10 to 2 in the first patient and from 9 to 4 in the second patient. Pain relief sustained in the first patient for 3 years with quarterly injections. Both patients had improvement in discoloration, swelling and temperature changes in the affected limb.	Results are different than, and complementary to, earlier results by the same group with intradermal BtxA.
Safarpour 2010 (29)	8 patients with severe CRPS affecting all 4 limbs.	6 similar CRPS patients treated with intradermal injections with normal saline.	Intradermal and subcutaneous injections, dose:40-100 U.	No improvement in pain scores, or secondary measures (quantitative sensory testing, sleep quality, pain impact, global satisfaction).	See discussion.
Carroll 2009 (30)	9 patients with lower limb CRPS.	Same 9 patients (double-blinded randomized crossover study) Placebo treatment was 10 mL of 0.5% bupivacaine.	Cervical sympathetic blocks using 10 mL of 0.5% bupivacaine and 75 U of BtxA.	Pain relieved for a longer duration in treatment group (median 71 days) compared to controls (median 10 days).	Primary endpoint was defined as return to baseline pain level.
Lauretti 2005 (31)	2 CRPS patients (extent not noted) with marked hand dystonia.	None	75 U of BtxA into intrinsic finger flexors and wrist.	All patients had improvement in dystonia and pain. Motor relief sustained for up to 8 months.	Patients also received a series of 5 ipsilateral stellate ganglion blocks. Effect of BtxA cannot be discerned separately, especially in the absence of a control group.
Argoff 2002 (10)	11 patients with CRPS affecting only one upper extremity	None	Intramuscular, shoulder girdle muscles. Dose: 25-50 U	All patients reported relief in pain and improvement of skin color and edema at 6 and 12 weeks.	Only study which documented changes in sudomotor symptoms.

study does not provide information on the efficacy of this treatment after one month. The current study was unable to identify predictors of pain relief after BtxA injection. Further studies are essential to determine these patient characteristics, and define subgroups of CRPS patients that are most likely to benefit from intramuscular BtxA injections.

This study is the largest study to date that documents a potentially useful therapy for a disease characterized by devastating and frequently intractable pain. In view of its limitations, this retrospective study

provides data to justify a larger prospective randomized control trial. Further studies need to confirm these results, identify the subgroups of CRPS patients and modes of BtxA administration that optimize pain relief, assess changes in other symptoms of CRPS (sudomotor, vasomotor, trophic) and associated conditions (migraine), assess its use as an adjunct with other treatments such as ketamine to increase the efficacy of these medications, or to prolong their effect by decreasing the chronic pain stimuli that lead to central sensitization (32,33).

REFERENCES

- Schwartzman RJ, Erwin KL, Alexander GM. The natural history of complex regional pain syndrome. *Clin J Pain* 2009; 25:273-280.
- Birklein F. Complex regional pain syndrome. *J Neurol* 2005; 252:131-138.
- Schwartzman RJ, Alexander GM, Grothusen J. Pathophysiology of complex regional pain syndrome. *Expert Rev Neurother* 2006; 6:669-681.
- Aoki KR. Review of a proposed mechanism for the antinociceptive action of botulinum toxin type A. *Neurotoxicology* 2005; 26:785-793.
- Park HJ, Lee Y, Lee J, Park C, Moon DE. The effects of botulinum toxin A on mechanical and cold allodynia in a rat model of neuropathic pain. *Can J Anaesth* 2006; 53:470-477.
- Ranoux D, Attal N, Morain F, Bouhasira D. Botulinum toxin type A induces direct analgesic effects in chronic neuropathic pain. *Ann Neurol* 2008; 64:274-283.
- Casale R, Tugnoli V. Botulinum toxin for pain. *Drugs R D* 2008; 9:11-27.
- Raj PP. Botulinum neurotoxin in chronic pain management. *Pain Pract* 2004; 4:S68-S72.
- Cui M, Khanijou S, Rubino J, Aoki KR. Subcutaneous administration of botulinum toxin A reduces formalin-induced pain. *Pain* 2004; 107:125-133.
- Argoff CE. A focused review on the use of botulinum toxins for neuropathic pain. *Clin J Pain* 2002; 18:S177-S181.
- Stanton-Hicks M, Jänig W, Hassenbusch S, Haddock JD, Boas R, Wilson P. Reflex sympathetic dystrophy: changing concepts and taxonomy. *Pain* 1995; 63:127-133.
- Farrar JT, Young JP, LaMoreaux L, Werth JL, Poole RM. Clinical importance of changes in chronic pain intensity measured on an 11-point numerical pain rating scale. *Pain* 2001; 94:149-158.
- Woolf CJ, Salter MW. Neuronal plasticity: Increasing the gain in pain. *Science* 2000; 288:1765-1769.
- Kilo S, Harding-Rose C, Hargreaves KM, Flores CM. Peripheral CGRP release as a marker for neurogenic inflammation: A model system for the study of neuropeptide secretion in rat paw skin. *Pain* 1997; 73:201-207.
- Duggan MJ, Quinn CP, Chaddock JA, Purkiss JR, Alexander FCG, Doward S, Fooks SJ, Friis LM, Hall YHJ, Kirby ER, Leeds N, Mouldsdale HJ, Dickenson A, Green GM, Rahman W, Suzuki R, Shone CC, Foster KA. Inhibition of release of neurotransmitters from rat dorsal root ganglia by a novel conjugate of a Clostridium botulinum toxin A endopeptidase fragment and Erythrina cristagalli lectin. *J Biol Chem* 2002; 277:34846-34852.
- Purkiss J, Welch M, Doward S, Foster K. Capsaicin-stimulated release of substance P from cultured dorsal root ganglion neurons: involvement of two distinct mechanisms. *Biochem Pharmacol* 2000; 59:1403-1406.
- Meng J, Wang J, Lawrence G, Dolly JO. Synaptobrevin I mediates exocytosis of CGRP from sensory neurons and inhibition by botulinum toxins reflects their anti-nociceptive potential. *J Cell Sci* 2007; 120:2864-2874.
- van Hilten JJ, van de Beek WJ, Vein AA, van Dijk JG, Middelkoop HA. Clinical aspects of multifocal or generalized tonic dystonia in reflex sympathetic dystrophy. *Neurology* 2001; 56:1762-1765.
- Schwartzman RJ, Kerrigan J. The movement disorder of reflex sympathetic dystrophy. *Neurology* 1990; 40:57-61.
- van Hilten BJ, van de Beek WJ, Hoff JI, Voormolen JH, Delhaas EM. Intrathecal baclofen for the treatment of dystonia in patients with reflex sympathetic dystrophy. *N Engl J Med* 2000; 343:625-630.
- van Rijn MA, Munts AG, Marinus J, Voormolen JHC, de Boer KS, Teepe-Twiss IM, van Dasselaa NT, Delhaas EM, van Hilten JJ. Intrathecal baclofen for dystonia of complex regional pain syndrome. *Pain* 2009; 143:41-47.
- Munts AG, van der Plas AA, Voormolen JH, Marinus J, Teepe-Twiss IM, Onkenhout W, van Gerven JM, van Hilten JJ. Intrathecal glycine for pain and dystonia in complex regional pain syndrome. *Pain* 2009; 146:199-204.
- Tugnoli V, Capone JG, Eleopra R, Quatrone R, Sensi M, Gastaldo E, Tola MR, Geppetti P. Botulinum toxin type A reduces capsaicin-evoked pain and neurogenic vasodilatation in human skin. *Pain* 2007; 130:76-83.
- Gazerani P, Pedersen NS, Staahl C, Drewes AM, Arendt-Nielsen L. Subcutaneous Botulinum toxin type A reduces capsaicin-induced trigeminal pain and vasomotor reactions in human skin. *Pain* 2009; 141:60-69.
- Carmichael NME, Dostrovsky JO, Charlton MP. Peptide-mediated transdermal delivery of botulinum neurotoxin type A reduces neurogenic inflammation in the skin. *Pain* 2010; 149:316-324.
- Yuan RY, Sheu JJ, Yu JM, Chen WT, Tseng JJ, Chang HH, Hu CJ. Botulinum toxin for diabetic neuropathic pain: A randomized double-blind crossover trial. *Neurology* 2009; 72:1473-1478.
- Jeynes LC, Gauci CA. Evidence for the use of botulinum toxin in the chronic pain setting--a review of the literature. *Pain Pract* 2008; 8:269-276.
- Safarpour D, Jabbari B. Botulinum toxin A (botox) for treatment of proximal myofascial pain in complex regional pain syndrome: Two cases. *Pain Med* 2010; 11:1415-1418.
- Safarpour D, Salardini A, Richardson D, Jabbari B. Botulinum Toxin A for Treatment of Allodynia of Complex Regional Pain Syndrome: A Pilot Study. *Pain Med* 2010; 11:1411-1414.
- Carroll I, Clark JD, Mackey S. Sympathetic block with botulinum toxin to treat complex regional pain syndrome. *Ann Neurol* 2009; 65:348-351.
- Lauretti GR, Veloso FDS, Mattos ALD. [Functional rehabilitation and analgesia with botulinum toxin A in upper limb complex regional pain syndrome type I: case reports.]. *Rev Bras Anestesiol* 2005; 55:207-211.
- Sigtermans MJ, van Hilten JJ, Bauer MCR, Arbous MS, Marinus J, Sarton EY, Dahan A. Ketamine produces effective and long-term pain relief in patients with Complex Regional Pain Syndrome Type 1. *Pain* 2009; 145:304-311.
- Kiefer RT, Rohr P, Ploppa A, Dieterich HJ, Grothusen J, Koffler S, Altemeyer KH, Unertl K, Schwartzman RJ. Efficacy of ketamine in anesthetic dosage for the treatment of refractory complex regional pain syndrome: An open-label phase II study. *Pain Med* 2008; 9:1173-120