

**Technical Report**

## Alternative Approach To Needle Placement In Cervical Spinal Cord Stimulator Insertion

Jie Zhu, MD<sup>1,2</sup>, Frank J. E. Falco, MD<sup>1,2</sup>, C. Obi Onyewu, MD<sup>1,2</sup>, Renato Vesga, MD<sup>1,2</sup>,  
Youssef Josephson, DO<sup>2</sup>, Asim Husain, DO<sup>2</sup>, and Gabriella Gutman, MD<sup>2</sup>

From: Mid Atlantic Spine & Pain Physicians, Newark, DE; and Temple University Hospital, Philadelphia, PA;

Dr. Zhu is Attending Physician, Mid Atlantic Spine & Pain Physicians, Newark, DE and Elkton, MD; Faculty, Pain Medicine Fellowship Program, Temple University Hospital, Philadelphia, PA; Adjunct Assistant Professor, Temple University Medical School, Philadelphia, PA. Dr. Falco is Medical Director, Mid Atlantic Spine & Pain Physicians, Newark, DE and Elkton, MD; Director, Pain Medicine Fellowship Program, Temple University Hospital, Philadelphia, PA; Adjunct Associate Professor, Temple University Medical School, Philadelphia, PA. Dr. Onyewu is Attending Physician, Mid Atlantic Spine & Pain Physicians, Newark, DE and Elkton, MD; Faculty, Pain Medicine Fellowship Program, Temple University Hospital, Philadelphia, PA; Adjunct Assistant Professor, Temple University Medical School, Philadelphia, PA. Dr. Vesga is Attending Physician, Mid Atlantic Spine & Pain Physicians, Newark, DE and Elkton, MD; Faculty, Pain Medicine Fellowship Program, Temple University Hospital, Philadelphia, PA; Adjunct Assistant Professor, Temple University Medical School, Philadelphia, PA. Dr. Josephson is a Fellow, Pain Medicine Fellowship Program, Temple University Hospital, Philadelphia, PA. Dr. Husain is a Fellow, Pain Medicine Fellowship Program, Temple University Hospital, Philadelphia, PA. Dr. Gutman is a Fellow, Pain Medicine Fellowship Program, Temple University Hospital, Philadelphia, PA.

Address correspondence:  
Jie Zhu, MD  
139 E. Chestnut Hill Rd.  
Newark, DE 19713  
Email: [zzzzjim@gmail.com](mailto:zzzzjim@gmail.com)

Disclosure: Frank J.E. Falco, MD is a consultant for St. Judes Medical. There was no outside funding

Manuscript received: 11/22/2010  
Revised manuscript received: 12/15/2010  
Accepted for publication: 01/20/2011

Free full manuscript:  
[www.painphysicianjournal.com](http://www.painphysicianjournal.com)

**Background:** Neuromodulation with spinal cord stimulation is a proven cost effective treatment for the management of common conditions such as chronic radicular leg pain from failed back surgery syndrome, complex regional pain syndrome, and other painful neuropathic pain syndromes. The traditionally instructed method for percutaneous spinal cord stimulator (SCS) lead placement promotes the use of a “loss of resistance” (LOR) technique under anteroposterior (AP) fluoroscopic guidance to assure midline lead placement and proper entry into the epidural space.

**Objective:** To describe the relevant anatomy and method for a precise needle placement approach for placement of percutaneous cervical spinal cord stimulation (SCS) leads without loss of resistance (LOR) using a syringe. An oblique fluoroscopic view is presented demonstrating successful placement of cervical SCS leads.

**Design:** Technical report.

**Setting:** Pain management clinic.

**Methods:** Discussion with accompanying fluoroscopic images. This technical report meets HIPAA compliance standards.

**Results:** Successful placement of percutaneous SCS leads without traditional loss of resistance using an oblique fluoroscopic approach.

**Limitations:** Technical report only. The risks, potential complications, and benefit from this approach are beyond the scope of the article.

**Conclusions:** This fluoroscopic technique provides an alternative means for placing percutaneous cervical SCS leads without the use of the traditional loss of resistance technique.

**Key words:** spinal cord stimulation, neuromodulation, cervical spine, fluoroscopy, loss of resistance, epidural injection, neuropathic pain, failed neck surgery.

**Pain Physician 2011; 14:195-210**

**T**he Loss of Resistance (LOR) technique was developed at a time when fluoroscopy was either not yet widely available or the circumstances would not have allowed for C-arm fluoroscopy use, specifically, in cases of pregnancy. This technique relies on the denseness of the ligamentum flavum and the sudden absence of resistance experienced during ballotment of a syringe filled with saline (with or without an air bubble) or air once through the ligament (1-4). Occasionally it is difficult to use LOR with certain clinical circumstances such as obesity, patients with an abnormal interlaminar opening at the anteroposterior

fluoroscopic views, or patients with changes to the integrity of the ligamentum flavum as may occur with previous spinal surgery. Furthermore, a false LOR may occur between changes in fascial planes that may lead to uncertainty of needle depth (5). This fluoroscopic technique provides an alternative means for placing percutaneous cervical spinal cord stimulator (SCS) leads with or without the use of the traditional LOR technique. The goal of this approach is to use the optimal oblique view (Figs. 1 and 2) of fluoroscopy to see the needle tip position precisely related to the target lamina, which serves as the bony landmark in cervical SCS lead insertion.

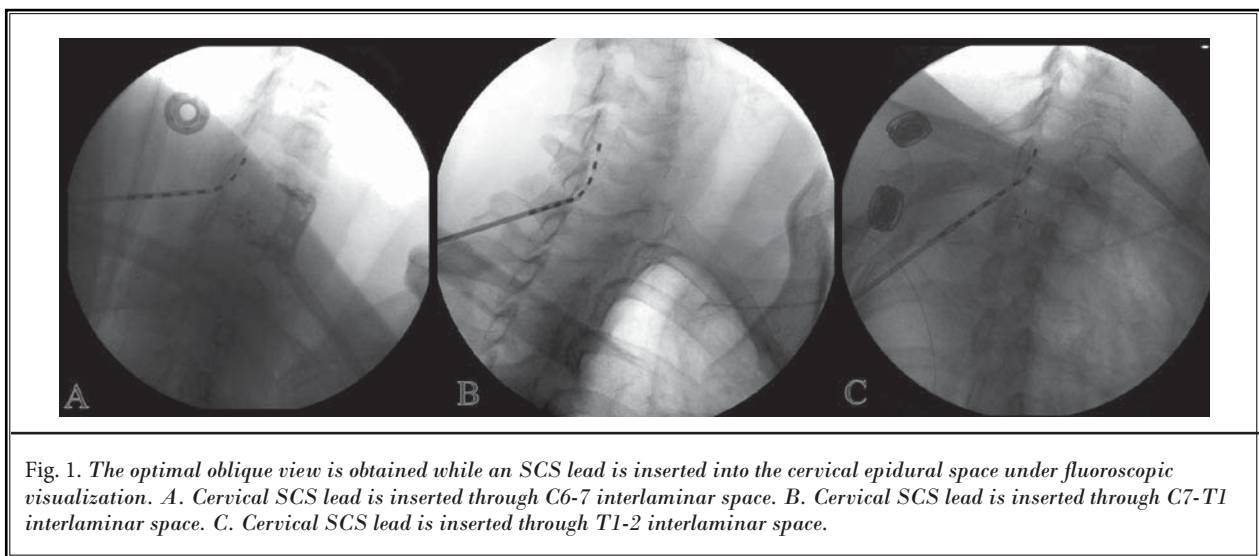


Fig. 1. The optimal oblique view is obtained while an SCS lead is inserted into the cervical epidural space under fluoroscopic visualization. A. Cervical SCS lead is inserted through C6-7 interlaminar space. B. Cervical SCS lead is inserted through C7-T1 interlaminar space. C. Cervical SCS lead is inserted through T1-2 interlaminar space.

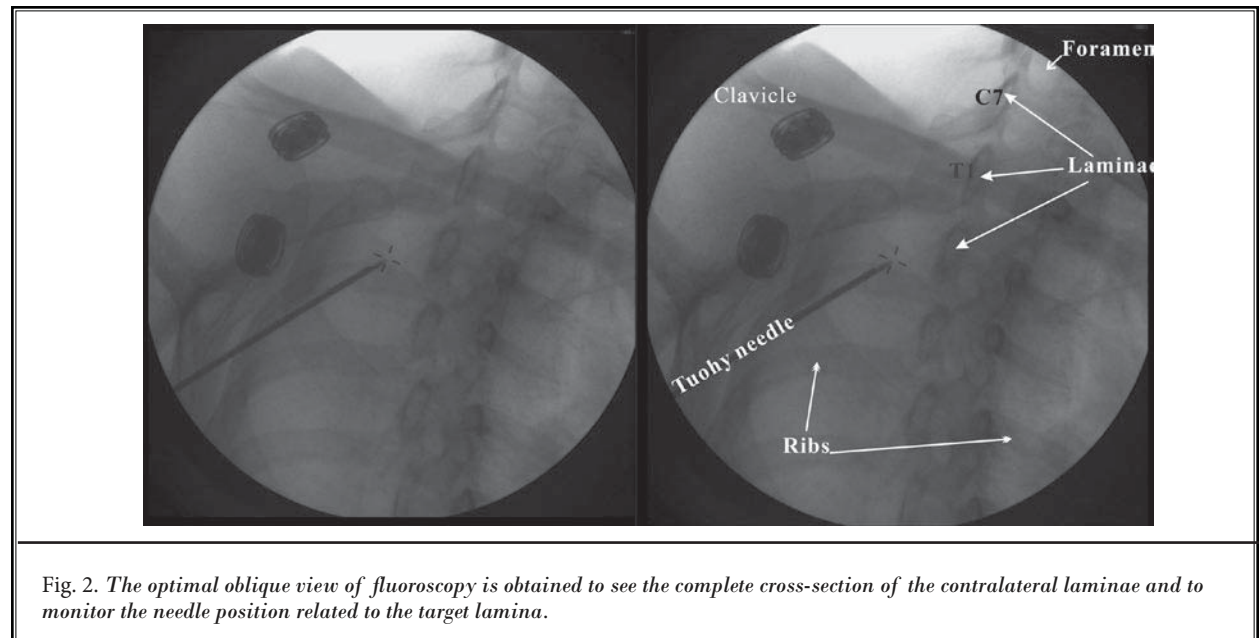


Fig. 2. The optimal oblique view of fluoroscopy is obtained to see the complete cross-section of the contralateral laminae and to monitor the needle position related to the target lamina.

## METHODS

### Step 1: Positioning patient (Fig. 3)

The patient is placed in the prone position on the table with the fluoroscope positioned to the contralateral side of the needle insertion. The target interlaminar space (such as C6-7, C7-T1, or T1-2, etc.) is identified on AP view with fluoroscopy. Then the fluoroscope is rotated to optimal oblique view to visualize the target contralateral lamina in true cross-sectional view. The

target lamina has a clear, sharp dense border around it. The epidural space should be below the lamina, but not more than by approximately 2-3 mm (Fig. 4). The level below T1-2 may be used if the optimal oblique view can be obtained, and there is no technique difficulty. The thoracic interlaminar space may be more difficult to be visualized clearly on the fluoroscopic screen due to the interference from the chest wall or shoulder girdle (Fig. 5).

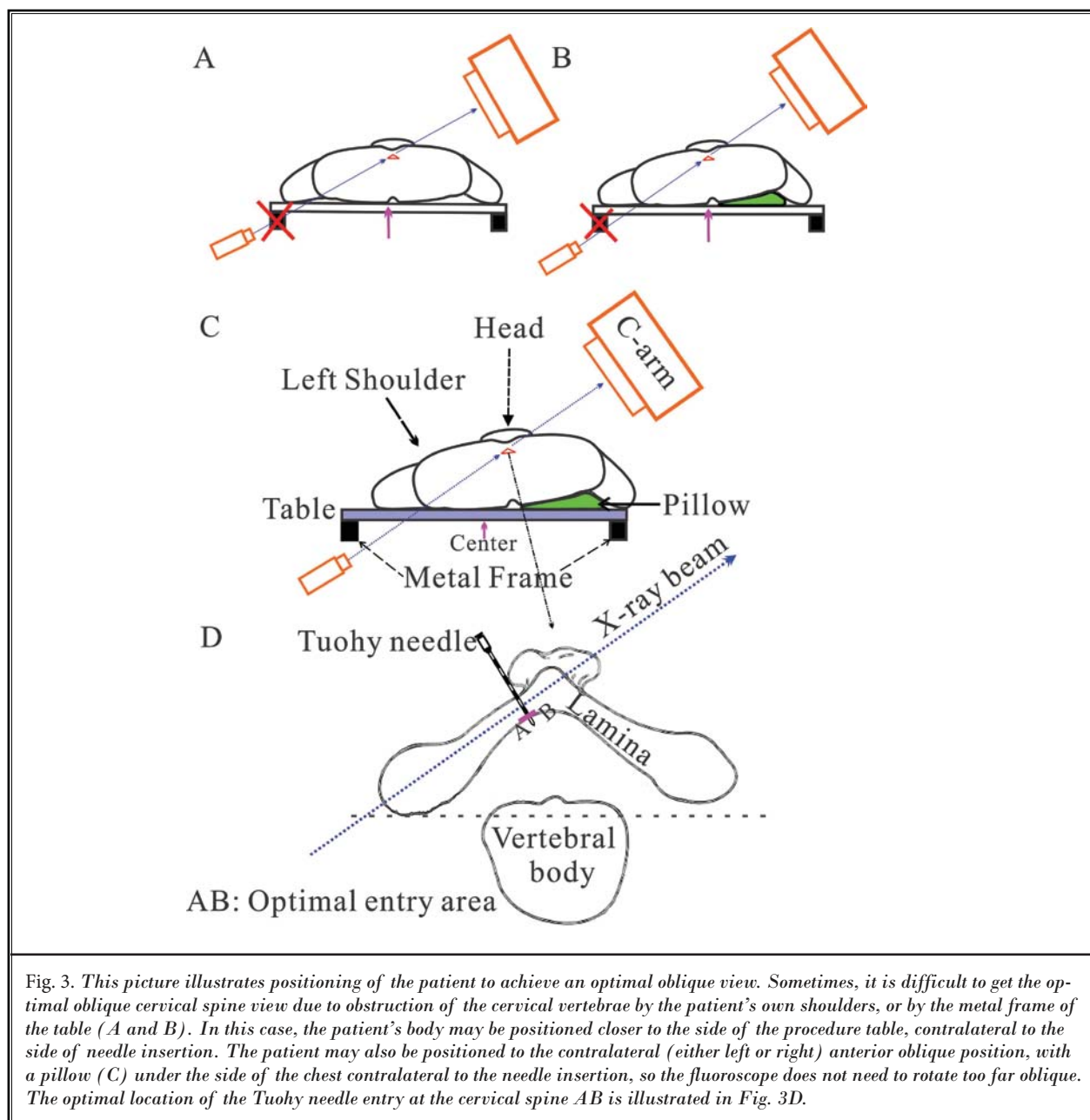
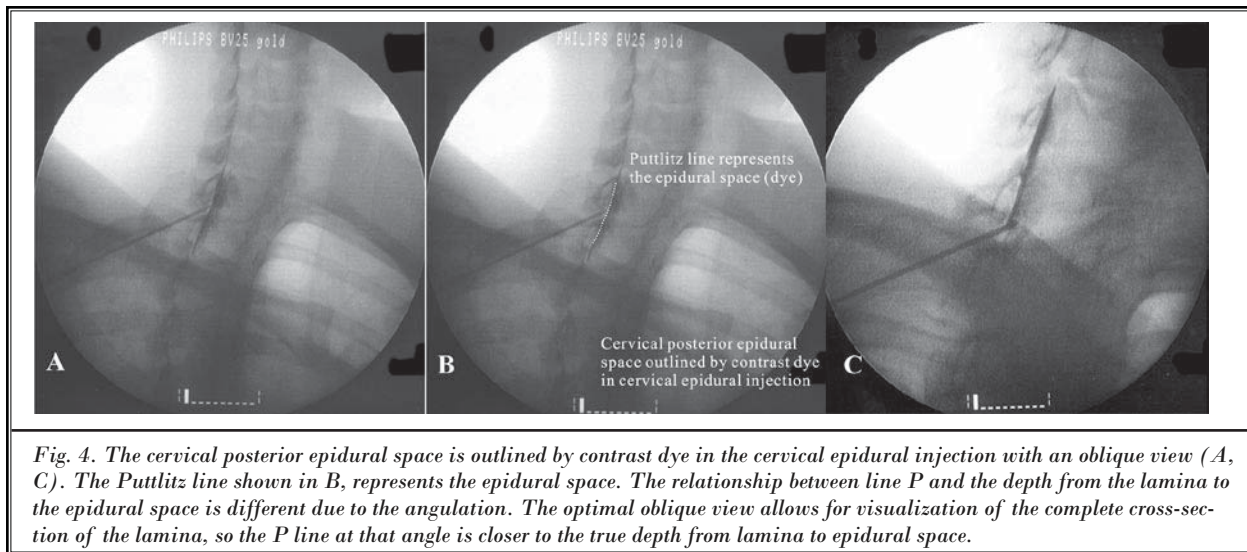
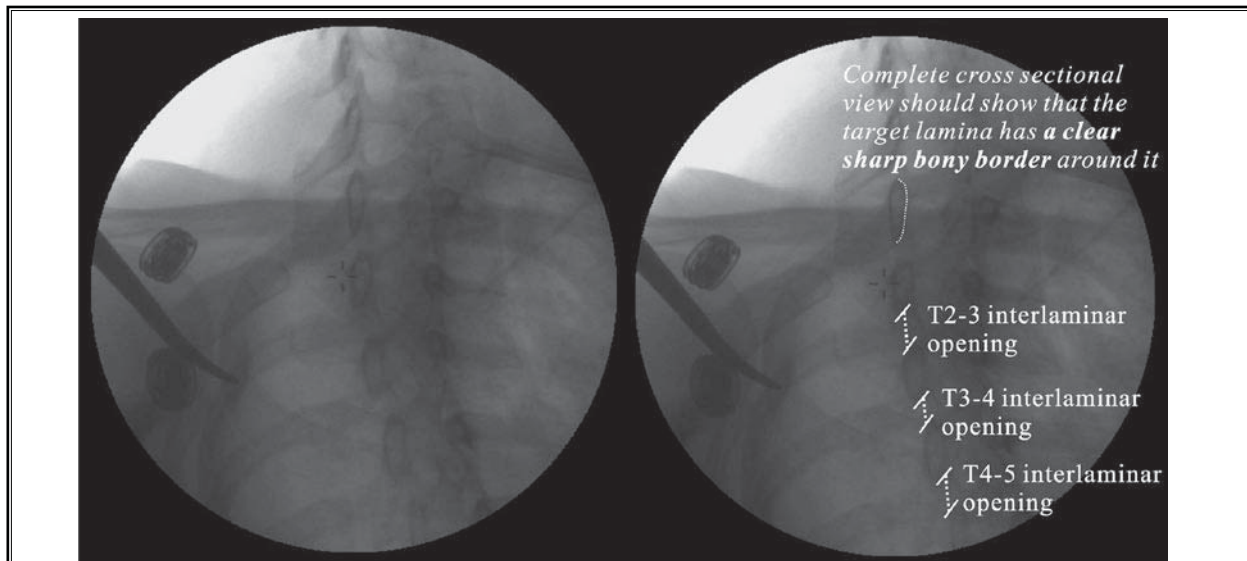


Fig. 3. This picture illustrates positioning of the patient to achieve an optimal oblique view. Sometimes, it is difficult to get the optimal oblique cervical spine view due to obstruction of the cervical vertebrae by the patient's own shoulders, or by the metal frame of the table (A and B). In this case, the patient's body may be positioned closer to the side of the procedure table, contralateral to the side of needle insertion. The patient may also be positioned to the contralateral (either left or right) anterior oblique position, with a pillow (C) under the side of the chest contralateral to the needle insertion, so the fluoroscope does not need to rotate too far oblique. The optimal location of the Tuohy needle entry at the cervical spine AB is illustrated in Fig. 3D.



*Fig. 4. The cervical posterior epidural space is outlined by contrast dye in the cervical epidural injection with an oblique view (A, C). The Puttlitz line shown in B, represents the epidural space. The relationship between line P and the depth from the lamina to the epidural space is different due to the angulation. The optimal oblique view allows for visualization of the complete cross-section of the lamina, so the P line at that angle is closer to the true depth from lamina to epidural space.*



*Fig. 5. The complete cross-sectional view of the laminae shows that the interlaminar openings of T2-5 are wide open. Technically, the SCS lead insertion can be done between these interlaminar spaces without difficulty on this patient. However, the SCS insertion in the thoracic spine is dependent on the patient's body habitus, C-arm, operative table, and the operator's experience; because the thoracic interlaminar opening is very narrow with a bigger angle. Whether it can be done or not is based on multiple factors of the patient's anatomy, the optimal oblique view to the patient, as well as the user's experience. The key is to use the optimal oblique view to precisely monitor that the needle tip is not inserted too deep inside of the epidural space.*

## Step 2

The cervical area is prepped and draped and the skin is anesthetized (Fig. 6). Next, a modified Tuohy needle from the SCS kit is inserted at least one level below the target interlaminar space and 1-2 cm away from midline, with the bevel facing up. The smaller entry angle of the needle to the spine will allow for easier lead

advancement and will lead to fewer potential problems with lead migration. The fluoroscope is turned to the optimal oblique view to ensure the needle is advanced toward the target interlaminar opening (Fig. 7). The needle is advanced toward the midline of the target interlaminar opening under alternate AP view (Fig. 8) and the optimal oblique view (Fig. 9).



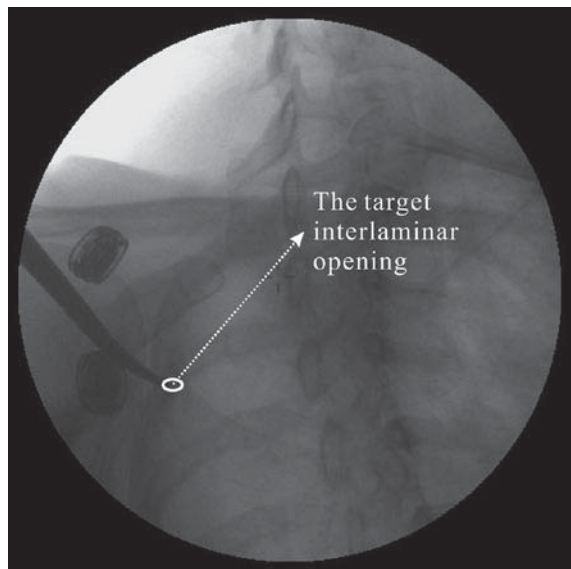


Fig. 6. The optimal oblique view of fluoroscopy is obtained to see the target interlaminar space and position the needle entry at skin. The skin entry point should be at least one level below and about 1-2 cm away from midline.

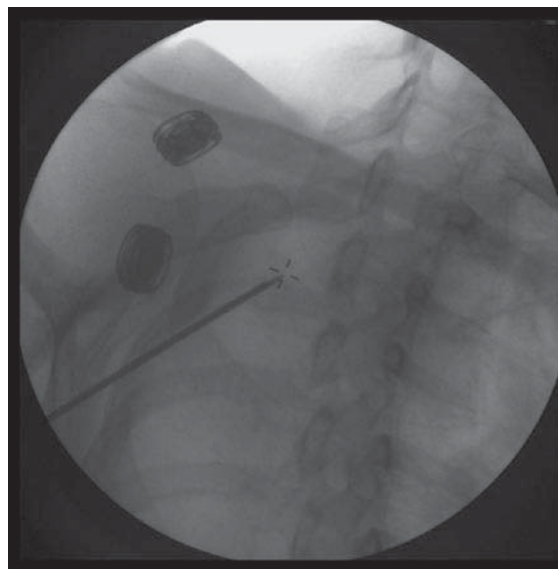


Fig. 7. The optimal oblique view is obtained to ensure that the needle is advanced toward the target interlaminar space.

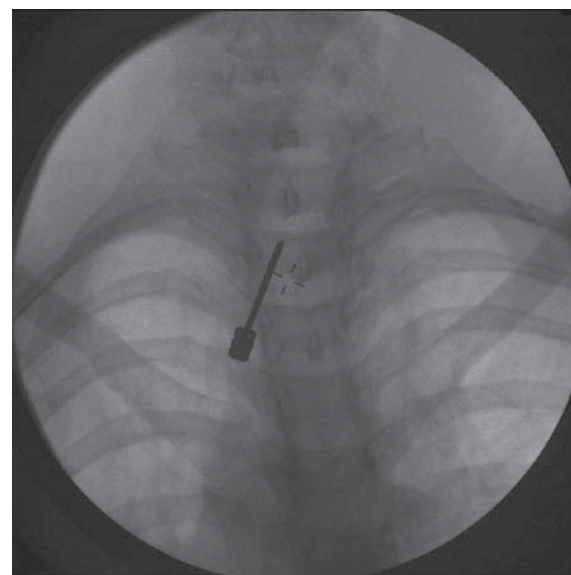


Fig. 8. The Tuohy needle is inserted and advanced toward midline under an AP view of fluoroscopy. The needle tip has just touched the lamina. The next step is that the needle is walked off from the lamina and advanced more medially towards midline under the visualization of the oblique view.

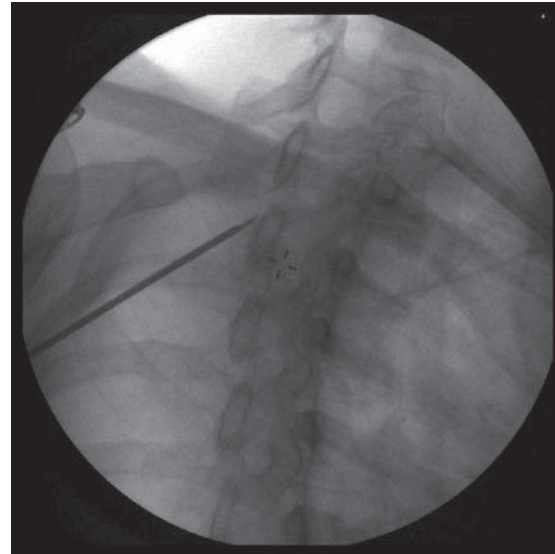
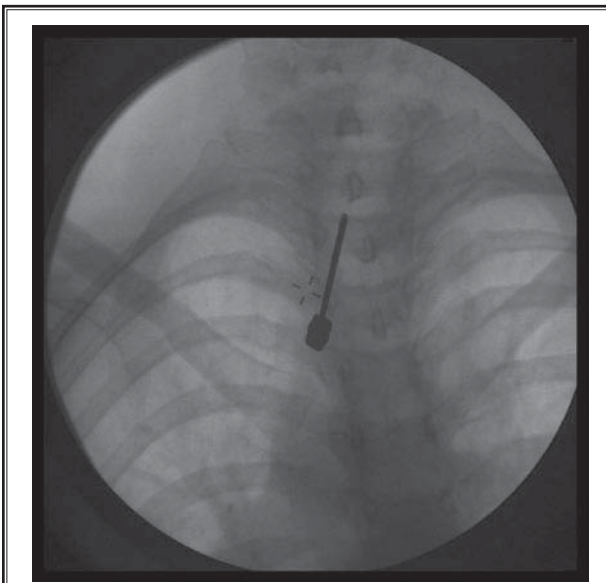


Fig. 9. The Tuohy needle lands on the target lamina under the optimal oblique view.

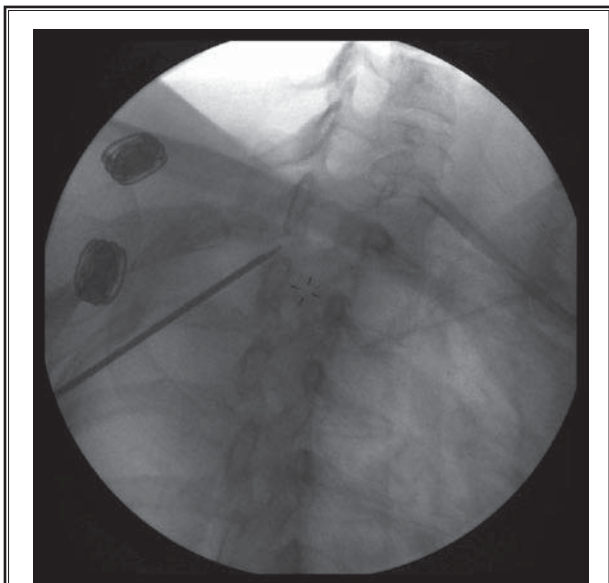
**Step 3**

The needle is then advanced with the bevel facing up, to land on the target lamina under the optimal oblique and AP views (Figs. 9,10). The needle is then advanced one millimeter at a time to walk off from the lamina through the target interlami-

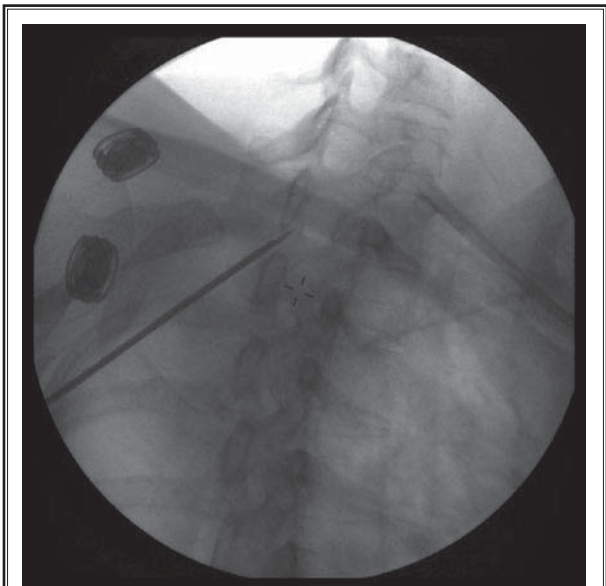
nar opening (LOR technique may be used if desired) (Figs. 11, 12). At this point, the stylet is removed and a spinal cord stimulator lead without a stylet is inserted in a gentle attempt to pass into the epidural space (Fig. 13).



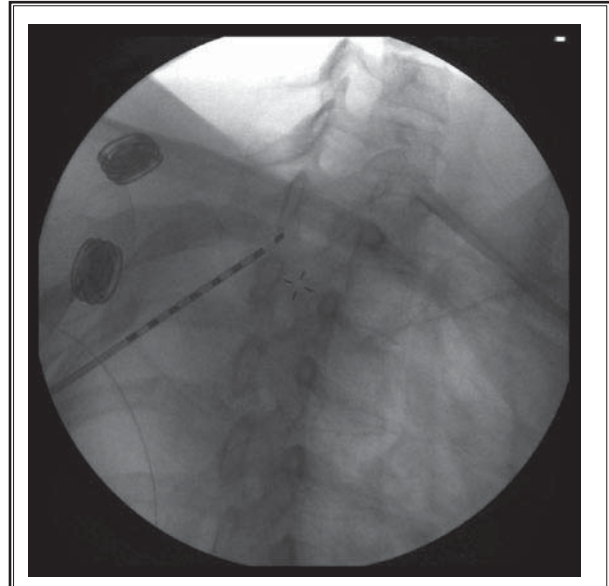
*Fig. 10. Intermittent AP views are used to ensure that the needle is advanced toward midline in AP view.*



*Fig. 11. The Tuohy needle walks off from the target lamina to the opening.*



*Fig. 12. The needle is advanced into the target interlaminar opening.*



*Fig. 13. At this point, the stylet is removed and a spinal cord stimulator lead without a stylet is inserted in a gentle attempt to pass into the epidural space.*

#### Step 4

If resistance is felt, the lead is withdrawn to the inside of the Tuohy needle. (Do not force the lead into the tissue or advance the Tuohy needle with the lead in place. Doing so will damage the outer surface of the lead.) The needle is advanced one millimeter at a time into the cervical spinal canal under oblique fluoroscopic visualization

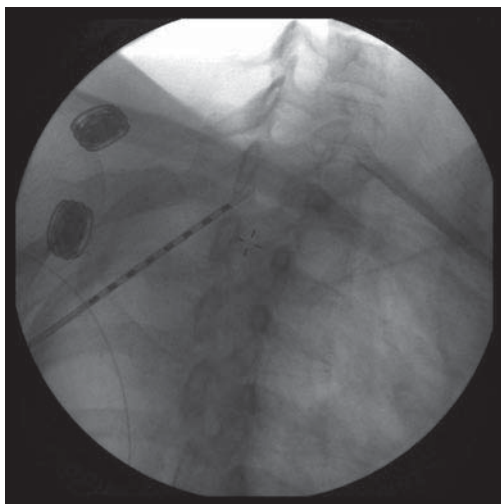


Fig. 14. *If resistance is felt, the lead is withdrawn to the inside of the Tuohy needle. (Do not force the lead into the tissue or advance the Tuohy needle with the lead in place. Doing so will damage the outer surface of the lead.) The needle is advanced one millimeter at a time into the cervical spinal canal under oblique fluoroscopic visualization.*

visualization (Fig. 14). The lead is then again advanced gently into the epidural space (Fig. 15). An intermittent AP view is used to ensure that the needle is advanced toward the midline of the spine.

#### Step 5

If resistance is experienced again, repeat this step one millimeter at a time (Fig. 16) until the Tuohy needle is successfully advanced into the epidural space (Figs. 17,18).

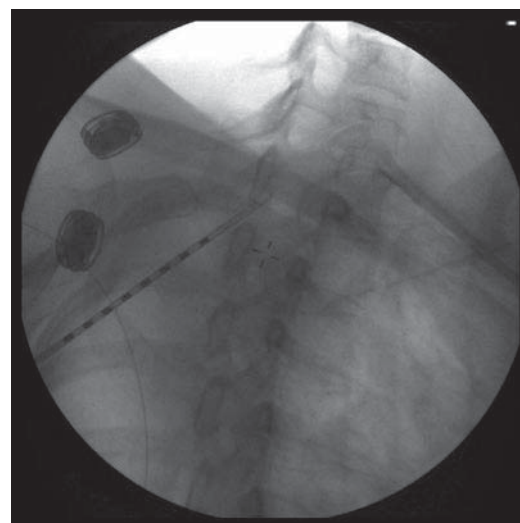


Fig. 16. *If resistance is experienced again, repeat this step one millimeter at a time until the Tuohy needle is advanced into the epidural space.*

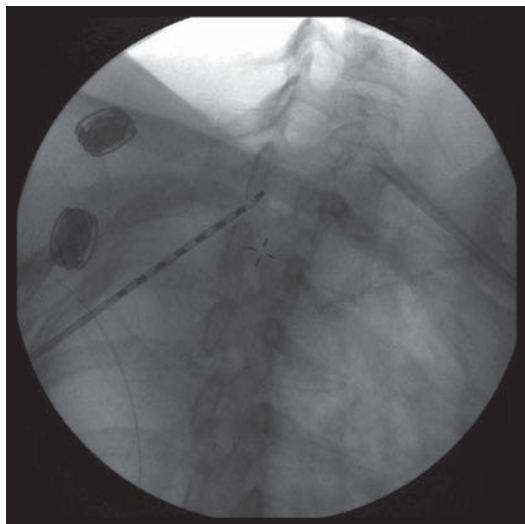


Fig. 15. *The lead is attempted to be advanced again gently into the epidural space. (An intermittent AP view is used to ensure that the needle is advanced toward the midline of spine.)*

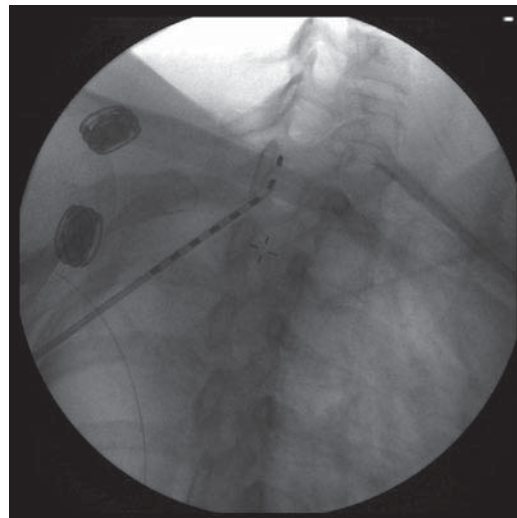


Fig. 17. *The SCS lead is advanced into the posterior cervical epidural space without the stylet.*

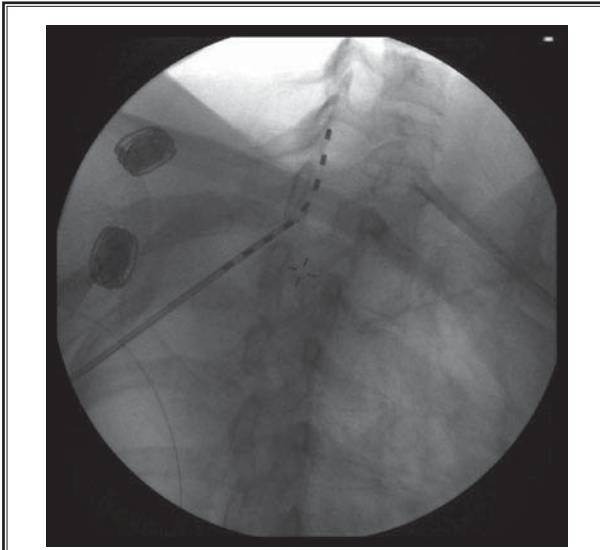


Fig. 18. *The SCS lead is advanced to a higher level in the posterior cervical epidural space.*

### Step 6

If the Tuohy needle tip is advanced too far into the cervical spinal canal (passing the Puttlitz line by more than 2-3 mm) (6) (Fig. 4) under the optimal oblique view of fluoroscopy, an AP view must be obtained to ensure that the tip of the needle is close to the midline of the target interlaminar space. If the needle is found lateral to the target epidural entry point, the needle should be withdrawn and repositioned toward the midline. Once the lead is in the epidural space, a series of AP and other views should be obtained and the lead should be positioned to the desired level.

### Step 7

A second lead may be placed in the same interlaminar space on the same side, either medial or lateral to the first needle. The first lead should be used as guidance for direction. Do not insert the second needle at a spot too close to the first needle at the skin level. This will ensure that the first needle will not be inadvertently advanced any deeper during manipulation of the second needle. The insertion of the second needle should follow the same technique as the insertion of the first needle.

Since the interlaminar space is often narrow in the cervical spine, the second lead should be inserted at the side of the first needle in most cases, but if there is a big interlaminar opening, the needle can be inserted behind (caudal to) the first lead. In that case, the first

lead is used as guidance for the second needle insertion. Also, the second needle should not be inserted too close to the first lead. The advantage of inserting the second needle behind or caudal to the first needle is that it will lift the first needle and not depress it. A depressed needle may accidentally cause injury to the thecal sac.

### DISCUSSION

We present an alternative approach for percutaneous lead placement. This alternate technique mainly utilizes an optimal oblique view under fluoroscopy to precisely monitor the Tuohy needle tip as it enters the epidural space. This technique may be used alone, or along with LOR (Fig. 1). Michael Whitworth (6) posted the Puttlitz line article to explain using the 30 degree oblique view of fluoroscopy to monitor needle position in cervical epidural injections (Fig. 4). However, the fluoroscope may rotate as far oblique as 60 degrees to see the complete cross-sectional view of the contralateral laminae in order to precisely monitor the needle insertion in the cervical spinal canal. One potential advantage of this approach is that one can visualize the needle tip and be able to gauge its depth in real time while entering the epidural space. A second potential advantage of this technique is the ability to use the same target interlaminar space repeatedly for subsequent lead placement, or for lead reinsertion, since this method does not rely on an intact ligamentum flavum for epidural placement.

The traditionally instructed method for percutaneous cervical spinal cord stimulator lead placement promotes the use of an LOR technique under anteroposterior (AP) fluoroscopic guidance to assure midline lead placement, as well as proper entry into the epidural space.

This technique relies on the denseness of the ligamentum flavum and the sudden absence of resistance experienced during ballottement of a syringe filled with saline (with or without an air bubble) or air once through the ligament (3,4). Occasionally it is difficult to use LOR with certain clinical circumstances such as obesity, patients with an abnormal interlaminar opening at the anteroposterior fluoroscopic views, or patients with changes to the integrity of the ligamentum flavum as may occur with previous spinal surgery. Further, a false LOR may occur between changes in fascial planes that may lead to uncertainty of needle depth (5).

It is more difficult to access the cervical epidural space with LOR due to the above reasons. The best way



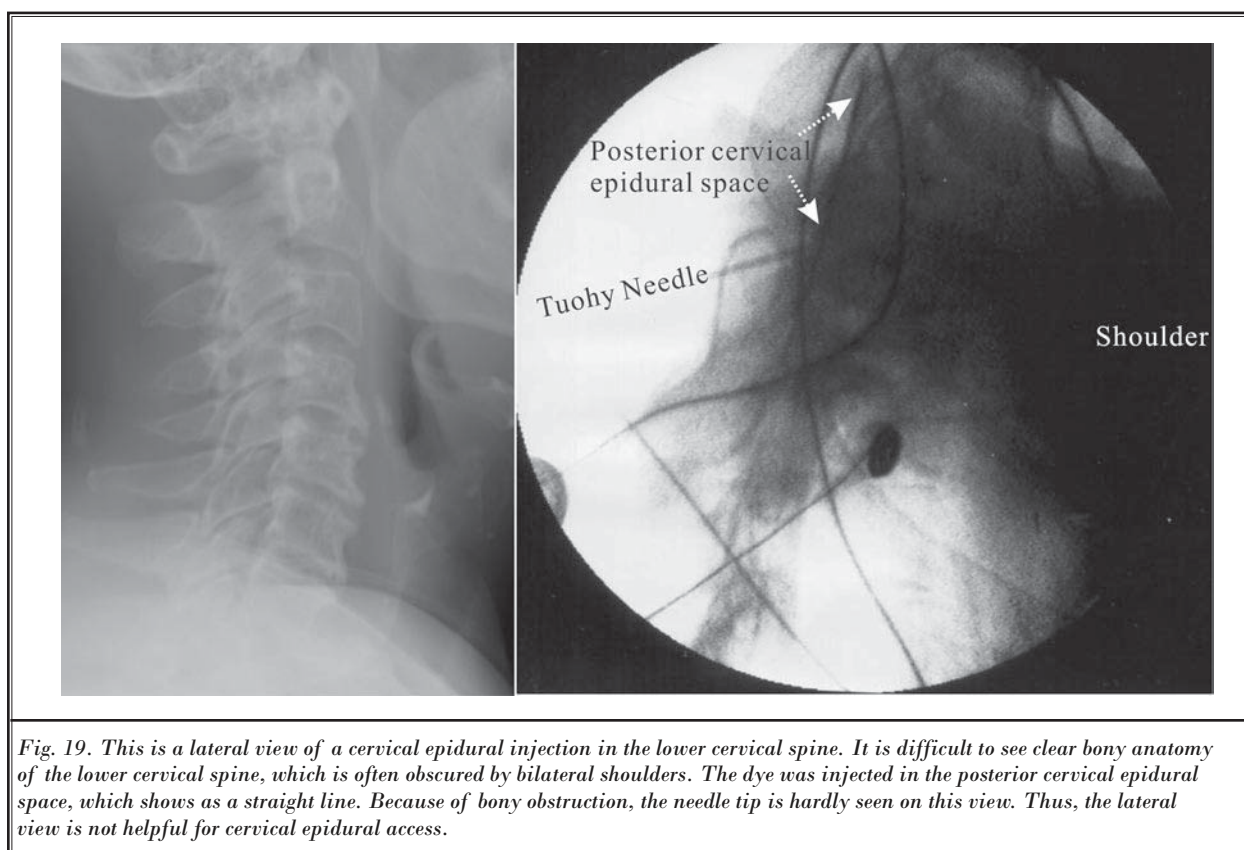
to monitor epidural access is to visualize needle movement related to bony landmarks. However, the lateral view is unable to provide a clear view of the lower cervical and upper thoracic spines because the patient's shoulders always block the view of the spine around the C7-T3 levels in lateral view (Fig. 19). It is possible to see the lower cervical spine if the patient's arms are pulled down forcefully. However, it is not safe to do this while there is a needle inserted into the cervical spinal canal. Thus, the optimal view to monitor the cervical epidural access is to visualize the Tuohy needle walking off the lamina in its cross-sectional view (oblique view) (Fig. 2). It is very important to place the patient in an optimal position to achieve the best fluoroscopic view; this will allow seeing the cross-sectional view of the contralateral laminae, where the needle is going to be inserted (Fig. 3).

The optimal view may require the fluoroscope to be rotated obliquely, close to the lateral view. However, sometimes it is difficult to obtain the optimal oblique view to visualize the complete cross-section of the contralateral laminae. This is due to the shoulders or metal

bar at the side of the table obscuring the view of the cervical spine. In this case, the patient's body should be positioned closer to the side of the procedure table, contralateral to the needle insertion (Fig. 3) in order to avoid obstruction of the oblique fluoroscopic view.

The patient may also be positioned to the left anterior oblique (LAO) position with a pillow placed under the right side of the chest (Fig. 3) if the needle is to be inserted left of the cervical spine. This way, the fluoroscope does not need to be rotated too far obliquely. If the needle is to be placed in the right side of the cervical spine, a pillow should instead be placed under the left side of the chest. The patient will now be placed in the right anterior oblique (RAO) position.

The key to this approach is positioning the patient before the procedure starts. The alternate AP and complete cross-sectional views of adjacent laminae should be obtained while the needle is inserted into the cervical spine. This approach is not meant to change the user's way, but is meant to add another layer of safety for cervical SCS lead insertion. Table 1 outlines the differences between the traditional LOR technique and this approach.



*Fig. 19. This is a lateral view of a cervical epidural injection in the lower cervical spine. It is difficult to see clear bony anatomy of the lower cervical spine, which is often obscured by bilateral shoulders. The dye was injected in the posterior cervical epidural space, which shows as a straight line. Because of bony obstruction, the needle tip is hardly seen on this view. Thus, the lateral view is not helpful for cervical epidural access.*

Table 1. Comparison of the Loss of Resistance technique with the direct visualization technique

Technique	Loss of Resistance Technique	Direct Visualization Technique
Needle insertion	Paramedian approach	Same as paramedian approach
Monitoring needle tip	Lateral view or less optimal oblique view of fluoroscopy 1. There are no clear bony landmarks to indicate the lower cervical or upper thoracic posterior epidural space. 2. Shoulders will obscure the lower cervical and upper thoracic spine	Optimal oblique view of fluoroscopy 1. Uses complete cross-sectional view to monitor the needle tip, related to the lamina. (It has been described in cervical epidural space as the Puttlitz line) 2. Eliminates the shoulders from the view
Locating epidural space	Use loss of resistance technique without knowing exactly the relative depth of the needle tip inside the cervical canal	1. Advance the needle one mm at a time after needle is inserted close to the interlaminar opening, and use the lead to access the epidural space 2. Use the optimal oblique view to make sure that the needle is advanced to proper depth
Accessing epidural space	Syringe is removed and a lead is inserted	A lead without the stylet is inserted.
Advancing lead inside of cervical epidural space	Originally taught approach	Same as paramedian approach
Requirements	1. Precise manipulation of needle. 2. Good experiences with LOR.	1. Precise manipulation of needle. (When the needle accesses the epidural space, any deviation from the optimal target epidural entry point may lead to severe problems) 2. Thorough knowledge of the anatomy of cervical spine and fluoroscopy
Common problems	There are many noted problems with this approach, which is dependent on the user. (It may be difficult to use the loss of resistance technique to access the epidural space due to the differences between patient's body habitus)	1. The needle is inserted too lateral to the target epidural entry point or right at the midline of the epidural access. In these cases, the needle tip will appear deeper than usual on the oblique view. 2. A large entry angle of the needle to the cervical spine in the sagittal plane may cause depressive tension from the lead to the thecal sac and a bigger turn of the lead from the angulated needle to the posterior cervical epidural space. This may cause the lead to slide down to the anterolateral aspect of the cervical epidural space.
Contraindications	As taught	1. Same as paramedian approach 2. Cervical spinal stenosis 3. Do not use unless the fully complete cross-sectional view of target laminae is obtained. 4. Lapse of attention may cause serious complications, such as death, paraplegia, etc. 5. Remove the needle and switch to the loss of resistance technique approach at another level if any difficulty is encountered
Risks and potential complications	As taught	1. Same as paramedian approach 2. Paraplegia, death, and other serious complications from carelessness
Benefits	As taught	1. Same as paramedian approach 2. The needle may re-enter the same level, same side of the target interlaminar opening for needle entry adjustment without loss of resistance technique
Recommendations	Caution and experiences needed	1. Anatomical knowledge of cervical spine and caution is needed 2. If the user has not had sufficient experience with this approach or is new to cervical SCS lead insertion, with caution, use this approach along with the loss of resistance technique.

## KEY POINTS

---

### 1. Needle insertion and advancement

The insertion and advancement of the Tuohy needle in this approach is the same as in the traditional paramedian approach.

### 2. Important things to know before starting

The main advantage of this approach is the use of the optimal oblique view of fluoroscopy to visualize the relative needle depth to the target lamina.

- a. It is very important to get a true cross-sectional view of the target lamina, in which the lamina has a definitive dense border completely around it. If the dense border on fluoroscopic view cannot be obtained, the C-arm should be repositioned until the complete cross-sectional view is visualized. This view will provide the relative needle depth to the lamina in the oblique direction; however, it will not give the true depth of the cervical canal in the sagittal plane. Keep in mind that it may or may not amplify the distance between the needle and the lamina, depending on the view of the lamina obtained. The reason is that laminae are often not absolutely straight at their border.
- b. It is also important to obtain the view at the farthest oblique (as close as lateral view) position. In this view, the visualized depth of the cervical canal will be closest to its true depth.
- c. Keep in mind that an oblique view will not show a true AP distance of the canal. Most of the time, this view may not be able to show the anterior border of the cervical canal. It uses the relative distance relationship between the needle and the target lamina to help.

### 3. Position patient and C-arm before starting

Before the procedure is started, an important step is to position the patient and fluoroscope to achieve the optimal oblique view. This allows for visualizing the target lamina in the cross-sectional view with fluoroscopy. Do not use this approach unless the patient is positioned properly. Otherwise, a satisfied oblique view may be unobtainable after the needle is inserted into the patient.

### 4. Needle tip position upon accessing the epidural space

Since the middle portion of the lamina is relatively straight (Fig. 3D) and the true cross sectional view of

fluoroscopy cannot give appropriate estimation of the depth at midline of the cervical canal, the needle tip is not recommended to be advanced right in the midline or too lateral to the spine. The best needle entry point is slightly off from the midline (Fig. 20). The exact needle tip entry point depends on the patient's pain problem, the regional anatomy of the patient's body, and the number of leads planned.

- a. If the needle entry point at the epidural space is too close to midline, the lead may be easily advanced to the anterior aspect of the contralateral side of the cervical spinal canal (Fig. 21).
- b. If the needle entry point is inserted too lateral to midline, the lead may also be easily advanced to the anterior aspect of the same side of the cervical spinal canal (Fig. 21).
- c. The needle will appear deeper than where it should be on the optimal oblique view of fluoroscopy (Fig. 22) if it is advanced too laterally from the midline, or if the needle tip is right at the midline. This is due to the realively triangularly oval shape of the cervical spine. The optimal area of needle entry in the cervical epidural space is shown in Fig. 3D.

### 5. The limit of the depth of the needle in the cervical canal

This approach adds an optimal fluoroscopic oblique view while the needle is inserted in the cervical spine for SCS lead insertion. It may add another layer of safety to the needle insertion. However, it will not prevent complications if the user is careless, as this oblique view does not give the true depth of the cervical spine at an oblique angle.

- a. It is important to get intermittent AP and optimal oblique views under fluoroscopy while the needle is being inserted in the cervical spine. The needle tip location and depth should be monitored very closely. The needle tip should not be advanced deeper than 2-3 mm below the joined line from the lower border of the adjacent upper and lower laminae (6). If the cervical epidural space cannot be accessed when the needle is advanced beyond that point, an AP view of fluoroscopy should be obtained to make sure that the needle does not deviate too lateral. If the epidural space still cannot be accessed beyond the 2-3 mm of the needle depth below the Puttlitz line, the Tuohy needle should be removed and the LOR technique should be used at another level.
- b. This approach is not the standard of care at the

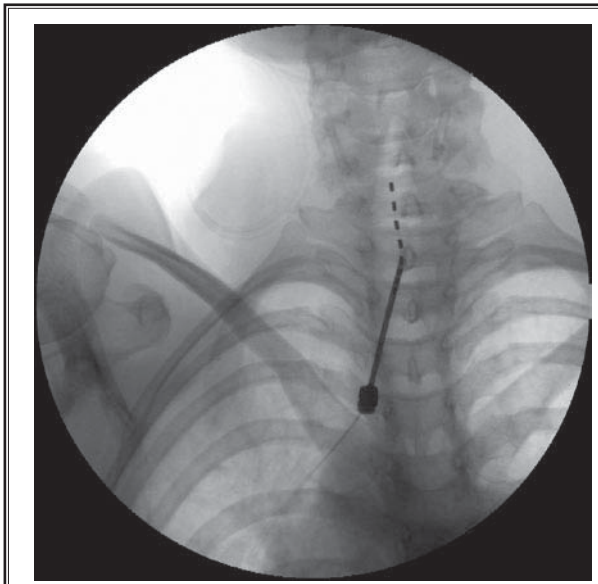


Fig. 20. The ideal epidural entry point is slightly off from midline. The exact needle tip entry point depends on the patient's pain problem, the regional anatomy of the patient's body, and the number of leads planned. In this patient's case (left occipital neuralgia), the needle tip location was slightly off from the midline. The SCS lead was advanced smoothly cephalad without a sharp curve outside of the needle. The lead was advanced to its target, left C2 level, for the SCS implantation. Importantly, keep in mind that in this case, the lead was advanced without the stylet. For patients with symptoms of cervical radicular pain, the leads should be directed to the midline with a curved stylet tip.

present time. The LOR technique for cervical SCS needle placement should be learned and mastered first. While doing cervical epidural access with LOR technique during epidural injections or SCS needle placements, a novice should add the optimal oblique view to get familiar with the needle tip position in the cervical canal related to the target lamina when the epidural space is accessed by the needle. Many observations are required to build up the experience for estimating the needle position to the invisible cervical epidural space at the lamina.

### 6. The interlaminar openings used for this approach

- It is suggested to access the C7-T1 and T1-T2 interlaminar spaces. The thoracic spine has less range of motion than the cervical spine due to the enforcement of the ribs. Theoretically, the T1-T2 level

may be the best opening to use due to the relatively fixed structure of the spine with the ribs. There is less ROM at this level, as well as less interference from the bony structure of the chest and shoulder girdle. It also makes the lead relatively stable with the patient's activity.

- The interlaminar space at T2-T3, T3-T4, and T4-T5 levels may also be used as an epidural access with this approach, if the optimal oblique view of fluoroscopy to the target interlaminar opening can be obtained. It is important to obtain a complete view with the clear, dense, and complete border of adjacent laminae on the screen before the needle is inserted. If the view can show the complete cross-section of the target lamina clearly, theoretically, epidural access can be tried by using this approach with caution.

### 7. The needle entry angle to the cervical spine in the sagittal plane

- The cervical spine has a unique anatomy. It has a smaller interlaminar opening view in the AP direction under fluoroscopy. The entry angle of the SCS needle to the cervical spine in AP direction is usually larger than at the thoracic region. The SCS lead from the larger entry angle of the needle in AP direction causes more direct tension to the thecal sac and makes a bigger turn before it slides into the posterior epidural space due to the rigidity of the lead. The thecal sac responds with more recoiling tension (Fig. 23), and this makes the SCS lead relatively unstable. The lead with a larger entry angle migrates more easily with activity.
- With the oblique approach, the user should see the interlaminar opening on the true cross sectional view before inserting the needle. It allows the user to estimate the skin entry point at the smallest possible angle, based on the observation of the needle at the skin related to the target interlaminar opening on the view (Fig. 6). The smaller the entry angle of the needle, the easier it is to advance the SCS lead to the target spinal level. This results in less tension between the lead and the thecal sac and spinal canal, which makes the lead less prone to migration.

### 8. Needle entry angle to midline of the spine in the coronal plane

- The paramedian approach is often used in SCS needle placement because the spinous processes in this approach do not block the needle pathway at a smaller entry angle. The problem with the para-



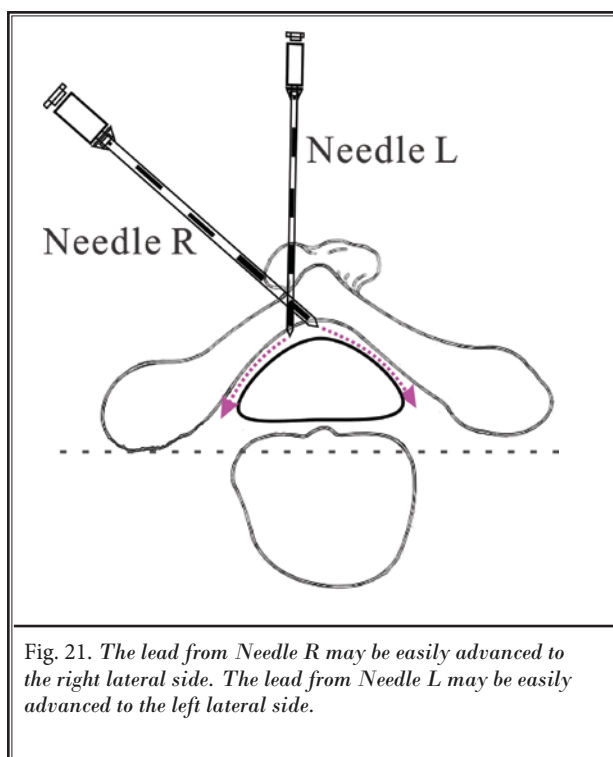


Fig. 21. The lead from Needle R may be easily advanced to the right lateral side. The lead from Needle L may be easily advanced to the left lateral side.

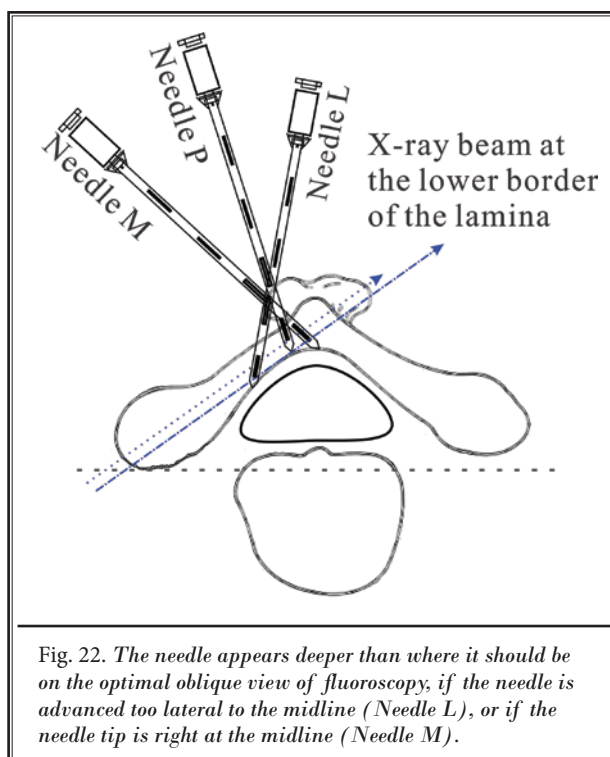


Fig. 22. The needle appears deeper than where it should be on the optimal oblique view of fluoroscopy, if the needle is advanced too lateral to the midline (Needle L), or if the needle tip is right at the midline (Needle M).

median approach is that the interlaminar opening often seems smaller in the cervical region, due to the unique bony anatomy in the cervical spine in the AP view of fluoroscopy. The needle entry angle to the spine in the AP direction is often bigger than it is at the lower thoracic region, due to visualization problems of fluoroscopy.

- b. Because of the triangularly oval shape of the cervical canal, a lead with a large entry angle to the spine in a lateral direction may easily slide to the contralateral side of the spinal canal (foraminal region). This occurs especially when the needle enters into the cervical spinal canal at midline in the paramedian approach (Fig. 21).
- c. If the needle has a very small angle to the cervical spine in the coronal plane as it enters into the epidural space too lateral to midline of the cervical spine, it may slide laterally to the same side of the cervical canal (Fig. 21).

### 9. SCS lead migration

- a. Lead migration occurs more frequently after SCS implantation in the cervical, rather than in the thoracic region. Theoretically, the lead migration often happens in the upper cervical region, as there

is more room in the lateral side of the upper cervical canal. In addition, the upper cervical region allows for a wide range of motion (the atlantoaxial joints provide 50% of all cervical rotation, allowing 40° of rotation to each side). The increased range of motion (such as rotation) of the upper cervical spine predisposes the distal portion of the SCS lead to migration in the cervical spinal canal. When a patient, who just underwent cervical SCS implantation, rotates or flexes/extends his head for activity, the lead tends to move to the area where it has the least tension. The lead migration will decrease as time goes by due to fibrous tissue built up around the lead to stabilize it. In the thoracic region, the rib cage helps prevent rotational movements and limit the flexion and extension movement. However, the flexion and extension of the thoracic and lumbar spines may still provide a small chance for SCS lead migration. Generally speaking, if the SCS lead is implanted in the same optimal condition, SCS lead migration happens more frequently after cervical SCS implantation, rather than thoracic SCS implantation.

- b. Many factors affect migration, such as lead/needle entry angle and location; the tension between the

SCS lead, the cervical spinal canal and thecal sac along its course; the anchor location/orientation; surgical skills; and the patient's activity. The patient's activity may contribute as a major factor for lead migration. Some factors can be controlled, but some may not be controlled due to the patient's body habitus, anatomic differences, pathologic changes, the level and type of activity, etc. No studies have been performed to discuss the definite major factors affecting SCS lead migration, or the technique or approach used effectively to prevent it.

- c. The best technique to prevent SCS lead migration should entail the following steps:
  - i. Make a smaller entry angle with the lead/needle. This will create less tension on the SCS lead to the spinal canal and thecal sac at the entry point, which will result in a less rigid curve of the lead in the cervical spinal canal (Fig. 24).
  - ii. Position the anchor along the direction of the lead. This will create less tension on the SCS lead outside of the spinal canal due to the less sharp curve of the lead.

- iii. Allow for a smooth course of the lead above the anchor in the SCS implantation. The lead will have a less sharp curve and thus will be under less tension, which will make it relatively stable.
- iv. It is important to utilize good surgical skills for the proper fixation of the anchors, which will make the lead less mobile.
- v. The patient should be told not to perform extreme cervical range of motion after SCS implantation.

The above efforts should be tried in every case; however, migration may still happen due to other unforeseen reasons. More studies on SCS lead migration are needed in the future to improve the success rate of SCS implantation.

### 10. Lumbar epidural injections with the optimal oblique view

This technique can also be utilized for difficult lumbar epidural injections along with the LOR technique under optimal oblique fluoroscopic guidance. It may help to monitor the needle tip location (Figs. 25,26) during the injections.

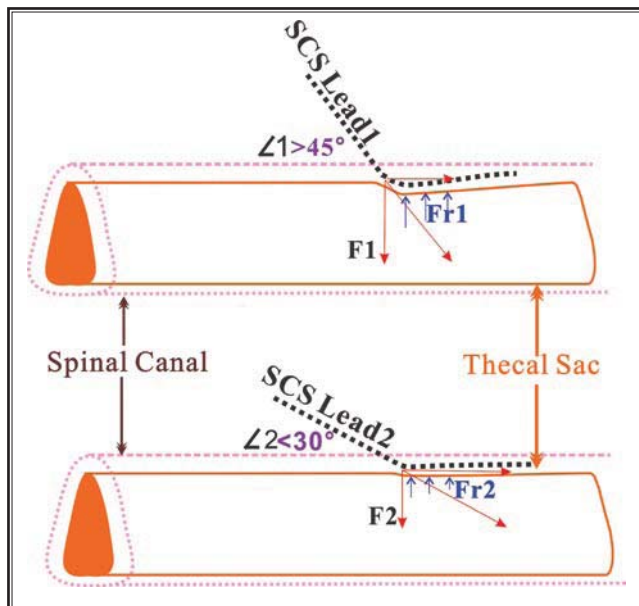


Fig. 23. The SCS lead is advanced into the posterior cervical epidural space. The SCS lead 1 has a larger angle ( $L1$ ) to the spine and causes more tension ( $F$ ) to the thecal sac and makes a bigger turn before it is inserted in the posterior epidural space, when compared with the SCS lead 2. ( $L1 > L2$ ;  $F1 > F2$ ) The thecal sac responds to the tension with more recoiled force ( $Fr$ ) from the lead 1 than the lead 2. [ $F1 > F2$ ;  $Fr1 > Fr2$ ]

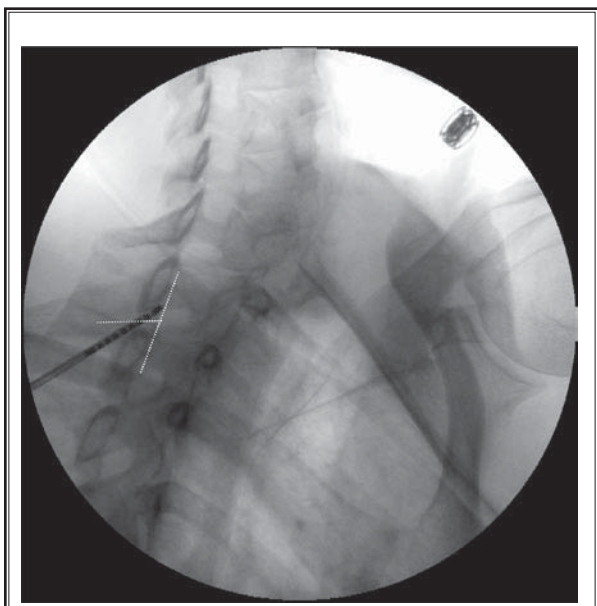


Fig. 24. Best efforts were made to ensure that the smallest angle in the sagittal plane was obtained by the needle during the SCS implantation in this case. The needle touched both the upper and lower laminae at the target opening with the smallest angle in the sagittal plane.

### 11. The optimal oblique view during SCS needle placement in the lower thoracic region

This optimal oblique view can also be used for SCS needle placement in the lower thoracic region (Fig. 27) to check the needle tip related to the laminae. However, it may be very difficult to obtain a clear oblique view due to the bony interference from ribs and the

larger body size in the thoracic region than the cervical region, which makes it less useful than a lateral view in the direct visualization approach (7). In the lower thoracic region, a lateral view provides a better view of the depth of the spinal canal for the SCS needle placement because there are no shoulders or pelvic bone to block the view of the spinal canal.

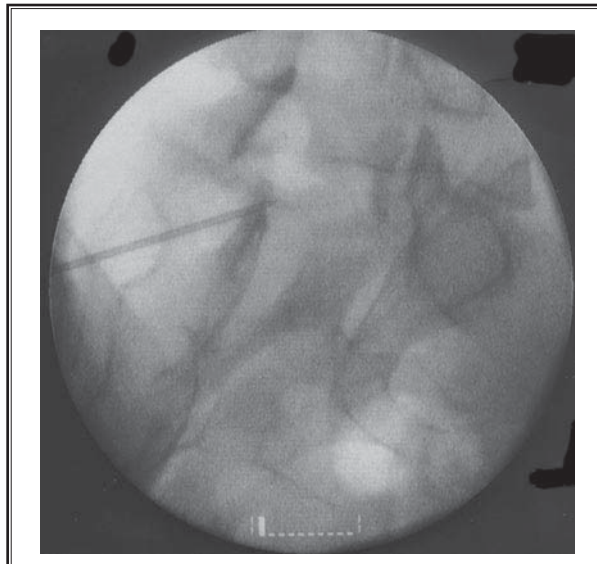


Fig. 25. The optimal oblique view is used to monitor the needle tip position in a lumbar epidural injection.

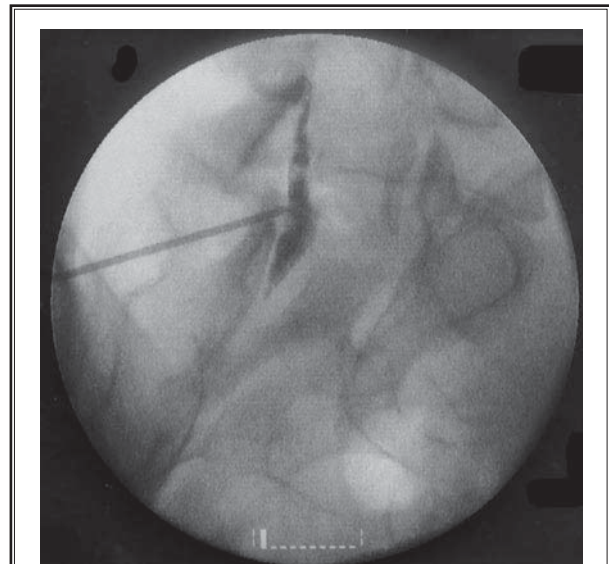


Fig. 26. The contrast dye is injected into the posterior lumbar epidural space.

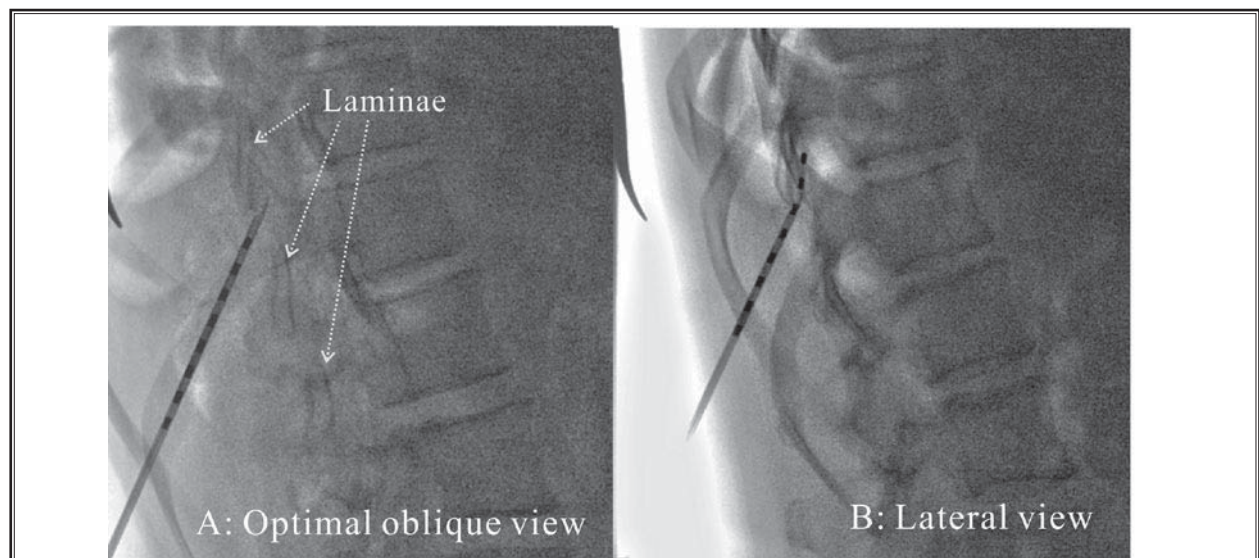


Fig. 27. A. An optimal oblique view for the SCS needle placement in the lower thoracic region, inserted under fluoroscopic guidance. This view demonstrates the relationship between the Touhy needle and the laminae, while the thoracic posterior epidural space is accessed. B. A lateral view for the same needle placement with an SCS lead inserted. The lateral view is easy to obtain and has less bony interference.

12. There are still many questions and problems regarding SCS trial and implantation, which require much more space to discuss in detail. The discussion to address these issues is beyond the scope of this report.

## CONCLUSIONS

This fluoroscopic technique provides an alternative means for placing percutaneous cervical SCS leads with or without the use of the traditional LOR technique. The optimal oblique view under fluoroscopy allows for visualization of the precise relation of the needle tip to

the target lamina, which serves as a bony landmark in cervical spinal cord stimulator lead insertion. The main advantage of this approach is the ability to visualize the relative needle depth to the target lamina. The risks, potential complications, and benefits from this approach are beyond the scope of this article. Readers should carefully evaluate this approach with their medical knowledge and experience to understand the risks, benefits, and potential complications one may encounter in this approach before employing it in their clinical work.

---

## REFERENCES

1. North RB, Kidd DH, Lee MS, Piantadosi D. Spinal cord stimulation versus reoperation for the failed back surgery syndrome: Initial results. *Stereotact Funct Neurosur* 1994; 62:267-272.
2. Kumar K, Taylor RS, Jacques L, Eldabe S, Meglio M, Molet J, Thomson S, O'Callaghan J, Eisenberg E, Milbouw G, Bushner E, Fortini G, Richardson J, North RB. Spinal cord stimulation versus conventional medical management for neuropathic pain: A multicenter randomized controlled trial in patients with failed back surgery syndrome. *Pain* 2007; 132:179-188.
3. Shenouda PE, Cunningham BJ. Assessing the superiority of saline versus air for use in the epidural loss of resistance technique: A literature review. *Reg Anesth Pain Med* 2003; 28:48-53.
4. Schier R, Guerra D, Aguilar J, Pratt GF, Hernandez M, Boddu K, Riedel B. Epidural space identification: A meta-analysis of complications after air versus liquid as the medium for loss of resistance. *Anesth & Analg* 2009; 109:2012-2021.
5. Gupta B, Sharma S, D'souza N, Kaur M. Pseudo loss of resistance in epidural space localization. *Saudi J Anaesth* 2010; 4:117-118.
6. Whitworth M. Puttlitz line: A rapid and reproducible fluoroscopic needle endpoint for cervical interlaminar epidural steroid injections. Posted at the 24th Annual Meeting of The American Academy of Pain Medicine; February 13-16, 2008; Orlando, FL. <http://aapm.confex.com/aapm/2008am/techprogram/P2979.HTM>.
7. Zhu J, Falco F, Onyewu C, Josephson Y, Vesga R, Jari R. Alternative Approach To Needle Placement In Spinal Cord Stimulator Trial/Implantation. *Pain Physician* 2011; 14:45-53.