

Observational Study

## New Image-Guided Ultra-Minimally Invasive Lumbar Decompression Method: The *mild*® Procedure

Timothy R. Deer, MD<sup>1</sup>, and Leonardo Kapural, MD, PhD<sup>2</sup>

From: <sup>1</sup>Center for Pain Relief, Charleston, WV, and  
<sup>2</sup>Cleveland Clinic, Cleveland, OH.

Dr. Deer is Director, Center for Pain Relief and Clinical Professor, Department of Anesthesiology, West Virginia University, Charleston, WV.

Dr. Kapural is Director of Pain Management Clinical Research in the Department of Pain Management at Cleveland Clinic, Cleveland, OH; and Associate Professor of Anesthesiology at Cleveland Clinic Lerner College of Medicine, Case Western University, Cleveland, OH.

Address correspondence:  
Timothy R. Deer, MD  
Center for Pain Relief  
400 Court Street, Suite 100  
Charleston, WV 25301  
E-mail: DocTDeer@aol.com

Disclaimer: Dr. Deer is a Consultant and Educational Advisor to VERTOS Medical, Inc. Conflict of interest: None.

Manuscript received: 010/09/2009  
Revised manuscript received:  
11/25/2009  
Accepted for publication:  
01/04/2010

Free full manuscript:  
[www.painphysicianjournal.com](http://www.painphysicianjournal.com)

**Background and Objectives:** Lumbar canal stenosis is a common source of chronic low back and leg pain. Minimally Invasive Lumbar Decompression (*mild*®) is a new minimally invasive treatment for pain relief from symptomatic central lumbar canal stenosis. The procedure involves limited percutaneous laminotomy and thinning of the ligamentum flavum in order to increase the critical diameter of the stenosed spinal canal. The objective of this technical report is to evaluate the acute safety of the *mild* procedure.

**Methods:** Manual and electronic chart survey was conducted by 14 treating physicians located in 9 U.S. states on 90 consecutive patients who underwent the *mild* procedure. Patients within local geographical practice areas were selected in keeping with product Instructions For Use. Those patients requiring lumbar decompression via tissue resection at the perilaminar space, within the interlaminar space and at the ventral aspect of the lamina were treated. Data collected included any complications and/or adverse events occurring during or immediately following the procedure prior to discharge.

**Results:** Of 90 procedures reviewed, there were no major adverse events or complications related to the devices or procedure. No incidents of dural puncture or tear, blood transfusion, nerve injury, epidural bleeding, or hematoma were observed.

**Limitations:** Data were not specifically collected; however, regardless of difficulty, in this series none of the procedures were aborted and none resulted in adverse events. Efficacy parameters were not collected in this safety survey.

**Conclusions:** This review demonstrates the acute safety of the *mild* procedure with no report of significant or unusual patient complications. To establish complication frequency and longer-term safety profile associated with the treatment, additional studies are currently being conducted. Survey data on file at Vertos Medical, Inc.

**Key words:** Spine, decompression, fluoroscopy, *mild*, stenosis, ligamentum

**Pain Physician 2010; 13:35-41**

Lumbar canal stenosis (LCS) is a very common source of lower back and leg pain. Current estimates place the number of Americans suffering from lumbar spinal stenosis at 400,000 (1), although this does not account for those who choose not to seek care and use self limited restriction as a method of treating their symptoms. The

pathophysiological changes of LCS include narrowing of the central spinal canal or its recesses with compression of the nerve roots in the central spinal canal, the lateral recesses, or in the neural foramina.

While lumbar laminectomy, bilateral laminotomy, or more extensive decompression with fusion have historically been the standard of care for surgical man-

agement of lumbar spinal stenosis, a number of new less-invasive surgical procedures have been introduced in recent years. These new less-invasive surgical procedures include unilateral lumbar laminotomy for bilateral decompression (ULBD), microendoscopic decompressive laminectomy, and lumbar micro decompression (2). Although significantly less invasive than the classic procedures, these new surgical techniques still require general anesthesia, in many cases involve hospital admission, and currently are unclear in their value for reduced health care utilization.

In this cost-containment era, it is imperative to improve patient outcomes using less invasive therapeutic options that allow for reduction of risks, preferably outpatient treatment, and lesser cost compared to more extensive surgical procedures or comprehensive medical management. The *mild* lumbar decompression procedure offers this less invasive approach utilizing a new method of spinal decompression that could significantly decrease risks while reducing costs. This ultra-minimally invasive procedure allows for lumbar decompression without the need for fixation/stabilization devices or spacers. This procedure is performed using a single 6 gauge portal site that involves a stab wound incision resulting in less patient trauma and increased potential for a rapid recovery time. In addition, the *mild* procedure can be conducted under a combination of local anesthetic and monitored anesthesia care (MAC), allowing for discharge home following a short period of observation. This technical survey was conducted to assess any significant issues with the procedure's safety profile. We report on an evaluation of possible complications related to the procedure performed by 14 physicians, conducted on 90 consecutive patients in 12 medical centers across the United States.

## METHODS

This was a retrospective survey of procedural notes by private practices and therefore Institutional Review Board approval was not obtained. The survey included 90 consecutive *mild* procedures for the decompression of the central lumbar stenosis. A preliminary safety survey of 90 patients treated at 12 facilities in the US from January 2008 through July 2009 provided information on device or procedure-related adverse events occurring at the time of treatment. Acute factors evaluated included the incidence of dural puncture or tear, blood transfusion, nerve injury, and epidural bleeding or hematoma. All of the patients who received the *mild* procedure previously failed to achieve adequate

improvement with comprehensive non-operative treatments including rehabilitation and medical therapies. To be included in the study, the procedural record was reviewed for content including age, gender, etiology of spinal stenosis (specifically hypertrophic ligamentum flavum), and complete notes stating any procedural difficulties, pre-procedural neurological status, and baseline co-morbidities. When these criteria were applied, 90 consecutive patients were identified and are the focus of this report. A data collection sheet was generated which included any procedural complications or adverse events observed during and immediately post-treatment with the *mild* devices. Case difficulty data were not specifically collected; however, regardless of difficulty, in this series none of the procedures were aborted and none resulted in adverse events. Efficacy parameters were not collected in this safety survey.

The Vertos *mild* Devices are used for image-guided Minimally Invasive Lumbar Decompression, referred to as the *mild* procedure. The Vertos *mild* Devices are a sterile, single-use system of surgical tools consisting of one each of the following components.

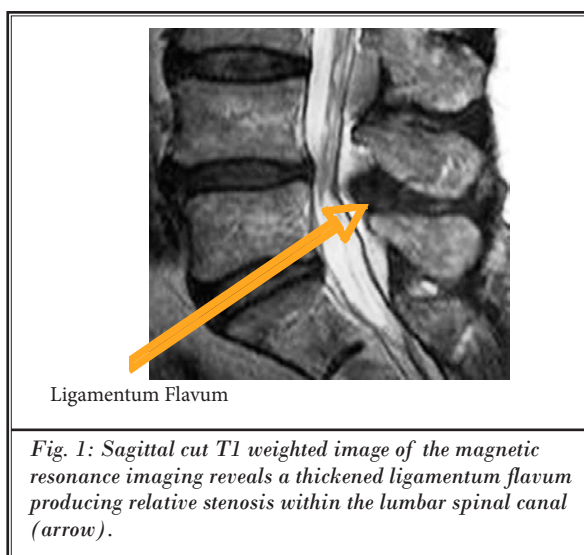
1. Mild tissue sculpter device – 8.5 gauge, 8.5-inch (21.59 cm) working length
2. Mild trocar and handle – 7 gauge, 6.5" (16.51 cm) working length
3. Mild portal cannula – 6 gauge, 6.5-inch (16.51 cm) working length
4. Surgical clamp – 14-inch (35.56 cm) length
5. Accessory guide
6. Mild bone sculpter rongeur (forward)
7. Back plate

*mild* procedures (Vertos Medical, Inc., Aliso Viejo, California) were completed as follows. The patient was placed in the prone position and the skin infiltrated with 1% lidocaine over the desired target entry, as determined by preoperative imaging studies including MRI, CT, or myelogram, after sterile site preparation was conducted. A bolster was used to facilitate opening of the treatment site spinal anatomy. Positioning is critical and was achieved with optimal reduction of lumbar lordosis, and reduction of any tilt of the axis of the body. C-arm fluoroscopy was used to visualize the lumbar spine. The contralateral oblique fluoroscopic view is the primary working view for the procedure, but verification of medial/lateral positioning under the lamina will be assessed by an anterior/posterior view. The *mild* devices are designed to access the intralaminar space from the posterior lumbar spine, enabling

the user to preferentially resect thickened ligamentum flavum and small areas of bony construct. Figure 1 presents the spinal anatomy for which the *mild* devices are intended. Figure 2 shows the lumbar spine from a lateral oblique view, revealing the intralaminar space and the *mild* device trajectory. The lateral oblique graphics present landmarks to guide the *mild* procedure. Proper positioning of the *mild* devices relative to bony and soft tissue allows for selection of the ligamentum flavum.

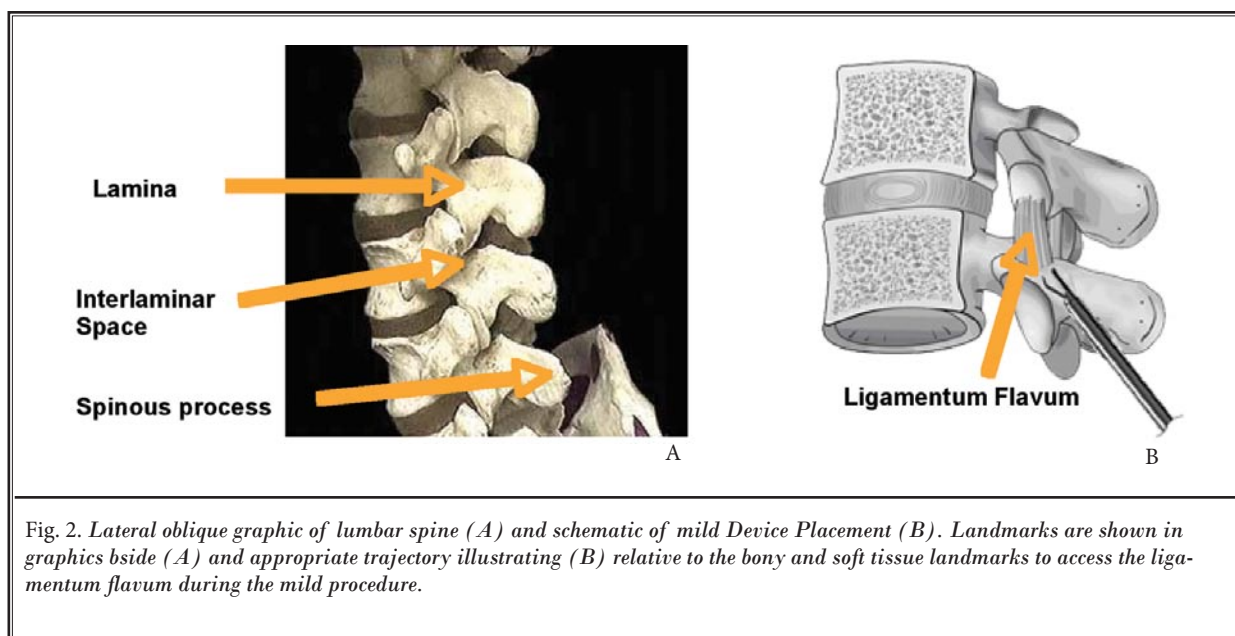
The *mild* devices are used for ultra-minimally invasive access, retraction and resection of tissue and bony structures within the lumbar spine via a posterior approach. This *mild* devices kit is comprised of single-use devices which includes 6G *mild* portal cannula with trocar to access into the soft tissue of the posterior lumbar spine, followed by a Bone Sculpter Rongeur which is used to precisely sculpt small pieces of lamina prior to tissue resection of the hypertrophic ligamentum flavum, and then the *mild* Tissue Sculpter is used to remove ligamentous and fatty tissues from the hypertrophic ligamentum flavum. These devices are currently contraindicated for disc procedures and are not intended to be used near the lateral neural elements.

The procedure was initiated by performing an epidurogram utilizing a myelographically compatible contrast. Contralateral oblique view was utilized most as it provides the thickest visualization of the lamina, creating a posterior working zone (Fig. 3). Additional contrast media was added to the epidurogram throughout



the procedure if needed to assist in maintaining visualization of the working zone, and to assess the amount of decompression achieved.

Following epidurography, the guiding portal and inner trocar were inserted percutaneously at the inferior lumbar segment and lateral to the spinous process margin. The system was advanced to the inferior vertebral segment lamina, toward the border of the interlaminar space, utilizing direct fluoroscopic visualization. The inner trocar was then removed leaving a



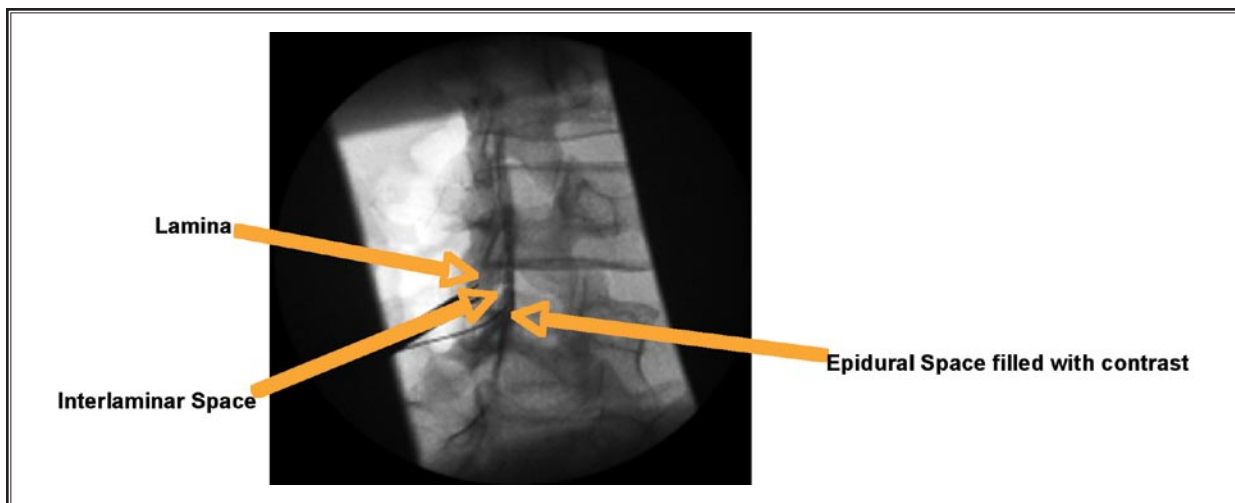


Fig. 3. Contralateral-oblique fluoroscopic projection of the lumbar spine with epidurography and mild Tissue Sculpter Placement. Please note the clear delineation of the epidural contrast and the epidural catheter position underneath the Tissue Sculpter which allows repeated instillation of the contrast to the epidural space.

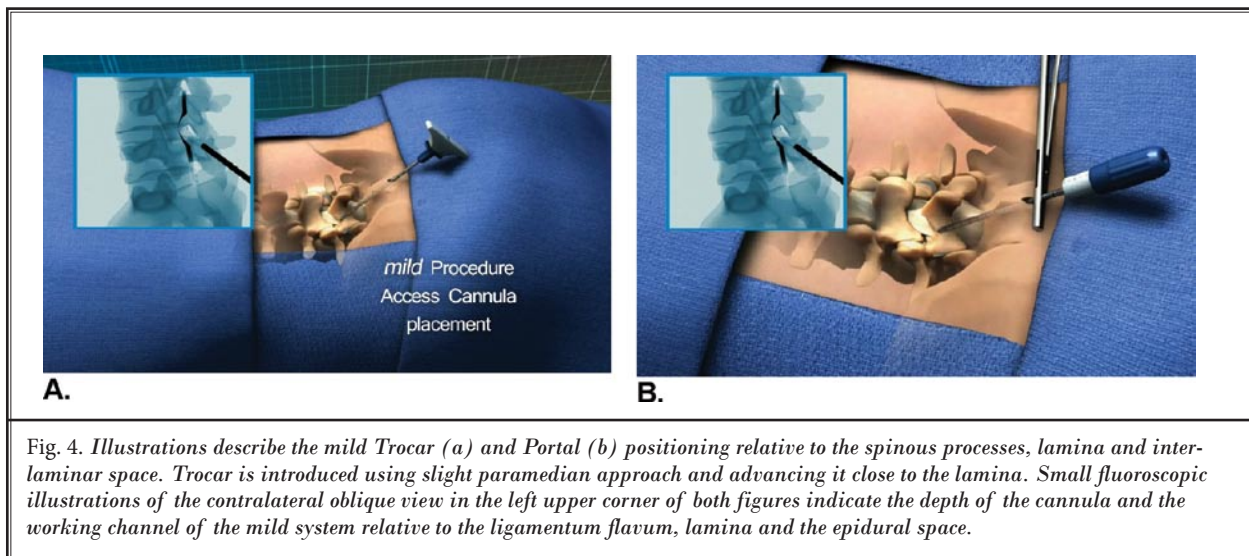
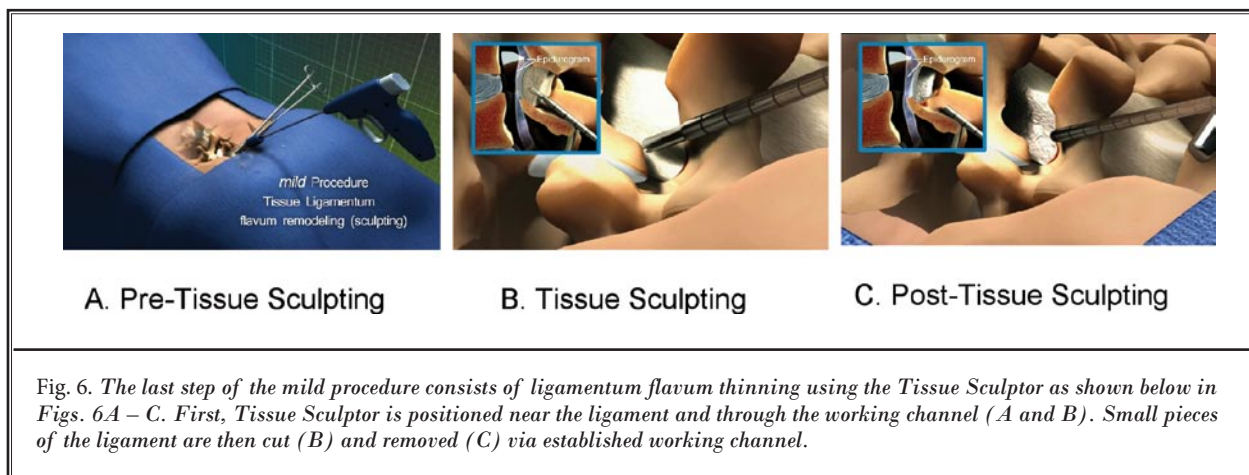
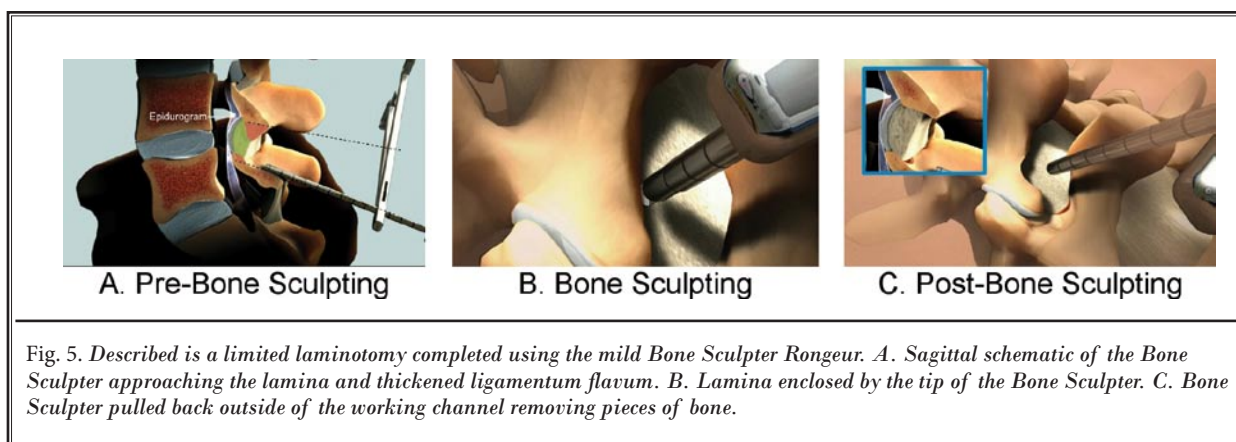


Fig. 4. Illustrations describe the mild Trocar (a) and Portal (b) positioning relative to the spinous processes, lamina and interlaminar space. Trocar is introduced using slight paramedian approach and advancing it close to the lamina. Small fluoroscopic illustrations of the contralateral oblique view in the left upper corner of both figures indicate the depth of the cannula and the working channel of the mild system relative to the ligamentum flavum, lamina and the epidural space.

hollow access portal into the interlaminar space. The portal was secured against the skin surface by the Back Plate and the Accessory Guide placed over the portal, limiting the forward motion of the working instruments. This portal allows working instrument access to the lamina and the ligamentum flavum (Fig. 4).

At this point, the Bone Sculpter was advanced through the access portal to the free edge of the lamina. The device was rotated to sculpt both the su-

perior and inferior lamina, removing small pieces of bone (Fig. 5). Once the interlaminar space has been adequately cleared, the Tissue Sculpter was advanced through the portal and under the lamina into the dorsal aspect of the hypertrophic ligamentum flavum. A specially designed sculpting tip allows the Tissue Sculpter to debulk the ligamentum flavum by removing the posterior portion of the ligament. (Fig. 6.) Decompression was visually confirmed through



noted changes in the epidurogram and contrast flow. The injected contrast media flows more easily into the epidural space, which appears to have a larger, thicker, straighter area when visualized in the contralateral oblique view. In some patients, the entire process was repeated on the opposite side of the spinous process to provide bilateral decompression of the central canal.

## RESULTS

Retrospective review of charts demonstrates no significant patient complication associated with the *mild* procedure. In each case, steps were taken to obtain contra-lateral oblique and lateral fluoroscopic views in order to confirm appropriate (safe) device position. Subsequently, no complications or adverse experiences were reported with the *mild* procedure.

## DISCUSSION

Various surgical decompressive treatments have been used to treat severe lumbar central canal stenosis. The Maine study and a newer SPORT study both claimed significantly better outcomes of surgical decompression when compared to nonsurgical treatments (3,4). Still, non-surgical treatments included in the Maine study consisted of bed rest (30% of the patients), exercise (39.3%), epidural steroid injection in only 18%, and just 20% of the patients were given opiates to mobilize. A similar (and inadequate) conservative program was compared to surgical decompression in the SPORT study (4) where less than half of the patients received lumbar steroid epidural injections. Therefore, such randomization may bias the outcomes in favor of rather extensive surgery.

Furthermore, the 10 year outcome of the Maine study clearly demonstrated that the benefit of decom-

pressive surgery (extensive surgery with long recovery time) diminished over time and the differences in lower back pain and patient satisfaction were no longer significant ( $P=.08$ ) when compared with very basic conservative therapy. Even more, those who underwent subsequent surgical procedures had less improvement in outcomes over time than patients who did not (5).

Therefore, in order to avoid such extensive surgical decompression surgeries with the long recovery times in relatively vulnerable geriatric patient population any percutaneous, minimally invasive approach is welcome as long as it carries minimal or no risk of complications related to the procedure itself and provides reasonable long-term pain relief. Our goal in conducting this short survey was to provide preliminary information on the possible complications related to lumbar central canal decompression using the novel *mild* procedure.

Dural tears and blood transfusions are relatively frequent complications of spinal surgical procedures (3). The prevalence of incidental durotomy during the primary lumbar spine surgery ranges from 6.8% to 15.6% in open surgical series, and from 5.8% to 12.5% in minimally invasive surgical series (Table 1).

The rate of blood transfusions in surgical patients was reported to be 9.9% in the Maine Lumbar Spine study (3) and 14.2% in the SPORT Lumbar Spinal Stenosis study (4). Transfusion requirements increase medical costs, exposure to blood borne pathogens, and the complexity of perioperative care.

One of the most serious complications of the surgical lumbar spinal decompression is an epidural hematoma. This complication requires emergent evacuation of the blood and even after timely surgical decompression, these patients may have serious neurological sequelae such as nerve injury or paraplegia. In the representative open surgical series, 4 patients (1.0%) in the SPORT Lumbar Spinal Stenosis surgical cohort, 2 patients (1.7%) in the open surgical cohort reported by Thomé et al (6) and two patients (0.8%) in the report by Silvers et al (7) experienced this complication. In the minimally invasive surgical series, Castro-Menéndez et al reported one patient (2.0%) (2) and Thomé et al reported 2 patients (5.0%) who had epidural hematoma (6). While this complication is rare, it is an extremely serious potential complication of lumbar spine surgery. There was no such complication associated with the *mild* procedure based on data obtained in this survey.

Finally, reported total number of complications during and after open surgical decompression of LCS ranges from 13.8% to 27.2% of the cases and after currently available minimally invasive decompressions from 9.8% to 25.5% (3-15). While informal, this initial clinical assessment on *mild* procedure frequency of complications suggests a much better safety profile than reported previously on open surgical and minimally invasive surgical alternatives.

This report does not deal with the clinical efficacy of the *mild* procedure. Prospective, randomized *mild*

Table 1. Lumbar Spinal stenosis published surgical series of  $\geq 40$  patients.

	Patients*	Rate of Dural Tears (%)	Rate of Total Complications (%)
Open Surgical Series:			
Ragab et al 2003 (8)	118	6.8	20.3
Khan et al 2006 (9)	2,024	7.6	N/A
Epstein 2007 (10)	98	8.2	N/A
Tafazal et al 2005 (11)	571	8.4	N/A
Weinstein et al 2008 (4)	394	9.2	N/A
Atlas et al 1996 (3)	81	9.9	27.2
Thomé et al 2005 (6)	80	12.5	13.8
Silvers et al 1993 (7)	244	13.1	23.4
Malmivaara et al 2007 (12)	45	15.6	26.7
Minimally Invasive Surgical Series:			
Oertel et al 2006 (13)	133	6.8	9.8
Podichetty et al 2006 (14)	220	7.7	25.0
Ikuta et al 2005 (15)	47	8.5	25.5
Castro-Menéndez et al 2009 (2)	50	10.0	16.0
Thomé et al 2005 (6)	40	12.5	17.5

\*Patients undergoing primary surgeries only.

studies have been initiated to collect patient outcomes data regarding post-treatment pain and functional capacity of the patients with painful lumbar central canal stenosis. Currently, additional protocols to gather prospective, randomized, multicenter studies comparing *mild* to comprehensive medical management and more invasive surgical techniques are being developed by the author (TD).

## CONCLUSIONS

This initial safety survey of early multicenter experience with the *mild* procedure suggests that complication rates may be lower than the complication rates reported for both open and minimally invasive lumbar

spinal stenosis surgeries. Particularly notable is that there were no reports of incidental durotomy or blood transfusions during the *mild* procedure, as these complications are relatively frequent during lumbar spine surgery. In addition, there were no reports of epidural hematomas during *mild* and, although infrequent with more aggressive surgical approaches, it can lead to serious permanent disability.

To establish accurate frequency of the complications associated with the *mild* treatment, a larger patient population is currently being studied. The authors encourage manufacturers to work on similar techniques to treat diseases of the foramen, discs, and other areas of lumbar spine.

## REFERENCES

1. Internet Reference: Spinalstenosis.org. Information on the diagnosis and treatment of spinal stenosis. www.spinalstenosis.org
2. Castro-Menéndez M, Bravo-Ricoy JA, Casal-Moro R, Hernández-Blanco M, Jorge-Barreiro FJ. Midterm outcome after microendoscopic decompressive laminotomy for lumbar spinal stenosis: 4-Year Prospective Study. *Neurosurgery* 2009; 65:100-110.
3. Atlas SJ, Deyo RA, Keller RB, Chapin AM, Patrick DL, Long JM, Singer DE. The maine lumbar spine study, part III: 1-year outcomes of surgical and nonsurgical management of lumbar spinal stenosis. *Spine* 1996; 21:1787-1794.
4. Weinstein JN, Tosteson TD, Lurie JD, Tosteson AN, Blood E, Hanscom B, Herkowitz H, Cammisa F, Albert T, Boden SD, Hilibrand A, Goldberg H, Berven S, An H; SPORT Investigators. Surgical versus nonsurgical therapy for lumbar spinal stenosis. *N Engl J Med* 2008; 358:794-810.
5. Chang Y, Singer DE, Wu YA, Keller RB, Atlas SJ. The effect of surgical and nonsurgical treatment on longitudinal outcomes of lumbar spinal stenosis over 10 years. *J Am Geriatr Soc* 2005; 53:785-792.
6. Thomé C, Zevgaridis D, Leheta O, Bänzner H, Pöckler-Schöniger C, Wöhrle J, Schmiedek P. Outcome after less-invasive decompression of lumbar spinal stenosis: A randomized comparison of unilateral laminotomy, bilateral laminotomy, and laminectomy. *J Neurosurg: Spine* 2005; 3:129-141.
7. Silvers HR, Lewis PJ, Asch HL. Decompressive lumbar laminectomy for spinal stenosis. *J Neurosurg* 1993; 78:695-701.
8. Ragab AA, Fye MA, Bohlman HH. Surgery of the lumbar spine for spinal stenosis in 118 patients 70 years of age or older. *Spine* 2003; 28:348-353.
9. Khan MH, Rihn J, Steele G, Davis R, Donaldson WF 3rd, Kang JD, Lee JY. Postoperative management protocol for incidental dural tears during degenerative lumbar spine surgery: A review of 3,183 consecutive degenerative lumbar cases. *Spine (Phila Pa 1976)*. 2006; 15; 31:2609-2613.
10. Epstein NE. The frequency and etiology of intraoperative dural tears in 110 predominantly geriatric patients undergoing multilevel laminectomy with non-instrumented fusions. *J Spinal Disord Tech* 2007; 20:380-386.
11. Tafazal SI, Sell PH. Incidental durotomy in lumbar spine surgery: Incidence and management. *Eur Spine J* 2005; 14:287-290.
12. Malmivaara A, Slätis P, Heliövaara M, Sainio P, Kinnunen H, Kankare J, Dalin-Hirvonen N, Seitsalo S, Herno A, Kortekangas P, Niinimäki T, Rönty H, Tallroth K, Turunen V, Knekt P, Härkänen T, Hurri H; Finnish Lumbar Spinal Research Group. Surgical or nonoperative treatment for lumbar spinal stenosis? A randomized controlled trial. *Spine (Phila Pa 1976)*. 2007; 32:1-8.
13. Oertel MF, Ryang YM, Korinath MC, Gilsbach JM, Rohde V. Long-term results of microsurgical treatment of lumbar spinal stenosis by unilateral laminotomy for bilateral decompression. *Neurosurgery* 2006; 59:1264-1270.
14. Podichetty VK, Spears J, Isaacs RE, Booher J, Biscup RS. Complications associated with minimally invasive decompression for lumbar spinal stenosis. *J Spinal Disord Tech* 2006; 19:161-166.
15. Ikuta K, Arima J, Tanaka T, Oga M, Nakano S, Sasaki K, Goshi K, Yo M, Fukagawa S. Short-term results of microendoscopic posterior decompression for lumbar spinal stenosis. *J Neurosurg: Spine* 2005; 2:624-633.

