

Letters to the Editor

Greater Occipital Nerve Block by Using Transcranial Doppler Ultrasonography

TO THE EDITOR:

Greater occipital nerve block (GONB) is a common procedure to diagnose and treat patients with occipital neuralgia and to differentiate headaches of cervical origin from other types of headaches (1,2). Although a relatively safe method and easy to perform, the classical method of blind injection just medial to the palpated occipital artery at the level of the superior nuchal line is not target specific (3). Imprecise use of high injection volumes without image guidance could lead to repeated injections. Possible reasons for failed blockade include wide variability in the courses of the occipital artery and greater occipital nerve, as identified through anatomic studies. Further, identification of the occipital artery by palpation in patients with thick necks or small occipital arteries can be technically difficult (3). In addition, the presence of hair often causes great difficulty in the identification of the pulse (4). Therefore, some authors have been attempting to increase the success rate of GONB by using ultrasound Doppler flowmeter or peripheral nerve stimulator (2-4). Here, we describe the new GONB technique with transcranial Doppler (TCD) ultrasonography that was performed with ease at the outpatient clinics.

The technique of GONB is well established. The greater occipital artery, which serves as the most reliable landmark, is palpated at this point. On the basis of our clinical experience, we believe that the TCD ultrasonography can be used to easily and precisely detect pulsation of the greater occipital artery. We performed GONB by using a portable TCD device (Pioneer TC2020, EME, Germany). The patient was placed in the prone position, and the 8-MHz probe was manipulated along the superior nuchal ridge until the blood flow in the occipital artery was audible and visible. After the pulsating vessel was identified, a 25-

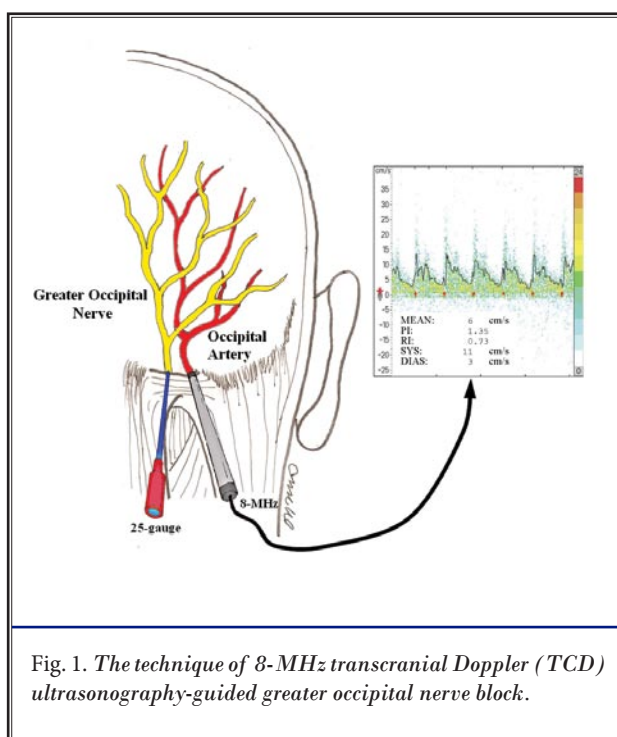


Fig. 1. The technique of 8-MHz transcranial Doppler (TCD) ultrasonography-guided greater occipital nerve block.

gauge 1.5-inch needle was inserted just medial to the point of pulsation, and a local anesthetic was injected around the artery (Fig. 1).

It is necessary to successfully block the targeted region of the GON with minimum amount of local anesthetic for a specific diagnosis. We believe that this new technique of TCD ultrasonography-guided GONB is easy and reliable and results in analgesia in all patients through low injection volumes.

Ki Seong Eom, MD, PhD
Associate Professor
Department of Neurosurgical Pain Management
Wonkwang University School of Medicine
344-2 Shinyong-dong
Iksan 570-749, Korea
E-mail: kseom@wonkwang.ac.kr

Tae Young Kim, MD, PhD
Professor
Department of Neurosurgery
Wonkwang University School of Medicine
344-2 Shinyong-dong
Iksan 570-749, Korea
E-mail: tykim@wonkwang.ac.kr

REFERENCES

1. Young WB, Marmura M, Ashkenazi A, Evans RW. Expert opinion: Greater occipital nerve and other anesthetic injections for primary headache disorders. *Headache* 2008; 48:1122-1125.
2. Naja ZM, El-Rajab M, Al-Tannir MA, Ziade FM, Tawfik OM. Occipital nerve blockade for cervicogenic headache: A double-blind randomized controlled clinical trial. *Pain Pract* 2006; 6:89-95.
3. Greher M, Moriggl B, Curatolo M, Kirchmair L, Eichenberger U. Sonographic visualization and ultrasound-guided blockade of the greater occipital nerve: A comparison of two selective techniques confirmed by anatomical dissection. *Br J Anaesth* 2010; 104:637-642.
4. Okuda Y, Ishikawa K, Usui Y, Nagao M, Ikeda T, Kitajima T. Use of an ultrasound doppler flowmeter for occipital nerve block. *Reg Anesth Pain Med* 2002; 27:444-445.