

## Case Report

## A Report of Paraparesis Following Spinal Cord Stimulator Trial, Implantation and Revision

Clark C. Smith, MD, John L. Lin, MD, Max Shokat, DO, Sonny S. Dosanjh, MD, and Dionne Casthely, MD

From: Emory University, Shepherd Center, Atlanta, GA.

Dr. Smith is chief resident, Physical Medicine and Rehabilitation Residency Program, Emory University, Atlanta, GA. Dr. Lin is Medical Director of Post Acute Services at Shepherd Center Emory University, Atlanta, GA. Dr. Shokat is a fourth-year resident at Emory University Department of Rehabilitation Medicine Residency Program, Atlanta, GA. Dr. Dosanjh and Dr. Casthely are third-year residents at Emory University Department of Rehabilitation Medicine Residency Program, Atlanta, GA.

Address correspondence:  
Clark Smith MD, MPH  
Chief Resident  
Physical Medicine and Rehabilitation  
Residency Program  
1441 Clifton Road  
Atlanta, GA 30322  
E-mail:  
ccsmit5@emory.edu

Disclaimer: There was no external funding in the preparation of this manuscript.

Conflict of interest: None.

Manuscript received: 02/18/2010

Revised manuscript received:  
05/06/2010

Accepted for publication: 05/20/2010

Free full manuscript:  
www.painphysicianjournal.com

**Background:** Spinal cord injury has been reported as a rare complication of spinal cord stimulation (SCS). A review of the literature shows a very low incidence of neurological injury after spinal cord stimulation trial, implantation and revision. The most common reported complication is equipment failure without neurologic injury. The incidence of spinal cord injury after SCS trial, implantation and revision is unknown. There have been limited reports of neurologic injury secondary to dural puncture, infection, cord contusion, actual needle penetration of the spinal cord and epidural hematoma.

**Study Design:** A report of 4 cases.

**Objective:** To report 4 occurrences of neurological complication after spinal cord stimulator implantation.

**Methods:** Four patients are presented who were admitted to an acute spinal cord rehabilitation hospital over a 4-month period. All 4 patients presented with paraparesis after spinal cord stimulator trial or implantation. One of the injuries is secondary to cord contusion, while the other 3 are secondary to cord compressions. Two of these compressions are due to epidural hematomas and one secondary to implantation in the setting of broad based thoracic disc herniations. The clinical cases are presented as well as a review of the literature.

**Results:** All 4 patients had the electrodes and neurostimulators successfully removed prior to their acute rehabilitation admissions. At discharge from acute inpatient rehabilitation, one patient continued to experience complete paraplegia, 2 patients had incomplete paraparesis and one had fully recovered all of his neurologic function.

**Conclusion:** SCS is considered a safe procedure. Further investigation into the true incidence of neurologic injury after SCS is warranted.

**Key words:** spinal cord stimulation, spinal cord injury, rehabilitation, pain, epidural hematoma, cord contusion, disc herniation

**Pain Physician 2010; 13:357-363**

Spinal cord stimulation (SCS) was introduced over 40 years ago as a treatment for chronic low back pain (1). Several randomized control trials have established SCS as a viable treatment option for complex regional pain syndrome (CRPS), chronic back and leg pain (CBLP) and failed back surgery

syndrome (FBSS) (2-6). One large study found SCS to be particularly effective for FBSS with predominant leg pain of neuropathic radicular origin (7). SCS has also been applied in the treatment of ischemic limb pain and intractable angina (8,9). In the United States, current indications for SCS are neuropathic pain, pain

of FBSS, or CRPS (10). From an economic standpoint, there is evidence that suggests that for CRPS and FBSS, SCS may be more cost effective than traditional management (6,11).

SCS works by placing an electrode in the epidural space that stimulates the dorsal columns inducing paresthesia that can replace the pain. The types of electrodes used most frequently are plate or paddle electrodes and round shaped electrodes. Paddle electrodes are inserted through a small laminotomy or laminectomy (8).

Spinal cord stimulator implantation has been reported to be generally safe (8,9). Most of the research on safety and efficacy of spinal cord stimulators has been in case series and case reports (8,9). A systematic review by Turner et al (4) in 2004 reported the overall complication rate to be 34%. Most reported complications were reported to be minor and included need for stimulator revision or removal (33%), equipment failure (10%), pain in region of hardware (5.8%), and superficial infection (4.5%) (4). The overall incidence of lead migration alone has been reported to be 5.7 to 13.5% (12-13). Turner et al (4) found no reports of neurologic related events. A systematic review by Taylor et al (8) also in 2004, found the overall complication rate to be 43%. The most common complications were found to be electrode or lead dysfunction (27%), extension cable problems (10%), CSF leaks (7%), and infections (6%) (9). Again no neurologic related complications were reported. A prospective observational study by Kemler et al (5) in 1997 found that 11% of patients undergoing test spinal cord stimulation suffered intradural puncture, though complications were limited to temporary headache. Adverse events published in case reports include epidural hematoma, subdural hematoma, acute renal failure, allergic reaction and epidural abscess (14-20). In 2007, Meyer et al (18) published a report of quadriplegia following dural puncture and intramedullary placement of leads. Barolat et al (9) describe a case in which a patient suffered a spinal cord injury resulting in quadriplegia after needle penetration in the lower cervical cord. Several authors suggested that the true incidence of neurologic complications of spinal cord stimulation may be under-reported.

We present 4 cases of neurologic injury after SCS implantation. Two cases involve injury secondary to epidural hematoma; one case involves injury secondary to cord contusion and one injury secondary to thoracic disc herniation. The clinical courses and outcomes are presented.

## CASE #1

The patient is a 59-year-old man with a history of chronic back and leg pain and FBSS. Several years prior to presentation he underwent L5 laminectomy and L5-S1 posterior fusion for chronic low back pain with radiation to the posterior legs. The surgery did not relieve his symptoms. He underwent implantation of a spinal cord stimulator with bipolar leads. This procedure resulted in improvement of his lower extremity symptoms but did not affect his low back pain.

The patient sought a second opinion on his back pain from another physician. Together, it was decided that the patient would undergo a spinal cord stimulator revision with placement of triplolar paddle leads and T8 and T9 laminectomy with the goal of improving the patient's back pain.

On date of surgery, the patient was placed under monitored anesthesia care. First, the 2 previously placed electrode leads and the associated neurostimulator were removed. Next, a T8 and T9 laminectomy was performed. The surgeon noted difficult dissection due to the presence of scarring of the dura to the underlying lamina. Tripolar paddle leads were placed and the screening cable was then connected to the screener for trial spinal cord stimulation. The patient was noted to have excellent coverage of his painful area of the low back and both legs.

When the patient awoke from anesthesia, he noted right greater than left lower extremity weakness. He also had difficulty urinating. He reported a band-like loss of sensation around his lower abdomen. On post-operative day #1, neurostimulator and leads were removed. The patient reported that following removal of leads, he had improved strength in his left lower extremity. His right leg weakness, sensory symptoms and bowel/bladder symptoms did not change.

The patient worked with physical therapy and was reportedly walking with a rolling walker with assistance. He was discharged to home on post-operative day #2. Patient returned to the emergency department (ED) 3 hours later complaining of ongoing sensory changes, inability to void, and inability to ambulate secondary to right leg weakness. The patient received IV steroids. An MRI was performed on post-operative day #3 showing no evidence of cord compression or epidural hematoma. MRI was repeated on post-operative day #5 and did show slight signal enhancement at the T8/T9 level (Fig. 1). He continued to have right leg weakness, and sensory changes.

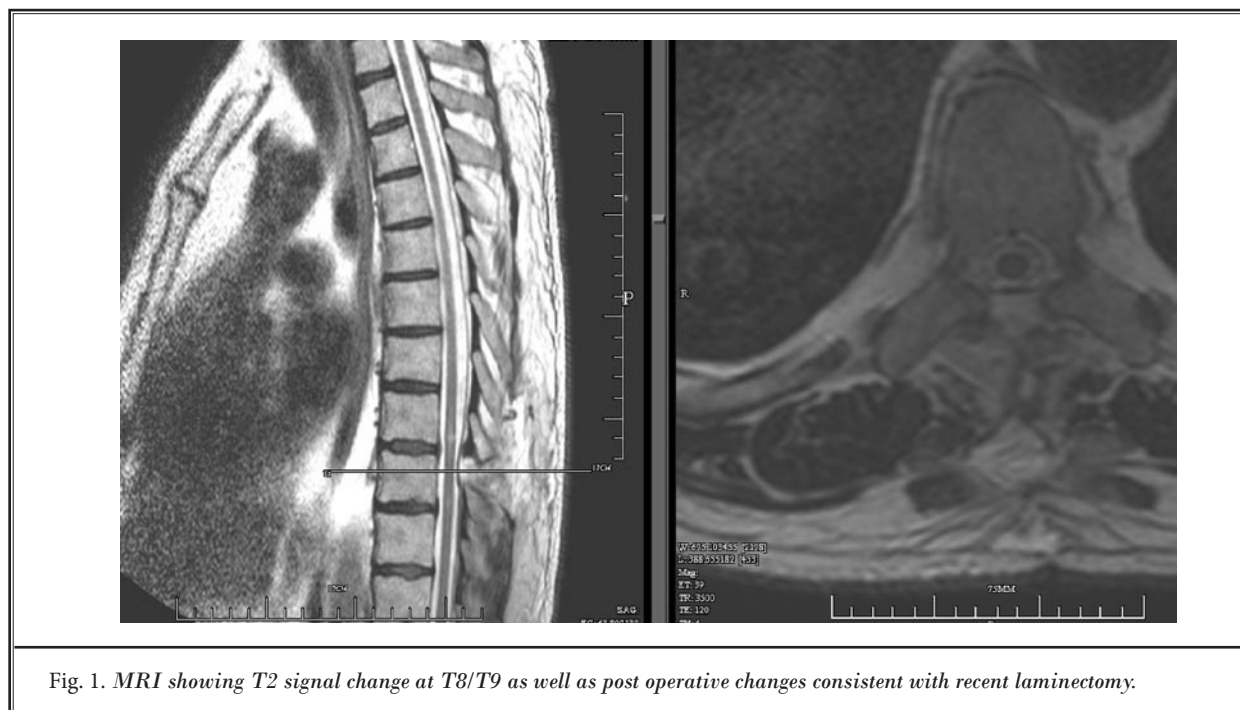


Fig. 1. MRI showing T2 signal change at T8/T9 as well as post operative changes consistent with recent laminectomy.

He was transferred to an inpatient rehabilitation hospital 8 days after the SCS revision. Manual motor strength testing in the lower extremity revealed hip flexion to be 1/5 on the right and 5/5 on the left. Hip extension was 1/5 on the right and 5/5 on the left. Knee extension was 1/5 on the right and 4/5 on the left. Knee flexion was 1/5 on the right and 4/5 on the left. Ankle dorsiflexion was 1/5 bilaterally, plantar flexion was 1/5 bilaterally and EHL was 1/5 bilaterally. Sensation was normal to LT and pinprick to T5. Sensation was diminished bilaterally in the T6 -T11 dermatomes. Sensation was absent at the T12 - S1 on the right and present but diminished on the left. Perianal sensation was present but diminished.

The patient participated in comprehensive interdisciplinary rehabilitation. The patient experienced full return of motor strength in the left leg, but only partial return on the right. At discharge, the patient was walking with a rolling walker and minimum assistance. He was voiding volitionally but was still using a suppository nightly. His discharge American Spinal Injury Association (ASIA) exam was consistent with a T8 ASIA D spinal cord injury.

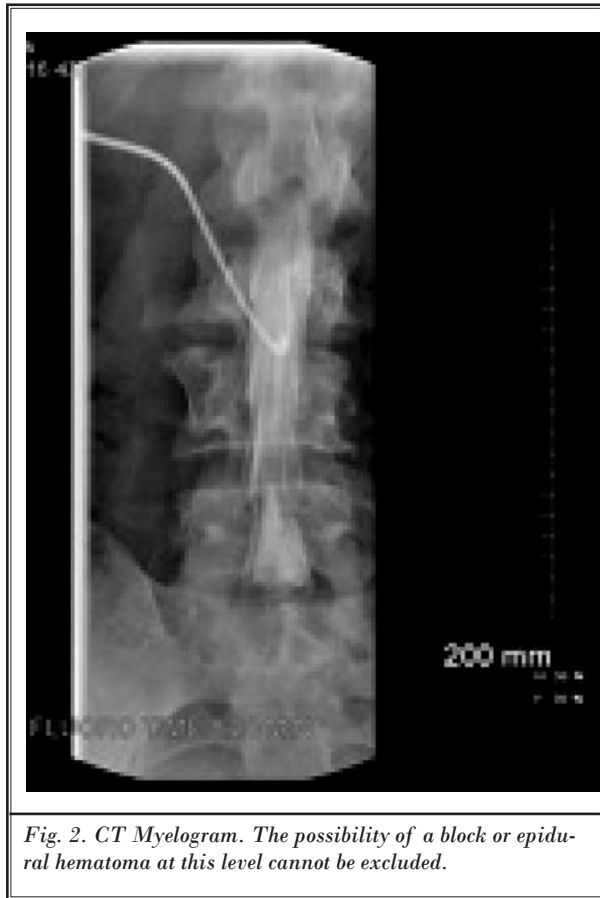## CASE #2

The patient is a 44-year-old male with a 10-year history of chronic low back pain and peripheral neuropathy

localized to his bilateral lower extremities secondary to diabetes mellitus (DM).

The patient underwent consultation with neurosurgery for his lower extremity pain. Spinal cord stimulator trial was reportedly successful and without complications. He underwent placement of spinal cord stimulator and leads without any acute post operative complications. Patient was discharged from the hospital having reportedly experienced significant symptom alleviation. However on post-operative day #5; patient noted an acute development of new mid back pain associated with rapid progressive weakness and motor loss to his bilateral lower extremities. There was associated urinary retention. The pattern of weakness began in this right lower extremity and then progressed to the left lower extremity. The onset was acute and progressed over the course of several hours.

The patient was taken to a local ED and was transferred the same day to the facility where the surgery had been performed. Post transfer; patient was started on intravenous methylprednisolone protocol. A thoracic CT myelogram and CT thoracic spine with intrathecal contrast were performed. Study results indicated evidence of an epidural hematoma which extended 2 levels above the area of spinal cord stimulator placement (Fig. 2). Complete blood count (CBC) and coagulation



*Fig. 2. CT Myelogram. The possibility of a block or epidural hematoma at this level cannot be excluded.*

studies were normal. The patient was not on any anti-platelet medications or anticoagulants. On post-operative day #5, the patient underwent a thoracic T8-9 laminectomy with excision of epidural hematoma and removal of spinal cord stimulator electrodes. Per report; there were no post-operative complications and the patient tolerated the procedure well. A follow up MRI of the thoracic spine revealed cord edema at T8 through the conus medullaris and a large herniated disc at T8/9 and T9/10.

The patient was transferred to acute inpatient rehabilitation. Initial exam demonstrated 0/5 strength in his lower extremity bilaterally. His L2-S3 motor levels were 0/5 bilaterally. His sensation was normal approximately to the T8 level. At the time of discharge, he was at a supervision level for manual wheelchair transfers, activities of daily living, bladder and bowel program. His discharge American Spinal Injury Association exam was consistent with a T8 ASIA A spinal cord injury.

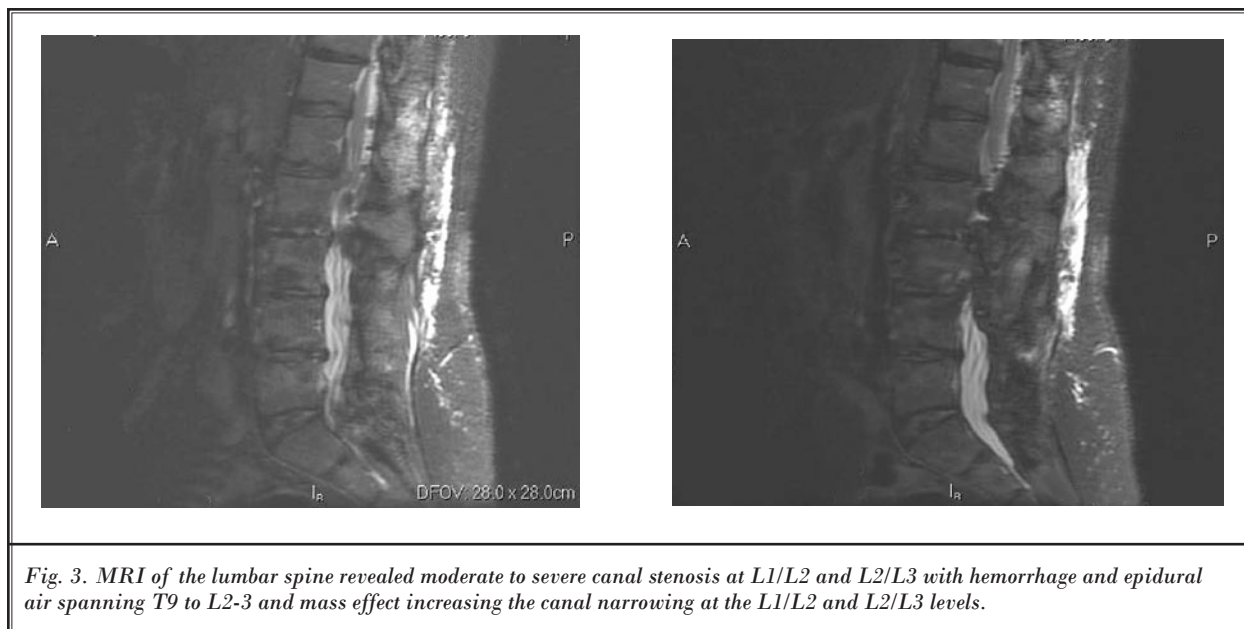
### CASE #3

The patient is a 66-year-old female with a history of chronic low back pain and failed back surgery syndrome (FBSS). She had previously undergone decompressive laminectomies at the L3, L4 and L5 levels. The patient complained of persistent and progressive low back pain.

She then underwent a spinal cord stimulator trial with successful lead placement. Immediately after the procedure, as the technician was adjusting the settings on the external spinal cord stimulator, the patient experienced sudden low back pain with bilateral lower extremity dysesthesias followed by lower extremity paralysis. The trial leads were removed and emergent MRI of the lumbar spine was performed. MRI revealed moderate to severe canal stenosis at L1/L2 and L2/L3 with epidural hematoma and air spanning T9 to L2-3 and mass effect increasing the canal narrowing at the L1/L2 and L2/L3 levels (Fig. 3). Complete blood count (CBC) and coagulation studies were normal. The patient was not on any anti-platelet medications or anticoagulants. She then underwent decompressive thoracic and lumbar laminectomies of the T11 through L2 levels that same day.

She transferred to an acute inpatient rehabilitation hospital 20 days after her decompressive surgery. She complained of persistent low back pain, bilateral left greater than right lower extremity weakness, and decreased sensation in her bilateral legs. She had neurogenic bowel and bladder. Manual muscle testing revealed bilateral 5/5 right hip flexion and 2/5 left hip flexion strength. Exam also revealed bilateral 4/5 toe dorsiflexion and ankle planar flexion strength, and 2/5 knee extension and ankle dorsiflexion strength. Deep tendon reflexes were 2/4 at the bilateral patella and Achilles tendon. She had negative Babinski reflexes and normal tone bilaterally. Her sensation was intact to light touch and pinprick from C2 to T7 and diminished below T8. Patient demonstrated intact clitoral-anal-reflex and voluntary anal contraction.

Upon completion of her acute inpatient rehabilitation stay, she had recovered full motor strength in bilateral lower extremities. At discharge, she was modified independent with limited community ambulation and had full bladder and bowel function recovery. Her discharge American Spinal Injury Association exam was consistent with a T7 ASIA D spinal cord injury.



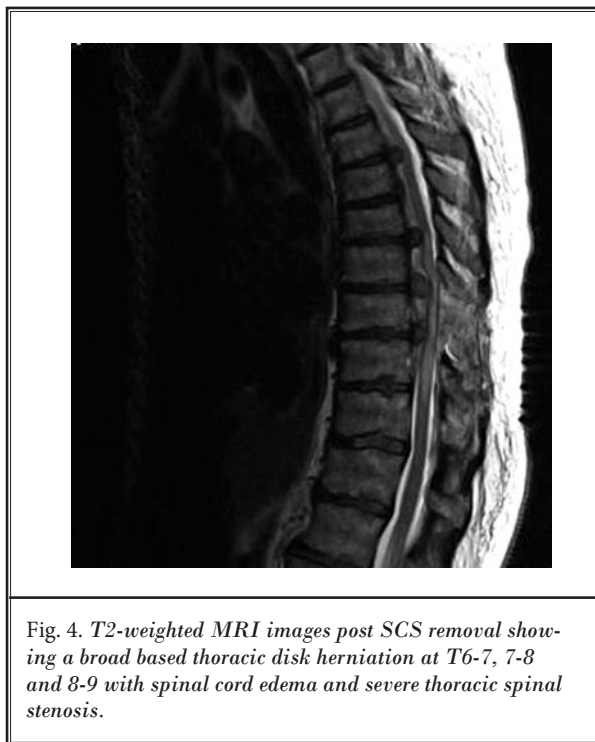*Fig. 3. MRI of the lumbar spine revealed moderate to severe canal stenosis at L1/L2 and L2/L3 with hemorrhage and epidural air spanning T9 to L2-3 and mass effect increasing the canal narrowing at the L1/L2 and L2/L3 levels.*

#### CASE #4

The patient is a 55-year-old female with a history of chronic low back pain and bilateral leg pain with associated numbness. She has a history of 2 previous lumbar fusion surgeries. She continued to experience low back and leg pain and she complained of mild of mid-thoracic pain.

She underwent spinal cord stimulator trial which was reported as successful without any complications. She then underwent spinal cord stimulator implantation with leads extending to the T8-9 level. There were no peri-operative adverse events. Three days post operatively, she developed worsening numbness and weakness in her legs with progressive inability to move her left lower extremity and some voluntary movement in the right lower extremity. Neurological examination at that time reportedly revealed 2/5 strength throughout her bilateral lower extremities.

The spinal cord stimulator was removed and the patient underwent an MRI scan which showed a large thoracic disk herniation at T6-7, 7-8 and 8-9 with spinal cord edema and severe thoracic spinal stenosis. The patient was placed on IV steroids. CT scan of the thoracic spine showed multilevel partially calcified disc herniations at T6-7, 7-8 and 8-9 (Fig. 4). At T6-7 there was a large partially calcified anterior soft tissue density suspicious for a large calcified disc herniation with severe central canal compromise, reducing the AP diameter of the thecal sac to 5 mm. At T7-8 there was a large left



*Fig. 4. T2-weighted MRI images post SCS removal showing a broad based thoracic disk herniation at T6-7, 7-8 and 8-9 with spinal cord edema and severe thoracic spinal stenosis.*

paramedian disc herniation. At T8-9 there were calcifications in the anterior canal contributing to severe central canal stenosis.



The patient was then taken to the operating room for a 2-stage procedure. Stage 1 consisted of a left sided thoracotomy with discectomies performed at T6-7, 7-8, and 8-9. This was followed by arthrodesis and fusion at these same levels. Stage 2 consisted of decompressive laminectomy from at T7-9 with posterior instrumentation and fusion from T6 through T10.

Post operatively, the patient had no additional complications but did have severe pain which was managed with morphine and oral oxycodone. She underwent physical therapy and occupational therapy. She was reportedly at a maximal assist level for bed to chair transfers.

She was transferred to acute inpatient rehabilitation 12 days after surgery. Initial exam showed 3/5 strength in her right hip flexors, knee extensors and ankle dorsiflexors and 4/5 strength in her long toe extensors and ankle plantar flexors on the right. She had progressed to 1/5 strength in her left lower extremity hip flexors, knee extensors, ankle dorsiflexors, plantar flexors and long toe extensors and she was rated at T11 ASIA C. At the end of the patient's inpatient rehabilitation stay of 33 days, she had 4/5 strength in her left ankle dorsiflexors, plantar flexors and long toe extensors. Also on the left, she had 2/5 strength in her left hip flexors and 3/5 strength in her knee extensors. She required the use of a wheelchair and rolling walker for ambulation. She required maximal assistance for stair climbing. The patient was to continue outpatient physical therapy and occupational therapy upon discharge from inpatient rehabilitation. Her discharge American Spinal Injury Association exam was consistent with a T11 ASIA C spinal cord injury.

## **DISCUSSION**

Spinal cord stimulation (SCS) is indicated as a treatment for complex regional pain syndrome (CPRS), chronic back and leg pain (CBLP) and failed back surgery syndrome (FBSS) (5-9). Spinal cord stimulation is also used in the treatment of ischemic limb pain and intractable angina (5-9).

This case series suggests that neurologic injury is a rare but serious possible complication of spinal cord stimulator trial and placement. We present 2 cases of epidural hematoma, one of cord contusion, and one of

cord edema secondary to thoracic disc herniations. In all 4 cases the injury area included the T8-9 level. Although epidural hematoma may be spontaneous, it often follows minor trauma, which would include spinal cord stimulator placement with or without lumbar puncture. Mechanical compression of the cord causes both an immediate and secondary injury (21). Immediately there is damage to the neural tissue and other soft tissues including endothelial cells of the vasculature. There is also secondary injury thought to be due to immune system reactions, oxidative damage, calcium and excitotoxicity (22).

This case series underscores the need for extreme caution and careful patient selection in performing spinal cord stimulator trial, implantation, or revision. Prior studies have demonstrated the importance of maintaining a high index of suspicion for thoracic disc herniations in patients with unexplainable mid-back or torso pain with or without sensorimotor deficits (23). We agree with the authors of these studies who have advocated the use of MR imaging prior to spinal interventional procedures in these patients. Careful consideration should also be given to patients with abnormal hemotologic or coagulation studies, and for patients on anti-platelet medications or anticoagulants. In the event of neurologic injury, leads should be removed immediately and, in the setting of cord compression, rapid decompression should be performed.

## **CONCLUSION**

This case series underscores the need for extreme caution and careful patient selection in performing spinal cord stimulator trial, implantation, or revision.

Spinal cord injury resulting in paraparesis should be noted in the risk-benefit discussion with the patient as a possible complication of spinal cord stimulator placement or revision. Further investigation into potential complications of this SCS and their true incidence is warranted.

## **ACKNOWLEDGMENTS**

The authors wish to thank the editorial board of *Pain Physician* for review and criticism in improving the manuscript.

## REFERENCES

1. North RB, Kidd DH, Farrokhi F, Piantadosi SA. Spinal cord stimulation versus repeated lumbosacral spine surgery for chronic pain: a randomized control trial. *Neurosurgery* 2005; 56:98-106.
2. North RB, Kidd DH, Zahurak M, et al. Spinal cord stimulation for chronic, intractable pain: experience over two decades. *Neurosurgery* 1993;32:384-394.
3. Kemler MA, Barendse GA, van Kleef M, de Vet HC, Rijks CP, Furnée CA, van den Wildenberg FA. Spinal cord stimulation in patients with chronic reflex sympathetic dystrophy. *N Engl J Med* 2000; 343:618-624.
4. Turner JA, Leoser JD, Deyo RA. Spinal cord stimulation for patients with failed back surgery or complex regional pain syndrome: a systematic review of effectiveness and complications. *Pain* 2004;108:137-147.
5. Kemler MA, De Vet HC, Barendse GA, Van Den Wildenberg FA, Van Kleef MV. The effect of spinal cord stimulation in patients with chronic reflex sympathetic dystrophy: Two years' follow-up of the randomized control trial. *Ann Neurol* 2004; 55:13-18.
6. Kemler MA, Furnee CA. Economic evaluation of spinal cord stimulation for chronic reflex sympathetic dystrophy. *Neurology* 2002; 59:1203-1209.
7. Kumar K, Taylor RS, Jacques L, Eldabed S, Meglio M, Molet J, Thomsong S, O'Callahan J, Eisenberg, Milbouwi G, Buschser E, Fortini G, Richardson J, North RB. Spinal cord stimulation versus conventional medical management for neuropathic pain: A multicentre randomised controlled trial in patients with failed back surgery syndrome. *Pain* 2007; 132:179-188.
8. Taylor RS, Van Buyten JP, Buchser E. Spinal cord stimulation for chronic back and leg pain and failed back surgery syndrome: A systematic review and analysis of prognostic factors. *Spine* 2005; 30:152-160.
9. Barolat G, Peacock WJ, Staudt LA. Pain and spasticity. In: Benzel EC, ed. *Spine Surgery: Techniques, Complication Avoidance, and Management, 2nd ed, vol. 2*. Philadelphia: Elsevier Churchill Livingstone; 2005:1239-1252.
10. Manchikanti, L, Boswell, MK, Singh V, Benyamin RM, Fellows B, S, Abdi S, Buenaventura RM, Conn A, Datta S, Derby R, Falco FJ, Erhart, S, Diwan S, Hayek SM, Helm S, Parr AT, Schulz DM, Smith HS, Wolfer LR, Hirsch JA. Comprehensive evidence based guidelines for interventional techniques in the management of chronic spinal pain. *Pain Physician* 2009; 12:699-802.
11. Bell GK, Kidd D, North RB. Cost-effectiveness analysis of spinal cord stimulation in treatment of failed back surgery syndrome. *J Pain Sympt Manage* 1997; 13:286-295.
12. Cameron, T. Safety and efficacy of spinal cord stimulation for the treatment of chronic pain: A 20-year literature review. *J Neurosurg* 2004; 100:254-267.
13. Washburn S. A review of articles published on spinal cord stimulation treatment for chronic pain: 1981 – 2009. Poster presentation at the North American Neuromodulation Society Annual Meeting, 2008.
14. Chiravuri S, Wasserman R, Chawla A, Haider N. Subdural hematoma following spinal cord stimulator implant. *Pain Physician* 2008; 11:97-101.
15. Arxer A, Busquets C, Vilaplana J, Vilalunga A. Subacute epidural abscess after spinal cord stimulator implantation. *Eur J Anesthesiol* 2008; 20:755-757.
16. Rauchwerger JJ, Zoarski GH, Waghmarae R, Rabinowitz RP, Kent JL, Aldrich EF, Closson CW. Epidural abscess due to spinal cord stimulator trial. *Pain Pract* 2008; 8:324-328.
17. Ochani TD, Almirante J, Siddiqui A, Kaplan R. Allergic reaction to spinal cord stimulator. *Clin J Pain* 2000; 16:178-180.
18. Meyer SC, Swartz K, Johnson JD. Quadriparesis and spinal cord stimulation: Case report. *Spine* 2007; 32:565-568.
19. Franzini A, Ferrolì P, Marras C, Broggi G. Huge epidural hematoma after surgery for spinal cord stimulation. *Acta Neurochir* 2005; 147:565-567.
20. Santiago FM, Santiago J, Prieto M, García-Sánchez MJ, Sánchez-Carrion JM, Martínez-Tellería A, Garzón A. Dorsal epidural hematoma after implantation of a dorsal nerve stimulator. *Rev Esp Anesthesiol Reanim* 2005; 52:440-441.
21. Hulsebosch CE. Recent advances in pathophysiology of spinal cord injury. *Advan Physiol Edu* 2002; 26:238-255, 1043-1046.
22. Spinal Cord Injury: Emerging Concepts. National Institute of Neurological Disorders and Stroke. National Institutes of Health. 2009. [www.ninds.nih.gov/news\\_and\\_events/proceedings/sci\\_report.htm](http://www.ninds.nih.gov/news_and_events/proceedings/sci_report.htm)
23. Kumar K, Hunter G, Demeria D: Benign pain: challenges in treatment planning and present status, a 22-year experience. *Neurosurgery* 2006; 58:481-496.

