

Case Reports



Management of Painful Vertebral Hemangiomas with Kyphoplasty: A Report of Two Cases and a Literature Review

Jonathan O. Jones, MD¹, Brian M. Bruel, MD^{1,2}, and Sreenadha R. Vattam, MD^{1,2}

From: ¹The Departments of Anesthesiology and Pain Management, and ²Physical Medicine and Rehabilitation at the University of Texas Southwestern Medical Center, Dallas, TX.

Dr. Bruel is Assistant Professor, Departments of Physical Medicine & Rehabilitation and Anesthesiology & Pain Management, McDermott Center for Pain Management, UTSW Spine Center, University of Texas Southwestern Medical Center, Dallas, TX

Address correspondence:
Jonathan O. Jones, MD
The University of Texas Southwestern
Department of Anesthesiology and
Pain Management
5323 Harry Hines Boulevard
Dallas, TX 75390-9806
E-mail: jjones@parknet.pmh.org

Disclaimer: The Department of Anesthesiology and Pain Management at the University of Texas Southwestern supported the research.
Conflict of interest: None.

Manuscript received: 12/29/2009
Revised manuscript received:
02/10/2009
Accepted for publication: 02/13/2009

Free full manuscript:
www.painphysicianjournal.com

Background and Objectives: Although uncommon, symptomatic vertebral hemangiomas can be a painful condition limiting daily activities. Balloon kyphoplasty is a developing technique that has successfully been used in the treatment of vertebral hemangiomas as reported in a few publications. The aim of this paper is to describe 2 cases of painful vertebral hemangiomas effectively treated with percutaneous balloon kyphoplasty and review the current literature.

Design and Methods: A 38-year-old male with a painful L5 biopsy-proven hemangioma and a 75-year-old female with a painful T12, hemangioma MRI-proven both presented with thoraco-lumbar pain. Physical exams correlated with imaging findings and no neurological symptoms were present. Both patients received conservative management including physical therapy and a variety of spinal injections without benefit. Percutaneous balloon kyphoplasty was subsequently performed on each patient to relieve pain.

Results: After kyphoplasty, both patients' pain resolved immediately and they were able to resume previous levels of activity.

Conclusions: This case series demonstrates a successful response to vertebral augmentation using balloon kyphoplasty when other treatment modalities failed. When compared to traditional first line treatments such as vertebroplasty or lytic therapies, kyphoplasty may offer fewer procedural risks such as a decreased exposure to radiation, a decreased risk of excessive hemorrhage, and a decreased risk of cement leakage which may make it the preferred treatment of painful vertebral hemangiomas in the future.

Key words: Painful vertebral hemangioma, kyphoplasty, vertebroplasty

Pain Physician 2009; 12:E297-E303

Vertebral hemangiomas are most commonly non-painful benign findings but in 0.9 to 1.2% of individuals they can contribute to pain symptomatology (1). Clinical signs frequently include severe mechanical back pain worsened with movement without a radicular component (1). However, they may be associated with neurogenic pain when the hemangioma extends into the spinal canal or neural foramen (1,2).

Percutaneous vertebroplasty has been used extensively in the treatment of vertebral compression fractures but also has been used in the treatment of painful vertebral hemangiomas (3-8). Recently, balloon kyphoplasty has been applied and has met with success in the treatment of painful vertebral hemangiomas as well (9-11). To the best of our knowledge, there are 2 case reports in English describing kyphoplasty as a treatment for painful vertebral hemangioma-

mas and one observational study that prospectively followed 6 patients with painful and/or neurologically compromised lesions (9-11). Herein, we describe 2 cases of painful hemangiomas treated with percutaneous balloon kyphoplasty located in the thoracic and lumbar spine and review all of the current literature.

CASE I

After evaluation at multiple centers, a 38-year-old male presented to our pain center with debilitating back pain for 3 years with a past medical history significant for poly-substance abuse. After an injury 3 years prior to presentation, the patient began experiencing low back pain with radiation to his bilateral lower extremities. Multiple imaging studies of the lumbar spine demonstrated a small hemangioma in the superolateral aspect of the 5th lumbar vertebra without neural foraminal stenosis or involvement of the dorsal nerves. Four months prior to presentation, a percutaneous biopsy demonstrated multiple small blood vessels consistent with a hemangioma. He received multiple interventional treatments for his pain including epidural steroid injections and implantation and subsequent explantation of a dorsal column nerve stimulator. Al-

though these procedures provided some short-lived benefits, none adequately managed his pain.

At the time of presentation, the patient complained of a constant, aching low-back pain aggravated with activity without neurological compromise. Except for tenderness to palpation over the right paraspinal muscles and mildly over the 5th lumbar spinal process, all other physical exam findings were normal. Magnetic resonance imaging was repeated that demonstrated edema-like abnormal marrow signal in the left superolateral aspect of the 5th lumbar vertebra likely related to the biopsy and the finding of a 7 mm hemangioma in the 5th lumbar vertebral body (Figs. 1 and 2).

After discussing potential procedures including all of the risks, benefits, and potential complications, balloon kyphoplasty was performed in the standard fashion under sedation and local anesthetic. Each balloon was inflated under live fluoroscopy and a total of 4 mL of cement was placed without anterior or posterior spread. At follow-up, the patient reported 0-1/10 pain score on the VAS pain scale and that he has resumed all his previous activities due to the significant pain relief.

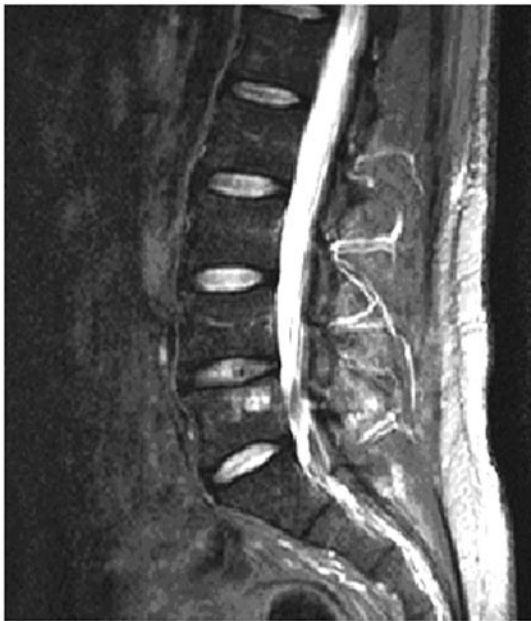

Fig. 1. T2-weighted image of L5 hemangioma located at the posterior vertebral body near the superior end-plate.

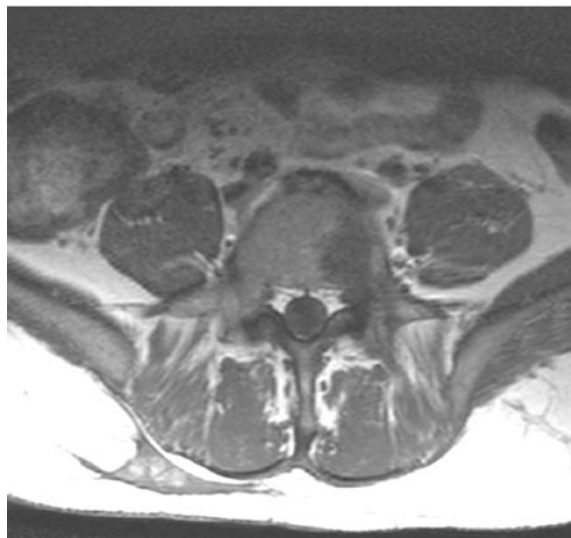


Fig. 2. T2-weighted image of L5 hemangioma located at the posterior vertebral body near the superior end-plate.

CASE II

A 75-year-old established female patient presented to our pain center complaining of a different quality of low back pain over the past month. She had a history of mild dementia, depression, 5 hip surgeries including bilateral hip replacement, left total knee arthroplasty, hysterectomy, and urinary incontinence requiring a sling procedure. Additionally, she has a history of bilateral sacroiliac joint pain, lumbar facet arthropathy, lumbar spondylosis, spinal stenosis with the left L4-L5 intervertebral disc impinging upon the left 5th lumbar nerve root, and bilateral cluneal nerve pain. She had previously been treated with lumbosacral median-branch nerve blocks and subsequent radiofrequency ablation and trigger point injections.

She reported pain of a different character in her middle to lower back without radiation that worsened with movement and reported a pain score of 10/10 on a VAS pain scale. Physical exam findings included tenderness to palpation on the thoracic and lumbar spine with step-offs appreciated in the low thoracic and upper lumbar spine. Suspicion for a pathological fracture was high and magnetic resonance imaging was obtained that demonstrated a T12 superior endplate compression fracture with no associated marrow

edema fracture and a small hemangioma at the border of the superior endplate (Fig. 3).

One month after her initial complaint, the patient consented to undergo balloon kyphoplasty at the T12 vertebral level to help relieve her pain. Under general anesthesia, balloon kyphoplasty was performed using a right transpedicular approach with a total of 6 mL of cement placed without anterior or posterior spread (Fig. 4). An approximate 3 to 5 mm reduction of the vertebral body was achieved (Fig. 5). At subsequent follow-up visits, the patient reported that her middle and lower back pain had totally resolved but continued to have generalized whole-body arthritic pain.

DISCUSSION

Because vertebral hemangiomas are rarely painful, determination of back pain etiology in the presence of a vertebral hemangioma can be difficult. Lesions generally become symptomatic when there is neural arch expansion, vertebral body enlargement, or direct compression of the thecal sac or nerve roots (7,8,12) and greater than 50% of patients with symptomatic vertebral hemangiomas present with pain (13).

Surgical, minimally invasive, and lytic therapies have been used to manage painful vertebral hemangiomas without neurological compromise with varying

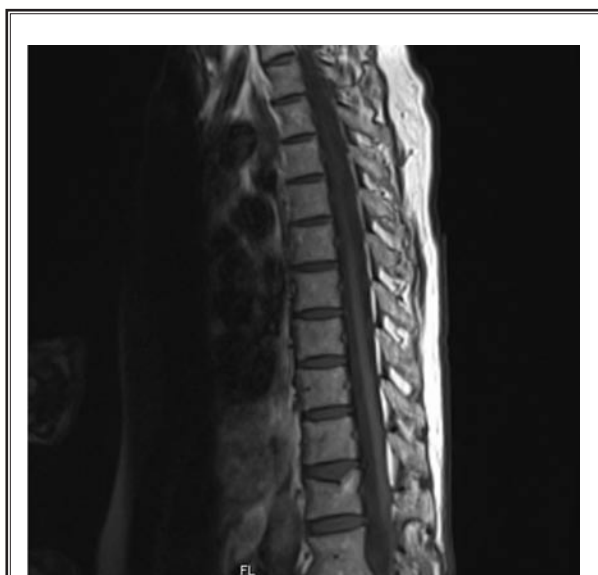

Fig. 3. T1-weighted image of T12 hemangioma located at the posterior vertebrae near the superior end-plate fracture.

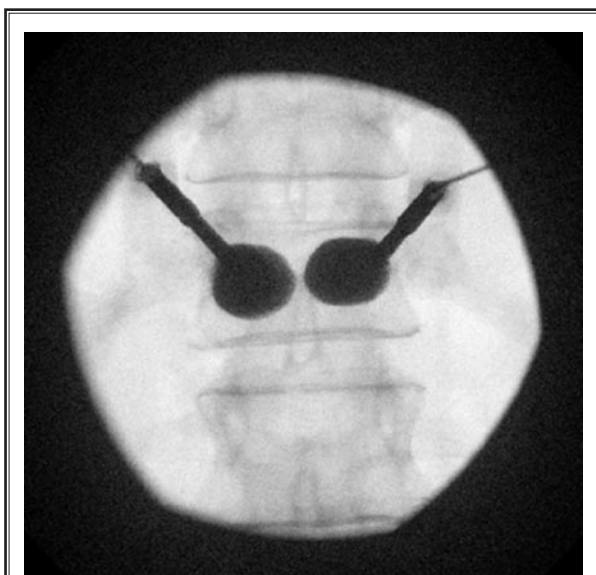


Fig. 4. Balloon inflation under fluoroscopy of T12 vertebrae.

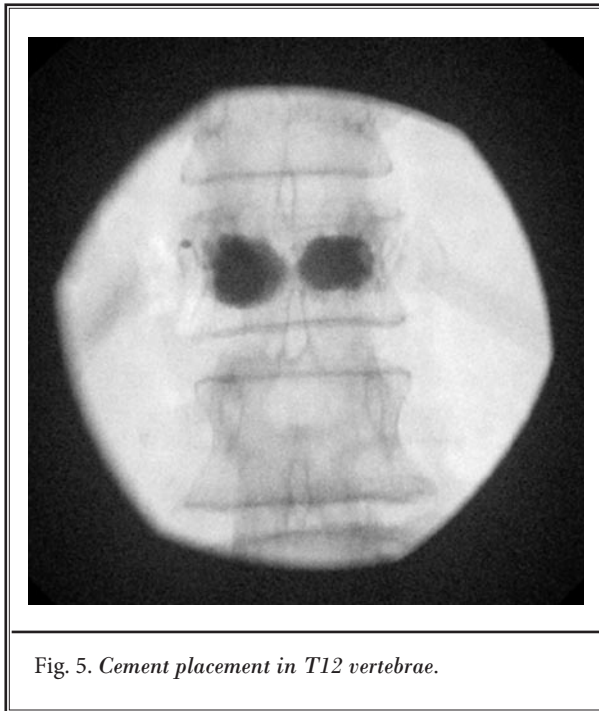


Fig. 5. Cement placement in T12 vertebrae.

results. Surgical removal is indicated with aggressive hemangiomas causing acute neurological compromise but may be complicated by excessive hemorrhage (2) or a consumptive coagulopathy (Kasabach-Merritt syndrome) (14). Emergency laminectomy should be performed in all cases of progressive neurological compromise (15).

Vertebral hemangiomas are radiosensitive and radiation therapy has been used successfully in the past and a review of 21 reports of 63 patients using radiation therapy revealed complete remission in 57%, partial remission in 32%, and no response in 11% (16). However, this therapy carries the risk of radiation-induced secondary sarcomas or the development of radionecrosis (17,18).

Transarterial embolization is often used prior to surgery to decrease blood loss and may be safer than radiation therapy but there have been few long-term studies on outcomes and complications. In a limited series, 2 patients with vertebral hemangiomas with neurological compromise treated solely with transarterial embolization failed to improve (19) but Acosta et al (7,8) reported improved pain in 4 patients receiving embolization. Additional concerns for embolization include anatomical anomalies (e.g. bilateral spinal ar-

teries) that may prohibit its use in certain cases and may not offer complete pain resolution (2). Additionally, angiography may not reveal the necessary feeding vessels to be embolized and may well be dangerous in the thoracic spine where a majority of painful vertebral hemangiomas are located (20,21). Percutaneous phenol or alcohol injections have also been used but have been with limited success and have been known to cause Brown-Sequard syndrome (22) and pathological fractures (23).

Percutaneous vertebroplasty, a relatively new technique for the management of aggressive vertebral hemangiomas, was developed in the 1980s by Galibert and colleagues (3) but was quickly applied to osteoporotic and metastatic fractures. Since then, several case reports have demonstrated significant pain relief from symptomatic vertebral hemangiomas with percutaneous vertebroplasty (4,24-28) (Table 1). Pain relief from vertebral augmentation is unclear but may be related to the stabilization of microfractures or compression fractures and from a PMMA-induced chemical lysis of nerve endings within the vertebral body (5,29,30).

The complication rate in the treatment of vertebral hemangiomas with vertebroplasty has been reported at 2.5% (31,32) and includes cement pulmonary embolism and transient worsening of pain (32,33). Nerve root pain from cement leakage can occur and necessitate treatment (5) but most symptoms are non-neurological, transitory, and subclinical while some may experience persistent symptoms requiring surgical extraction (32).

Percutaneous kyphoplasty has been suggested as an alternate therapy for painful vertebral hemangiomas in 3 publications that demonstrated short and long-term benefit (Table 1) (9-11). In most of the cases, percutaneous kyphoplasty resolved the patients' pain immediately and a few required additional procedures to become pain-free. Hadjipavlou et al (10) described sustained pain and neurological improvement in 6 patients at 6 months when using kyphoplasty alone and in conjunction with surgery and ethanol ablation. The authors (10) suggested that kyphoplasty might not be limited to painful hemangiomas but could also be used with neurological compromise with good outcomes. Case reports by Atalay et al (9) and Zapalowicz et al (11) described positive outcomes in 2 patients without complications. In this case series, both patients' pain completely resolved shortly after undergoing the procedure without any complications.

Table 1. Summary of vertebral augmentation for painful vertebral hemangiomas without neurological compromise.

Author, Date	Type of Publication	Number Patients	Type of Treatment	Outcomes	Notes
Hadjipavlou et al 2007 (10)	Prospective, observational	6	Balloon Kyphoplasty (along with ethanol in 2 cases & laminectomy in 2 cases)	Immediate & sustained relief at 6 months	Recommends kyphoplasty as sole treatment or with alcohol ablation as adjunct
Acosta et al 2006 & 2008 (7,8)	Retrospective review	4	Vertebroplasty (all had interosseous lesions)	3/4 (75%) experienced improvement	Algorithm suggests vertebroplasty or embolization for painful hemangiomas as 1st line treatment
Cohen et al 2004 (4)	Retrospective review	31	Vertebroplasty	7/31 (23%) required same or increased analgesics at 1 week	5/148 (3.4%) patients developed nerve root pain from cement leakage
Zapalowicz et al 2008 (11)	Case report	1	Balloon Kyphoplasty	Immediate & sustained relief at 13 months	Used kyphoplasty to avoid potential leakage
Fuwa et al 2006 (6)	Case report	1	Pedunculoplasty (Vertebroplasty)	Immediate & sustained relief at 6 months	Symptomatic neural arch hemangioma can be treated with PMMA
Atalay et al 2006 (9)	Case report	1	Sacroplasty (Balloon Kyphoplasty)	Immediate & sustained relief	Balloon kyphoplasty is effective and safer than open surgery.
Feydy et al 1996 (4)	Case report	2	Cervical Vertebroplasty	Immediate & sustained relief at 6 & 9 months	

Percutaneous kyphoplasty has several benefits over vertebroplasty including a decreased risk of cement leakage. Compared to a rate of up to 65% with vertebroplasty, kyphoplasty has an extravasation rate of less than 10%, theoretically leading to fewer complications than vertebroplasty (34-37). The majority of complications from vertebral augmentation arise from extravasation of cement and consequently any technique that decreases this event would be beneficial. The choice of kyphoplasty over vertebroplasty in the 2 patients presented in this series was largely based upon a decreased extravasation rate with kyphoplasty.

Hemangiomas are generally intraosseous lesions (7,8) but may also cause vertebral compression fractures as illustrated in one of the cases presented. Therefore, the added benefit of potentially restoring vertebral height when compared to vertebroplasty suggests that kyphoplasty could potentially treat 2 sources of pain—the hemangioma itself and the vertebral compression fracture (5,29,30). In fact, it may be difficult to distinguish whether the compression fracture or the hemangioma is the pain generator. The decision to use kyphoplasty instead of vertebroplasty in the second case was in part for height restoration.

Vertebroplasty and transarterial embolization has

been suggested as the preferred treatments in an algorithm by Acosta and colleagues (7,8) when conservative therapy failed. However, they did not include any cases of vertebral hemangiomas treated with kyphoplasty likely because it remains an emerging technique. With limitations on arterial embolization and lytic therapies as well as an increased rate of cement extravasation with vertebroplasty, balloon kyphoplasty may offer a safer and more effective primary treatment option than previously described techniques. Additionally, adjuvant treatments such as radiation or lytic therapy can be used in conjunction or if pain relief was not complete after kyphoplasty (10,38).

Considering the limitations and known complications of surgery, transarterial embolization, lytic therapies, and vertebroplasty, kyphoplasty may offer a less invasive technique to treat painful hemangiomas without neurological compromise. Although controversial, it treats the 2 potential pain generators and has the ability to restore vertebral height while also having a decreased rate of cement extravasation compared to vertebroplasty. Further research needs to be completed prior to any further recommendations being made, but in our pain clinics, kyphoplasty is the first line treatment for painful vertebral hemangiomas without neurological compromise.

REFERENCES

1. Deramond H, Cotton A, Depriester C. Benign tumors. In: Deramond H, Cotton A (eds). *Percutaneous Vertebroplasty*. Springer, New York 2002; 138-153.
2. Laredo JD, Reizine D, Bard M, Merland JJ. Vertebral hemangiomas: Radiologic evaluation. *Radiology* 1986; 183:189.
3. Galibert P, Deramond H, Rosat P, Le Gars D. Preliminary note on the treatment of vertebral angioma by percutaneous acrylic vertebroplasty. *Neurochirurgie* 1987; 33:166-168.
4. Feydy A, Cognard C, Miaux Y, Sola Martínez MT, Weill A, Rose M, Chiras J. Acrylic vertebroplasty in symptomatic cervical vertebral haemangiomas: Report of 2 cases. *Neuroradiology* 1996; 38:389-391.
5. Cohen JE, Lylyk P, Ceratto R, Kaplan L, Umanskyt F, Gomori JM. Percutaneous vertebroplasty: Technique and results in 192 procedures. *Neurol Res* 2004; 26:41-49.
6. Fuwa S, Numaguchi Y, Kobayashi N, Saida Y. Percutaneous pediculoplasty for vertebral hemangioma involving the neural arch: A case report. *Cardiovasc Intervent Radiol* 2008; 31:189-192.
7. Acosta FL Jr, Sanai N, Chi JH, Dowd CF, Chin C, Tihan T, Chou D, Weinstein PR, Ames CP. Comprehensive management of symptomatic and aggressive vertebral hemangiomas. *Neurosurg Clin N Am* 2008; 19:17-29.
8. Acosta FL Jr, Dowd CF, Chin C, Tihan T, Ames CP, Weinstein PR. Current treatment strategies and outcomes in the management of symptomatic vertebral hemangiomas. *Neurosurgery* 2006; 58:287-295.
9. Atalay B, Caner H, Yilmaz C, Altinors N. Sacral kyphoplasty for relieving pain caused by sacral hemangioma. *Spinal Cord* 2006; 44:196-199.
10. Hadjipavlou A, Tosounidis T, Gaitanis I, Kakavelakis K, Katonis P. Balloon kyphoplasty as a single or as an adjunct procedure for the management of symptomatic vertebral haemangiomas. *J Bone Joint Surg [Br]* 2007; 89-B:495-502.
11. Zapalowicz K, Skora P, Myslinski R, Karnicki F, Radek A. Balloon kyphoplasty for painful C-7 vertebral hemangioma. Case Report. *J Neurosurg Spine* 2008; 8:458-461.
12. Dagi TF, Schmidek HH. Vascular tumors of the spine. In: Sundaresan N, Schmidek HH, Schiller AL, Rosenthal DI (eds) *Tumors of the Spine: Diagnosis and Clinical Management*. Philadelphia, W.B. Saunders Co., 1990: 181-191.
13. Pastushyn AI, Slin'ko EI, Mirzoyeva GM. Vertebral hemangiomas: Diagnosis, management, natural history and clinicopathological correlates in 86 patients. *Surg Neurol* 1998; 50:535-547.
14. Scott DL, Pedlow FX, Hecht AC, Hornicek FJ. Primary benign and malignant extradural spine tumors. In: Frymoyer JW, Wiesel SW (eds). *The Adult and Pediatric Spine*. Third ed. Vol. 1.: Lippincot Williams, and Wilkens, Philadelphia 2004; 207-210.
15. Fox MW, Onofrio BM. The natural history and management of symptomatic and asymptomatic vertebral hemangiomas. *J Neurosurg* 1993; 78:36-45.
16. Heyd R, Strassmann G, Filipowicz I, Borowsky K, Martin T, Zamboglou N. Radiotherapy in vertebral hemangioma [in German]. *Rontgenpraxis* 2001; 53:208-220.
17. Guedea F, Majó J, Guardia E, Canals E, Craven-Bartle J. The role of radiation therapy in vertebral hemangiomas without neurological signs. *Int Orthop* 1994; 18:77-79.
18. Nguyen JP, Djindjian M, Gaston A, Gherardi R, Benhaiem N, Caron JP, Poirier J. Vertebral hemangiomas presenting with neurologic symptoms. *Surg Neurol* 1987; 27:391-397.
19. Smith TP, Koci T, Mehringer CM, Tsai FY, Fraser KW, Dowd CF, Higashida RT, Halbach VV, Hieshima GB. Transarterial embolization of vertebral hemangioma. *J Vasc Interv Radiol* 1993; 4:681-685.
20. Templin CR, Stambough JB, Stambough JL. Acute spinal cord compression caused by vertebral hemangioma. *Spine J* 2004; 4:595-600.
21. Ahn H, Jhaveri S, Yee A, Finkelstein J. Lumbar vertebral hemangioma causing cauda equina syndrome: A case report. *Spine* 2005; 30:E662-E664.
22. Niemeyer T, McClellan J, Webb J, Jaspán T, Ramli N. Brown-Sequard syndrome after management of vertebral hemangioma with intraserial alcohol. A case report. *Spine* 1999; 24: 1845-1847.
23. Doppman JL, Oldfield EH, Heiss JD. Symptomatic vertebral hemangiomas: treatment by means of direct intraserial injection of ethanol. *Radiology* 2000; 214: 341-348.
24. Deramond H, Depriester C, Galibert P, Le Gars D. Percutaneous vertebroplasty with polymethylmethacrylate: Technique, indications, and results. *Radiol Clin North Am* 1998; 36:533-546.
25. Cotten A, Deramond H, Cortet B, Lejeune JP, Leclerc X, Chastanet P, Clarisse J. Preoperative percutaneous injection of methyl methacrylate and N-butyl cyanoacrylate in vertebral hemangiomas. *AJNR Am J Neuroradiol* 1996; 17:137-142.
26. Ide C, Gangi A, Rimmelin A, Beaujeux R, Maitrot D, Buchheit F, Sellal F, Diemann JL. Vertebral haemangiomas with spinal cord compression: The place of preoperative percutaneous vertebroplasty with methyl methacrylate. *Neuroradiology* 1996; 38:585-589.
27. Cortet B, Cotten A, Deprez X, Deramond H, Lejeune JP, Leclerc X, Chastanet P, Duquesnoy B, Delcambre B. Vertebroplasty with surgical decompression for the treatment of aggressive vertebral hemangiomas. A report of three cases. *Rev Rhum Ed Fr* 1994; 61:14-20.
28. Brunot S, Berge J, Barreau X, Ménégon P, Dousset V. Long term clinical follow up of vertebral hemangiomas treated by percutaneous vertebroplasty. *J Radiol* 2005; 214:314-318.
29. Cotten A, Boutry N, Cortet B, Assaker R, Demondion X, Leblond D, Chastanet P, Duquesnoy B, Deramond H. Percutaneous vertebroplasty: State of the art. *Radiographics* 1998; 18:311-320.
30. San Millán Ruíz D, Burkhardt K, Jean B, Muster M, Martin JB, Bouvier J, Fasel JH, Rüfenacht DA, Kurt AM. Pathology findings with acrylic implants. *Bone* 1999; 25(2 Suppl):85S-90S.
31. Chiras J, Depriester C, Weill A, Sola-Martinez MT, Deramond H. Percutaneous vertebral surgery. Techniques and indications. *J Neuroradiol [Fr]* 1997; 24:45-59.
32. DePalma MJ, Slipman CW. Vertebroplasty. In: Slipman CW, Derby R, Simeone FA, Mayer TG (eds). *Interventional Spine*. W.B. Saunders Co., Philadelphia 2008; 495-505.
33. Jensen ME, Evans AJ, Mathis JM, Kallmes DF, Cloft HJ, Dion JE. Percutaneous polymethylmethacrylate vertebroplasty

- ty in the treatment of osteoporotic vertebral compression fractures: Technical aspects. *AJNR Am J Neuroradiol* 1997; 18:1897-1904.
34. Phillips FM, Ho E, Campbell-Hupp M, McNally T, Todd Wetzel F, Gupta P. Early radiographic and clinical results of balloon kyphoplasty for the treatment of osteoporotic vertebral compression fractures. *Spine* 2003; 28:2260-2265.
35. Coumans JV, Reinhardt MK, Lieberman IH. Kyphoplasty for vertebral compression fractures: 1-year clinical outcomes from a prospective study. *J Neurosurg* 2003; 99:44-50.
36. Lieberman IH, Dudeney S, Reinhardt MK, Bell G. Initial outcome and efficacy of 'kyphoplasty' in the treatment of painful osteoporotic vertebral compression fractures. *Spine* 2001; 26:1631-1638.
37. Togawa D, Lieberman IH. Kyphoplasty. In: Slipman CW, Derby R, Simeone FA, Mayer TG (eds). *Interventional Spine*. Philadelphia, PA 2008; 507-513.
38. Chi JH, Gokaslan ZL. Vertebroplasty and kyphoplasty for spinal metastases. *Curr opin Support Palliat Care* 2008; 2:9-13.

