

## Evidence-Based Medicine



## An Algorithmic Approach for Clinical Management of Chronic Spinal Pain

Laxmaiah Manchikanti, MD<sup>1</sup>, Standiford Helm, MD<sup>2</sup>, Vijay Singh, MD<sup>3</sup>, Ramsin M. Benyamin, MD<sup>4</sup>, Sukdeb Datta, MD<sup>5</sup>, Salim M. Hayek, MD, PhD<sup>6</sup>, Bert Fellows, MA<sup>7</sup> and Mark V. Boswell, MD, PhD<sup>8</sup>

From: <sup>1,7</sup>Pain Management Center of Paducah, Paducah, KY; <sup>2</sup>Pacific Coast Pain Management Center, Laguna Hills, CA; <sup>3</sup>Pain Diagnostics Associates, Niagara, WI; <sup>4</sup>Millennium Pain Center, Bloomington, IL; <sup>5</sup>Vanderbilt University Medical Center, Nashville, TN; <sup>6</sup>University Hospitals of Cleveland and Outcomes Research Consortium, Cleveland, OH; and; <sup>8</sup>Texas Tech University Health Sciences Center, Lubbock, TX.

Author affiliation information is provided on page E257.

Address correspondence: Laxmaiah Manchikanti, MD  
2831 Lone Oak Road  
Paducah, Kentucky 42003  
E-mail: drlm@thepainmd.com

Disclaimer: There was no external funding in preparation of this manuscript. The authors are solely responsible for the content of this article. No statement in this article should be construed as an official position of ASIPP.

Conflict of Interest: Dr. Datta receives research support from Sucampo Pharmaceuticals and an honorarium from Smith and Nephew. Dr. Hayek is a consultant for Boston Scientific, Valencia, CA.

Manuscript received: 05/24/2009

Revised manuscript received 06/06/2009

Accepted for publication: 06/26/2009

Free full manuscript: [www.painphysicianjournal.com](http://www.painphysicianjournal.com)

Interventional pain management, and the interventional techniques which are an integral part of that specialty, are subject to widely varying definitions and practices. How interventional techniques are applied by various specialties is highly variable, even for the most common procedures and conditions. At the same time, many payors, publications, and guidelines are showing increasing interest in the performance and costs of interventional techniques.

There is a lack of consensus among interventional pain management specialists with regards to how to diagnose and manage spinal pain and the type and frequency of spinal interventional techniques which should be utilized to treat spinal pain. Therefore, an algorithmic approach is proposed, providing a step-by-step procedure for managing chronic spinal pain patients based upon evidence-based guidelines. The algorithmic approach is developed based on the best available evidence regarding the epidemiology of various identifiable sources of chronic spinal pain.

Such an approach to spinal pain includes an appropriate history, examination, and medical decision making in the management of low back pain, neck pain and thoracic pain. This algorithm also provides diagnostic and therapeutic approaches to clinical management utilizing case examples of cervical, lumbar, and thoracic spinal pain.

An algorithm for investigating chronic low back pain without disc herniation commences with a clinical question, examination and imaging findings. If there is evidence of radiculitis, spinal stenosis, or other demonstrable causes resulting in radiculitis, one may proceed with diagnostic or therapeutic epidural injections. In the algorithmic approach, facet joints are entertained first in the algorithm because of their commonality as a source of chronic low back pain followed by sacroiliac joint blocks if indicated and provocation discography as the last step. Based on the literature, in the United States, in patients without disc herniation, lumbar facet joints account for 30% of the cases of chronic low back pain, sacroiliac joints account for less than 10% of these cases, and discogenic pain accounts for 25% of the patients. The management algorithm for lumbar spinal pain includes interventions for somatic pain and radicular pain with either facet joint interventions, sacroiliac joint interventions, or intradiscal therapy. For radicular pain, epidural injections, percutaneous adhesiolysis, percutaneous disc decompression, or spinal endoscopic adhesiolysis may be performed. For non-responsive, recalcitrant, neuropathic pain, implantable therapy may be entertained.

In managing pain of cervical origin, if there is evidence of radiculitis, spinal stenosis, post-surgery syndrome, or other demonstrable causes resulting in radiculitis, an interventionalist may proceed with therapeutic epidural injections. An algorithmic approach for chronic neck pain without disc herniation or radiculitis commences with clinical question, physical and imaging findings, followed by diagnostic facet joint injections. Cervical provocation discography is rarely performed. Based on the literature available in the United States, cervical facet joints account for 40% to 50% of cases of chronic neck pain without disc herniation, while discogenic pain accounts for approximately 20% of the patients. The management algorithm includes either facet joint interventions or epidural injections with surgical referral for disc-related pain and rarely implantable therapy.

In managing thoracic pain, a diagnostic and therapeutic algorithmic approach includes either facet joint interventions or epidural injections.

**Key words:** Algorithmic approach, chronic pain, chronic spinal pain, diagnostic interventional techniques, therapeutic interventional techniques, comprehensive evaluation, documentation, medical decision making.

**Pain Physician 2009; 12:E225-E264**

Interventional techniques and the specialty of interventional pain management continue to emerge. Available evidence documents a wide degree of variance in the definition and practice of interventional pain management and interventional techniques. Application of interventional techniques by multiple specialties is highly variable for even the most commonly performed procedures and treated conditions (1-12). Manchikanti et al (6-11) and others (2-5) have shown an exponential growth of interventional techniques. To combat the problem of overuse, and to some extent, abuse, multiple recommendations have been made to strengthen safeguards to prevent improper payment for interventional pain management services (2). In fact, multiple insurers have been implementing many regulations and the Centers for Medicare and Medicaid Services (CMS) has issued a program memorandum to this effect (13). Manchikanti et al (8) recommended that Congress enact interventional pain management procedure standards mandating that these procedures only be performed in either a facility setting or in an accredited office and only by well-trained, qualified physicians.

Many guidelines, systematic reviews, Cochrane reviews, and peer-reviewed articles pertaining to interventional pain management have been published (1,13-49). However, none of the guidelines have been in a position to provide guidance on patient care.

Consequently, the American Society of Interventional Pain Physicians (ASIPP) guidelines (1) and International Spine Intervention Society (ISIS) guidelines (50,51) provided an algorithmic approach. ASIPP guidelines developed an algorithmic approach based on the structural basis of spinal pain and incorporated acceptable evidence of diagnostic and therapeutic interventional techniques available in managing chronic spinal pain. However, no case specific or patient specific approach in the changing paradigm of modern medicine, with its major focus on evidence-based medicine (EBM), has been available. Thus, an algorithmic approach for management of chronic low back pain is described to assist interventional pain physicians in the clinical practice of providing care, which is of maximum benefit to the patient and least expensive.

## **1.0 AN ALGORITHMIC APPROACH**

An algorithm is a step-by-step procedure for solving a problem in a finite amount of time. An algorithmic approach is the implementation of guidelines in

a step-by-step fashion. At present there is a lack of consensus among interventional pain management specialists regarding diagnostic and management criteria, and type and frequency of interventions. The literature focuses on the complications attributed to the use of epidural steroids and extrapolates the same to the entire arena of interventional pain management. Thus, various limitations of interventional techniques have arisen from false impressions.

The algorithmic approach described here is based on the best available evidence on the epidemiology of various identifiable sources of chronic spinal pain. This algorithmic approach is designed to promote the efficient use of interventional pain management techniques based on the best available evidence. However, this may not be applicable for each and every patient. The purpose of the described algorithmic approach is to provide a disciplined use of interventional techniques in managing spinal pain. This includes evaluation and diagnostic and therapeutic approaches, which in turn avoid unnecessary care and poorly documented practices.

## **2.0 AN ALGORITHMIC APPROACH TO SPINAL PAIN**

### **2.1 Comprehensive Algorithm**

Figure 1 illustrates an algorithmic approach for evaluation and management of a chronic pain patient. Appropriate history, physical examination, and medical decision-making are essential to provide appropriate documentation and patient care. Not covered in this basic algorithm are socioeconomic issues and psychosocial factors that may be important in the clinical decision-making process. Related manuscripts provide principles of EBM, scope, and impact of chronic spinal pain, guidance on diagnostic and therapeutic interventional techniques, and documentation requirements (52-56). A comprehensive and complete evaluation will assist in complying with the regulations and providing appropriate care while fulfilling an algorithmic approach.

### **2.2 Low Back Pain**

#### **2.2.1 Diagnosis**

Figure 2 illustrates a diagnostic algorithmic approach for chronic low back pain without disc herniation. This algorithm for the investigation of low back pain is based on the best available evidence on the

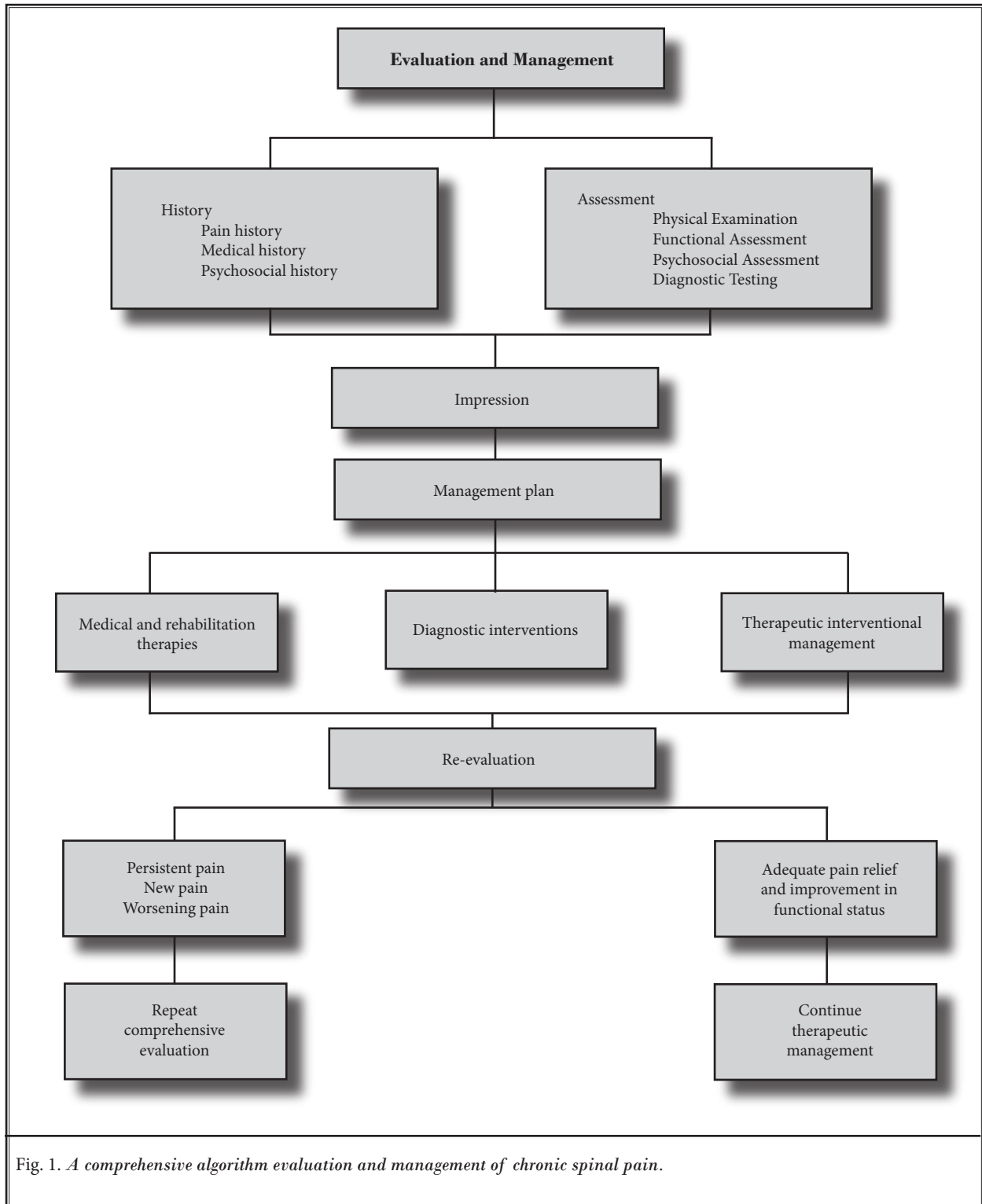


Fig. 1. A comprehensive algorithm evaluation and management of chronic spinal pain.

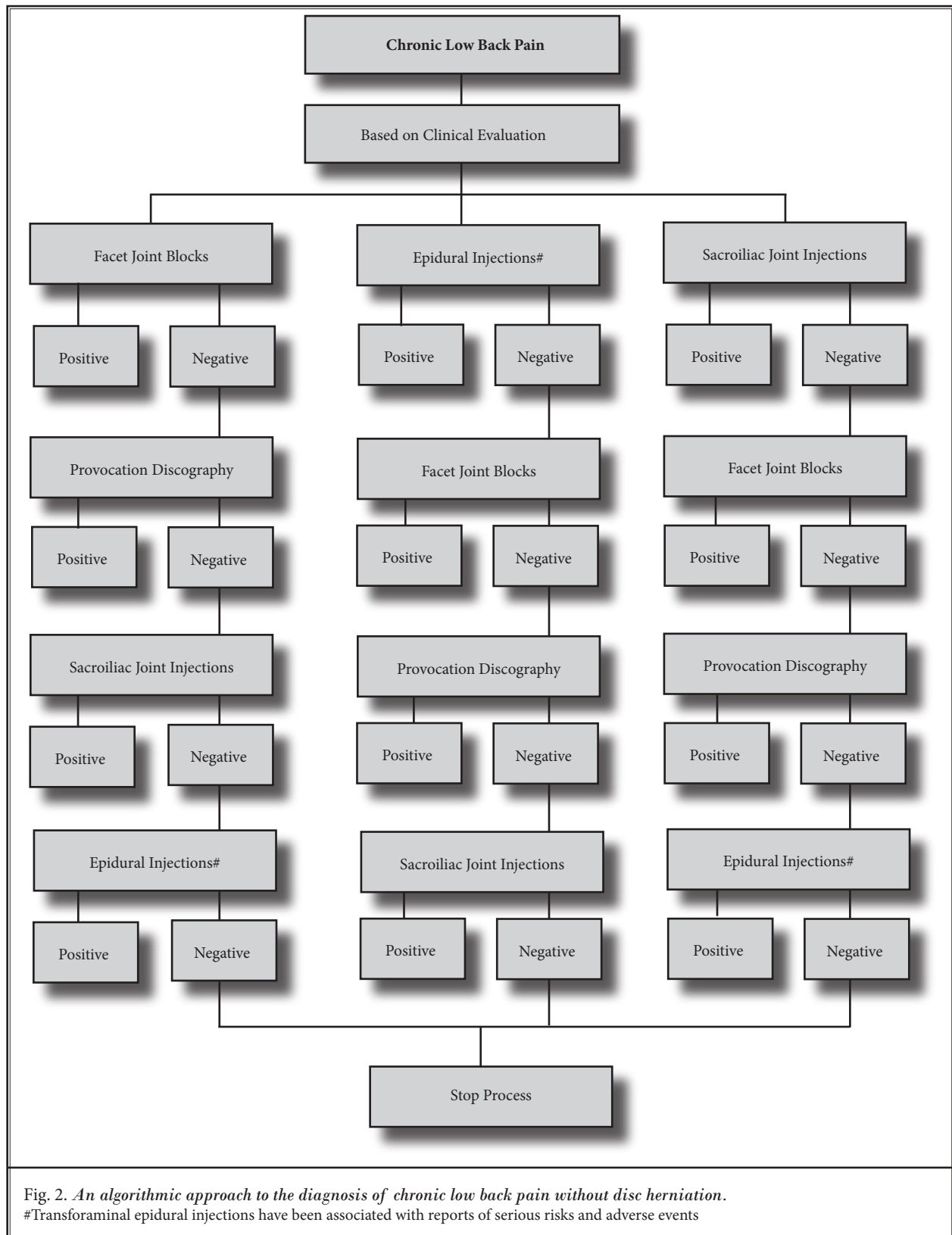


Fig. 2. An algorithmic approach to the diagnosis of chronic low back pain without disc herniation.  
 #Transforaminal epidural injections have been associated with reports of serious risks and adverse events

epidemiology of various identifiable sources of chronic low back pain. Kuslich et al (57) identified intervertebral discs, facet joints, ligaments, fascia, muscles, and nerve root dura as tissues capable of transmitting pain in the low back. Facet joint pain, discogenic pain, nerve root pain, and sacroiliac joint pain have been proven to be common causes of pain with proven diagnostic techniques (22,23,28,58-64). In a prospective evaluation (65), the relative contributions of various structures in patients with chronic low back pain who failed to respond to conservative modalities of treatments, with lack of radiological evidence to indicate disc protrusion or radiculopathy, were evaluated utilizing controlled, comparative, double diagnostic blocks. In this study, 40% of the patients were shown to have facet joint pain, 26% discogenic pain, 2% sacroiliac joint pain, and possibly, 13% segmental dural-nerve root irritation. No cause was identified in 19% of the patients.

If there is evidence of radiculitis, spinal stenosis, or other demonstrable causes resulting in radiculitis, one may proceed with diagnostic transforaminal or therapeutic epidural injections (64). Otherwise an algorithmic approach should include the diagnostic interventions with facet joint blocks, sacroiliac joint injections, followed by discography. Lumbar discography at the present time suffers from significant controversy with Level II-2 evidence (22). In contrast, facet joint nerve blocks in the diagnosis of lumbar facet joint pain provide higher evidence with Level I or Level II-1 (23). However, sacroiliac joint injections provide Level II-2 evidence (28).

An algorithm for investigating chronic low back pain without disc herniation commences with clinical questions, physical findings, and findings of radiological investigations. Radiological investigations should be obtained if the history and physical exam findings indicate their need. Controlled studies have illustrated a prevalence of lumbar facet joint pain in 21% to 41% of patients with chronic low back pain (23,58-61,65-70) and 16% in post laminectomy syndrome (71). The average prevalence of 31% (95% CI 28%-33%) and false-positive rate of 30% (95% CI 27%-33%) was shown by Datta et al (23). Thus, facet joints are entertained first in the algorithm because of their commonality as a source of chronic low back pain, available treatment, and ease of performance of the blocks. Further, among all the diagnostic approaches in the lumbosacral spine, medial branch blocks have the best evidence (Level I) with the ability to rule out false-positives (27% to 47%) and demonstrated validity with multiple confounding

factors, including psychological factors (72,73), exposure to opioids (74), and sedation (75-77). In this approach, investigation of facet joint pain is considered as a prime investigation, ahead of disc provocation and sacroiliac joint blocks. Multiple studies have indicated that facet joint pain may be bilateral in 60% to 79% of cases, involving at least 2 joints and involving 3 joints in 21% to 37% of patients (67-69).

Diagnostic blocks must be performed under controlled conditions. In the United States, commonly performed diagnostic blocks are often accomplished with 2 separate local anesthetics in what is referred to as controlled comparative local anesthetic blocks. Due to the innocuous nature of lumbar facet joint nerve blocks, it is recommended that all blocks be performed in one setting. ISIS guidelines recommend a multi-level evaluation with a screening test and multiple confirmatory blocks (51). However, in this algorithm, based on the clinical examination, only 2 blocks are performed provided the first block was positive, thus avoiding a screening block and repeat blocks for separate joints (51). If a patient experiences at least 80% relief with the ability to perform previously painful movements within a time frame that is appropriate for the duration of the local anesthetic used and the duration of relief with the second block relative to the first block is commensurate with the respective local anesthetic employed in each block, then a positive diagnosis is made. In this algorithm, to pursue the sacroiliac joint as the pain generator, pain must be caudal to L5 and must be positive for at least some provocative tests, along with tenderness over the sacroiliac joint (28,54,78). Sacroiliac joint blocks have a Level II-2 evidence in the diagnosis of sacroiliac joint pain utilizing comparative controlled local anesthetic blocks. The prevalence of sacroiliac joint pain is estimated to range between 2% and 38% using a double block paradigm in specific study populations (28,62,63,65,78-83). The false-positive rates of single, uncontrolled, sacroiliac joint injections have been shown to be 20% to 54% (28). However, there has been a paucity of the evidence in the evaluation of the effectiveness of sacroiliac joint blocks in the diagnosis of sacroiliac joint pain (28,62,63).

One or both sacroiliac joints may be blocked utilizing controlled comparative local anesthetic block paradigms in the United States. The relief obtained should be 80% with the ability to perform previously painful movements and also should be concordant based on the local anesthetic injection with bupivacaine injection outlasting lidocaine injection (28,54).

If pain is not suggestive of facet joint or sacroiliac joint origin, then the epidural injection algorithm is followed. Caudal and lumbar interlaminar epidurals are non-specific as far as identifying the source of pain. If a patient fails to respond to epidural injections, the discogenic approach may be undertaken.

Lumbar provocation discography is seldom performed as an initial test in the present algorithm. Provocation lumbar discography is performed as the first test in only specific settings of suspected discogenic pain and availability of a definitive treatment is offered solely for diagnostic purposes prior to fusion. Otherwise, once facet joint pain, and if applicable sacroiliac joint pain, is ruled out and the patient fails to respond to at least 2 fluoroscopically directed epidural injections, discography may be pursued if determination of the disc as the source of pain is crucial. Magnetic resonance imaging (MRI) will assist in ruling out any red flags and disc herniation, but will not determine if the disc is the cause of the pain. Hancock et al (78) in a systematic review of tests designed to identify the disc as a pain generator concluded that centralization was the only clinical feature associated with a discogenic pain etiology (84). Further, this systematic review (78) also showed low sensitivity and specificity of various tests, including radiologic imaging, in determining whether or not the disc is a primary source of low back pain. Lumbar provocation discography has been shown to reveal abnormalities in asymptomatic patients with normal MRI scans (85,86). Thus, when performed appropriately, discography can enhance sensitivity and specificity compared to non-provocational imaging. Discography continues to be the only diagnostic tool capable of establishing whether or not a particular disc is painful, irrespective of the presence or absence of degenerative pathology observed on other imaging modalities. Provocation discography continues to be controversial with respect to diagnostic accuracy (22,87-89), utilization (4-11,90), and its impact on surgical volume (91,92). However, lumbar discography has been refined substantially since its inception and its diagnostic accuracy has been established as Level II-2 (22,39,54,89). In order to be valid, the provocation discography must be performed utilizing strict criteria of having concordant pain in one disc with at least 2 negative discs, one above and one below except when the L5/S1 is involved. In that case, only one negative disc is needed along with the suspect disc (L5/S1 in this case) displaying evoked intensity of a pain score of 7 on a scale of 0 to 10 or 70% of worst spontaneous pain (i.e., worst pain of 7 =  $7 \times 70\% = 5$ ) (22,54).

### 2.2.1.1 Diagnostic Efficiency

Under the present algorithmic approach, once facet joint pain is excluded, the patient may be treated with epidural injections or sacroiliac joint blocks may be pursued provided the patient meets the criteria for sacroiliac joint blocks. Lumbar provocation discography is the last step in the diagnostic algorithm and is utilized only when appropriate treatment can be performed if disc abnormality is noted. The only other indication is to satisfy patients' impressions if the patient does not improve with any other modalities of treatments. In absence of effective treatments for discogenic pain, establishing the diagnosis by virtue of discography may prevent patients from undergoing any further unnecessary testing or treatment. Studies have shown the effectiveness of epidural injections in discogenic pain, with or without the use of steroids, after facet joint pain and other sources of low back pain have been eliminated (93-95). In addition, the relief derived from discogenic pain with caudal epidural injections, with or without steroids, was equivalent to relief in managing disc herniation and superior to the relief obtained by patients with either spinal stenosis or post lumbar laminectomy syndrome (93-98).

Given the realities of health care in the United States and the available evidence from the literature, it appears that lumbar facet joints account for 30% of cases of chronic low back pain, sacroiliac joint pain accounts for less than 10% of cases, and discogenic pain accounts for 25% of cases.

Under this algorithm, approximately 70% of low back pain patients would undergo investigations of their facet joints, with approximately 30% proving positive and requiring no other investigations. Of the 70% remaining, approximately 10% will require sacroiliac joint blocks and perhaps 30% will prove positive. The remaining 60% of 70% and original 30% not undergoing facet injections — overall 60% to 70% — will probably undergo epidural injections and approximately 65% will respond to epidural injections and the remaining 20% of 35% will be candidates for provocation discography if a treatment can be provided (1,18-21,93-98).

### 2.2.2 Management Algorithm

#### 2.2.2.1 Somatic Pain Algorithm

Figure 3 illustrates therapeutic algorithmic management. The patients testing positive for facet joint pain may undergo either therapeutic facet joint nerve blocks or radiofrequency neurotomy based on the pa-

tients' preferences, values, and physician expertise. However, there is no evidence for lumbar intraarticular facet joint injections (23). In contrast, based on the review of included therapeutic studies (99-101), Level II-1 to II-2 evidence is presented for lumbar facet joint nerve blocks with an indicated level of evidence of II-2 to II-3 for lumbar radiofrequency neurotomy (23,99-103).

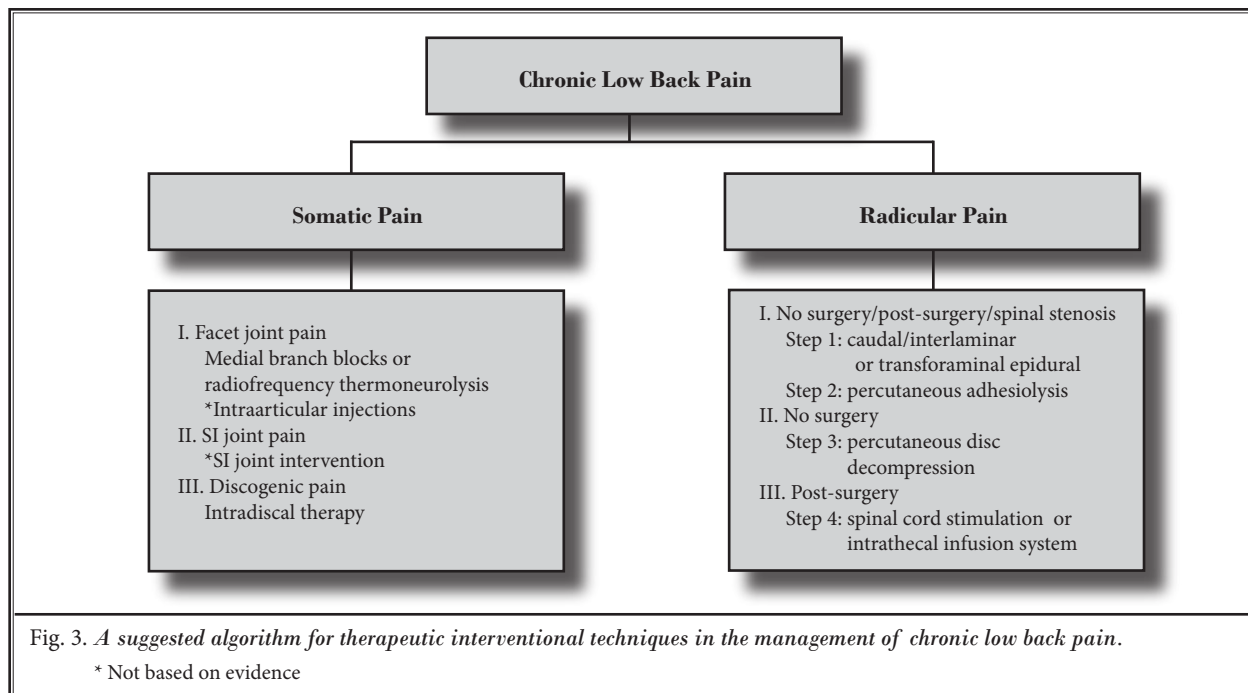
The next modality of treatment is epidural injections. Epidural injections have been shown to present with variable evidence. A recent systematic review of caudal epidural injections in the management of chronic low back pain (93) showed Level I evidence for relief of chronic pain secondary to disc herniation or radiculitis and discogenic pain without disc herniation or radiculitis (94-96). Further, the indicated evidence was Level II-1 or II-2 for caudal epidural injections in managing chronic pain of post lumbar surgery syndrome and spinal stenosis (93,97,98). A systematic review of therapeutic lumbar transforaminal epidural steroid injections (21) showed an indicated level of evidence of Level II-1 for short-term relief and Level II-2 for long-term relief in managing chronic lumbar radicular pain. The majority of the patients derived from the diagnostic algorithmic approach do not have radicular pain or disc herniation, thus, transforaminal epidural injections are applied with the proper indica-

tions for patients with radiculitis (21). In contrast, the evidence for lumbar interlaminar epidurals is lacking (18) with a paucity of contemporary literature and lack of fluoroscopically directed studies, and an indicated evidence of Level II-2 for short-term relief of pain of disc herniation or radiculitis with limited or lack of evidence for other conditions.

The indicated evidence for therapeutic sacroiliac joint interventions (28,62,63) is Level II-2 with no evidence for sacroiliac joint neurotomy. Finally, the evidence for intradiscal procedures with thermal annular technology is also limited. The systematic review of the effectiveness of thermal annular procedures in treating discogenic low back pain (20) showed an indicated level of evidence of II-2 for IDET, Level II-3 for radiofrequency annuloplasty, and limited or lack of evidence for intradiscal biacuplasty.

### 2.2.2.2 Radicular Pain Algorithm

While disc protrusion, herniation, or prolapse resulting in sciatica are seen in less than 5% of the patients with low back pain (104,105), approximately 30% of the patients presenting to interventional pain management clinics will require either caudal, interlaminar, or transforaminal epidural injections as an initial treatment. Many patients with post-surgery syndrome, spinal stenosis, and radiculitis with-





out disc protrusion may respond to epidural injections (18,19,21,93,106-109). Patients non-responsive to epidural injections will require either mechanical disc decompression (31,36-38), percutaneous adhesiolysis (26,106,108), spinal endoscopic adhesiolysis (30,106,108), implantation of spinal cord stimulation (25), or intrathecal infusion systems (27) depending on the clinical presentation, pathology, and other biopsychosocial factors. Transforaminal epidural injections may be performed for diagnostic purposes; however, these also lead to therapeutic improvement.

Buenaventura et al (21) in a systematic review of therapeutic lumbar transforaminal epidural steroid injections showed the indicated level of evidence as II-1 for short-term relief of 6 months or less and Level II-2 for long-term relief of longer than 6 months in managing chronic low back and lower extremity pain. Conn et al (93) in a systematic review of caudal epidural injections in the management of chronic low back pain showed variable evidence for various conditions causing low back and lower extremity pain. The evidence level shown is Level I for short- and long-term relief in managing chronic low back and lower extremity pain secondary to lumbar disc herniation and radiculitis and discogenic pain without disc herniation or radiculitis. The indicated level of evidence is Level II-1 or II-2 for caudal epidural injections in managing low back pain of post-lumbar laminectomy syndrome and spinal stenosis.

In contrast to lumbar transforaminal epidural and caudal epidural injections, the evidence for lumbar interlaminar epidural injections in managing chronic low back and lower extremity pain is limited due to the lack of availability of studies utilizing fluoroscopy. The evidence is delivered from blind interlaminar epidural injections. Based on Parr et al's (18) systematic review, the indicated evidence is Level II-2 for short-term relief of pain of disc herniation or radiculitis utilizing blind interlaminar epidural steroid injections with a lack of evidence with Level III for long-term relief of disc herniation and radiculitis. Furthermore, the evidence at present is lacking for short- and long-term relief of spinal stenosis and discogenic pain without radiculitis or disc herniation utilizing blind epidural injections.

If a patient presents with unilateral, single, or 2 level involvement, one may proceed with transforaminal epidural injections (diagnostic and therapeutic). Bilateral or extensive involvement of multiple segments will lead to either interlaminar or caudal based on the upper or lower levels being involved, extensive

stenosis (central or foraminal) and lack of response to caudal or interlaminar approaches. Except in specific documented circumstances with spinal stenosis, the approach also is based on the same philosophy as described above for transforaminal epidurals. For post-surgery syndrome, a caudal epidural is preferred and one may consider a transforaminal epidural if essential in patients without obstructing hardware.

### **2.2.3 Algorithm for Chronic Non-Responsive Pain**

Patients non-responsive to epidural injections, may be considered for mechanical disc decompression, percutaneous adhesiolysis, spinal endoscopic adhesiolysis, spinal cord stimulation, or implantation of intrathecal infusion systems.

Percutaneous mechanical disc decompression lacks evidence even though there are 4 modalities, namely automated percutaneous lumbar discectomy, percutaneous laser discectomy, a high RPM device utilizing Dekompressor, and coblation nucleoplasty or plasma decompression. Recent systematic reviews (31,36-38) showed the evidence to be Level II-2 for short- and long-term (> 1 year) improvement for percutaneous automated lumbar discectomy and laser discectomy. The evidence for coblation nucleoplasty (Level II-3) and Dekompressor (Level III) is only emerging.

In patients with post-lumbar surgery syndrome after failure to respond to fluoroscopically directed epidural injections, percutaneous adhesiolysis is considered (26). Despite a paucity of efficacy and pragmatic trials, the systematic review by Epter et al (26) indicated the evidence as Level I or II-1 with short-term relief being considered as 6 months or less and long-term longer than 6 months (110-116), in managing post-lumbar laminectomy syndrome. Another type of adhesiolysis is spinal endoscopic adhesiolysis, which is considered to be an experimental procedure. It also showed the indicated level of evidence of II-1 for short-term and Level III for long-term relief ( $\leq$  6 months or > 6 months) (30).

The next step in the radicular pain algorithm is implantable therapy. Frey et al (25) in a systematic review of spinal cord stimulation for patients with failed back surgery syndrome (FBSS) indicated the level of evidence as II-1 or II-2 for long-term relief (> 1 year) in managing patients with FBSS. In this systematic review (25), 2 randomized trials (117,118) and 8 observational studies were included (119-126). Despite early increased expense, cost-effectiveness has been demonstrated for spinal cord stimulation (127-131).



Finally, long-term management of chronic non-cancer pain may be achieved with intrathecal infusion systems (27). Intrathecal infusion systems are also utilized for non-cancer pain in FBSS as an advanced stage intervention. While there is a lack of conclusive evidence, Patel et al (27), due to the paucity of quality literature, concluded that the level of evidence for intrathecal infusion systems was indicated as Level II-3 or Level III with longer than one-year improvement considered as long-term response. There were no randomized trials meeting inclusion criteria for this systematic review (27).

## 2.3 Neck Pain

### 2.3.1 Diagnosis

Figure 4 illustrates an algorithmic approach to the diagnosis of chronic neck pain without disc herniation. This represents an algorithmic approach for the investigation of neck pain based on the best available evidence on the epidemiology of various identifiable sources of chronic neck pain. Cervical intervertebral discs, cervical facet joints, atlanto-axial and atlanto-occipital joints, ligaments, fascia, muscles, and nerve root dura have been shown to be capable of transmitting pain from the cervical spine with resulting symptoms of neck pain, upper extremity pain, and headache. Yin and Bogduk (132) demonstrated the prevalence of discogenic pain in 16%, facet joint pain in 55%, and lateral atlanto-axial joint pain in 9%, in 143 patients with chronic neck pain in a private practice pain clinic in the United States. In a systematic review of diagnostic utility and therapeutic effectiveness of cervical facet joint interventions, Falco et al (24), based on controlled diagnostic blocks, determined the prevalence of facet joint pain to be 36% to 67% with an average prevalence of 49% based on 8 studies (67-69,132-136) and with a false-positive rate of 27% to 63% (average 49%) with single diagnostic blocks. However, in one large study (67) with 80% pain relief as the criterion standard, the prevalence rate was 39% and false-positive rate was 45%. In a systematic review of cervical discography as a diagnostic test for chronic spinal pain (29), the prevalence of cervical discogenic pain utilizing the International Association for the Study of Pain (IASP) criteria ranged between 16% to 20% based on 3 studies (132,137,138). The evidence evaluating other structures such as atlanto-axial and occipital joints, is lacking.

If there is evidence of radiculitis, spinal stenosis, post-surgery syndrome, or other demonstrable causes

resulting in radiculitis, an interventionist may proceed with therapeutic epidural injections. For diagnostic purposes one may proceed with diagnostic cervical selective nerve root blocks or transforaminal epidural injections. However, diagnostic accuracy of cervical selective nerve root blocks has not been established (64,139), and cervical transforaminal epidural injections have been associated with substantial risk (140-153). In contrast, therapeutic cervical interlaminar epidural injections have been shown to have an indicated level of evidence of II-2 in managing chronic neck and upper extremity pain (19). Otherwise an algorithmic approach should include the diagnostic interventions with facet joint blocks, epidural injections, followed by discography. Discography suffers with significant controversy with Level II-2 evidence (29). In contrast, facet joint nerve blocks in the diagnosis of cervical facet joint pain provide evidence of Level I or Level II-1 (24).

An algorithm of investigation of chronic neck pain without disc herniation or radiculitis commences with clinical questions and physical and imaging findings. The controlled studies have illustrated the presence of facet joint pain on average in 40% to 50% of cases, ranging from 36% to 67% of the patients and 39% in a large study. Thus, the facet joints are entertained first in the algorithm in patients without radicular symptoms because of their commonality as a causative factor for chronic neck pain and headache and ease of performance. Consequently, the investigation of facet joint pain is considered as a prime investigation ahead of disc stimulation. Multiple studies have indicated facet joint pain to be bilateral in 69% to 72% of cases and involving at least 3 joints in 50% to 85% of patients (67-69).

The diagnostic blocks must be performed under controlled conditions. In the United States, commonly performed diagnostic blocks are often achieved using 2 separate local anesthetics — controlled comparative local anesthetic blocks. Due to ease of performance and safety when performed appropriately with cervical medial branch nerve blocks, multiple joints may be blocked in one setting. However, ISIS guidelines recommend a multi-level methodology with a screening test and multiple confirmatory blocks (51). In the present algorithm, based on the clinical examination, only 2 blocks are performed provided the first block was positive, thus, avoiding a screening block and repeat blocks for separate joints.

If the facet joints are shown to be causative of chronic neck pain with 80% relief and the ability to

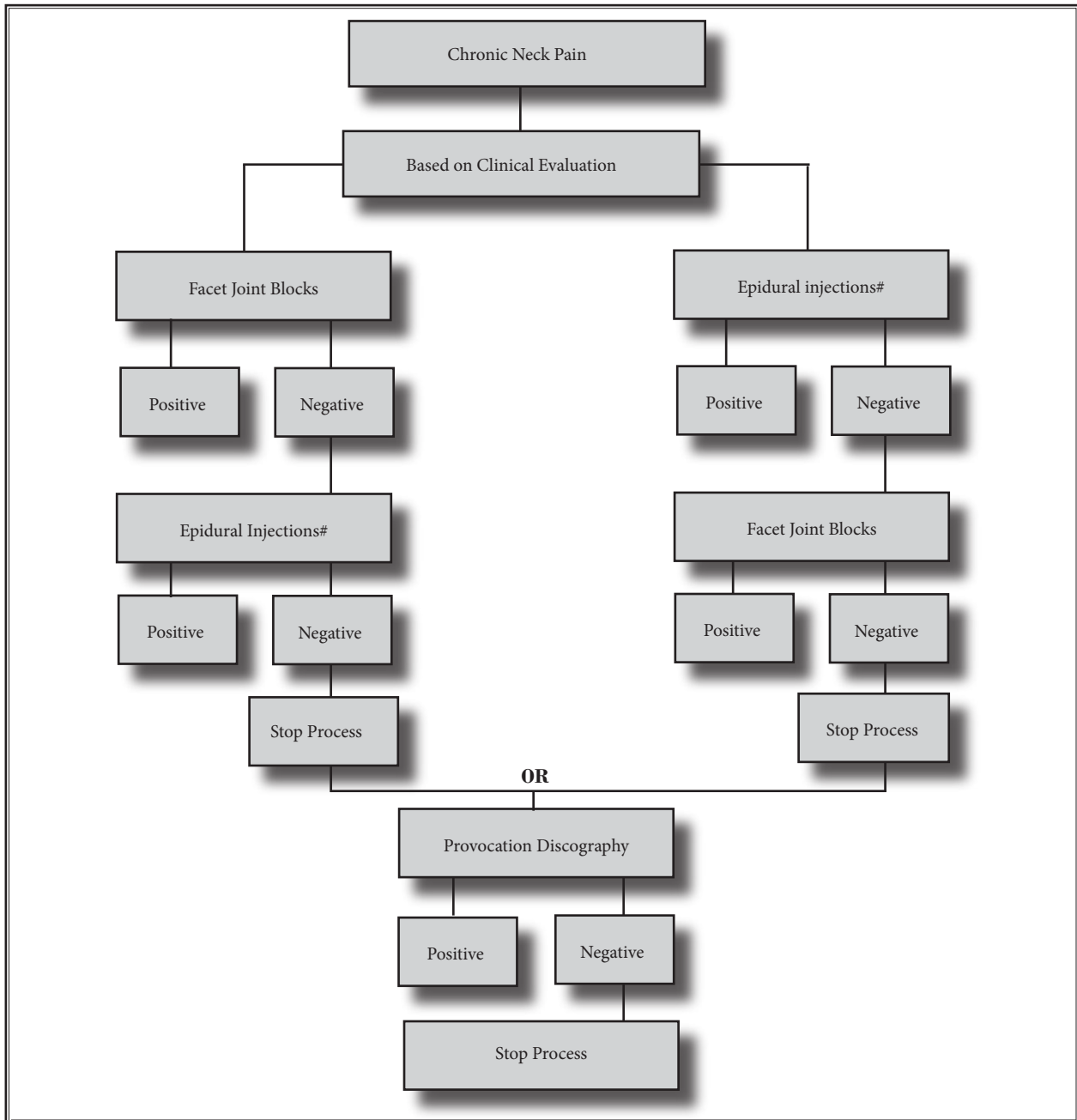


Fig. 4. An algorithmic approach to diagnosis of chronic neck pain without disc herniation.

# Transforaminal epidural injections have been associated with reports of serious risks and adverse events

\* Not based on evidence

perform previously painful movements with concordant response with 2 different local anesthetics, a positive diagnosis is made.

Cervical interlaminar injections are indicated if the facet joints are not suspected as a source for neck

pain. However, if the patient fails to respond to epidural injections, further diagnostic interventions evaluating the disc may be undertaken provided a treatment can be offered.

Cervical provocation discography is seldom per-

formed as an initial test in the present algorithmic approach. Once the facet joint pain is ruled out and the patient fails to respond to at least 2 fluoroscopically directed epidural injections, discography may be pursued, if determination of the disc as the source of pain is crucial. Multiple questions have been raised regarding the utility of cervical discography, including the reported high false-positive rate in select subpopulations; the lack of standardization; the discrepancies regarding the need for "control levels," pain concordance, and pain intensity threshold; and utilization. However, provocation discography continues to be the only diagnostic tool capable of establishing whether or not a particular disc is painful, irrespective of the presence or absence of degenerative pathology observed on other imaging modalities. Compared to lumbar discography, which also continues to be controversial and has been refined substantially, cervical discography is behind in establishing diagnostic accuracy and its utility in managing chronic pain syndromes, part of the reason being lack of proven therapeutic management techniques, specifically non-surgical. However, to be valid, the provocation discography must be performed utilizing criteria with concordant pain in one disc with at least 2 negative discs, with evoked intensity of pain of 7 of 10 or 70% of worst spontaneous pain (e.g., worst pain of 7 =>  $7 \times 70\% = 5$ , being the pain score that would be significant upon disc provocation) (29,54).

### 2.3.1.1 Diagnostic Efficiency

Under the present algorithmic approach, which is simple, efficient, and cost-effective, once facet joint pain is excluded, the patient may be treated with epidural injections. Essentially, cervical provocation discography is the last step in the diagnostic algorithm and is utilized only when appropriate treatment can be offered if the disc abnormality is demonstrated. However, a rare but justifiable indication is to satisfy the patients' impressions if the patient does not improve with any other modalities of treatment. Thus far, studies have demonstrated the effectiveness of epidural injections in the cervical region as well as specifically in discogenic pain in the lumbar region (19,93-98,154-161).

In the United States, based on available literature, cervical facet joints account for 40% to 50% of cases of chronic neck pain without disc herniation, while discogenic pain accounts for approximately 20% of the cases.

Under this algorithm, approximately 70% of patients would undergo investigations of their facet joints, with approximately 40% proving positive and requiring no other investigations. Of the 60% remaining, approximately 5% require provocation discography, and perhaps 20% to 30% will prove positive. The remaining 50% to 60% of the 70% pursuing investigations and original 30% with an overall population of 50% to 60% will probably undergo epidural injections and approximately 65% will respond to epidural injections.

## 2.3.2 Management Algorithm

### 2.3.2.1 Somatic Pain Algorithm

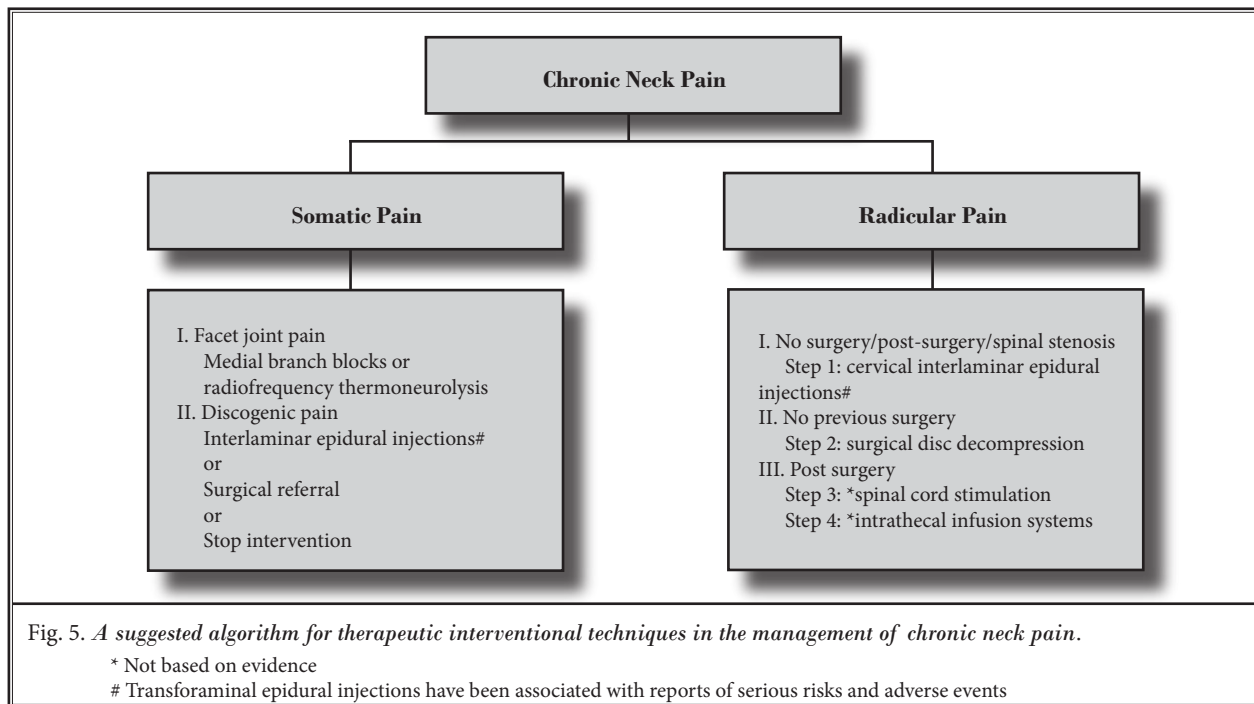
As illustrated in Fig. 5 the therapeutic algorithmic management of chronic neck pain, patients testing positive for facet joint pain may undergo either therapeutic facet joint nerve blocks or radiofrequency neurotomy based on the patients' preferences, values, and physician expertise. However, there is no evidence for cervical intraarticular facet joint injections (24). In contrast to the lack of evidence for intraarticular injections, Falco et al (24) have shown evidence for cervical medial branch blocks of II-1 or II-2 for cervical medial branch radiofrequency neurotomy based on studies utilizing appropriate diagnostic criteria (162-168).

### 2.3.2.2 Radicular Pain Algorithm

Disc protrusions, herniations, or prolapses resulting in radiculitis are less common in the cervical spine than in the lumbar spine. Radiculitis may also result from cervical spinal stenosis, spondylolisthesis, post-surgery syndrome, and discogenic pain without disc herniation. Approximately 30% of the patients presenting to interventional pain management will require interlaminar epidural injections as their initial treatment. Transforaminal epidurals may be performed for diagnostic purposes, but they lack evidence and are associated with increased risk (64,139-153).

### 2.3.2.3 Chronic Non-Responsive Pain Algorithm

Given the failure to respond to less invasive modalities of treatment, the consideration is then for spinal cord stimulation and intrathecal infusion systems. Evidence for these modalities in managing chronic intractable neck pain has not been evaluated. The evidence in the lumbar spine (25) is Level II-1 or II-2 for long-term relief in managing patients with FBSS. The evidence for intrathecal infusion systems is Level II-3 or Level III with one-year long-term improvement (27).



## 2.4 Thoracic Pain

### 2.4.1 Diagnosis

Figure 6 illustrates the diagnostic algorithmic approach for chronic thoracic pain without disc herniation or radiculitis.

This algorithm for investigation of thoracic pain is based on the best available evidence of the epidemiology of various identifiable sources of chronic mid back and upper back pain. Even though separate investigations and studies are not available, based on the experience with the cervical and lumbar spine, it is expected that thoracic intervertebral discs, facet joints, ligaments, fascia, muscles, and nerve root dura are tissues capable of transmitting pain in the mid back, upper back, and chest wall. Of these, facet joint pain has been proven to be one of the common causes of pain with proven diagnostic techniques (16,67,68,169). However, in contrast to the cervical and lumbar spine, the relative contributions of various structures in patients with chronic mid back and upper back pain who failed to respond to conservative modalities of treatments has not been evaluated except for facet joint pain. Based on the controlled, comparative local anesthetic blocks, thoracic facet joint pain has been shown to be present in approximately 40% of patients with mid-upper back pain when data from 3 studies were

combined (34% to 48%) with a false-positive rate of 42%. In contrast, the prevalence, as well as diagnostic accuracy, of thoracic discogenic pain has not been well demonstrated (17). Further, there are no significant therapeutic modalities available in managing thoracic discogenic pain other than epidural injections.

Consequently, if a patient has any signs of radiculitis or disc herniation or other demonstrable causes resulting in radiculitis, one may proceed with therapeutic epidural injections. Otherwise, an algorithmic approach should include diagnostic interventions with facet joint blocks, epidural injections, and in rare circumstances, provocation thoracic discography and transforaminal epidural injections. Thoracic discography suffers from substantial controversy with low levels of evidence compared to cervical and lumbar discography. Thoracic transforaminal epidural injections are associated with high risk (170).

An algorithm for investigating chronic mid back or upper back pain without disc herniation commences with clinical questions, clinical findings, and findings of imaging. In this approach, investigation of facet joint pain is considered to be the prime investigation, ahead of disc stimulation. Facet joint pain is bilateral in 64% to 84% of cases and involving 3 joints or more in 81% to 94% of patients (67,68,169).

The diagnostic blocks must be performed under

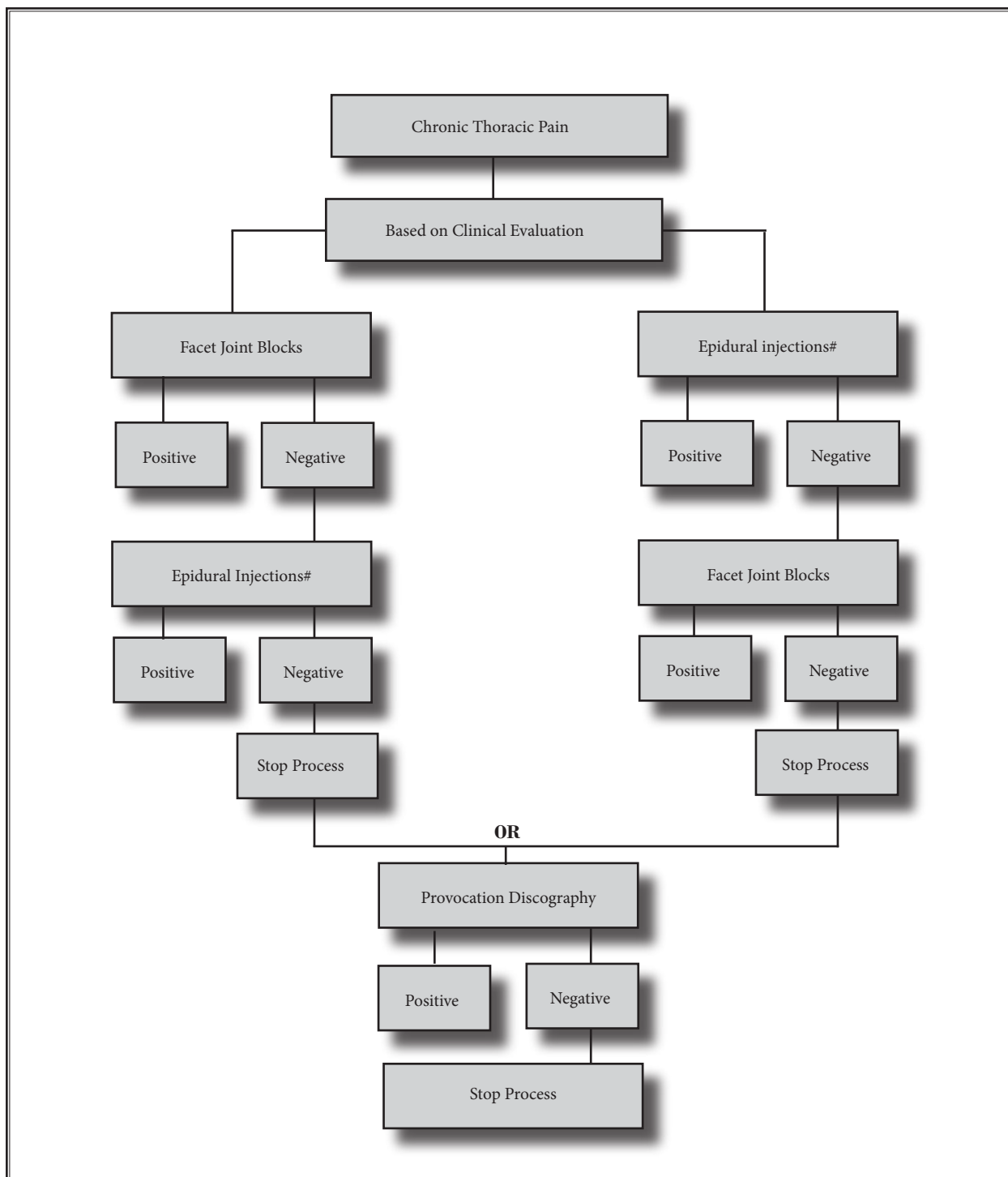


Fig. 6. An algorithmic approach to diagnosis of chronic thoracic pain without disc herniation or radiculitis.

# Transforaminal epidural injections have been associated with reports of serious risks and adverse events

controlled conditions. While placebo diagnostic blocks are recommended, in the United States commonly performed diagnostic blocks are often achieved with 2 separate local anesthetics — controlled, comparative local anesthetic blocks. Due to the innocuous nature of thoracic medial branch blocks, it is recommended that all blocks be performed in one setting. If a patient experiences at least 80% relief with the ability to perform previously painful movements with a concordant response in relation to duration of local anesthetics, a positive diagnosis is made.

Thoracic provocation discography is seldom performed, not only as an initial test, but in the settings of interventional pain management. Once facet joint pain is ruled out and the patient fails to respond to at least 2 fluoroscopically directed epidural injections, investigations may cease or, under rare circumstances, discography may be pursued.

#### 2.4.1.1 Diagnostic Efficiency

Under the present algorithmic approach, once facet joint pain is excluded, the patient may be treated with epidural injections. Thoracic provocation dis-

cography is an extremely rare and last step in the diagnostic algorithm and is utilized only when appropriate treatment can be performed if the disc abnormality is noted. The very rare exception may be to perform discography to satisfy the patient's impressions if the patient does not improve with any other modalities of treatments. However, at present, there is no evidence supporting epidural injections either, except for extrapolating from cervical interlaminar and caudal epidural injections performed under fluoroscopy. One might expect thoracic epidural injections to be equally effective.

Given the frequency of involvement of the thoracic spine and the practice of medicine in the United States as well as the lack of significant pertinent literature, it appears that thoracic facet joints account for 40% of the cases of chronic mid back and upper back pain, whereas the remaining is considered to be discogenic pain or without specific diagnosis. Thus, under this algorithm, approximately 80% of patients would undergo investigations of their facet joints, with approximately 40% proving positive and requiring no other investigations.

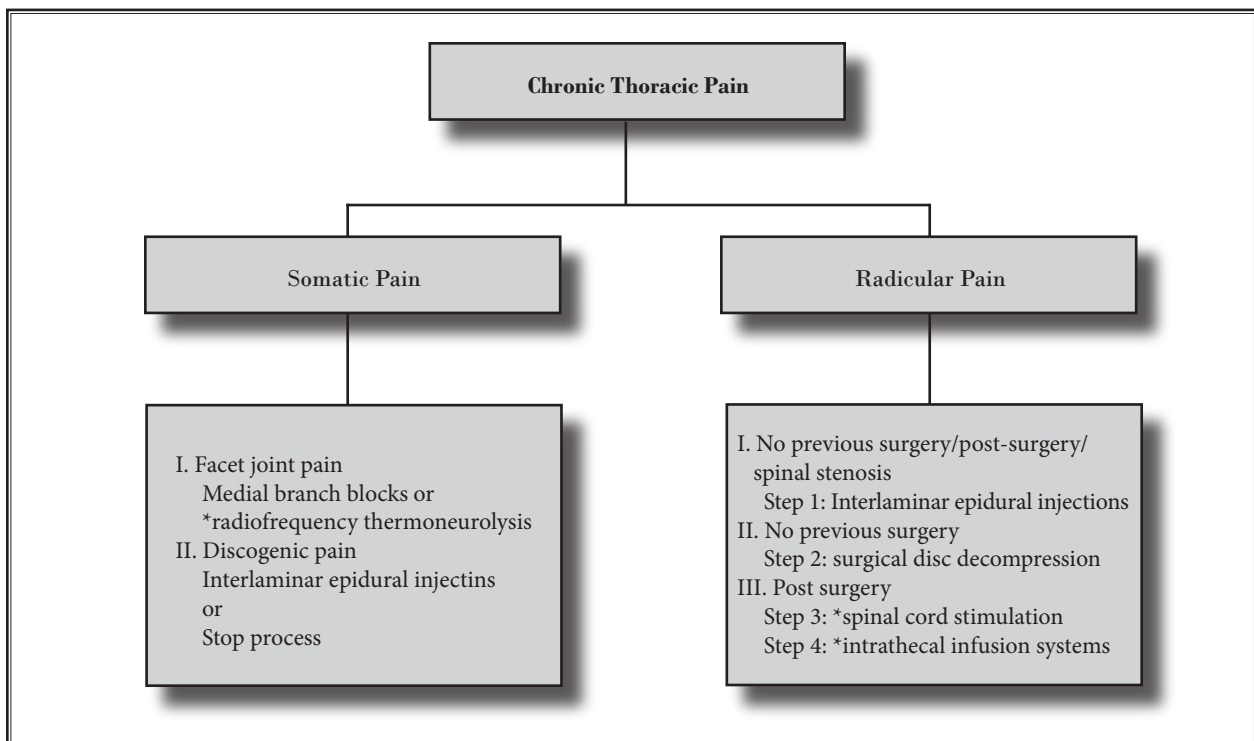


Fig. 7. A suggested algorithm for therapeutic interventional techniques in the management of chronic thoracic pain.

\* Not based on evidence



### 2.4.2 Management Algorithm

Figure 7 illustrates therapeutic algorithmic management. The patients testing positive for facet joint pain may undergo either therapeutic facet joint nerve blocks or radiofrequency neurotomy based on the patient's preferences, values, and physician's expertise. However, there is no evidence for either thoracic intraarticular facet joint injections or radiofrequency neurotomy (16). The only available evidence is for therapeutic thoracic medial branch blocks with a Level II-1 or II-2 for short-term and long-term relief (16).

#### 2.4.2.1 Somatic Pain Algorithm

As illustrated in Fig. 7 displaying the therapeutic algorithmic management of chronic thoracic pain, patients testing positive for facet joint pain may undergo therapeutic facet joint nerve blocks, however radiofrequency neurotomy may be offered based on the patient's preferences, values, and physician expertise. At present there is no evidence for either thoracic intraarticular facet joint injections or radiofrequency neurotomy. In contrast, based on the review of included therapeutic studies (16,171,172), Level II-1 or II-2 evidence is presented for thoracic facet joint nerve blocks.

The next modality of treatment is epidural injections. Epidural injections have been shown to have variable evidence in cervical and lumbar regions with no analyzable evidence in the thoracic spine (18,19,21,93).

#### 2.4.2.2 Radicular Pain Algorithm

Disc protrusions and herniations are much less common in the thoracic spine than the lumbar or cervical spine. Nonetheless, very few patients who present with thoracic radiculitis, post-surgery syndrome, spinal stenosis, and radiculitis without disc protrusion, and patients failing to show evidence of facet joint pain are candidates for epidural injections. Epidural injections are most commonly provided through an interlaminar route rather than transforaminal which is associated with high risk; the use of blunt needles may mitigate this risk. Thoracic interlaminar epidural injections have not been evaluated or proven as to their effectiveness.

#### 2.4.2.3 Algorithm for Chronic Non-Responsive Pain

Patients non-responsive to facet joint interventions and epidural interventions, in rare circumstances, may be considered for disc decompression or intrathecal implantables either with spinal cord stimulation or intrathecal infusion systems. However, there is no evidence available for any of the management modalities. Consequently, management is based on the physician's experience and the patient's values and beliefs.

## 3.0 DELIVERY OF INTERVENTIONAL TECHNOLOGY

---

There is no consensus among interventional pain management specialists with regards to type, dosage, frequency, total number of injections, or other interventions. Fortunately, the recent literature provides some guidance even though not conclusive. Based on the principles of EBM, the average relief per procedure is considered as the recommended duration if it is safely performed without complications.

The recent literature shows no significant difference in the outcomes with or without steroids with medial branch blocks (16,23,24,99,171,172) and epidural injections (18,19,21,93,94,96-98). Further many of the techniques including radiofrequency neurolysis and disc decompressions do not require any steroids.

The most commonly used formulations of long-acting steroids include methylprednisolone (Depo-Medrol), triamcinolone acetonide (Aristocort or Kenalog), and betamethasone acetate and phosphate mixture (Celestone Soluspan) (173-198).

Soon after the historic introduction of cortisone in 1949, steroids were used for various other purposes including placement in the epidural space, spinal joints, peripheral joints, and for infiltration of other nerves (193,199-201). The first published report of the injection of steroids into an arthritic joint was in 1951 (199), followed by the application of transforaminal epidural steroid injections in 1952 and 1953. Since then, the use of spinal steroids has been reported with various approaches (193,202-206). Simultaneous with the introduction of neuraxial steroids in interventional pain management, various complications related to steroid therapy, including systematic effects of particulate steroids, have been described with increasing frequency, cautioning against use of spinal steroids in interventional pain management (1,107,109,193-204). The rationale for the use of epidural steroids into various joints and epidural space has been based on the strong anti-inflammatory effects of corticosteroids (204). However, while inflammation is an issue with discogenic pain and radiculitis, no inflammation has been proven to be present in other cases. It is postulated that corticosteroids reduce inflammation either by inhibiting the synthesis of or release of a number of pro-inflammatory substances or by causing irreversible local anesthetic effect on C-fibers (207-222). The role of epidural steroids has been evaluated in experimental models with betamethasone reducing the nerve root injury produced by epidural application of autologous nucleus pulposus in a pig experimental model (212,215), with suppression

of disc resorption by high dose steroids (219), the depression of heat hyperalgesia and mechano-allodynia (221), prevention of neuropathic edema and blockade of neurogenic extravasation (220), inhibition of phospholipase A2 activity (216), protection of damage to C-fibers (217), prevention of endoneural vascular permeability induced by nucleus pulposus (218), and decrease of the extent of intramedullary spinal cord injury secondary to spinal cord hemorrhage (222).

The chemistry of neuraxial steroids has taken center stage in recent years due to devastating complications following epidural injections, specifically transforaminals (194-197,223-234,236,283). Steroid particle embolization of small radicular arteries is believed to be an important causative factor (197,229,283). Tiso et al (194) and Benzon et al (195) extensively evaluated chemical properties and their relationship to interventional pain management. Data from Tiso et al and Benzon et al regarding particle sizes were in general agreement with regards to methylprednisolone, triamcinolone, and commercial betamethasone. However, there were some differences pertaining to dexamethasone and betamethasone sodium phosphate. Nonetheless, based on the available literature and scientific applications, all the formulations of steroids may be considered clinically safe; however important

physiochemical characteristics distinguish one compound from the others (Tables 1 and 2). Though all formulations of steroids may be considered safe, formulations of betamethasone appear to be safer with no significant difference in the effectiveness (193). Formulations of commonly used epidural steroids are shown in Table 1 and the pharmacologic profile of commonly used epidural steroids is shown in Table 2.

Steroids lead to suppression of the hypothalamic-pituitary axis with decreased plasma cortisol, decreased plasma adrenocorticotropic hormone (ACTH), and adrenal atrophy (193,235-237). Other side effects may be specific to the site of injection which includes arachnoiditis, intrathecal injection, and particulate embolism. Numerous arguments of steroid toxicity to the nervous system stem from the potential toxicity of multiple chemical entities used mostly as preservatives in the formulations of epidural steroids. Nelson (198) spearheaded the crusade against intraspinal therapy using steroids and argued that methylprednisolone acetate was neurotoxic. Betamethasone does not contain either polyethylene glycol or benzyl alcohol. Similarly, single dose vials of methylprednisolone (DepoMedrol) are available without alcohol. Latham et al (185) reported that when injected deliberately into the subarachnoid space in sheep, betametha-

Table 1. Formulations of commonly used epidural steroids.

	Depo-Medrol		Kenalog	Celestone	Decadron	Non-particulate Celestone
	Methylprednisolone		Triamcinolone acetate	Betamethasone preservative free	Dexamethasone sodium phosphate	Betamethasone sodium phosphate
Amount of steroid	40 mg/mL	80 mg/mL	40 mg/mL	6 mg/mL	4 mg/mL	6 mg/mL
Polyethylene glycol 3350	29.1	28.2	—	—	—	—
Polysorbate 80	1.94	1.88	0.4	—	—	—
Monobasic sodium phosphate	6.8	6.59	—	3.4	—	3.0
Benzyl alcohol	9.16	8.8	9	—	—	—
Dibasic sodium phosphate	—	—	—	7.1	—	6.0
Edetate disodium	—	—	—	0.1	—	—
Benzalkonium chloride	—	—	—	0.2	—	—
Sodium sulfite	—	—	—	—	1 mg	—

Table 2. Profile of commonly used epidural steroids.

Drug	Equivalent Dose	Epidural Dose	Anti-Inflammatory Potency	Sodium Retention Capacity	Duration of Adrenal Suppression		
					IM	Single Epidural	Three Epidurals
Hydrocortisone	20 mg	N/A	1	1	N/A	N/A	N/A
Depo-Methylprednisolone (Depo-Medrol)	4 mg	40–80 mg	5	0.5	1–6 weeks	1–3 weeks	N/A
Triamcinolone acetonide (Kenalog)	4 mg	40–80 mg	5	0	2–6 weeks	N/A	2–3 months
Betamethasone (Celestone Soluspan)	0.6 mg	6–12 mg	33	0	1–2 weeks	N/A	N/A
Dexamethasone (Decadron)	0.75 mg	8–16 mg	27	1	N/A	N/A	N/A

N/A = Not available

Data adapted and modified from McEvoy et al (175), Jacobs et al (223) Kay et al (224), Hsu et al (225), Manchikanti et al (171,172), Schimmer and Parker (174), and Benzon et al (195).

some caused no reaction in the meninges or neural structures when small doses of 1 mL were used, even on repeated occasions. Other central nervous system (CNS) events described are worrisome. These are based on the particle size of epidural steroids and the risk of vascular obstruction and ischemic CNS injury as a result of embolization. There have been several reported cases of CNS injuries after transforaminal epidural injections (143,170,194,195,226-233). One of the postulated mechanisms of these events is occlusion of the segmental artery accompanying the nerve root by the particulate steroid or embolization of the particulate steroid through the vertebral artery (194,195,231,234-237).

Consistent with the present literature of the pharmacology of steroids, it appears that non-particulate steroids may be the agents of choice for transforaminal epidural injections, though no trials have compared particulate to non-particulate steroids. However, particulate steroids may be safely utilized for interlaminar or caudal epidural injections. Caution must be exercised in the use of particulate steroids in transforaminal epidural injections and specifically for cervical transforaminal epidural injections, particularly if sharp needles are used.

The frequency and total number of injections have been considered important issues, even though controversial and poorly addressed. These are based on flawed assumptions from non-existing evidence. Over the years, some authors have recommended one injection for diagnostic as well as therapeutic purposes. Some have preached 3 injections in a series, irrespective of a patient's progress or lack thereof, whereas others suggest 3 injections followed by a repeat course of 3 injections after 3-, 6-, or 12-month intervals. There are also proponents of an unlimited number of injections with no established goals or parameters. A limitation of 3 mg per kilogram of body weight of steroid or 210 mg per year in an average person and a lifetime dose of 420 mg of steroid also has been advocated, however, with no scientific basis. The comprehensive review of the literature in preparation of these guidelines and review of all the systematic reviews has not shown any basis for the above reported assumptions and limitations. The administration must be based solely on the patients' responses, safety profile of the drug, experience of the patient, and pharmacological and chemical properties such as duration of action and suppression of adrenals.

## 4.0 MEDICAL NECESSITY MANAGEMENT

The following criteria should be considered carefully in performing interventional techniques:

1. Complete initial evaluation, including history and physical examination.
2. Psychosocial and functional assessment, as necessary and feasible.
3. Determination of indications and medical necessity:
  - ◆ Suspected organic problem.
  - ◆ Nonresponsiveness to less invasive modalities of treatments except in acute situations such as acute disc herniation, herpes zoster, complex regional pain syndrome (CRPS), and intractable cancer-related pain.
  - ◆ Pain and disability of moderate-to-severe degree.
  - ◆ No evidence of contraindications such as severe spinal stenosis resulting in intraspinal obstruction, infection, impaired coagulation, or predominantly psychogenic pain.
  - ◆ Responsiveness to prior interventions with improvement in physical and functional status to justify repeat blocks or other interventions.
  - ◆ Repeating interventions only upon return of pain and deterioration in functional status; decreased pain and increased function after the initial intervention must be documented.

## 5.0 INDICATIONS

Indications are variable for various types of interventional techniques.

### 5.1 Facet Joint Interventions

These guidelines apply for cervical, thoracic, and lumbar facet joint interventions.

- ◆ Common indications for diagnostic facet joint interventions are as follows:
  - Somatic or nonradicular low back, neck, mid-back, or upper back and/or lower extremity, upper extremity, chest wall pain or cervicogenic headache.
  - Duration of pain of at least 3 months.
  - Average pain levels of  $\geq 6$  on a scale of 0 to 10.
  - Intermittent or continuous pain causing functional disability.
  - Failure to respond to more conservative management, including physical therapy modalities with exercises, chiropractic man-

agement, and nonsteroidal anti-inflammatory agents.

- Lack of evidence, either for discogenic or sacroiliac joint pain.
- Lack of disc herniation or evidence of radiculitis.
- No contraindications with understanding of consent, nature of the procedure, needle placement, or sedation.
- No history of allergy to contrast administration, local anesthetics, steroids, Sarapin, or other drugs potentially utilized.
- Contraindications or inability to undergo physical therapy, chiropractic management, or inability to tolerate nonsteroidal anti-inflammatory drugs.
- ◆ Positive response to controlled local anesthetic blocks ( $< 1\text{mL}$ ) with a criterion standard of 80% pain relief and the ability to perform prior painful movements without any significant pain.

### 5.1.1 Frequency of Interventions

- ◆ In the diagnostic phase, a patient may receive 2 procedures at intervals of no sooner than one week or preferably 2 weeks, with careful judgment of response.
- ◆ In the therapeutic phase (after the diagnostic phase is completed), the suggested frequency would be 2–3 months or longer between injections, provided that  $\geq 50\%$  relief is obtained for 6–8 weeks.
- ◆ If the interventional procedures are applied for different regions, they may be performed at intervals of no sooner than one week or preferably 2 weeks for most types of procedures.
  - It is suggested that therapeutic frequency remain at least a minimum of 2 months for each region; it is further suggested that all the regions be treated at the same time provided that all procedures can be performed safely.
- ◆ In the treatment or therapeutic phase, facet joint interventions should be repeated only as necessary according to the medical necessity criteria, and it is suggested that these be limited to a maximum of 4 to 6 times for local anesthetic and steroid blocks over a period of one year, per region.
- ◆ Under unusual circumstances with a recurrent injury or cervicogenic headache, procedures may be repeated at intervals of 6 weeks after stabilization in the treatment phase.

- ◆ For medial branch neurotomy, the suggested frequency would be 3 months or longer (maximum of 3 times per year) between each procedure, provided that 50% or greater relief is obtained for 10 to 12 weeks.
  - The therapeutic frequency for medial branch neurotomy should remain at intervals of at least 3 months per each region with multiple regions involved. It is further suggested that all regions be treated at the same time, provided all procedures are performed safely.
- ◆ Cervical and thoracic are regions considered as one region and lumbar and sacral are considered as one region for billing purposes.

## 5.2 Epidural Injections

Epidural injections include caudal, interlaminar, and transforaminal in cervical, thoracic, lumbar, and sacral regions.

These guidelines apply to all epidural injections including caudal, interlaminar, and transforaminal.

### 5.2.1 Caudal

- ◆ Common Indications are as follows:
  - Chronic low back and/or lower extremity pain which has failed to respond or poorly responded to noninterventional and non-surgical conservative management resulting from:
    - Disc herniation/lumbar radiculitis
    - Lumbar spinal stenosis
    - Post lumbar surgery syndrome
    - Epidural fibrosis
    - Degenerative disc disease/discogenic low back pain
    - Other causes
  - Absence of facet joint pain determined by controlled local anesthetic blocks.
  - Intermittent or continuous pain causing functional disability.
  - Average pain level of  $\geq 6$  on a scale of 0 to 10.

### 5.2.2 Lumbar Interlaminar

- ◆ Indications are same as for caudal epidural injections, except for post-surgery syndrome.
  - Caudal epidural is the modality of choice for post-surgery syndrome.

### 5.2.3 Cervical Interlaminar

- ◆ Common indications are as follows:
  - Chronic neck and/or upper extremity pain which has failed to respond or poorly responded to non-interventional and non-surgical conservative management resulting from:
    - Herniated, protruded, or extruded disc with or without radiculitis
    - Cervical spinal stenosis
    - Post cervical surgery syndrome
    - Degenerative disc disease
    - Other causes
  - Absence of facet joint pain determined by controlled local anesthetic blocks.
  - Intermittent or continuous pain causing functional disability.
  - Average pain level of  $\geq 6$  on a scale of 0 to 10.

### 5.2.4 Thoracic Interlaminar

- ◆ Common indications are as follows:
  - Chronic mid back or upper back pain which has failed to respond or poorly responded to non-interventional and non-surgical conservative management resulting from:
    - Herniated, protruded, or extruded disc with or without radiculitis
    - Thoracic spinal stenosis
    - Thoracic post-surgery syndrome
    - Degenerative disc disease
    - Other causes

### 5.2.5 Lumbar Transforaminal

Lumbar transforaminal epidurals are provided for diagnostic and therapeutic purposes.

- ◆ Diagnostic indications:
  - To identify an inflamed nerve root in a patient with a history of radicular pain when results of visual anatomic studies and neurophysiologic studies are not collaborative
  - To identify the pain generator when patients have multiple abnormalities on visual anatomic studies
  - To determine the symptomatic level in multi-level disc herniation
  - To determine a primary pain generator in the spine-hip syndrome
  - To determine a previously undocumented nerve root irritation as a result of spondylolisthesis

- To determine the symptomatic level in multi-level stenosis
- To determine the symptomatic root in patients with documented postoperative fibrosis
- ◆ Therapeutic indications:
  - Average pain levels of  $\geq 6$  on a scale of 0 to 10
  - Intermittent or continuous pain causing functional disability
  - Chronic low back and/or lower extremity pain which has failed to respond or poorly responded to non-interventional and non-surgical conservative management
  - Chronic low back and/or lower extremity pain resulting from:
    - Disc herniation
    - FBSS without extensive scar tissue and hardware
    - Spinal stenosis with radiculitis
    - Discogenic pain with radiculitis

### 5.2.6 Frequency of Interventions

- ◆ Guidelines of frequency of interventions apply to epidural injections caudal, interlaminar, and transforaminal.
- ◆ In the diagnostic phase, a patient may receive 2 procedures at intervals of no sooner than one week or preferably 2 weeks except in cancer-related pain or when a continuous administration of local anesthetic is employed for CRPS.
- ◆ In the therapeutic phase (after the diagnostic phase is completed), the suggested frequency of interventional techniques should be 2 months or longer between each injection, provided that  $> 50\%$  relief is obtained for 6 to 8 weeks.
- ◆ If the neural blockade is applied for different regions, they may be performed at intervals of no sooner than one week and preferably 2 weeks for most types of procedures. The therapeutic frequency may remain at intervals of at least 2 months for each region. It is further suggested that all regions be treated at the same time, provided all procedures can be performed safely.
- ◆ In the treatment or therapeutic phase, the epidural injections should be repeated only as necessary according to medical necessity criteria, and it is suggested that these be limited to a maximum of 4–6 times per year.
- ◆ Under unusual circumstances with a recurrent injury, cancer-related pain, or CRPS, blocks may be repeated at intervals of 6 weeks or less after diagnosis/stabilization in the treatment phase.
- ◆ Cervical and thoracic regions are considered as one region and lumbar and sacral are considered as one region.

### 5.3 Percutaneous Adhesiolysis

- ◆ Common indications are as follows:
  - Chronic low back and/or lower extremity pain resulting from:
    - Failed back surgery syndrome/epidural fibrosis
    - Spinal stenosis
    - Disc herniation with radiculitis
    - Duration of pain of at least 6 months.
    - Intermittent or continuous pain causing functional disability.
    - Average pain levels of  $\geq 6$  on a scale of 0 to 10.
    - Failure to respond or poor response to non-interventional and non-surgical conservative management and fluoroscopically-directed epidural injections.
    - Absence of facet joint pain determined by controlled local anesthetic blocks.

#### 5.3.1 Frequency of Interventions

- ◆ The number of procedures is preferably limited to:
  - 2 interventions per year, with a 3-day protocol
  - 4 interventions per year, with a one-day protocol

### 5.4 Spinal Endoscopic Adhesiolysis

- ◆ Common indications are as follows:
  - Chronic low back and lower extremity pain nonresponsive or poorly responsive to conservative treatment, including fluoroscopically directed epidural injections and percutaneous adhesiolysis with hypertonic saline neurolysis.
  - Moderate to severe disability.
  - Absence of facet joint pain determined by controlled local anesthetic blocks.

#### 5.4.1 Frequency of Interventions

- ◆ The procedures are preferably limited to a maximum of 2 per year provided the relief was  $> 50\%$  for  $> 4$  months.



### 5.5 Intradiscal Procedures

- ◆ Common indications are as follows:
  - Axial low back pain of at least 6 months duration.
  - Failure to respond to conservative treatment.
  - Abnormal nucleus signal on T2-weighted MRI images with > 60% residual disc height.
  - Positive concordant discogram at low pressure.
  - Normal neurologic exam (or at least no new deficits attributable to level to be treated).
  - Negative straight-leg raise.
  - MRI with no evidence of root compression, tumor, or infection (if root compression is present, consider PMDD).

### 5.6 Mechanical Disc Decompression

- ◆ Common indications are as follows:
  - Unilateral leg pain greater than back pain.
  - Radicular symptoms in a specific dermatomal distribution that correlates with MRI findings.
  - Positive straight leg raising test or positive bowstring sign, or both.
  - Neurologic findings or radicular symptoms.
  - No improvement after 6 weeks of conservative therapy.
  - Imaging studies (CT, MRI, discography) indicating a subligamentous contained disc herniation.
  - Well maintained disc height of 60%.

### 5.7 Sacroiliac Joint Injections

- ◆ Common indications are as follows:
  - Somatic or nonradicular low back and lower extremity pain below the level of L5 vertebra.
  - Duration of pain of at least 3 months.
  - Average pain levels of  $\geq 6$  on a scale of 0 to 10.
  - Intermittent or continuous pain causing functional disability.
  - Failure to respond to more conservative management, including physical therapy modalities with exercises, chiropractic management, and non-steroidal anti-inflammatory agents.
  - Lack of obvious evidence for disc-related or

facet joint pain.

- No contraindications with understanding of consent, nature of the procedure, needle placement, or sedation.
- No history of allergy to contrast administration, local anesthetics, steroids, Sarapin, or other drugs potentially utilized.
- Contraindications or inability to undergo physical therapy, chiropractic management, or inability to tolerate nonsteroidal anti-inflammatory drugs.
- For therapeutic sacroiliac joint interventions with intraarticular injections or radiofrequency neurotomy, the joint should have been positive utilizing controlled diagnostic blocks.

#### 5.7.1 Frequency of Interventions

- ◆ In the diagnostic phase, a patient may receive 2 SI joint injections at intervals of no sooner than one week or preferably 2 weeks.
- ◆ In the therapeutic phase (after the diagnostic phase is completed), the suggested frequency would be 2 months or longer between injections, provided that > 50% relief is obtained for 6 weeks.
- ◆ If the procedures are done for different joints, they should be performed at intervals of no sooner than one week or preferably 2 weeks. It is suggested that therapeutic frequency remain at 2 months for each joint. It is further suggested that both joints be treated at the same time, provided the injections can be performed safely.
- ◆ In the treatment or therapeutic phase, the interventional procedures should be repeated only as necessary according to the medical necessity criteria, and it is suggested that they be limited to a maximum of 4 – 6 times for local anesthetic and steroid blocks over a period of one year, per region.
- ◆ Under unusual circumstances with a recurrent injury, procedures may be repeated at intervals of 6 weeks after stabilization in the treatment phase.
- ◆ For sacroiliac joint radiofrequency neurotomy the suggested frequency is 3 months or longer between each procedure (maximum of 3 times per year), provided that > 50% relief is obtained for 10 to 12 weeks.

## 6.0 CASE DISCUSSIONS

In this section the most common modalities of management are described. However, there is no single approach that covers every patient. Further, typical patients present with multiple problems.

This algorithmic approach does not dictate standard of care—these are guidelines. Further, with space constraints, comprehensive initial evaluation and all the findings are not provided. Thus, this should not be construed as the entire evaluation. Only relevant descriptions are provided. Further, changes in physical functional and psychological status are not described for each encounter.

These case discussions do not attempt to cover all interventional procedures. They do represent a philosophy of attempting to provide as much diagnostic and therapeutic services as efficiently as possible, so that, for example, lumbar and cervical facet injections are done at the same setting. If facet injections document that the facets are not the source of pain, an epidural may be performed at the same setting. It is important to note that from a billing and coding perspective, only the primary procedure done in each region (cervical/thoracic or lumbar/sacral) may be billed for when multiple procedures are done in the same day. Thus, if one performs diagnostic cervical facet injections followed by a cervical epidural, only the facets may be billed for. Abuse and overuse of multiple procedures is a major concern. These guidelines must not be used to justify multiple procedures, without documentation of medical necessity.

### 6.1 A Case of Chronic Neck and Back Pain

#### 6.1.1 History of Present Illness

1. Intermittent; deep, aching, throbbing and cramping; midline and bilateral paravertebral low back; since 1997; with gradual onset without injury; with intermittent radiation to both hips; since 1997; with gradual onset without injury; with worsening gradually since onset; associated without numbness, tingling, pins and needles, or weakness; with exacerbation with standing, walking, lumbar flexion, lumbar extension, right lateral flexion, and left lateral flexion; with relief with lying down, resting, and medicine; with back pain worse than leg pain; which failed to respond to chiropractic, physical therapy, cortisone by mouth, cortisone injections, and exercises; with some response to medical therapy; with good response to

nerve blocks; until 11/28/2007.

2. Intermittent; deep, aching, throbbing and cramping; midline and bilateral paravertebral neck pain; since 1997; with gradual onset without injury; with intermittent radiation to both sides of head; since 1997; with gradual onset without injury; with worsening gradually since onset; associated without tingling, pins and needles, and weakness; with exacerbation with neck flexion, right lateral flexion, left lateral flexion, lifting, and overhead activity; with relief with medicine; which failed to respond to chiropractic, physical therapy, cortisone by mouth, cortisone injections, and exercises; with some response to medical therapy; with good response to nerve blocks; until 11/28/2007.

#### 6.1.2 Physical Evaluation

**Cervical Spine:** There was no evidence of scars. There was no superficial or nonanatomic tenderness. There was moderate midline and bilateral paravertebral tenderness from C2 to C7. There was moderate suboccipital tenderness bilaterally with elicitation of a headache. There was moderate upper trapezius tenderness bilaterally. Range of motion of the cervical spine was decreased 20% in all directions with mild pain. Range of motion of both shoulders was normal with no evidence of impingement. Motor examination was shown to be with mildly reduced grip strength. The deep tendon reflexes were 2+ for Biceps, Triceps, and Brachioradialis.

**Lumbar Spine:** There was no evidence of scars. There was no superficial or nonanatomic tenderness. There was mild midline tenderness from L1 to L3 and moderate midline tenderness from L4 to S1. There was mild paravertebral tenderness bilaterally from L1 to L3 and moderate paravertebral tenderness bilaterally from L4 to S1. There was moderate tenderness noted in sciatic notch region bilaterally. There was mild bilateral S1 joint tenderness noted. Range of motion of the lumbar spine was reduced 20% in flexion with moderate pain and reduced 20% in extension; right lateral rotation, right lateral flexion, left lateral rotation and left lateral flexion with mild pain. Range of motion of the both hips was normal with negative Patrick-Fabere's Test. Motor strength evaluation showed mild reduction bilaterally with no focal neurological deficits. Sciatic tension signs were 80 degrees and negative on both sides. The deep tendon reflexes were as follows: Quadriceps Femoralis 2 on the right side, and 2 on the left side, Achilles 2 on the right side, and 2 on the left side. Superficial reflexes were shown to be within normal limits.

### **6.1.3 Relevant Imaging Findings**

12/27/2007 – MRI of the cervical spine. Broad based central C5-C6 protruding type cervical disc herniation resulting in minimal cord displacement and compression. No free disc fragment identified.

12/27/2007 – MRI of the lumbar spine. Normal annular bulging at the L3-L4 and L4-L5 interspaces. No disc herniations are identified. No nerve impingements.

### **6.1.4 Medical Decision Making**

This patient presents with spinal pain involving lumbosacral and cervical regions. Radiological findings indicate broad based central C5/6 protruding type disc herniation without cord displacement or compression of the nerve roots or free-fragment, and normal annular bulging at L3-4 and L4-L5 interspaces.

Her first problem is midline and bilateral paravertebral low back pain with radiation into both hips, without neurological symptoms with exacerbation with all types of movements with lack of response to various conservative modalities of treatments. Based on the history, examination, and imaging findings, the diagnosis of facet joint pain may be entertained followed by pain secondary to disc disease; however, there is no indication for sacroiliac joint pain.

Her second problem is intermittent midline and bilateral paravertebral neck pain associated with headaches with no neurological symptoms. Once again, the symptomatology meets the criteria for facet joint pain with possible discogenic pain if facet joint pain cannot be confirmed.

### **6.1.5 Relevant Diagnosis**

- Lumbar disc displacement
- Lumbar facet joint arthropathy
- Cervical disc displacement
- Cervical facet joint arthropathy

### **6.1.6 Planned Procedures**

1. Bilateral cervical facet joint nerve blocks C2/3-C5/6
2. Bilateral lumbar facet joint nerve blocks L3/4-L5/S1
3. Probable cervical epidural with local anesthetic with or without steroids
4. Probable caudal epidural with local anesthetic with or without steroids

### **6.1.7 First Interventional Pain Management Encounter**

The patient was treated with bilateral cervical facet joint nerve blocks from C2/3-C5/6 utilizing a total of 5 mL of lidocaine and bilateral lumbar facet joint nerve blocks from L3/4-L5/S1 utilizing a total of 3 mL of 1% preservative free lidocaine. Positive preliminary diagnosis was established with lidocaine blocks with more than 80% pain relief and the ability to perform painful maneuvers in both regions.

### **6.1.8 Second Interventional Pain Management Encounter**

At one-month, she reported 80% relief for 3 days and 70% for 3 weeks with low back, and 30% relief for 3 weeks with neck and head.

Even though she reported greater than 80% relief with the ability to perform multiple painful maneuvers after the lidocaine blockade, it was short-lived and the patient was not satisfied with the relief with her cervical spine. Thus, it was assumed that she is negative for cervical facet joint pain, and we proceeded with cervical interlaminar epidural with local anesthetic and steroids with 2 mL of ominipaque 2240, followed by injection of 4mL 0.5% lidocaine and 6 mg of non-particulate celestone.

For lumbar spine, confirmatory blocks with bupivacaine are required. Thus, due to positive response bilateral lumbar facet joint nerve blocks from L3/4-L5/S1 with 3 mL of 0.5% preservative free bupivacaine were performed. She reported approximately 90% pain relief with the ability to perform painful movements in the lumbar spine.

### **6.1.9 Third Interventional Pain Management Encounter**

During the third encounter (2 months after the second encounter), she reported 80% relief for 5 days and 70% relief for 2 months with her low back. With the cervical spine, she experienced more than 50% relief for 2 months.

It was confirmed that patient suffered with bilateral lumbar facet joint pain and with disc related pain in the cervical spine. Based on the diagnostic criteria of 80% relief with the ability to perform multiple maneuvers with appropriate duration of relief with bupivacaine longer than lidocaine, based on the systematic reviews and guidelines, it was judged that she had lumbar facet joint pain (23). Thus, it was decided to

continue bilateral lumbar facet joint nerve blocks and cervical epidural with local anesthetic and steroids. Patient was offered an opportunity for radiofrequency neurolysis; however, patient refused to undergo radiofrequency thermoneurolysis and opted for repeat medial branch blocks.

Now the patient has entered a therapeutic phase, thus these treatments may be continued, based on the guidelines, 4 times per year per region, if required. Treatments must be repeated only if pain returns and functional status deteriorates or complications or side effects ensue.

Further, if patient fails to respond, re-evaluation and other modalities of treatment may be considered. In the cervical spine no other modalities of treatment are available, hence, interventional techniques may cease unless recurrent injury or other factors ensue.

In the lumbar spine radiofrequency neurolysis may be considered or epidural injections may be pursued. If epidural injections also fail, lumbar provocation discography may be considered if appropriate treatment is available or treatments may cease.

## 6.2 A Case of Chronic Neck Pain

### 6.2.1 History of Present Illness

Intermittent; deep, aching, throbbing, cramping and burning; midline and bilateral paravertebral neck pain; since 05/19/2000; following work related incident; with intermittent radiation to both sides of head, both shoulder blades and both upper extremities up to elbows; since 05/19/2000; following work related incident; with worsening gradually since onset; associated with numbness, tingling, pins and needles and weakness in both hands; with exacerbation with neck flexion, neck extension, right lateral flexion, left lateral flexion, overhead activity and cold and damp weather; with relief with lying down, resting, and medicine; with neck pain and arm pain equal, which failed to respond to cortisone injections and exercises; with some response to medical therapy; until 09/24/2008.

### 6.2.2 Physical Evaluation

**Cervical Spine:** There was no superficial or non-anatomic tenderness. There was severe midline and bilateral paravertebral tenderness bilaterally from C2 to C7. There was severe suboccipital tenderness bilaterally. There was severe upper trapezius tenderness bilaterally. Range of motion of the cervical spine was decreased 40% in flexion with moderate pain, 60%

in extension with severe pain and decreased 30% in right lateral rotation, right lateral flexion, left lateral rotation, and left lateral flexion with mild pain. Range of motion of both shoulders was normal with no evidence of impingement. Motor strength of the upper extremities was shown to be mildly reduced bilaterally with no focal deficits. The grip strength was moderately reduced bilaterally with no focal deficits. There was mild sensory dysfunction noted bilaterally at C6 and C7 level. The deep tendon reflexes were Biceps 1, Triceps, and Brachioradialis 1 and equal.

### 6.2.3 Relevant Imaging Findings

10/02/2008 – X-ray of cervical spine. 1) Mild degenerative spurring changes in the mid cervical spine at the C4-C5 and C5-C6 interspaces. 2) Some right sided foraminal narrowing is suspected at the C4-C5 interspace. 3) Foramina appear patent. 4) No obvious displaced fracture seen.

10/02/2008 – MRI of cervical spine. 1) Some disc bulging and right lateral protrusion at the C5-C6 level, with possible right lateral disc herniation. Some right lateral foraminal encroachment is felt present. 2) More broad based disc bulging and protrusion identified at the C4-C5 level with some possible bilateral foraminal narrowing.

### 6.2.4 Medical Decision Making

This patient presents with intermittent cervical pain with radiation to both sides of the head, shoulders blades, and upper extremities. However, there was no radicular symptomology present. Further, neck and arm pain were equal.

The imaging illustrates degenerative changes with disc protrusion and foraminal narrowing, however, without radicular symptomatology. Based on the history, examination, and imaging findings, the diagnosis of facet joint pain is entertained, followed by pain secondary to disc disease.

### 6.2.5 Relevant Diagnosis:

Cervical facet joint arthropathy  
Cervical degeneration of intervertebral disc  
Cervical disc displacement

### 6.2.6 Planned Procedures

1. Bilateral cervical facet joint nerve blocks C2/3-C6/7
2. Probable cervical epidural with local anesthetic with or without steroids

### **6.2.7 First Interventional Pain Management Encounter**

The patient was treated with bilateral cervical facet joint nerve blocks from C2/3- C6/7 with a total of 5 mL lidocaine 1% preservative free with immediate impression of positive diagnosis of cervical facet joint pain with 100% pain relief and the ability to perform previously painful movements.

### **6.2.8 Second Interventional Pain Management Encounter**

At this visit, the patient reported 90% relief for one day and 50% relief for 2 weeks.

She was treated with bilateral cervical facet joint nerve blocks from C2/3-C6/7 with 5 mL of 0.25% preservative free bupivacaine, with immediate impression of positive diagnosis of cervical facet joint pain.

### **6.2.9 Third Interventional Pain Management Encounter**

At the third interventional pain management encounter, she reported 90% pain relief for 8 days and 50% pain relief for 8 weeks. Thus, she was treated with bilateral cervical facet joint nerve blocks from C2/3-C6/7 with bupivacaine 0.25% preservative free.

We have considered other bilateral cervical facet joint nerve blocks or radiofrequency neurotomy. The advantages of cervical facet joint nerve blocks included performing bilaterally in the same setting whereas radiofrequency neurotomy is offered only one side at a time due to potential side effects of radiofrequency thermoneurotomy in the cervical spine. The limitations of each treatment were also explained and understood which included the average relief of 6 months with radiofrequency neurotomy and 3 months with facet joint nerve blocks (24). She chose to undergo bilateral facet joint nerve blocks. If she fails to respond we can proceed with cervical epidural and if that also fails we should cease interventional techniques.

### **6.2.10 Fourth Interventional Pain Management Encounter**

Subsequent to the therapeutic facet joint nerve blocks in the cervical spine, at the return visit after 3 months she reported on average 60% relief lasting for 3 months. Following this she was treated with repeat therapeutic cervical facet joint nerve block procedures.

Now the patient has entered a therapeutic phase, thus, therapeutic facet joint nerve blocks may be con-

tinued, however, if patient fails to respond to therapeutic facet joint nerve blocks, a re-evaluation and other modalities of treatment may be considered.

## **6.3 A Case of Chronic Low Back Pain**

### **6.3.1 History of Present Illness**

Intermittent; deep, aching, throbbing, cramping, sharp, shooting; midline and right paravertebral low back pain; since 2002; with gradual onset without injury; with intermittent radiation into right hip and right lower extremity above the knee; since 2002; with gradual onset without injury; with worsening gradually since onset; associated with weakness; with exacerbation with lumbar flexion, lumbar extension, lifting, cold/damp weather; with relief with lying down/resting and medicine; with back pain worse than leg pain; which failed to respond to chiropractic treatment, physical therapy, cortisone by mouth/injections, medical therapy, and exercises; until 07/23/2008.

### **6.3.2 Physical Evaluation**

**Lumbar Spine:** There was evidence of scars on the right hip. His right leg was shorter than left leg. There was no superficial or nonanatomic tenderness. There was moderate midline and right paravertebral tenderness from L4 to S1. There was mild paravertebral tenderness on the left side from L4 to S1. There was moderate tenderness noted in right hip. Range of motion of the lumbar spine was reduced 40% on flexion with moderate pain. Extension with reduced 30% with moderate pain. Right lateral rotation, right lateral flexion, left lateral rotation, and left lateral flexion was reduced 20% with mild pain. Range of motion of the right hip were reduced whereas left hip was normal with negative Patrick-Fabere's Test. Motor strength evaluation showed moderate reduction bilaterally with no focal neurological deficits. The deep tendon reflexes were as follows: Quadriceps Femoralis 1 and bilaterally, Achilles 1 and equal bilaterally. Superficial reflexes were shown to be within normal limits. Straight leg raising in supine at 60° was positive for back pain bilaterally. Straight leg raising in supine at 70° was positive for back pain on the left side.

### **6.3.3 Relevant Imaging Findings**

07/28/2008 – X-ray of lumbar spine. Small osteophytes project anteriorly from the superior margins of L3, L4, and L5. No fracture of subluxation is identified.



07/28/2008 – MRI lumbar spine. Findings of degenerative disc disease and at the L5-S1 disc level there is a small central and left paracentral disc protrusion suggested near the central spinal canal does not appear significantly narrowed. There is a small anterior extradural defect in the midline at L1-2 suggesting a small central disc protrusion without spinal stenosis.

#### **6.3.4 Medical Decision Making**

This patient presented with spinal pain involving the right hip and right lower extremity above the knee, without radicular symptomatology with exacerbation with lumbar flexion, lumbar extension, lifting, cold/damp weather with no response to multiple modalities.

#### **6.3.5 Relevant Diagnosis**

Lumbar facet joint arthropathy  
Lumbar degeneration of intervertebral disc  
Lumbar disc displacement

#### **6.3.6 Planned Procedures**

1. Right lumbar facet joint nerve blocks L2/3-L5/S1
2. Probable lumbar interlaminar epidural with local anesthetic with or without steroids

#### **6.3.7 First Interventional Pain Management Encounter**

The patient was treated with right lumbar facet joint nerve blocks from L2/3-L5/S1, utilizing a total of 2 mL of 1% preservative free lidocaine with positive diagnosis of lumbar facet joint pain.

#### **6.3.8 Second Interventional Pain Management Encounter**

The patient experienced 95% relief for 4 days and 60% relief for 3 weeks and was treated with right lumbar facet joint nerve blocks from L2/3-L5/S1, utilizing a total of 2 mL of 0.25% preservative free bupivacaine, with positive diagnosis of lumbar facet joint pain.

#### **6.3.9 Third Interventional Pain Management Encounter**

The patient experienced 95% relief for 5 days and 60% relief for 5 weeks following the second block, thus facet joint pain was confirmed.

Following this discussions with regards to radiofrequency neurotomy and medial branch blocks, the patient opted to undergo radiofrequency neurotomy. Thus, radiofrequency neurotomy was carried out for facet joint nerves from L2-L4 and L5 dorsal ramus.

#### **6.3.10 Fourth Interventional Pain Management Encounter**

The patient experienced 70% relief for 3 months, hence no further treatment was carried out. Patient was scheduled to return in approximately 3 months, at that time if the pain returned and functional status starts deteriorating further radiofrequency will be carried out, otherwise no further treatment is necessary.

### **6.4 A Case of Chronic Low Back Pain**

#### **6.4.1 History of Present Illness**

Intermittent; deep, aching, throbbing, cramping, sharp, shooting, stabbing; midline and left paravertebral low back pain; since 1978; with gradual onset without injury; with intermittent radiation to left lower extremity below the knee; since 1978; with gradual onset without injury; with worsening gradually since onset; associated with numbness, tingling, pins & needles, and weakness; with exacerbation with lumbar flexion, lumbar extension, right lateral flexion, left lateral flexion, and lifting; with relief with lying down/resting and medicine; with back pain worse than leg pain; which failed to respond to chiropractic treatment, physical therapy, cortisone by mouth, cortisone injection, medical therapy, and exercises; until 5/7/2008.

#### **6.4.2 Physical Evaluation**

**Lumbar Spine:** There was no evidence of scars. There was no superficial or nonanatomic tenderness. There was mild midline, left paravertebral tenderness from L3 to S1, and left sciatic notch tenderness. Range of motion of the lumbar spine was reduced 30% on flexion with moderate pain. Other movements were normal. Range of motion of the both hips was normal with negative Patrick-Fabere's Test. Motor strength was mildly reduced on the left side. Sciatic tension signs were positive on the left side at 70°, and negative on the right side at 90°. The deep tendon reflexes were 1+ Quadriceps Femoralis and Achilles, and equal bilaterally. Superficial reflexes were within normal limits.

#### **6.4.3 Relevant Imaging Findings**

11/20/2007 – X-ray lumbar spine. 1) Overall moderate degenerative change mostly focused about L4-5 and to a lesser extent L5-S1.

02/5/2008 – MRI lumbar spine. 1) Moderately severe degenerative changes in the disk and endplates at the L4-5 level with disk osteophyte impression of the ventral thecal sac and intrusion into the foramina. The central canal is not severely narrowed. However, there



is at least moderate stenosis of the foramina, particularly the right by the combination of facet arthropathy and disk osteophyte intrusion. 2) Asymmetric foraminal stenosis on the left at L3-4 resulting from a foraminal disk. The right foramen and central canal are adequately patent at this level. 3) The spinal canal and foramina are adequately patent at the other reviewed levels.

03/19/2008 – CT scan lumbar spine. 1) At L3-4, there is a left foraminal and far left lateral disk protrusion which may be contacting the exiting left L3 nerve root. 2) At L4-5, there is diffuse ventral bony ridging and bilateral foraminal disk protrusions which may be contacting the exiting L4 nerve roots. This is in association with bilateral facet hypertrophy. 3) At L5-S1, there is mild diffuse disk bulging causing a mild ventral impression upon the thecal sac and there is associated mild left neural foraminal narrowing due to a contribution from facet hypertrophy.

#### **6.4.4 Medical Decision-Making**

Based on the history, examination, and imaging, she was diagnosed with lumbar radiculitis secondary to disc displacement and spinal stenosis. Interventional techniques with caudal, lumbar interlaminar, and transforaminal were discussed and patient desired to undergo transforaminal epidural.

#### **6.4.5 Relevant Diagnosis**

- Lumbar radiculitis
- Lumbar spinal stenosis
- Lumbar disc displacement
- Lumbar degeneration of intervertebral disc

#### **6.4.6 Planned Procedures**

Left lumbar transforaminal epidural with local anesthetic and steroids L4, L5.

#### **6.4.7 First Interventional Pain Management Encounter**

The patient was treated with left lumbar transforaminal epidural with local anesthetic and steroids. This first transforaminal was performed at the L5 level with injection of 1mL of 1% preservative free lidocaine followed by injection of 3 mg of nonparticulate celestone, followed by an injection of 0.125 mL of lidocaine and then the patient was examined for pain relief. However, the pain relief was not complete; hence, transforaminal at L4 level was also performed with same dosages as at L4.

#### **6.4.8 Second Interventional Pain Management Encounter**

She reported 90% relief for 2 hours and 60% pain relief for one week at one month follow-up visits. She was treated with left lumbar transforaminal epidural with local anesthetic and steroids at L4 and L5 levels as the previous visit, with L4 first, followed by L5, with appropriate evaluation, with positive results.

#### **6.4.9 Third Interventional Pain Management Encounter**

The patient was seen a third time one month later reporting 90% relief for 10 days with sudden return of pain.

Since the patient failed to respond significantly, percutaneous adhesiolysis was planned. Even though there is no convincing evidence for percutaneous adhesiolysis in spinal stenosis or disc herniation, the evidence is emerging. Consequently, it was opted to proceed with this procedure. Provocation discography was not indicated and surgical intervention was not an option. Consequently, percutaneous adhesiolysis with hypertonic saline neurolysis was performed. The procedure involved a caudal entry into the epidural space, lumbar epidurography with 5 mL of omnipaque 240, adhesiolysis followed by repeat epidurography with 3mL of omnipaque X 2 with subsequent injection of 5 mL of 2% preservative free lidocaine. This was followed in recovery room with 6 mL of 10% hypertonic saline with 2 divided doses, followed by injection of 6 mg of nonparticulate celestone, followed injection of 1mL of 0.9% sodium chloride solution and removal of catheter.

#### **6.4.10 Fourth Interventional Pain Management Encounter**

The patient was seen a fourth time reporting 70% relief for 13 weeks. At that time she was stable, therefore the patient may be continued on this modality of treatment or reconsider surgery versus the management if she fails to respond. Spinal cord stimulation is not an option since there is no evidence of neuropathic pain and the evidence for spinal cord stimulation is mainly in post-laminectomy syndrome. All surgical options were ruled out due to patient's refusal to undergo any type of surgical intervention.

## 6.5 A Case of Chronic Low Back Pain

### 6.5.1 History of Present Illness

1. Intermittent; deep, aching, throbbing, shooting and burning; midline and bilateral paravertebral low back pain; since 08/11/2003; with gradual onset without injury after a labor epidural; with intermittent radiation to right lower extremity above the knee; predominantly on left; since 08/11/2003; with gradual onset without injury after labor epidural; associated with numbness, tingling, and pins and needles in left leg; with exacerbation with standing, walking, lumbar flexion, lumbar extension, lifting, cold and damp weather, and coughing and sneezing; with relief with sitting, lying down, resting, and medicine; with back pain worse than leg pain; which failed to respond to medical therapy; with some response to chiropractic and exercises; until 05/21/2008.

### 6.5.2 Physical Evaluation

**Lumbar Spine:** There was no evidence of scars. There was no superficial or nonanatomic tenderness. There was moderate midline tenderness from L3 to S1. There was mild paravertebral tenderness on the right side from L3 to S1 and moderate paravertebral tenderness on the left side from L3 to S1. There was moderate tenderness noted in sciatic notch region on the left side. There was mild SI joint tenderness noted. Range of motion of the lumbar spine was reduced 20% in flexion and extension with mild pain and was reduced 10% in right lateral rotation, right lateral flexion, left lateral rotation, and left lateral flexion with no pain. Range of motion of the both hips was normal with negative Patrick-Fabere's Test. The deep tendon reflexes were 1+ and equal bilaterally at Quadriceps Femoralis and Achilles. Superficial reflexes were within normal limits. Straight leg raising in supine was 90° on the right side with 60° on the left side with positive sciatic tension.

### 6.5.3 Relevant Imaging Findings

04/01/2008 – X-ray of lumbar spine. Bilateral pars defects at L5 with spondylolisthesis and disc degeneration at L5-S1.

05/12/2008 – MRI of lumbar spine. Degenerative and arthritic changes including disc protrusion and spondylolisthesis at L5-S1. No definite impingement on neural structures.

08/22/05 – MRI cervical spine without contrast. De-

generative spondylosis of the cervical spine with cervical bulges at the C4-C5 and C5-C6 interspaces. Mild facet hypertrophy at the C6 vertebral level.

### 6.5.4 Medical Decision Making

This patient presented with spinal pain. Radiologic findings indicated disc abnormalities as well as facet joint abnormalities; however, there was no definite disc herniation and evidence for radiculitis.

Based on the history, examination, and imaging findings, the diagnosis of facet joint pain was entertained. The second potential diagnosis was pain secondary to disc disease. There was no indication for sacroiliac joint pain.

### 6.5.5 Relevant Diagnosis

Lumbar acquired spondylolisthesis  
Lumbar facet joint arthropathy  
Lumbar disc displacement  
Cervical facet joint arthropathy  
Cervical degeneration of intervertebral disc

### 6.5.6 Planned Procedures

1. Left lumbar facet joint nerve block L3/4-L5/S1
2. Probable lumbar interlaminar epidural with local anesthetic with or without steroids

### 6.5.7 First Interventional Pain Management Encounter

The patient was treated with left lumbar facet joint nerve blocks from L3/4-L5/S1 utilizing 1.5 mL of 1% preservative free lidocaine with a negative response. Hence, she was treated with lumbar interlaminar epidural with local anesthetic with 10 mL of 0.5% preservative free lidocaine, followed by injection of 2mL 0.9% sodium chloride solution.

### 6.5.8 Second Interventional Pain Management Encounter

The patient was seen one month later and reported 70% relief for 4 weeks. At this time, her neck pain has increased substantially. The neck pain is in the midline and bilaterally in the neck with radiation to the left side of the head, left shoulder blade, left side of upper back, and left upper extremity above the elbow.

As per her choice, she was treated with bilateral cervical facet joint nerve blocks C2/3-C5/6 with 5 mL of 1% lidocaine preservative free, with a positive result. She was also treated with a lumbar interlaminar epidural with local anesthetic.

### **6.5.9 Third Interventional Pain Management Encounter**

She reported following the first diagnostic block for cervical facet joint nerve blocks 90% relief for 2 weeks followed by 60% relief for 4 weeks with cervical pain. She also reported 70% relief for 7 weeks with her lumbar spinal pain.

Thus, she was treated with bilateral cervical facet joint nerve blocks from C2/3-C5/6 as a confirmatory block with 5 mL of 0.25% preservative free bupivacaine. She was also treated with lumbar interlaminar epidural with local anesthetic.

### **6.5.10 Fourth Interventional Pain Management Encounter**

Following the second cervical diagnostic block with bupivacaine she reported 90% relief for one hour and 60% relief lasting for 2 weeks. The relief was less than with lidocaine and also she failed to report 90% relief as similar to the first block for 2 weeks. Thus, it was considered that her cervical pain is not related to facet joints.

However, reported 60% relief for 9 weeks with lumbar spine, thus it was decided that we will continue with lumbar interlaminar epidural, and also proceed with cervical epidural with local anesthetic.

During this visit she was treated with lumbar interlaminar epidural with local anesthetic and cervical epidural with local anesthetic, due to her desire not to have any steroids.

### **6.5.11 Fifth Interventional Pain Management Encounter**

She returned with good relief lasting for 3 months with lumbar spine and over 2 months with cervical spine. At this time she wanted to continue to undergo injection therapy without steroids. Thus, she was treated with cervical and lumbar epidural injections. She was scheduled to return in 3 months.

She has entered therapeutic phase. Therapy can be repeated in 3 months and if there is lack of response the treatment should cease in the cervical spine and in the lumbar spine.

If she fails to respond, multiple other options could be entertained including a referral to surgeon.

## **6.6 A Case of Chronic Low Back Pain**

### **6.6.1 History of Present Illness**

1. Intermittent; deep, aching, throbbing, cramping, sharp, shooting, and stabbing; midline and right

paravertebral low back pain; since 07/2004; with gradual onset without injury; with intermittent radiation to right lower extremity above the knee and occasional radiation to toes; since 07/2004; with gradual onset without injury; with worsening gradually since onset; associated with numbness, tingling, pins and needles, weakness, and burning; with exacerbation with walking, lumbar flexion, lumbar extension, right lateral flexion, left lateral flexion, cold and damp weather, and coughing and sneezing; with relief with lying down, resting, and medicine; with leg pain worse than back pain; which failed to respond to chiropractic, physical therapy, cortisone by mouth, cortisone injections, medical therapy, and exercises; with good response to epidurals and surgical intervention for one month; until 10/22/2008.

### **6.6.2 Physical Evaluation**

**Lumbar Spine:** There was evidence of a scar on the lumbar spine. There was no superficial or nonanatomic tenderness. There was mild midline tenderness from L4 to S1. There was mild paravertebral tenderness on the left side from L4 to S1 and moderate paravertebral tenderness on the right side from L4 to S1 without paravertebral spasm. There was mild tenderness noted in sciatic notch region on the left side and moderate tenderness noted in sciatic notch region on the right side. There was SI joint tenderness noted which was mild on the right side. Range of motion of the lumbar spine was reduced 10% in flexion with mild pain, reduced 20% in extension with moderate pain and normal in right lateral rotation, right lateral flexion, left lateral rotation and left lateral flexion with no pain. Range of motion of the both hips was normal with negative Patrick-Fabere's Test. The deep tendon reflexes were: Quadriceps Femoralis was 1 on the right and equal bilaterally at left. However, Achilles reflex absent on the right side, and 1 on the left side. Superficial reflexes were within normal limits. Straight leg raising in supine was 70° on the right side, and 90° on the left side with back pain only.

### **6.6.3 Relevant Imaging Findings**

02/20/2006 – X-ray of hip. Normal hip radiograph.

10/31/2008 – MRI of lumbar spine w/ & w/o contrast. 1) Degenerative disc, endplate, facet, and ligamentous disease of the lumbar spine. There are multiple asymmetries. The most severe asymmetries are at L4-L5 where there is broad based asymmetric

disc protrusion/herniation in a right central, right lateral recess, and right neural foraminal position. With associated facet hypertrophy there is asymmetric right neural foraminal stenosis at this level. 2) Very mild central spinal stenosis at L3-L4 and L4-L5. 3) Substantial disease at L5-S1, which results in mild central spinal stenosis and bilateral foraminal stenosis, which appears moderate and is greater on the right than the left. This is due to a combination of disc bulging and facet hypertrophy.

#### **6.6.4 Medical Decision-Making**

The patient presented with low back pain associated with right lower extremity pain with exacerbation with walking, lumbar flexion, lumbar extension, right lateral flexion, left lateral flexion, cold and damp weather, and coughing and sneezing which failed to respond to various modalities of treatments including surgical intervention and blind epidural injections.

Based on history, examination, and imaging, caudal epidural was chosen due to post-lumbar laminectomy syndrome. Patient underwent surgery with laminectomy and fusion with hardware. Significant evidence has been shown in a systematic review (93) for fluoroscopically directed caudal epidurals (97,98).

#### **6.6.5 Relevant Diagnosis**

- Lumbar post laminectomy syndrome
- Lumbar spinal stenosis
- Lumbar degeneration of intervertebral disc

#### **6.6.6 Planned Procedures**

Caudal epidural with local anesthetic with or without steroids.

#### **6.6.7 First Interventional Pain Management Encounter**

The patient was treated with caudal epidural with local anesthetic (9mL of 0.5% preservative free lidocaine) and steroids (6 mg of nonparticulate celestone).

#### **6.6.8 Second Interventional Pain Management Encounter**

The patient was seen one month later reporting 90% relief for 3 days. The relief of 3 days is not significant with regards to the duration, even though quality of relief was good. At this time with the discussions, patient opted to undergo another epidural procedure prior to proceeding with another modality of treatment, namely, percutaneous adhesiolysis.

#### **6.6.9 Third Interventional Pain Management Encounter**

She returned with a report of approximately relief of 50% for one month. She was not satisfied with either the quality or duration of relief. Following the discussions, it was decided that we will proceed with percutaneous adhesiolysis.

She underwent percutaneous adhesiolysis with steroids and hypertonic saline neurolysis, with a Racz catheter, 11 mL of omnipaque 240, 5mL of 2% preservative free lidocaine, 6 mL of 10% sodium chloride solution, 6 mg of nonparticulate celestone and 1 mL of 0.9 % sodium chloride solution.

#### **6.6.10 Fourth Interventional Pain Management Encounter**

She returned 3 months after the treatment and reported 60% to 70% improvement in her physical and functional status which lasted for almost 3 months. She had only one episode of pain which was controlled with exercises and medication. Thus, the percutaneous non-endoscopic adhesiolysis procedure was repeated.

Now she has entered the therapeutic phase. If she fails to respond to percutaneous adhesiolysis and if willing, other options include spinal cord stimulation or intrathecal morphine infusion system implantation may be considered.

### **6.7 A Case of Chronic Neck Pain**

#### **6.7.1. History of Present Illness**

Intermittent; deep, aching and throbbing; midline and right paravertebral neck pain since 2004 and right shoulder pain since 1995; with intermittent radiation to right shoulder blade, right side of upper back, and right upper extremity above elbow; since 2004; with gradual onset without injury; with worsening gradually since onset; associated with numbness and weakness; with exacerbation with coughing/sneezing, lifting, standing, walking, overhead activity, and cold/damp weather; with relief with lying down/resting and medicine; with neck pain worse than arm pain; which failed to respond to chiropractic treatment, cortisone injection into joint, medical therapy, exercises, and Synvisc injections; until 8/2/2006.

#### **6.7.2 Physical Evaluation**

**Cervical Spine:** There was no evidence of scars. There was no superficial or nonanatomic tenderness. There was moderate midline paravertebral tenderness from C2 to C7. There was moderate suboccipital ten-

derness on the right side with elicitation of a headache. There was moderate upper trapezius tenderness on the right side. There was severe shoulder tenderness on the right side. There was severe AC joint tenderness on the right side. Range of motion of the cervical spine was reduced 10% in all directions with mild pain. Range of motion of right shoulder was reduced with evidence of impingement, right shoulder was normal. Motor strength was significantly reduced on the right side with no focal deficits. Grip strength was moderately reduced on the right side. The deep tendon reflexes evaluation were 1+ and equal.

### **6.7.3. Relevant Imaging Findings**

11/9/2005 – X-ray of the cervical spine. X-rays show multiple level disc disease with subluxation of C2 on C3 and angulatory deformity of C3 on C4. There is narrow disc space at C4-5 and C5-6. Flexion extension films show no gross instability or reduction. There is straightening of the cervical lordosis on extension. This motion appears to be occurring at the 3-4 level.

12/29/2006 – MRI cervical spine. Disc and bony degenerative changes within the cervical spine most pronounced at the C5-C6 level where there is mild narrowing of the central canal.

### **6.7.4. Medical Decision-Making**

The patient presented with pain in the cervical, lumbar, and thoracic regions. However, her primary problem was cervical pain. Based on the history and physical examination and imaging studies, it appeared that she was suffering with cervical facet joint pain. She also had shoulder problems, however these have been addressed separately.

### **6.7.5 Relevant Diagnosis**

Cervical facet joint arthropathy  
Cervical degeneration of intervertebral disc  
Right AC joint arthritis

### **6.7.6 Planned Procedures**

1. Right cervical facet joint nerve blocks C3/4-C6/7
2. Probable cervical epidural with local anesthetic with or without steroids

### **6.7.7 First Interventional Pain Management Encounter**

The patient was treated with right cervical facet joint nerve blocks from C3/4-C6/7, utilizing 2.5 mL of 1% preservative free lidocaine with positive results.

### **6.7.8 Second Interventional Pain Management Encounter**

The patient reported 100% relief for one week and 80% relief for 2 weeks with neck. He was treated with right cervical facet joint nerve blocks C3/4-C6/7 with 0.25% preservative free 2.5 mL bupivacaine with positive result.

### **6.7.9 Third Interventional Pain Management Encounter**

The patient reported more than 90% relief for 2 weeks and more than 70% relief for 4 weeks with neck. His diagnosis of cervical facet joint pain was confirmed.

He was provided with options which were radiofrequency neurotomy or therapeutic medial branch nerve blocks. Patient chose radiofrequency thermal neurotomy, thus, these were performed on C3-C6 medial branches.

### **6.7.10 Fourth Interventional Pain Management Encounter**

Patient was seen after 6 months following the medial branch radiofrequency neurotomy with no treatment provided after 3 months because of continued relief. He reported 60% relief with functional status improvement lasting for 5 months.

Hence, medial branch radiofrequency thermal neurotomy was repeated. He will be monitored for follow-up and if required he will be treated with repeat cervical facet joint nerve radiofrequency thermal neurotomy. If he fails to respond, cervical epidural may be considered.

## **6.8 A Case of Chronic Thoracic Pain**

### **6.8.1 History of Present Illness**

Intermittent; deep, aching, sharp, burning; left paravertebral thoracic pain; since 1996; with gradual onset without injury; with intermittent radiation to left side of chest wall and left side of abdominal wall; since 1996; with gradual onset without injury; with worsening gradually since onset; not associated with numbness, tingling, or pins & needles; with exacerbation with thoracic flexion, right lateral flexion, left lateral flexion; with relief with lying down/resting and medicine; with thoracic pain worse than chest wall pain; which failed to respond to chiropractic treatment, medical therapy, or exercises; until 05/28/2008.



### **6.8.2 Physical Evaluation**

**Thoracic Spine:** There was no evidence of scars on the thoracic spine or chest wall. There was mild midline tenderness from T9 to T12. There was moderate paravertebral tenderness on the left side from T9 to T12. There was chest wall tenderness on the left side from T9 to T12 in midaxillary line.

### **6.8.3 Relevant Imaging Findings**

06/02/2008 – X-ray of thoracic spine. Mild degenerative disc disease is seen throughout the mid thoracic spine. A small Schmorl's node may be present along the inferior endplate of T11.

06/02/2008 – MRI thoracic spine. There is mild disc space narrowing and desiccation seen from the T6/7 through T8/9 levels. Mild broad based disc bulges are suggested at T6/7, T8/9, and T9/10. These create only minimal narrowing of the adjacent spinal canal.

### **6.8.4 Medical Decision Making**

This patient presented with pain in the thoracic region with radiation towards the chest wall and abdominal wall with radiographic findings of disc bulges at 3 levels causing minimal narrowing of the spinal canal. Pain was both axial and radicular, thus the options were to proceed with a thoracic interlaminar epidural. However if the patient failed to respond to this, facet joint nerve blocks or provocation discography, if options were available for managing thoracic discogenic pain, were of consideration.

### **6.8.5 Relevant Diagnosis**

- Thoracic disc displacement
- Thoracic degeneration of intervertebral disc
- Thoracic facet joint arthropathy

### **6.8.6 Planned Procedure**

Thoracic epidural with local anesthetic with or without steroids

### **6.8.7 First Interventional Pain Management Encounter**

Patient was treated with thoracic interlaminar epidural injection with steroids entering the epidural space between T9 and T10 under fluoroscopy, utilizing 6 mL of omnipaque 240, followed by injectin of 5 mL 0.5% preservative free lidocaine mixed with 6 mg of nonparticulate Celestone.

### **6.8.8 Second Interventional Pain Management Encounter**

Patient reported 90% relief for 5 weeks with improvement in functional status, hence, a repeat procedure was carried out.

### **6.8.9 Third Interventional Pain Management Encounter**

He reported 70% relief lasting approximately 9 weeks with improvement in functional status, hence, a third epidural injection was repeated.

### **6.8.10 Fourth Interventional Pain Management Encounter**

The patient experienced 70% relief for 3 months and 50% relief for one-month following the third epidural injection. At this time the repeat injection was provided.

Now the patient has entered the therapeutic phase. Based on the response, future treatments will be carried out either with continued epidural injections or if patient fails to respond other modalities should be considered.

## **6.9 A Case of Chronic Thoracic Pain**

### **6.9.1 History of Present Illness**

Intermittent; deep, aching and stabbing; midline and bilateral paravertebral thoracic pain; since 2005; with gradual onset following gunshot injury; with rare radiation to both sides of chest wall; since 2005; with gradual onset following gunshot injury; with worsening gradually since onset; not associated with numbness, tingling, pins and needles, weakness, and burning; with exacerbation with thoracic flexion, thoracic extension, overhead activity, and cold and damp weather; with relief with lying down, resting and medicine; with thoracic pain worse than chest wall pain; which failed to respond to medical therapy and exercises; until 10/01/2008.

### **6.9.2 Physical Evaluation**

**Thoracic Spine:** There was no evidence of scars. There was moderate midline and bilateral paravertebral tenderness from T8 to T12.

### **6.9.3 Relevant Imaging Findings**

05/26/2007 – X-ray of thoracic spine. No definite acute pathology is seen.



09/07/2007 - MRI thoracic spine. No fracture or subluxation is evident. No lesion is noted in the spinal cord. No disc protrusion or spinal stenosis is evident.

#### **6.9.4 Medical Decision Making**

This patient presented with pain in the thoracic and lumbar regions, however predominant pain was present in the thoracic spine. Thoracic pain was of axial nature with no radicular component. Thus, based on history, examination, and results of imaging a diagnosis of thoracic facet joint pain was entertained.

#### **6.9.5 Relevant Diagnosis**

Thoracic degeneration of intervertebral disc  
Thoracic facet joint arthropathy

#### **6.9.6 Planned Procedures**

1. Bilateral thoracic facet joint nerve blocks T8/9-T11/12
2. Probable thoracic epidural with local anesthetic with or without steroids

#### **6.9.7 First Interventional Pain Management Encounter**

The patient was treated with bilateral thoracic facet joint nerve blocks from T8/9 to T11/12 utilizing 4 mL of 1% preservative free lidocaine with positive preliminary diagnosis of thoracic facet joint pain.

#### **6.9.8 Second Interventional Pain Management Encounter**

The patient experienced 50% relief for one week, with negative diagnosis for facet joint pain. Thus, he was treated with a thoracic epidural with local anesthetic (5mL of 0.5% preservative free lidocaine) and steroids (6 mg of nonparticulate celestone).

#### **6.9.9 Third Interventional Pain Management Encounter**

The patient experienced 50% relief for one month and was treated with thoracic epidural with local anesthetic and steroids.

#### **6.9.10 Fourth Interventional Pain Management Encounter**

The patient experienced 60% relief for 2½ months and was treated with thoracic epidural with local an-

esthetic and steroids.

Thus, he has entered into the therapeutic phase. He appears to be stable. If he continues to respond with at least 3 months of relief without any adverse effects, this may be continued. If there is no response or insignificant response, further options should be evaluated. However, there are not many options available.

### **CONCLUSION**

The algorithmic approach described in this article included some of the commonly utilized interventional techniques, but has not described a case by case basis of mechanical disc decompression, intradiscal therapies, sacroiliac joint injections, or intrathecal implantables.

If this algorithm is utilized, it should be followed appropriately without excessive use of modalities.

### **ACKNOWLEDGMENTS**

The authors wish to thank the editorial board of *Pain Physician*, for review and criticism in improving the manuscript; Sekar Edem and Vidyasagar Pampati for their assistance in the literature search; and Tonie M. Hatton and Diane E. Neihoff, transcriptionists (Pain Management Center of Paducah), for their assistance in preparation of this manuscript.

### **AUTHOR AFFILIATION**

Dr. Manchikanti is Medical Director of the Pain Management Center of Paducah, Paducah, KY. Dr. Helm is Medical Director, Pacific Coast Pain Management Center, Laguna Hills, CA. Dr. Singh is Medical Director of Pain Diagnostics Associates, Niagara, WI. Dr. Benyamin is Medical Director, Millennium Pain Center, Clinical Associate Professor, Department of Surgery, College of Medicine, University of Illinois, Urbana-Champaign, IL. Dr. Datta is Director, Vanderbilt University Interventional Pain Program, Associate Professor, Dept. of Anesthesiology, Vanderbilt University Medical Center, Nashville, TN. Dr. Hayek is Chief of the Division of Pain Medicine, Department of Anesthesiology, University Hospitals of Cleveland, Cleveland, OH; and a member of the Outcomes Research Consortium, Cleveland, OH. Mr. Fellows is Director Emeritus of Psychological Services, Pain Management Center of Paducah, Paducah, KY. Dr. Boswell is the Chairman of Department of Anesthesiology and Director of the International Pain Center, Texas Tech University Health Sciences Center, Lubbock, TX.

## REFERENCES

- Boswell MV, Trescot AM, Datta S, Schultz DM, Hansen HC, Abdi S, Sehgal N, Shah RV, Singh V, Benyamin RM, Patel VB, Buenaventura RM, Colson JD, Cordero HJ, Epter RS, Jasper JF, Dunbar EE, Atluri SL, Bowman RC, Deer TR, Swicegood JR, Staats PS, Smith HS, Burton AW, Klothe DS, Giordano J, Manchikanti L. Interventional techniques: Evidence-based practice guidelines in the management of chronic spinal pain. *Pain Physician* 2007; 10:7-111.
- US Department of Health and Human Services. Office of Inspector General (OIG). Medicare Payments for Facet Joint Injection Services (OEI-05-07-00200). September 2008. [www.oig.hhs.gov/oei/reports/oei-05-07-00200.pdf](http://www.oig.hhs.gov/oei/reports/oei-05-07-00200.pdf)
- Estimate based on OIG analysis of facet joint injection procedure codes in the following Medicare claims files: (1) 2003 1-percent sample of NCH outpatient and physician/supplier files, and (2) 2006 100-percent NCH outpatient and physician/supplier files.
- Friedly J, Chan L, Deyo R. Increases in lumbosacral injections in the Medicare population: 1994 to 2001. *Spine* 2007; 32:1754-1760.
- Friedly J, Chan L, Deyo R. Geographic variation in epidural steroid injection use in Medicare patients. *J Bone Joint Surg Am* 2008; 90:1730-1737.
- Manchikanti L, Giordano J. Physician payment 2008 for interventionalists: Current state of health care policy. *Pain Physician* 2007; 10:607-626.
- Manchikanti L, Boswell MV. Interventional techniques in ambulatory surgical centers: A look at the new payment system. *Pain Physician* 2007; 10:627-650.
- Manchikanti L, Singh V, Pampati V, Smith HS, Hirsch JA. Analysis of growth of interventional techniques in managing chronic pain in Medicare population: A 10-year evaluation from 1997 to 2006. *Pain Physician* 2009; 12:9-34.
- Manchikanti L, McMahon EB. Physician refer thyself: Is Stark II, Phase III the final voyage? Health Policy Update. *Pain Physician* 2007; 10:725-741.
- Manchikanti L. Health care reform in the United States: Radical surgery needed now more than ever. *Pain Physician* 2008; 11:13-42.
- Manchikanti L, Hirsch JA. Obama health care for all Americans: Practical implications. *Pain Physician* 2009; 12:289-304.
- Eden J, Wheatley B, McNeil B, Sox H. *Knowing What Works in Health Care: A Roadmap for the Nation*. National Academies Press, Washington, DC, 2008.
- U.S. Department of Health and Human Services. Centers for Medicare and Medicaid Services. CMS Manual System. Facet Joints. Transmittal #440. Publication # 100-20. Change Request 6317. March 9, 2009. [www.cms.hhs.gov/transmittals/downloads/R440OTN.pdf](http://www.cms.hhs.gov/transmittals/downloads/R440OTN.pdf)
- Staal JB, de Bie R, de Vet HC, Hildebrandt J, Nelemans P. Injection therapy for subacute and chronic low-back pain: An updated Cochrane review. *Spine* 2009; 34:49-59.
- van Tulder MW, Koes BW, Bouter LM. Conservative treatment of acute and chronic nonspecific low back pain. A systematic review of randomized controlled trials of the most common interventions. *Spine* 1997; 22:2128-2156.
- Atluri S, Datta S, Falco FJE, Lee M. Systematic review of diagnostic utility and therapeutic effectiveness of thoracic facet joint interventions. *Pain Physician* 2008; 11:611-629.
- Singh V, Manchikanti L, Shah RV, Dunbar EE, Glaser SE. Systematic review of thoracic discography as a diagnostic test for chronic spinal pain. *Pain Physician* 2008; 11:631-642.
- Parr AT, Diwan S, Abdi S. Lumbar interlaminar epidural injections in managing chronic low back and lower extremity pain: A systematic review. *Pain Physician* 2009; 12:163-188.
- Benyamin RM, Singh V, Parr AT, Conn A, Diwan S, Abdi S. Systematic review of the effectiveness of cervical epidurals in the management of chronic neck pain. *Pain Physician* 2009; 12:137-157.
- Helm S, Hayek S, Benyamin RM, Manchikanti L. Systematic review of the effectiveness of thermal annular procedures in treating discogenic low back pain. *Pain Physician* 2009; 12:207-232.
- Buenaventura RM, Datta S, Abdi S, Smith HS. Systematic review of therapeutic lumbar transforaminal epidural steroid injections. *Pain Physician* 2009; 12:233-251.
- Manchikanti L, Glaser S, Wolfer L, Derby R, Cohen SP. Systematic review of lumbar discography as a diagnostic test for chronic low back pain. *Pain Physician* 2009; 12:541-560.
- Datta S, Lee M, Falco FJE, Bryce DA, Hayek SM. Systematic assessment of diagnostic accuracy and therapeutic utility of lumbar facet joint interventions. *Pain Physician* 2009; 12:437-460.
- Falco FJE, Erhart S, Wargo BW, Bryce DA, Atluri S, Datta S, Hayek SM. Systematic review of diagnostic utility and therapeutic effectiveness of cervical facet joint interventions. *Pain Physician* 2009; 12:323-344.
- Frey ME, Manchikanti L, Benyamin RM, Schultz DM, Smith HS, Cohen SP. Spinal cord stimulation for patients with failed back surgery syndrome: A systematic review. *Pain Physician* 2009; 12:379-397.
- Epter RS, Helm S, Hayek SM, Benyamin RM, Smith HS, Abdi S. Systematic review of percutaneous adhesiolysis and management of chronic low back pain in post lumbar surgery syndrome. *Pain Physician* 2009; 12:361-378.
- Patel VB, Manchikanti L, Singh V, Schultz DM, Hayek SM, Smith HS. Systematic review of intrathecal infusion systems for long-term management of chronic non-cancer pain. *Pain Physician* 2009; 12:345-360.
- Rupert MP, Lee M, Manchikanti L, Datta S, Cohen SP. Evaluation of sacroiliac joint interventions: A systematic appraisal of the literature. *Pain Physician* 2009; 12:399-418.
- Manchikanti L, Dunbar EE, Wargo BW, Shah RV, Derby R, Cohen SP. Systematic review of cervical discography as a diagnostic test for chronic spinal pain. *Pain Physician* 2009; 12:305-321.
- Hayek SM, Helm S, Benyamin RM, Singh V, Bryce DA, Smith HS. Effectiveness of spinal endoscopic adhesiolysis in post lumbar surgery syndrome: A systematic review. *Pain Physician* 2009; 12:419-435.
- Hirsch JA, Singh V, Falco FJE, Benyamin RM, Manchikanti L. Automated percutaneous lumbar discectomy for the contained herniated lumbar disc: A systematic assessment of evidence. *Pain Physician* 2009; 12:601-620.
- American College of Occupational and Environmental Medicine. Low Back Disorders Chapter. In: *Occupational Medicine Practice Guidelines: Evaluation and Management of Common Health Problems and Functional Recovery of Workers*, Second Edition. American College of Occupational and Environmental Medicine, Elk Grove Village, 2007.
- American College of Occupational and Environmental Medicine. Chronic Pain Chapter (revised 2008). In: *Occupational Medicine Practice Guidelines: Evaluation and Management of Common*

- Health Problems and Functional Recovery of Workers*, Second Edition. American College of Occupational and Environmental Medicine, Elk Grove Village, 2008.
34. HAYES, Inc. Independent Health Technology Assessment Company. www.hayesinc.com
  35. Dennison PL. *Official Disability Guidelines*, 13th ed. Work Loss Data Institute, 2008.
  36. Singh V, Manchikanti L, Benyamin RM, Helm S, Hirsch JA. Percutaneous lumbar laser disc decompression: A systematic review of current evidence. *Pain Physician* 2009; 12:573-588.
  37. Singh V, Benyamin RM, Datta S, Falco FJE, Helm S, Manchikanti L. Systematic review of percutaneous lumbar mechanical disc decompression utilizing Dekompressor. *Pain Physician* 2009; 12:589-600.
  38. Manchikanti L, Derby R, Benyamin RM, Helm S, Hirsch JA. A systematic review of mechanical lumbar disc decompression with nucleoplasty. *Pain Physician* 2009; 12:561-572.
  39. Manchikanti L, Singh V, Derby R, Schultz DM, Benyamin RM, Prager JP, Hirsch JA. Reassessment of evidence synthesis of occupational medicine practice guidelines for interventional pain management. *Pain Physician* 2008; 11:393-482.
  40. Wilson PR, Caplan RA, Connis RT, Gilbert HC, Grigsby EJ, Haddox JD, Harvey AM, Korevaar WC, Lubenow TR, Simon DL. Practice guidelines for chronic pain management. A report by the American Society of Anesthesiologists Task Force on Pain Management, Chronic Pain Section. *Anesthesiology* 1997; 86:995-1004.
  41. Sanders SH, Harden RN, Benson SE, Vicente PJ. Clinical practice guidelines for chronic non-malignant pain syndrome patients II: An evidence-based approach. *J Back Musc Rehabil* 1999; 13:47-58.
  42. Nelemans PJ, deBie RA, DeVet HC, Sturmans F. Injection therapy for subacute and chronic benign low back pain. *Spine* 2001; 26:501-515.
  43. Geurts JW, van Wijk RM, Stolker RJ, Groen GJ. Efficacy of radiofrequency procedures for the treatment of spinal pain: A systematic review of randomized clinical trials. *Reg Anesth Pain Med* 2001; 26:394-400.
  44. Niemisto L, Kalso E, Malmivaara A, Seit-salo S, Hurri H. Cochrane Collaboration Back Review Group. Radiofrequency denervation for neck and back pain: A systematic review within the framework of the Cochrane collaboration back review group. *Spine* 2003; 28:1877-1888.
  45. van Tulder MW, Koes B, Malmivaara A. Outcome of non-invasive treatment modalities on back pain: An evidence-based review. *Eur Spine J* 2006; 15:S64-S81.
  46. Bogduk N, McGuirk B. *Management of Acute and Chronic Neck Pain. An Evidence-Based Approach*. Elsevier, Edinburgh, 2006.
  47. Koes BW, Scholten RJ, Mens JMA, Butler LM. Epidural steroid injections for low back pain and sciatica. An updated systematic review of randomized clinical trials. *Pain Digest* 1999; 9:241-247.
  48. Bigos SJ, Boyer OR, Braen GR, Brown K, Deyo R, Haldeman S, Hart JL, Johnson EW, Keller R, Kido D, Liang MH, Nelson RM, Nordin M, Owen BD, Pope MH, Schwartz RK, Stewart DH, Susman J, Triano JJ, Tripp LC, Turk DC, Watts C, Weinstein JN. Acute Low Back Problems in Adults. Clinical Practice Guideline No. 14, AHCPR Publication No. 95-0642. Rockville, Maryland, U.S.A., Agency for Health Care Policy and Research, Public Health Service, U.S., Department of Health and Human Services, December, 1994, pp 1-60.
  49. Boswell MV, Shah RV, Everett CR, Sehgal N, McKenzie-Brown AM, Abdi S, Bowman RC, Deer TR, Datta S, Colson JD, Spillane WF, Smith HS, Lucas-Levin LF, Burton AW, Chopra P, Staats PS, Waserman RA, Manchikanti L. Interventional techniques in the management of chronic spinal pain: Evidence-based practice guidelines. *Pain Physician* 2005; 8:1-47.
  50. Bogduk N. An algorithm for the investigation of low back pain. *Practice Guidelines for Spinal Diagnostic and Treatment Procedures*. International Spine Intervention Society (ISIS), San Francisco, 2004, pp 87-94.
  51. Bogduk N. An algorithm for the conduct of cervical synovial joint blocks. *Practice Guidelines for Spinal Diagnostic and Treatment Procedures*. International Spine Intervention Society (ISIS). San Francisco, 2004, pp 152-160.
  52. Manchikanti L, Singh V, Helm S, Schultz DM, Datta S, Hirsch J. An Introduction to an Evidence-Based Approach to Interventional Techniques in the Management of Chronic Spinal Pain. *Pain Physician* 2009; 12: E1-E33.
  53. Manchikanti L, Singh V, Datta S, Cohen SP, Hirsch JA. Comprehensive Review of Epidemiology, Scope, and Impact of Spinal Pain. *Pain Physician* 2009; 12: E35-E70.
  54. Manchikanti L, Boswell MV, Singh V, Derby R, Fellows B, Falco FJE, Datta S, Smith HS, Hirsch JA. Comprehensive Review of Neurophysiologic Basis and Diagnostic Interventions in Managing Spinal Pain. *Pain Physician* 2009; 12: E71-E120.
  55. Manchikanti L, Boswell MV, Datta S, Fellows B, Abdi S, Singh V, Benyamin RM, Falco FJE, Helm S, Hayek S, Smith HS. Comprehensive Review of Therapeutic Interventions in Managing Chronic Spinal Pain. *Pain Physician* 2009; 12:E123-E198.
  56. Manchikanti L, Singh V, Pampati V, Boswell MF, Benyamin RM, Hirsch JA. Description of Documentation in the Management of Chronic Spinal Pain. *Pain Physician* 2009; 12:E199-E224.
  57. Kuslich SD, Ulstrom CL, Michael CJ. The tissue origin of low back pain and sciatica: A report of pain response to tissue stimulation during operation on the lumbar spine using local anesthesia. *Orthop Clin North Am* 1991; 22:181-187.
  58. Boswell MV, Singh V, Staats PS, Hirsch JA. Accuracy of precision diagnostic blocks in the diagnosis of chronic spinal pain of facet or zygapophysial joint origin: A systematic review. *Pain Physician* 2003; 6:449-456.
  59. Sehgal N, Shah RV, McKenzie-Brown A, Everett CR. Diagnostic utility of facet (zygapophysial) joint injections in chronic spinal pain: A systematic review of evidence. *Pain Physician* 2005; 8:211-224.
  60. Sehgal N, Dunbar EE, Shah RV, Colson JD. Systematic review of diagnostic utility of facet (zygapophysial) joint injections in chronic spinal pain: An update. *Pain Physician* 2007; 10:213-228.
  61. Bogduk N. International Spinal Injection Society guidelines for the performance of spinal injection procedures. Part 1. Zygapophysial joint blocks. *Clin J Pain* 1997; 13:285-302.
  62. McKenzie-Brown AM, Shah RV, Sehgal N, Everett CR. A systematic review of sacroiliac joint interventions. *Pain Physician* 2005; 8:115-125.
  63. Hansen HC, McKenzie-Brown AM, Cohen SP, Swicegood JR, Colson JD, Manchikanti L. Sacroiliac joint interventions: A systematic review. *Pain Physi-*

64. Datta S, Everett CR, Trescot AM, Schulz DM, Adlaka R, Abdi S, Atluri SL, Smith HS, Shah RV. An updated systematic review of diagnostic utility of selective nerve root blocks. *Pain Physician* 2007; 10:113-128.
65. Manchikanti L, Singh V, Pampati V, Damron K, Barnhill R, Beyer C, Cash K. Evaluation of the relative contributions of various structures in chronic low back pain. *Pain Physician* 2001; 4:308-316.
66. Manchikanti L, Hirsch JA, Pampati V. Chronic low back pain of facet (zygapophysial) joint origin: Is there a difference based on involvement of single or multiple spinal regions? *Pain Physician* 2003; 6:399-405.
67. Manchukonda R, Manchikanti KN, Cash KA, Pampati V, Manchikanti L. Facet joint pain in chronic spinal pain: An evaluation of prevalence and false-positive rate of diagnostic blocks. *J Spinal Disord Tech* 2007; 20:539-545.
68. Manchikanti L, Boswell MV, Singh V, Pampati V, Damron KS, Beyer CD. Prevalence of facet joint pain in chronic spinal pain of cervical, thoracic, and lumbar regions. *BMC Musculoskelet Disord* 2004; 5:15.
69. Manchikanti L, Singh V, Pampati V, Damron KS, Beyer CD, Barnhill RC. Is there correlation of facet joint pain in lumbar and cervical spine? An evaluation of prevalence in combined chronic low back and neck pain. *Pain Physician* 2002; 5:365-371.
70. Schwarzer AC, Wang S, Bogduk N, McNaught PJ, Laurent R. Prevalence and clinical features of lumbar zygapophysial joint pain: A study in an Australian population with chronic low back pain. *Am Rheum Dis* 1995; 54:100-106.
71. Manchikanti L, Manchukonda R, Pampati V, Damron KS, McManus CD. Prevalence of facet joint pain in chronic low back pain in postsurgical patients by controlled comparative local anesthetic blocks. *Arch Phys Med Rehabil* 2007; 88:449-455.
72. Manchikanti L, Pampati V, Fellows B, Rivera JJ, Damron KS, Beyer CD, Cash KA. Influence of psychological factors on the ability to diagnose chronic low back pain of facet joint origin. *Pain Physician* 2001; 4:349-357.
73. Manchikanti L, Cash KA, Pampati V, Fellows B. Influence of psychological variables on the diagnosis of facet joint involvement in chronic spinal pain. *Pain Physician* 2008; 11:145-160.
74. Manchikanti L, Boswell MV, Manchukonda R, Cash KA, Giordano. Influence of prior opioid exposure on diagnostic facet joint nerve blocks. *J Opioid Manage* 2008; 4:351-360.
75. Manchikanti L, Damron KS, Rivera J, McManus CD, Jackson SD, Barnhill RC, Martin JC. Evaluation of effect of sedation as a confounding factor in the diagnostic validity of lumbar facet joint pain: A prospective, randomized, double-blind, placebo-controlled evaluation. *Pain Physician* 2004; 7:411-417.
76. Manchikanti L, Pampati V, Damron K. The role of placebo and nocebo effects of perioperative administration of sedatives and opioids in interventional pain management. *Pain Physician* 2005; 8:349-355.
77. Smith HS, Chopra P, Patel VB, Frey ME, Rastogi R. Systematic review on the role of sedation in diagnostic spinal interventional techniques. *Pain Physician* 2009; 12:195-206.
78. Hancock MJ, Maher CG, Latimer J, Spindler MF, McAuley JH, Laslett M, Bogduk N. Systematic review of tests to identify the disc, SIJ or facet joint as the source of low back pain. *Eur Spine J* 2007; 16:1539-1550.
79. Irwin RW, Watson T, Minick RP, Ambrosius WT. Age, body mass index, and gender differences in sacroiliac joint pathology. *Am J Phys Med Rehabil* 2007; 86:37-44.
80. Maigne JY, Aivakiklis A, Pfefer F. Results of sacroiliac joint double block and value of sacroiliac pain provocation test in 54 patients with low back pain. *Spine* 1996; 21:1889-1892.
81. Laslett M, Young SB, Aprill CN, McDonald B. Diagnosing painful sacroiliac joints: A validity study of a McKenzie evaluation and sacroiliac provocation tests. *Aust J Physiother* 2003; 49:89-97.
82. van der Wurff P, Buijs EJ, Groen GJ. A multitest regimen of pain provocation tests as an aid to reduce unnecessary minimally invasive sacroiliac joint procedures. *Arch Phys Med Rehabil* 2006; 87:10-14.
83. Rubinstein SM, van Tulder M. A best-evidence review of diagnostic procedures for neck and low-back pain. *Best Pract Res Clin Rheumatol* 2008; 22:471-482.
84. Donelson R, Aprill C, Medcalf R, Grant W. A prospective study of centralization of lumbar and referred pain. A predictor of symptomatic discs and anular competence. *Spine* 1997; 22:1115-1122.
85. Horton WC, Daftari TK. Which disc as visualized by magnetic resonance imaging is actually a source of pain? A correlation between magnetic resonance imaging and discography. *Spine* 1992; 17: S164-S171.
86. Zucherman J, Derby R, Hsu K, Picetti G, Kaiser J, Schofferman J, Goldthwaite N, White A. Normal magnetic resonance imaging with abnormal discography. *Spine* 1988; 13:1355-1359.
87. Shah RV, Everett C, McKenzie-Brown A, Sehgal N. Discography as a diagnostic test for spinal pain: A systematic and narrative review. *Pain Physician* 2005; 8:187-209.
88. Buenaventura RM, Shah RV, Patel V, Benyamin R, Singh V. Systematic review of discography as a diagnostic test for spinal pain: An update. *Pain Physician* 2007; 10:147-164.
89. Wolfer L, Derby R, Lee JE, Lee SH. Systematic review of lumbar provocation discography in asymptomatic subjects with a meta-analysis of false-positive rates. *Pain Physician* 2008; 11:513-538.
90. Carrino JA, Morrison WB, Parker L, Schweitzer ME, Levin DC, Sunshine JH. Spinal injection procedures: Volume, provider distribution, and reimbursement in the U.S. medicare population from 1993 to 1999. *Radiology* 2002; 225:723-729.
91. Specialty Utilization data files from CMS: [www.cms.hhs.gov](http://www.cms.hhs.gov).
92. Schoelles K, Reston J, Treadwell J, Noble M, Snyder D. Spinal fusion and discography for chronic low back and uncomplicated lumbar degenerative disc disease. Health Technology Assessment. Washington State Health Care Authority, October 19, 2007.
93. Conn A, Buenaventura R, Datta S, Abdi S, Diwan S. Systematic review of caudal epidural injections in the management of chronic low back pain. *Pain Physician* 2009; 12:109-135.
94. Manchikanti L, Cash KA, McManus CD, Pampati V, Smith HS. Preliminary results of randomized, equivalence trial of fluoroscopic caudal epidural injections in managing chronic low back pain: Part 1. Discogenic pain without disc herniation or radiculitis. *Pain Physician* 2008; 11:785-800.
95. Manchikanti L, Singh V, Rivera JJ, Pampati V, Beyer CD, Damron KS, Barnhill RC. Effectiveness of caudal epidural injections in discogram positive and negative chronic low back pain. *Pain Physician* 2002; 5:18-29.
96. Manchikanti L, Singh V, Cash KA, Pam-



- pati V, Damron KS, Boswell MV. Preliminary results of randomized, equivalence trial of fluoroscopic caudal epidural injections in managing chronic low back pain: Part 2. Disc herniation and radiculitis. *Pain Physician* 2008; 11:801-815.
97. Manchikanti L, Cash KA, McManus CD, Pampati V, Abdi S. Preliminary results of randomized, equivalence trial of fluoroscopic caudal epidural injections in managing chronic low back pain: Part 4. Spinal stenosis. *Pain Physician* 2008; 11:833-848.
  98. Manchikanti L, Singh V, Cash KA, Pampati V, Datta S. Preliminary results of randomized, equivalence trial of fluoroscopic caudal epidural injections in managing chronic low back pain: Part 3. Post surgery syndrome. *Pain Physician* 2008; 11:817-831.
  99. Manchikanti L, Singh V, Falco FJ, Cash KA, Pampati V. Lumbar facet joint nerve blocks in managing chronic facet joint pain: One-year follow-up of a randomized, double-blind controlled trial: Clinical Trial NCT00355914. *Pain Physician* 2008; 11:121-132.
  100. Manchikanti L, Pampati V, Bakhit C, Rivera J, Beyer C, Damron K, Barnhill R. Effectiveness of lumbar facet joint nerve blocks in chronic low back pain: A randomized clinical trial. *Pain Physician* 2001; 4:101-117.
  101. Nath S, Nath CA, Pettersson K. Percutaneous lumbar zygapophysial (facet) joint neurotomy using radiofrequency current, in the management of chronic low back pain: A randomized double-blind trial. *Spine* 2008; 33:1291-1298.
  102. Gofeld M, Jitendra J, Faclier G. Radiofrequency facet denervation of the lumbar zygapophysial joints: 10-year prospective clinical audit. *Pain Physician* 2007; 10:291-300.
  103. Dreyfuss P, Halbrook B, Pauza K, Joshi A, McLarty J, Bogduk N. Efficacy and validity of radiofrequency neurotomy for chronic lumbar zygapophysial joint pain. *Spine* 2000; 25:1270-1277.
  104. Gibson JN, Waddell G. Surgical interventions for lumbar disc prolapse: Updated Cochrane review. *Spine* 2007; 32:1735-1747.
  105. Gibson JNA, Waddell G. Surgical interventions for lumbar disc prolapse. *Cochrane Database Syst Rev* 2009; (1): CD001350.
  106. Trescot AM, Chopra P, Abdi S, Datta S, Schultz DM. Systematic review of effectiveness and complications of adhesiolysis in the management of chronic spinal pain: An update. *Pain Physician* 2007; 10:129-146.
  107. Abdi S, Datta S, Trescot AM, Schultz DM, Adlaka R, Atluri SL, Smith HS, Manchikanti L. Epidural steroids in the management of chronic spinal pain: A systematic review. *Pain Physician* 2007; 10:185-212.
  108. Chopra P, Smith HS, Deer TR, Bowman RC. Role of adhesiolysis in the management of chronic spinal pain: A systematic review of effectiveness and complications. *Pain Physician* 2005; 8:87-100.
  109. Abdi S, Datta S, Lucas LF. Role of epidural steroids in the management of chronic spinal pain: A systematic review of effectiveness and complications. *Pain Physician* 2005; 8:127-143.
  110. Manchikanti L, Rivera J, Pampati V, Damron KS, McManus CD, Brandon DE, Wilson SR. One day lumbar epidural adhesiolysis and hypertonic saline neurolysis in treatment of chronic low back pain: A randomized double blind trial. *Pain Physician*. 2004; 7:177-186.
  111. Heavner JE, Racz GB, Raj P. Percutaneous epidural neuroplasty. Prospective evaluation of 0.9% NaCl versus 10% NaCl with or without hyaluronidase. *Reg Anesth Pain Med* 1999; 24:202-207.
  112. Veihelmann A, Devens C, Trouiller H, Birkenmaier C, Gerdsmeyer L, Refior HJ. Epidural neuroplasty versus physiotherapy to relieve pain in patients with sciatica: A prospective randomized blinded clinical trial. *J Orthop Science* 2006; 11:365-369.
  113. Manchikanti L, Pampati V, Fellows B, Rivera JJ, Beyer CD, Damron KS. Role of one day epidural adhesiolysis in management of chronic low back pain: A randomized clinical trial. *Pain Physician* 2001; 4:153-166.
  114. Manchikanti L, Pakanati R, Bakhit CE, Pampati V. Role of adhesiolysis and hypertonic saline neurolysis in management of low back pain. Evaluation of modification of Racz protocol. *Pain Digest* 1999; 9:91-96.
  115. Gerdsmeyer L, Lampe R, Veihelmann A, Burgkart R, Gobel M, Gollwitzer H, Wagner K. Chronic radiculopathy. Use of minimally invasive percutaneous epidural neurolysis according to Racz. *Der Schmerz* 2005; 19:285-295.
  116. Manchikanti L, Pampati V, Bakhit CE, Pakanati RR. Non-endoscopic and endoscopic adhesiolysis in post lumbar laminectomy syndrome. A one-year outcome study and cost effective analysis. *Pain Physician* 1999; 2:52-58.
  117. Kumar K, Taylor RS, Jacques L, Eldabe S, Meglio M, Molet J, Thomson S, O'Callaghan J, Eisenberg E, Milbouw G, Buchser E, Fortini G, Richardson J, North RB. The effects of spinal cord stimulation in neuropathic pain are sustained: A 24-month follow-up of the prospective randomized controlled multicenter trial of the effectiveness of spinal cord stimulation. *Neurosurgery* 2008; 63:762-770.
  118. North RB, Kidd DH, Farrokhi F, Piantadosi SA. Spinal cord stimulation versus repeated lumbosacral spine surgery for chronic pain: A randomized, controlled trial. *Neurosurgery* 2005; 56:98-107.
  119. Van Buyten JP, Van Zundert J, Vueghs P, Vanduffel L. Efficacy of spinal cord stimulation: 10 years of experience in a pain centre in Belgium. *Eur J Pain* 2001; 5:299-307.
  120. De La Porte C, Van de Kelft E. Spinal cord stimulation in failed back surgery syndrome. *Pain* 1993; 52:55-61.
  121. Devulder J, De Laat M, Van Bastelaere M, Rolly G. Spinal cord stimulation: A valuable treatment for chronic failed back surgery patients. *J Pain Symptom Manage* 1997; 13:296-301.
  122. North RB, Ewend MG, Lawton MT, Kidd DH, Piantadosi S. Failed back surgery syndrome: 5-year follow-up after spinal cord stimulator implantation. *Neurosurgery* 1991; 28:692-699.
  123. Dario A. Treatment of failed back surgery syndrome. *Neuromodulation* 2001; 4:105-110.
  124. De La Porte C, Siegfried J. Lumbosacral spinal fibrosis (spinal arachnoiditis). Its diagnosis and treatment by spinal cord stimulation. *Spine* 1983; 8:593-603.
  125. Burchiel KJ, Anderson VC, Brown FD, Fessler RG, Friedman WA, Pelofsky S, Weiner RL, Oakley J, Shatin D. Prospective, multicenter study of spinal cord stimulation for relief of chronic back and extremity pain. *Spine* 1996; 21:2786-2794.
  126. Ohnmeiss DD, Rashbaum RF, Bogdanffy GM. Prospective outcome evaluation of spinal cord stimulation in patients with intractable leg pain. *Spine* 1996; 21:1344-1350.
  127. Taylor RS, Taylor RJ, Van Buyten JP, Buchser E, North R, Bayliss S. The cost effectiveness of spinal cord stimulation in the treatment of pain: A systematic review of the literature. *J Pain Symptom Manage* 2004; 27:370-378.
  128. Bala MM, Riemsma RP, Nixon J, Kleijnen J. Systematic review of the (cost-) effective-

- tiveness of spinal cord stimulation for people with failed back surgery syndrome. *Clin J Pain* 2008; 24:757-758.
129. North RB, Kidd D, Shipley J, Taylor RS. Spinal cord stimulation versus reoperation for failed back surgery syndrome: A cost effectiveness and cost utility analysis based on a randomized, controlled trial. *Neurosurgery* 2007; 61:361-368.
  130. Kumar K, Malik S, Demeria D. Treatment of chronic pain with spinal cord stimulation versus alternative therapies: Cost-effectiveness analysis. *Neurosurgery* 2002; 51:106-115.
  131. Manca A, Kumar K, Taylor RS, Jacques L, Eldabe S, Meglio M, Molet J, Thomson S, O'Callaghan J, Eisenberg E, Milbouw G, Buchser E, Fortini G, Richardson J, Taylor RJ, Goeree R, Sculpher MJ. Quality of life, resource consumption and costs of spinal cord stimulation versus conventional medical management in neuropathic pain patients with failed back surgery syndrome (PROCESS trial). *Eur J Pain* 2008; 12:1047-1058.
  132. Yin W, Bogduk N. The nature of neck pain in a private pain clinic in the United States. *Pain Med* 2008; 9:196-203.
  133. Barnsley L, Lord SM, Wallis BJ, Bogduk N. The prevalence of chronic cervical zygapophyseal joint pain after whiplash. *Spine* 1995; 20:20-26.
  134. Lord SM, Barnsley L, Wallis BJ, Bogduk N. Chronic cervical zygapophysial joint pain with whiplash: A placebo-controlled prevalence study. *Spine* 1996; 21:1737-1745.
  135. Manchikanti L, Manchikanti K, Pampati V, Brandon D, Giordano J. The prevalence of facet joint-related chronic neck pain in postsurgical and non-postsurgical patients: A comparative evaluation. *Pain Pract* 2008; 8:5-10.
  136. Speldewinde G, Bashford G, Davidson I. Diagnostic cervical zygapophyseal joint blocks for chronic cervical pain. *Med J Aust* 2001; 174:174-176.
  137. Palit M, Schofferman J, Goldthwaite N, Reynolds J, Kerner M, Keaney D, Lawrence-Miyasaki L. Anterior discectomy and fusion for the management of neck pain. *Spine* 1999; 24:2224-2228.
  138. Bogduk N, Aprill C. On the nature of neck pain, discography and cervical zygapophysial joint blocks. *Pain* 1993; 54:213-217.
  139. Everett CR, Shah R, Sehgal N, McKenzie-Brown AM. A systematic review of diagnostic utility of selective nerve root blocks. *Pain Physician* 2005; 8:225-233.
  140. Manchikanti L, Schultz DM, Racz GB. Cervical transforaminal epidural injections. In: Manchikanti L, Singh V (eds) . *Interventional Techniques in Chronic Spinal Pain*. ASIPP Publishing, Paducah, KY, 2007; pp 455-478.
  141. Malhotra G, Abbasi A, Rhee M. Complications of transforaminal cervical epidural steroid injections. *Spine* 2009; 34:731-739.
  142. Lee JH, Lee JK, Seo BR, Moon SJ, Kim JH, Kim SH. Spinal cord injury produced by direct damage during cervical transforaminal epidural injection. *Reg Anesth Pain Med* 2008; 33:377-379.
  143. Scanlon GC, Moeller-Bertram T, Romanowsky SM, Wallace MS. Cervical transforaminal epidural steroid injections. More dangerous than we think? *Spine* 2007; 32:1249-1256.
  144. Windsor RE, Storm S, Sugar S, Nagula D. Cervical transforaminal injection: review of the literature, complications, and a suggested technique. *Pain Physician* 2003; 6:457-465.
  145. Furman MB, Giovanniello MT, O'Brien EM. Incidence of intravascular penetration in transforaminal cervical epidural steroid injections. *Spine* 2003; 28:21-25.
  146. Derby R, Lee S, Kim B, Chen Y, Seo KS. Complications following cervical epidural steroid injections by expert interventionalists in 2003. *Pain Physician* 2004; 7:445-449.
  147. Muro K, O'Shaughnessy B, Ganju A. Infarction of the cervical spinal cord following multilevel transforaminal epidural steroid injection: Case report and review of the literature. *J Spinal Cord Med* 2007; 30:385-388.
  148. Suresh S, Berman J, Connell DA. Cerebellar and brainstem infarction as a complication of CT-guided transforaminal cervical nerve root block. *Skeletal Radiol* 2007; 36:449-452.
  149. Bogduk N, Dreyfuss P, Baker R, Yin W, Landers M, Hammer M, Aprill C. Complications of spinal diagnostic and treatment procedures. *Pain Med* 2008; 9: S11-S34.
  150. Kaplan MS, Cunniff J, Cooke J, Collins JG. Intravascular uptake during fluoroscopically guided cervical interlaminar steroid injection at C6-7: A case report. *Arch Phys Med Rehabil* 2008; 89:553-558.
  151. Beckman WA, Mendez RJ, Paine GF, Mazzilli MA. Cerebellar herniation after cervical transforaminal epidural injection. *Reg Anesth Pain Med* 2006; 31:282-285.
  152. Huntoon MA. Cervical spine: Case presentation, complications, and their prevention. *Pain Med* 2008; 9:S35-S40.
  153. Ludwig MA, Burns SP. Spinal cord infarction following cervical transforaminal epidural injection: A case report. *Spine* 2005; 30:E266-E268.
  154. Castagnera L, Maurette P, Pointillart V, Vital JM, Erny P, Senegas J. Long term results of cervical epidural steroid injection with and without morphine in chronic cervical radicular pain. *Pain* 1994; 58:239-243.
  155. Stav A, Ovadia L, Sternberg A, Kaadan M, Weksler N. Cervical epidural steroid injection for cervicobrachialgia. *Acta Anaesthesiol Scand* 1993; 37:562-566.
  156. Pasqualucci A, Varrassi G, Braschi A, Peduto VA, Brunelli A, Marinangeli F, Gori F, Colò F, Paladini A, Mojoli F. Epidural local anesthetic plus corticosteroid for the treatment of cervical brachial radicular pain: Single injection versus continuous infusion. *Clin J Pain* 2007; 23:551-557.
  157. Rowlingson JC, Kirschenbaum LP. Epidural analgesic techniques in the management of cervical pain. *Anesth Analg* 1986; 65:938-942.
  158. Ferrante FM, Wilson SP, Iacobo C, Orav EJ, Rocco AG, Lipson S. Clinical classification as a predictor of therapeutic outcome after cervical epidural steroid injection. *Spine* 1993; 18:730-736.
  159. Grenier B, Castagnera L, Maurette P, Erny P, Senegas J. Chronic cervico-brachial neuralgia treated by cervical epidural injection of corticosteroids. Long-term results. *Ann Fr Anesth Reanim* 1995; 14:484-488.
  160. Proano FA, Morgan PJ, Hymes JA, Rosenblatt RM, Weiss JA. Cervical steroid epidural block for treatment of cervical herniated intervertebral discs. *Pain* 1990; 5:S87.
  161. Cicala RS, Thoni K, Angel JJ. Long-term results of cervical epidural steroid injections. *Clin J Pain* 1989; 5:143-145.
  162. Lord S, Barnsley L, Wallis B, McDonald G, Bogduk N. Percutaneous radio-frequency neurotomy for chronic cervical zygapophyseal-joint pain. *N Engl J Med* 1996; 335:1721-1726.
  163. Manchikanti L, Singh V, Falco FJ, Cash KA, Fellows B. Cervical medial branch blocks for chronic cervical facet joint pain: A randomized double-blind, controlled trial with one-year follow-up. *Spine* 2008; 33:1813-1820.
  164. Manchikanti L, Manchikanti K, Damron



- K, Pampati V. Effectiveness of cervical medial branch blocks in chronic neck pain: A prospective outcome study. *Pain Physician* 2004; 7:195-201.
165. Sapir DA, Gorup JM. Radiofrequency medial branch neurotomy in litigant and non-litigant patients with cervical whiplash. *Spine* 2001; 26:E268-E273.
166. Barnsley L. Percutaneous radiofrequency neurotomy for chronic neck pain: Outcomes in a series of consecutive patients. *Pain Med* 2005; 6:282-286.
167. McDonald G, Lord S, Bogduk N. Long-term follow-up of patients treated with cervical radiofrequency neurotomy for chronic spinal pain. *Neurosurgery* 1999; 45:61-67.
168. Govind J, King W, Bailey B, Bogduk N. Radiofrequency neurotomy for the treatment of third occipital headache. *J Neurol Neurosurg Psychiatry* 2003; 74:88-93.
169. Manchikanti L, Singh V, Pampati V, Beyer CD, Damron KS. Evaluation of the prevalence of facet joint pain in chronic thoracic pain. *Pain Physician* 2002; 5:354-359.
170. Glaser SE, Falco F. Paraplegia following a thoracolumbar transforaminal epidural steroid injection. *Pain Physician* 2005; 8:309-314.
171. Manchikanti L, Singh V, Falco FJE, Cash KA, Pampati V. Effectiveness of thoracic medial branch blocks in managing chronic pain: A preliminary report of a randomized, double-blind controlled trial: Clinical Trial NCT00355706. *Pain Physician* 2008; 11:491-504.
172. Manchikanti L, Manchikanti KN, Manchukonda R, Pampati V, Cash KA. Evaluation of therapeutic thoracic medial branch block effectiveness in chronic thoracic pain: A prospective outcome study with minimum 1-year follow up. *Pain Physician* 2006; 9:97-105.
173. Mikhail GR, Sweet LC, Mellinger RC. Parenteral long-acting corticosteroid effect on hypothalamic pituitary adrenal function. *Ann Allergy* 1973; 31:337-343.
174. Schimmer BP, Parker KL. Adrenocorticotropic hormone; adrenocortical steroids and their synthetic analogs; inhibitors of the synthesis and actions of adrenocortical hormones. In: Hardman JG, Limbird LE (eds). *Goodman & Gilman, The Pharmacological Basis of Therapeutics*, Tenth Edition. McGraw-Hill, New York, 2001; pp 1649-1679.
175. McEvoy GK, Snow EK, Miller J, Kester L, Welsh OH. *AHFS Drug Information* 2009. American Society of Health System Pharmacists, Bethesda, 2009.
176. Boonen S, Van Distel G, Westhovens R, Dequeker J. Steroid myopathy induced by epidural triamcinolone injection. *Brit J Rheumatol* 1995; 34:385-386.
177. Maillefert JF, Aho S, Huguenin MC, Chataud C, Peere T, Marquignon MF, Lucas B, Tavernier C. Systemic effects of epidural dexamethasone injections. *Revue du Rhumatisme* 1995; 62:429-432.
178. Ward A, Watson J, Wood P, Dunne C, Kerr D. Glucocorticoid epidural for sciatica: Metabolic and endocrine sequelae. *Rheumatology* 2002; 41:68-71.
179. Weissman DE, Dufer D, Vogel V, Abeloff MD. Corticosteroid toxicity in neuro-oncology patients. *J Neurooncol* 1987; 5:125-128.
180. Delaney TJ, Rowlingson JC, Carron H, Butler A. Epidural steroid effects on nerves and meninges. *Anesth Analg* 1980; 58:610-614.
181. Mackinnon SE, Hudson AR, Gentili F, Kline DG, Hunter D. Peripheral nerve injection injury with steroid agents. *Plast Reconstr Surg* 1982; 69:482-489.
182. Chino N, Awad EA, Kottke FJ. Pathology of propylene glycol administered by perineural and intramuscular injection in rats. *Arch Phys Med Rehab* 1974; 55:33-38.
183. Benzon HT, Gissen AJ, Strichartz GR, Avram MJ, Covino BG. The effect of polyethylene glycol on mammalian nerve impulses. *Anesth Analg* 1987; 66:553-559.
184. Abram SE, Marsala M, Yaksh TL. Analgesic and neurotoxic effects of intrathecal corticosteroids in rats. *Anesthesiology* 1994; 81:1198-1205.
185. Latham JM, Fraser RD, Moore RJ, Blumbergs PC, Bogduk N. The pathologic effects of intrathecal betamethasone. *Spine* 1997; 22:1558-1562.
186. Robustelli della Cuna FS, Mella M, Magistrali G, Ricci M, Losurdo A, Goglio AM. Stability and compatibility of methylprednisolone acetate and ropivacaine hydrochloride in polypropylene syringes for epidural administration. *Am J Health Syst Pharm* 2001; 58:1753-1756.
187. Swai EA, Rosen M. An attempt to develop a model to study the effects of intrathecal steroids. *Eur J Anaesthesiol* 1986; 3:127-136.
188. Dunbar SA, Manikantan P, Philip J. Epidural infusion pressure in degenerative spinal disease before and after epidural steroid therapy. *Anesth Analg* 2002; 94:417-420.
189. Slucky AV, Sacks MS, Pallares VS, Malinin TI, Eismont FJ. Effects of epidural steroids on lumbar dura material properties. *J Spin Disord* 1999; 12:331-340.
190. Stanczak J, Blankenbaker DG, De Smet AA, Fine J. Efficacy of epidural injections of Kenalog and Celestone in the treatment of lower back pain. *AJR Am J Roentgenol* 2003; 181:1255-1258.
191. Noe CE, Haynsworth RF Jr. Comparison of epidural depo-medrol vs. aqueous betamethasone in patients with low back pain. *Pain Pract* 2003; 3:222-225.
192. Benyamin RM, Vallejo R, Kramer J, Rafeyan. Corticosteroid induced psychosis in the pain management setting. *Pain Physician* 2008; 11:917-920.
193. Manchikanti L. Pharmacology of neuraxial steroids. In: Manchikanti L, Singh V (eds). *Interventional Techniques in Chronic Spinal Pain*. ASIPP Publishing, Paducah, KY, 2007; pp 167-184.
194. Tiso RL, Cutler T, Catania JA, Whalen K. Adverse central nervous system sequelae after selective transforaminal block: The role of corticosteroids. *Spine J* 2004; 4:468-474.
195. Benzon HT, Chew TL, McCarthy RJ, Benzon HA, Walega DR. Comparison of the particle sizes of different steroids and the effect of dilution. *Anesthesiology* 2007; 106:331-338.
196. Derby R, Lee SH, Date ES, Lee JH, Lee CH. Size and aggregation of corticosteroids used for epidural injections. *Pain Med* 2008; 9:227-234.
197. Huntoon MA. Complications associated with chronic steroid use. In: Neal JM, Rathmell JP (eds). *Complications in Regional Anesthesia & Pain Medicine*. Saunders: Philadelphia, PA, 2007; pp 331-339.
198. Nelson D. Dangers from methylprednisolone acetate therapy by intraspinal injection. *Arch Neurol* 1988; 45:804-806.
199. Hollander JL, Brown EM Jr, Jessar RA, Brown CY. Hydrocortisone and cortisone injected into arthritic joints; comparative effects of and use of hydrocortisone as a local antiarthritic agent. *J Am Med Assoc* 1951; 147:1629-1635.
200. Robecchi A, Capra R. L'idrocortisone (composto F). Prime esperienze cliniche in campo reumatologico. *Minerva Med* 1952; 98:1259-1263.
201. Lievre JA, Bloch-Michel H, Pean G, Uro J. L'hydrocortisone en injection locale. *Rev Rhum* 1953; 20:310-311.
202. Cappio M. Il trattamento idrocortisonico per via epidurale sacrale delle lombosciatalgie. *Reumatismo* 1957; 9:60-70.

203. Goebert HW, Jallo SJ, Gardner WJ, Was-muth CE. Painful radiculopathy treated with epidural injections of procaine and hydrocortisone acetate results in 113 patients. *Anesth Analg* 1961; 140:130-134.
204. Bogduk N, Christophidis N, Cherry D. Epidural Use of Steroids in the Management of Back Pain. Report of the Working Party on Epidural Use of Steroids in the Management of Back Pain. National Health and Medical Research Council: Canberra, Commonwealth of Australia; 1994, pp 1-76.
205. McClain RF, Kapural L, Mekhail NA. Epidural steroid therapy for back and leg pain: Mechanisms of action and efficacy. *Spine J* 2005; 5:191-201.
206. Manchikanti L. Role of neuraxial steroids in interventional pain management. *Pain Physician* 2002; 5:182-199.
207. Fowler RJ, Blackwell GJ. Anti-inflammatory steroid induced biosynthesis of a phospholipase A2 inhibitor which prevents prostaglandin generation. *Nature* 1979; 278:456-459.
208. Devor M, Govrin-Lippmann R, Raber P. Corticosteroids suppress ectopic neural discharges originating in experimental neuromas. *Pain* 1985; 22:127-137.
209. Hua SY, Chen YZ. Membrane receptor mediated electrophysiological effects of glucocorticoid on mammalian neurons. *Endocrinology* 1989; 124:687-691.
210. Johansson A, Hao J, Sjolund B. Local corticosteroid application blocks transmission in normal nociceptor C-fibers. *Acta Anaesthesiol Scand* 1990; 34:335-338.
211. Faber LE, Wakim NG, Duhning JL. Evolving concepts in the mechanism of steroid action: Current developments. *Am J Obstet Gynecol* 1987; 156:1449-1458.
212. Olmarker K, Byrod G, Cornefjord M, Nordborg C, Rydevik B. Effects of methylprednisolone on nucleus pulposus induced nerve root injury. *Spine* 1994; 19:1803-1808.
213. Nicol GD, Klingberg DK, Vasko MR. Prostaglandin E2 enhances calcium conductance and stimulates release of substance P in avian sensory neurons. *J Neurosci* 1992; 12:1917-1927.
214. Coderre T. Contribution of protein kinase C to central sensitization and persistent pain following tissue injury. *Neurosci Lett* 1992; 140:181-184.
215. Hayashi N, Weinstein JN, Meller ST, Lee HM, Spratt KF, Gebhart GF. The effect of epidural injection of betamethasone or bupivacaine in a rat model of lumbar radiculopathy. *Spine* 1998; 23:877-885.
216. Lee HM, Weinstein JN, Meller ST, Hayashi N, Spratt KF, Gebhart GF. The role of steroids and their effects on phospholipase A2. An animal model of radiculopathy. *Spine* 1998; 23:1191-1196.
217. Lundin A, Magnuson A, Axelsson K, Nilsson O, Samuelsson L. Corticosteroids preoperatively diminishes damage to the C-fibers in microscopic lumbar disc surgery. *Spine* 2005; 30:2362-2367.
218. Byrod G, Otani K, Brisby H, Rydevik B, Olmarker K. Methylprednisolone reduces the early vascular permeability increase in spinal nerve roots induced by epidural nucleus pulposus application. *J Orthop Res* 2000; 18:983-987.
219. Minamide A, Tamaki T, Hashizume H, Yoshida M, Kawakami M, Hayashi N. Effects of steroids and lipopolysaccharide on spontaneous resorption of herniated intervertebral discs. An experience study in the rabbit. *Spine* 1998; 23:870-876.
220. Kingery WS, Castellote JM, Maze M. Methylprednisolone prevents the development of autotomy and neuropathic edema in rats, but has no effect on nociceptive thresholds. *Pain* 1999; 80:555-566.
221. Johansson A, Bennett GJ. Effect of local methylprednisolone on pain in a nerve injury model. A pilot study. *Reg Anesth* 1997; 22:59-65.
222. Leypold BG, Flanders AE, Schwartz ED, Burns AS. The impact of methylprednisolone on lesion severity following spinal cord injury. *Spine* 2007; 32:373-378.
223. Somayaji HS, Saifuddin A, Casey ATH, Briggs TWR. Spinal cord infarction following therapeutic computed tomography-guided left L2 nerve root injection. *Spine* 2005; 30:E106-E108.
224. Brouwers PJAM, Kottnik EJBL, Simon MAM, Prevo RL. A cervical anterior spinal artery syndrome after diagnostic blockade of the right C6- nerve root. *Pain* 2001; 91:397-399.
225. Houten JK, Errico TJ. Paraplegia after lumbosacral nerve root block: Report of three cases. *Spine J* 2002; 2:70-75.
226. Baker R, Dreyfuss P, Mercer S, Bogduk N. Cervical transforaminal injection of corticosteroids into a radicular artery: A possible mechanism for spinal cord injury. *Pain* 2003; 103:211-215.
227. McMillan MR, Crompton C. Cortical blindness and neurological injury complicating cervical transforaminal injection for cervical radiculopathy. *Anesthesiology* 2003; 99:509-511.
228. Rozin L, Rozin R, Koehler SA, Shakir A, Latham S, Barmada M, Dominick J, Wecht CH. Death from transforaminal epidural steroid nerve root block (C7) due to perforation of the left vertebral artery. *Am J Forensic Med Pathol* 2003; 24:351-355.
229. Huntoon MC, Martin DP. Paralysis after transforaminal epidural injection and previous spinal surgery. *Reg Anesth Pain Med* 2004; 29:494-495.
230. Karasek M, Bogduk N. Temporary neurologic deficit after cervical transforaminal injection of local anesthetic. *Pain Med* 2004; 5:202-205.
231. Rathmell JP, April C, Bogduk N. Cervical transforaminal injection of steroids. *Anesthesiology* 2004; 100:1595-1600.
232. Rathmell JP, Benzon HT. Transforaminal injection of steroid: Should we continue? (editorial). *Reg Anesth Pain Med* 2004; 29:397-399.
233. Huntoon MA. Anatomy of the cervical intervertebral foramina: Vulnerable arteries and ischemic neurologic injuries after transforaminal epidural injections. *Pain* 2005; 117:104-111.
234. Hoeft MA, Rathmell JP, Monsey RD, Fonda BJ. Cervical transforaminal injection and the radicular artery: Variation in anatomical location within the cervical intervertebral foramina. *Reg Anesth Pain Med* 2006; 31:270-274.
235. Jacobs A, Pullan PT, Potter JM, Shenfield GM. Adrenal suppression following extradural steroids. *Anaesthesia* 1983; 38:953-956.
236. Kay JK, Findling JW, Raff H. Epidural triamcinolone suppresses the pituitary adrenal axis in human subjects. *Anesth Analg* 1994; 79:501-505.
237. Hsu D, Fu P, Gyermek L, Tan C. Comparison of plasma cortisol and ACTH profile after a single lumbar epidural dose of triamcinolone 40 mg, 80 mg respectively in low back pain patients. *Anesth Analg* 1996; 82:S191.