

A CASE REPORT

METHICILLIN-RESISTANT STAPHYLOCOCCUS AUREUS EPIDURAL ABSCESS AFTER TRANSFORAMINAL EPIDURAL STEROID INJECTION

Abdallah Kabbara, MD, Samuel K Rosenberg, MD, and Carlos Untal, MD

Transforaminal epidural steroid injections are provided frequently for patients with lumbar radiculopathy, having demonstrated efficacy and safety. We present a patient who developed methicillin-resistant *Staphylococcus aureus* epidural ab-

cess 11 days after a transforaminal epidural steroid injection. The abscess required surgical intervention and intravenous vancomycin. Fortunately, the patient made a full recovery, and continues to do well one year later. The incidence, etiology and treat-

ment of epidural injection-related infections are reviewed.

Keywords: Infection, epidural abscess, transforaminal epidural, methicillin-resistant *staphylococcus aureus*

Transforaminal epidural injections in the lumbar region have been proposed as a target-specific modality of treatment for the management of lumbar nerve root pain (1-3). An evidence-based evaluation of transforaminal epidural injections (3, 4) showed positive short-term and long-term effectiveness of transforaminal epidural steroids in managing nerve root pain according to a number of randomized evaluations (5-12) and numerous non-randomized evaluations (3, 4). The most common and worrisome complications of transforaminal epidural steroid injections in the lumbar spine are related to dural puncture, infection, and steroids (3, 4, 13-18). In a large survey examining the reports of adverse reactions associated with epidural steroid injections, Abram and O'Connor (19) reported two cases of epidural abscess and two cases of meningitis. However, no such reviews exist for transforaminal epidural steroid injections. Multiple authors describing transforaminal epidurals have reported no incidences of infection (1-18, 20).

Strict adherence to aseptic technique is critical to avoid infection with transfo-

raminal epidural steroid injections. Epidural steroids suppress the adrenal system for two to six weeks and may unmask a systemic infection or allow it to disseminate. Development of any type of infection, specifically epidural abscess, requires rapid investigation and appropriate treatment to minimize the risk of permanent neurologic sequela. Infection following epidural steroid injections with development of an epidural abscess is associated with increased back pain, nerve root pain, weakness and paralysis, fever, and leukocytosis. The symptoms may progress slowly, ranging from weeks to months.

We present a patient developing methicillin-resistant *staphylococcus aureus* epidural abscess 11 days after a transforaminal epidural steroid injection.

CASE DESCRIPTION

A 44 year-old man with a history of previous lumbar laminectomy at L4-L5 presented with intractable back and radiculopathic pain, for which transforaminal epidural steroid injections were performed under fluoroscopy, over the course of 8 weeks. One transforaminal injection was done at the L4 level and 2 injections at the L5 level. The injections were done in the operating room with aseptic technique, prepping with 10 % aqueous povidone iodine and using sterile drapes, mask and gloves. The first two injections provided excellent pain relief for two to three weeks, with each injection. A day after the third epidural injection, he noted worsening of back pain, without leg pain.

He called the office 6 days later, did not report fever or chill, but continued to have back pain. Hydrocodone/acetaminophen were prescribed for pain. Four days later he went to see his family physician, who in turn called the pain service resident after finding a fever of 102 °F, with redness and swelling at the epidural injection site. The patient was immediately transferred to the hospital where an emergency MRI of the lumbar spine identified the previous laminectomy and revealed a paraspinous abscess at the L4-L5 level, with extension to the epidural space (Figs. 1 and 2).

The patient underwent emergency debridement of the abscess and the infectious disease service was consulted; cefazolin was administered until cultures and sensitivities revealed methicillin-resistant *Staphylococcus aureus*. The organism was sensitive to vancomycin and one day after starting vancomycin, the infection defervesced. Unfortunately, the infection did not clear, and subsequent surgery was required to fully drain the infection. The patient was discharged home with a peripherally inserted central catheter line and vancomycin was continued for six weeks. Postoperative pain control was treated with hydrocodone/acetaminophen as needed.

The patient made an uneventful recovery and had no neurologic sequelae. He did not have additional epidural steroid injections. He was doing well at the one-year follow-up, and the MRI, except for demonstrating previous surgery, was normal.

From Cleveland Veterans Administration Medical Center, Cleveland, Ohio, University Hospitals of Cleveland, Cleveland, Ohio, and University Anesthesiologists Inc, Cleveland, Ohio. Address Correspondence: Abdallah Kabbara, MD, Cleveland Veterans Administration Medical Center, Cleveland, Ohio 44106

E-mail: draikabbara@yahoo.com

Support: There was no external funding in preparation of this manuscript

Conflict of Interest: None

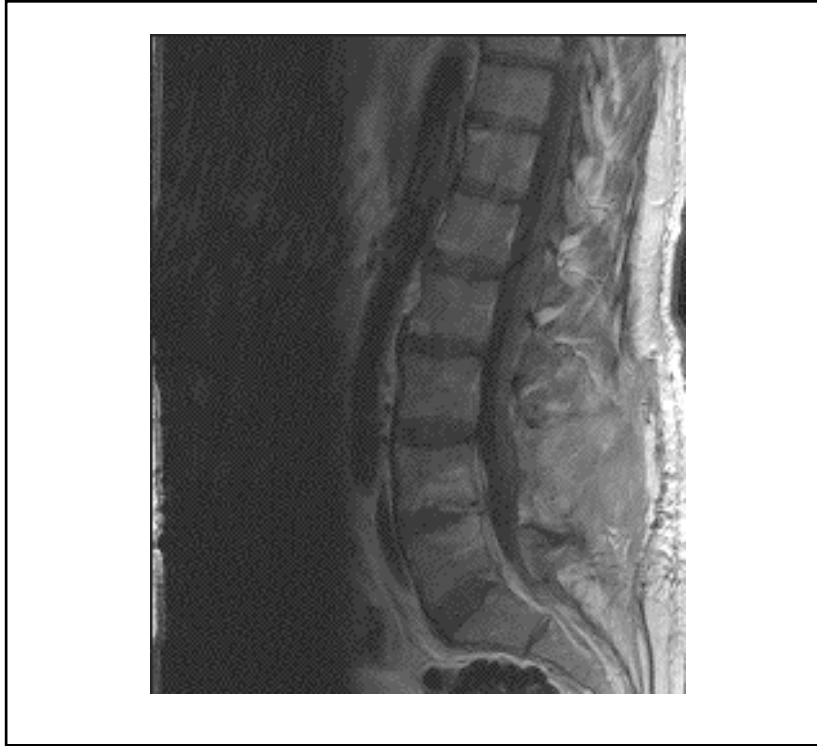

Fig. 1. Sagittal T1 weighted post gadolinium image demonstrating enhancement in the anterior epidural space, and increased signal posteriorly at the L4/5 and L5/S1 discs. A previous laminectomy is evident, and there is enhancement in the lumbar soft tissues as well.

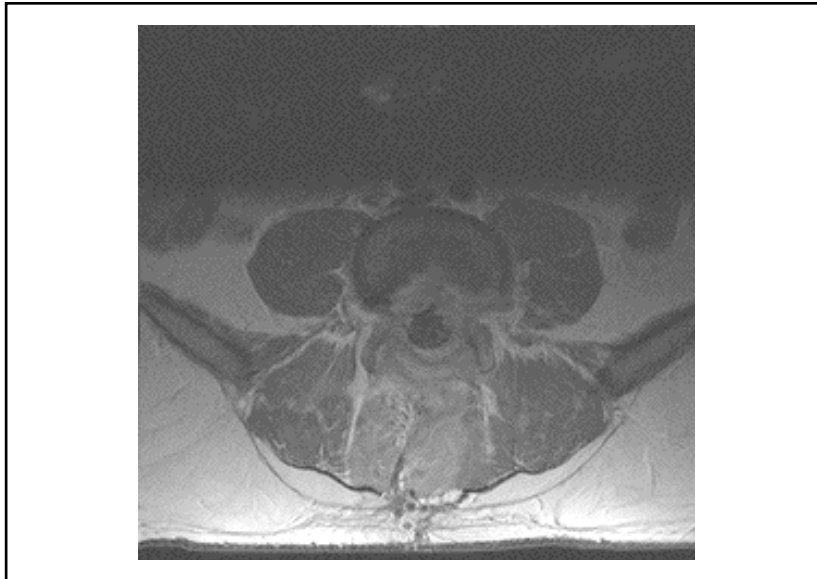


Fig. 2. Axial T1 weighted post gadolinium image demonstrates postoperative changes and a laminectomy defect (from the previous surgery) and enhancing soft tissue, which surrounds and flattens the thecal sac. There is enhancing soft tissue in the paraspinal muscle tissue, consistent with infection and abscess.

DISCUSSION

We present an unusual complication of a commonly performed procedure done for lumbar radiculopathy and spinal stenosis. There did not appear to be a break in sterile technique in this case, and it is assumed that the source of infection was inadequate bactericidal effect of the povidone-iodine preparation. The site of infection, with apparent spread from paraspinal muscle to the epidural space, and the identification of the organism as *Staphylococcus aureus* confirm the impression that this infection was due to introduction of skin flora during the epidural injection. However, it remains unclear if the infection was nosocomial or due to the possibility that the patient's skin was colonized with MRSA. The patient did not have any risk factors for nosocomial infections, other than the three epidural injections. However, he worked cleaning sewers and septic systems, which may have put him at risk for colonization.

The incidence of infection after spinal or epidural procedures varies. In a Swedish Patient Injury Claims Department review, the incidence of epidural abscess was reported to be 1 in 60,000 cases after epidural anesthesia. There were 1 in 40,000 cases of meningitis after spinal anesthesia (21). Other studies have reported an incidence of 0.2-2.8 per 10,000 cases of epidural abscesses after spinal interventions (22).

The most commonly detected organism on the human skin is *Staphylococcus epidermidis* (65-69%), whereas *Staphylococcus aureus* is present in only 1-2% of individuals, but is the most common pathogen identified in epidural abscesses (22, 23). Other organisms include *E. coli*, other gram-negative bacteria and anaerobic streptococci.

Staphylococcus aureus is a common human pathogen that frequently colonizes neonates and adults at different sites, such as the nasopharynx, occasionally the skin, and rarely the vagina (24). This gram-positive organism has developed resistance to methicillin in some cases, hence the term MRSA (methicillin resistant *Staphylococcus aureus*). In addition, povidone-iodine is not as effective in preventing infections with MRSA (25).

MRSA is commonly linked to nosocomial infections. In our case, the patient did not have any risk factors for nosocomial infections, although his occupation

may have put him at risk for colonization. Other populations at higher risk for carrier states include physicians, nurses, and other hospital workers, diabetics and patients on dialysis, immunocompromised patients, including those with HIV and intravenous drug abusers. Infection after colonization requires penetration of skin or mucosa (24-26).

Staphylococcus aureus infections after surgery typically present with fever, prostration, edema, erythema, and pain around the point of entry. Serious complications of untreated infection include septicemia, endocarditis, osteomyelitis, meningitis and pneumonia. In about a third of cases of septicemia, no apparent foci of infection can be identified (24).

Povidone iodine is a commonly used antiseptic solution for interventional procedures, including surgery. It also remains the most popular antiseptic agent used to prevent catheter-related infections. However, a recent meta-analysis showed that the use of chlorhexidine compared to povidone iodine reduced the incidence of bloodstream infections by 49%, in patients undergoing central line placements. In addition, it is estimated that for every 1000 catheter sites disinfected with chlorhexidine gluconate rather than povidone-iodine, 71 catheter colonizations, and 11 blood-stream infections can be prevented (27).

A recent comparison of povidone iodine and iodophor in isopropyl alcohol (Duraprep®, 3M, St. Paul, MN) (28) used for skin disinfections prior to epidural catheter insertion in parturient showed a marked decrease in the number of positive skin cultures after disinfections with Duraprep (30% vs. 3%), as well as a decrease in bacterial regrowth and colonization of epidural catheters. Alcohol speeds drying and organism killing, and the preparation forms a water-insoluble film that may resist contamination.

In another study, Birnbach et al (29) demonstrated that the frequency of bacterial contamination in previously open bottles of povidone iodine was 40% at the inside of the bottle cap, but none was found in unopened bottles. Also, the antibacterial activity of previously opened bottles of povidone appeared to be decreased. The loss of antimicrobial activity, seen in previous studies (29, 30), may be due to partitioning of the iodine between the micelle structure of the surface-active

agent and the water phase.

Chlorhexidine in alcohol was compared to aqueous povidone iodine for cutaneous antisepsis before epidural catheter insertion in 96 children (25). Epidural catheters were kept in place for an average of 50 hours. Those patients who were prepped with chlorhexidine/alcohol were one sixth as likely to be colonized with microorganisms than the povidone group. In this study, coagulase-negative staphylococci were the only microorganisms recovered.

The superior results of alcoholic chlorhexidine may be explained by its more potent bactericidal activity and its high permeability into hair follicles. In addition, its antimicrobial activity persists for hours after topical application, and in contrast to povidone, is not neutralized by proteinaceous solutions, and it does not induce allergic reactions. Bacterial resistance to chlorhexidine is rare (25).

Bacterial contamination can occur even following strict aseptic guidelines. Readler et al (31) reported that bacterial contamination occurred in 18% of needles after epidural or subarachnoid block, even after strict antisepsis was followed.

The addition of alcohol to chlorhexidine has been shown to improve its antibacterial activity against MRSA. Sakuragi et al (23) compared 10% povidone, 0.5% chlorhexidine gluconate and 0.5% chlorhexidine gluconate in 80% ethanol, against four strains of methicillin-resistant, and two strains of methicillin-susceptible *Staphylococcus aureus*. The pathogens were exposed to each disinfectant for 15, 30, 60, 120, and 240 seconds. All six strains grew colonies after 60 seconds in the povidone group, five of six grew colonies after 60 seconds of exposure in the chlorhexidine group, and no bacteria grew after 15 seconds of exposure to the 0.5% chlorhexidine ethanol preparation.

This case illustrates the need for prompt recognition of infection after a transforaminal epidural steroid injection, even one performed in a sterile operating room with good sterile technique. In fact, there did not appear to be a break in sterile technique in this case, although it is assumed that the source of infection was inadequate bactericidal effect of the povidone-iodine preparation. In any case, prompt diagnosis, surgical drainage and the correct antibiotic management were necessary to completely cure the infection.

Although the incidence of spinal in-

fection following injections is rare (less than 1 in 10,000 injections), the physician should be constantly alert to that possibility. A busy practice may see several thousand patients per year, so the chance of seeing a patient with a spinal infection may not be so small. Indeed, one must also be alert to the possibility that a new patient may present with an undiagnosed infection that can manifest shortly after an injection. The incidence of spontaneous spinal infection is about 1 in 20,000 hospital admissions (32). In such cases, cultures will guide therapy and may provide a clue as to the origin of the infection. For example, gram-negative infections may result from hematogenous spread from the gastrointestinal or urinary tract. A *Streptococcus viridans* infection would suggest hematogenous spread from a dental abscess.

CONCLUSION

Skin flora are the most common organisms implicated in spinal infections after spinal injections. Povidone iodine may not be as effective as other antiseptic agents in preventing this complication. Chlorhexidine gluconate/alcohol and iodophor/alcohol have been shown in several studies to be superior to povidone alone in preventing infections after interventional procedures. Full bactericidal effect requires that the preparations dry completely, which may take several minutes; the alcohol also must be allowed to dry fully to eliminate the risk of fire hazard. When back pain or fever develops following spinal injections, the physician should consider the possibility of spinal infection.

Author Affiliation:

Abdallah Kabbara, MD

Cleveland Veterans Administration
Medical Center
Cleveland, Ohio 44106
E-mail: draikabbara@yahoo.com

Samuel K. Rosenberg, MD

University Anesthesiologists, Inc
11100 Euclid Avenue
Cleveland, Ohio 44106
E-mail: sammyrosenberg@yahoo.com

Carlos Untal, MD

Resident in anesthesiology
University Hospitals of Cleveland
Cleveland, Ohio 44106
E-mail: carlos.untal@uhhs.com

REFERENCES

1. Rosenberg SK, Grabinsky A, Kooser C et al. Effectiveness of transforaminal epidural steroid injections in low back pain: a one-year experience. *Pain Physician* 2002; 5: 432-438.
2. Lutz GE, Vad VB, Wisneski RJ. Fluoroscopic transforaminal lumbar epidural steroids: An outcome study. *Arch Phys Med Rehab* 1998; 79:1362-1366.
3. Manchikanti L, Staats PS, Singh V et al. Evidence-based practice guidelines for interventional techniques in the management of chronic spinal pain. *Pain Physician* 2003; 6:3-80.
4. Boswell MV, Hansen HC, Trescot AM et al. Epidural steroids in the management of chronic spinal pain and radiculopathy. *Pain Physician* 2003; 6:319-334.
5. Silva J, Costa AO, Simoes MT et al. Management of radicular pain from lumbar herniated disc using betamethasone epidural injection. *Revista Brasileira de Ortopedia* 1999; 34:165-168.
6. Riew KD, Yin Y, Gilula L et al. The effect of nerve-root injections on the need for operative treatment of lumbar radicular pain. *J Bone Joint Surg Am*, 2000; 82:1589-1593.
7. Karppinen J, Malmivaara A, Kurunlahti M et al. Periradicular infiltration for sciatica. *Spine* 2001; 26:1059-1067.
8. Karppinen J, Ohinmaa A, Malmivaara A et al. Cost effectiveness of periradicular infiltration for sciatica. *Spine* 2001; 26:2587-2595.
9. Vad V, Bhat AL, Lutz GE et al. Transforaminal epidural steroid injections in lumbosacral radiculopathy: A prospective randomized study. *Spine* 2002; 27:11-16.
10. Kolsi I, Delecrin J, Berthelot JM et al. Efficacy of nerve root versus interspinous injections of glucocorticoids in the treatment of disc-related sciatica. A pilot, prospective, randomized, double-blind study. *Joint Bone Spine*, 67, 113-118, 2000.
11. Thomas E, Cyteval C, Abiad L et al. Efficacy of transforaminal versus interspinous corticosteroid injection in discal radiculalgia - a prospective, randomised, double-blind study. *Clin Rheumatol* 2003; 22:299-304.
12. Kraemer J, Ludwig J, Bickert U et al. Lumbar epidural perineural injection: A new technique. *Eur Spine J* 1997; 6:357-361.
13. Manchikanti L. Transforaminal lumbar epidural steroid injections. *Pain Physician* 2000; 3:374-398.
14. Furman MB, O'Brien EM, Zgleszewski TM. Incidence of intravascular penetration in transforaminal lumbosacral epidural steroid injections. *Spine* 2000; 25:2628-2632.
15. Botwin KP, Gruber RD, Bouchlas CG et al. Complications of fluoroscopically guided transforaminal lumbar epidural injections. *Arch Phys Med Rehabil*, 2000; 81:1045-1050.
16. Houten JK, Errico TJ. Paraplegia after lumbosacral nerve root block: Report of three cases. *Spine J* 2002; 2:70-75.
17. Elias M. A rare cause of radiculopathy following transforaminal epidural steroid injection. *Pain Clinic* 1998; 11:159-160.
18. Stohr M, Mayer K. Nerve-root damage from local injections. *Dtsch Med Wochenschr* 1976; 101:1218-1220.
19. Abram SE, O'Connor TC. Complications associated with epidural steroid injections. *Reg Anesth* 1996; 21:149-162.
20. Manchikanti L, Pakanati RR, Pampati V. Comparison of three routes of epidural steroid injections in low back pain. *Pain Digest* 1999; 9:277-285.
21. Moen V, Irestedt L, Raf L. Review of claims from the patients insurance: Spinal anesthesia is not completely without risks. *Lakartidningen* 2000; 97:5769-5774.
22. Martin RJ, Yuan HA. Neurosurgical care of spinal epidural, subdural, and intramedullary abscesses and arachnoiditis. *Orthop Clin North Am* 1996; 27:125-136.
23. Sakuragi, T, Yanagisawa, K, Dan K. bactericidal activity of skin disinfectants on Methicillin-resistant *Staphylococcus aureus*. *Anesth Analg* 1995; 81:555-558.
24. Wladvogel FA. *Staphylococcus aureus* (Including *Staphylococcal Toxic Shock*). In Mandel GL, Bennett JE, Dolin R, (eds). *Mandell, Douglas, and Bennett's Principles and Practice of Infectious Diseases*. Philadelphia, Churchill Livingstone, 2000, pp 2069-2092.
25. Kinirons B, Olivier M, Lafendi L et al. Chlorhexidine versus Povidone Iodine in Preventing Colonization of Continuous Epidural Catheters in Children: A Randomized, Controlled Trial. *Anesthesiology* 2001; 94:239-244.
26. Olivier M, Pieroni L, Lawrence C, et al. Prospective, randomized trial of two antiseptic solutions for prevention of central venous or arterial catheter colonization and infection in intensive care unit patients. *Crit Care Med* 1996; 24:1818-1823.
27. Chaiyakunapruk N, Veenstra DL, Lipsky BL et al. Chlorhexidine compared with povidone-iodine solution for vascular catheter-site care: A meta-analysis. *Ann Intern Med* 2002; 136:792-801.
28. Birnbach DJ, Meadows, W, Stein DJ, et al. Comparison of povidone iodine and Dura-Prep, an iodophor-in-isopropyl alcohol solution, for skin disinfection prior to epidural catheter insertion in parturients. *Anesthesiology* 2003; 98:164-169.
29. Birnbach DJ, Stein DJ, Murray O et al. Povidone Iodine and skin disinfection before initiation of epidural anesthesia. *Anesthesiology* 1998; 88:668-672.
30. Craven DE, Moody B, Connolly MG et al. Pseudobacteremia caused by Povidone-iodine solution contaminated with *Pseudomonas cepacia*. *N Engl J Med* 1981; 305:621-623.
31. Readler C, Lass-Flörl C, Pühringer F et al. Bacterial contamination of needles used for spinal and epidural anaesthesia. *Br J Anaesth* 1999; 83:657-658.
32. Miller JR, Jubelt B. Bacterial Infections. In Rowland LP (ed). *Merritt's Neurology*, 10th ed. Lippincott Williams and Wilkins, Philadelphia, 2000, pp 103-126.