

Case Report

Pulsed Radiofrequency of Lumbar Dorsal Root Ganglia for Chronic Post-Amputation Stump Pain

Vidya Ramanavaru MD, Thomas T. Simopoulos MD

From: Department of Anesthesia, Critical Care, and Pain Medicine, Beth Israel Deaconess Medical Center, Harvard Medical School, Boston, MA

Address correspondence:
Thomas Simopoulos
Harvard Medical School
Department of Anesthesia & Critical Care
Beth Israel Deaconess Medical Center
Boston, MA 02115
E-mail: tsimopou@bidmc.harvard.edu

Disclaimer: There was no external funding in the preparation of this manuscript.

Conflict of interest: None.

Manuscript received: 01/30/2008
Revised manuscript received: 04/14/2008
Accepted for publication: 04/25/2008

Free full manuscript:
www.painphysicianjournal.com

Background: Chronic pain following limb amputations is now a recognized chronic pain syndrome usually described in a combination of phantom and stump pain. Both stump and phantom pain continue to be significant treatment challenges. If pharmacotherapy does not provide effective analgesia for stump pain, a clinician has interventional options that frequently give only transient benefit, or have a high chance of failure in the long run.

Methods: We selected 2 patients with primarily stump pain and difficulty tolerating the limb prosthesis. After a positive response to segmental nerve root blocks at L4 and L5, pulsed radiofrequency (PRF) was performed to the dorsal root ganglia (DRG).

Results: Both patients experienced 50% pain relief or better for 6 months. Each patient tolerated the prosthetic limb and could function at a higher level.

Conclusion: PRF treatment of the DRG at the L4 and L5 nerve root level may be a therapeutic option for patients with peripherally mediated intractable stump pain. A decrease in pain intensity and improved toleration of the limb prosthesis was appreciated in both patients.

Key words: Stump pain, dorsal root ganglia, pulsed radiofrequency

Pain Physician 2008; 11:4:561-566

Every year, nearly 185,000 persons undergo a limb amputation in the United States (1,2). Many of these individuals then go on to develop secondary pain syndromes such as phantom limb pain, stump pain, and back pain. The prevalence of post-amputation stump pain varies widely from 10% to 76%, depending on the study quoted (2-6). Such variability exists due to several reasons. First, the incidence of stump pain often changes in relation to the amount of time that

has elapsed since the amputation. Second, studies often do not make a clear distinction between stump pain and phantom pain. Third, even with clear definitions, it is often difficult for patients to be able to differentiate between the 2 types of pain (5,6). Nevertheless, stump pain afflicts many patients who have undergone limb amputation (7). Often, this secondary pain condition impairs their function and rehabilitation more than the amputation itself.

The etiology of stump pain can often be determined in clinical practice. Chronic stump pain may occur as a result of skin pathology, vascular insufficiency, infection, bone spurs, or neuromas (3,4,6). Frequently pain practitioners are faced with treating pain related to neuroma formation in the stump. Pharmaceutical agents consisting of a combination of antiepileptic, antidepressants, and analgesics are the first line of management (8). Very commonly in clinical practice however, even this multimodal approach may fail to bring satisfactory relief. Local injections into the stump neuroma commonly render short-term relief with risk of infection. Furthermore, patients who are considered for surgical neurectomy of the stump are at risk for poor wound healing and infection of the stump.

Pulsed radiofrequency (PRF) has gained popularity in recent years for the treatment of neuropathic pain because of its minimally destructive nature (9, 10). Continuous radiofrequency (CRF) which uses high frequency (500 kHz) electrical current to generate high tissue temperature (80 – 90°C) has long been used to treat non-malignant pain (11,12). CRF involves thermal coagulation of neural structures and has found more use in pain derived from somatic structures such as zygapophysial joints. Multiple authors have cautioned against the use of radiofrequency ablation for neuropathic pain because of the potential to cause dysesthesia, hypesthesias, deafferentation, and motor weakness (10,13).

On the other hand PRF has been accepted in clinical practice as a safer alternative to CRF particularly when applied for the treatment of neuropathic pain. PRF exposes a target neural structure to high frequency current (300 – 500 kHz) for very brief intervals of time (20 msec) followed by a silent period (480 msec) so as to allow for heat dissipation. Thus the electrode tip does not exceed 42°C. Electron microscopic evaluation of rabbit dorsal root ganglia (DRG) exposed to PRF at 42°C have revealed increased cytoplasmic vacuolization and enlarged endoplasmic reticulum compared to sham RF and control groups at 2 weeks post lesioning (14). PRF results in no cell or nuclear membrane disruption as seen in rabbit DRG exposed to CRF at 67°C.

While the analgesic mode of action of CRF is understood, PRF has not been explained. PRF is thought to induce changes in C-fos expression at the level of the dorsal horn that may then result in less central excitation from afferent C fibers (15). Despite shortcomings in the knowledge of cellular analgesic mech-

anisms, clinicians have reported successful treatment of various neuropathic pain states for nearly a decade (16). A recent case series and one retrospective evaluation have reported favorable results in patients with chronic post-surgical inguinal and thoracic pain by exposure of the corresponding DRG to PRF (17,18).

We present 2 cases in which we performed PRF more proximally at the level of the DRG to modulate pain at the distal stump site.

METHODS

In our case study we identified 2 patients with primarily stump pain caused by neuromas. We were careful to select patients without significant phantom limb pain. Both patients had localized pain over the stump described as burning, sharp, stabbing or electrical sensations. The 2 patients had received infiltration of the neuroma sites with 1% lidocaine rendering complete but temporary relief. In addition both patients struggled to use a prosthetic lower extremity because of pain and sensitivity of the stump.

The 2 patients were carefully screened by physical exam for location of stump neuromas. In both cases the major nerve(s) thought to contribute to the stump was the sciatic nerve, and possibly the saphenous nerve in the first case. The main sensory dorsal root ganglia contributing to these peripheral nerves are at the levels of L4 (common to saphenous and sciatic nerves), L5, S1, and S2 (sciatic nerve only) (19). The DRGs of L4 and L5 are accessible without surgical intervention, and therefore were chosen as targets.

Initial diagnostic selective nerve root blocks were performed under fluoroscopic guidance at the L4 and L5 levels. Non-ionic contrast (isovue-M300, Bracco Diagnostics, Princeton NJ) was initially injected to outline the contour of the spinal nerve and determine the maximum volume of local anesthetic that would avoid significant central epidural spread. The volume of local anesthetic injected ranged between 0.5 – 1.0 mL of 2% preservative-free lidocaine. A reduction in visual analog scale (VAS) of 50% or more was accepted as a positive response to the nerve blocks lasting for at least one hour. Within the analgesic time effectiveness of lidocaine, both patients were asked to wear their respective prosthesis and to ambulate. A better tolerated prosthetic, as reported by the patient, was also used to determine the effectiveness of the block.

The patients were then scheduled for PRF of the DRG at the levels of L4 and L5 vertebral levels. As with diagnostic blocks, informed consent was obtained.

The patient was placed in the prone position with the lumbosacral region prepped with iodophor solution and sterile towels. One to 2 milliliters of lidocaine 1% was used for local anesthesia of the skin prior to the placement of the RF needle. A C-arm fluoroscopy machine was used for visualization during the sterile placement of the RF electrode (22-G, 10 cm needle, with a 10 mm active tip, Radionics, Burlington, MA). On fluoroscopy, this corresponded to the dorsal-cranial quadrant of the intervertebral foramen on lateral view (Fig.1), and on antero-posterior view the tip was located midway into the pedicle column (Fig. 2). Once the electrode was appropriately positioned, the stylet was then replaced by the radiofrequency probe (SMK-TC 5, Radionics, Burlington, MA). The final physiologic testing for each patient treated was as follows: (1) Sensory stimulation (50 Hz) in the range was 0.33 – 0.47 volts that created paresthesia in the stump and/or amputated extremity (reported in the calf and foot). The impedances in the foramen ranged from 230 to 285. The radiofrequency generator (RFG-3C Plus; Radionics, Inc., Burlington, MA) was used for all lesions. Each patient was treated with PRF at 42°C for 120 seconds. No local anesthetic was injected around the nerve root prior to treatment.

CASE REPORT #1

A 39-year-old woman had a left below the knee amputation (BKA) 5 months prior to her initial visit at our clinic. She presented complaining of left side stump pain. Her BKA was the result of an ankle fracture four years prior which had required multiple surgeries and was then further complicated by osteomyelitis. Since her amputation, she had experienced constant, electric shock-like sensations shooting from her left stump up to her knee. On exam, there were no areas of redness, swelling, or other signs of infection at the stump site. However, she did have 2 specific points of severe tenderness along the posterolateral and anteromedial aspects of the stump with a positive Tinel's sign. She was treated for these neuromas with gabapentin, nortriptyline, and a transdermal lidocaine patch. She was also prescribed an opioid regimen (oxycodone/acetaminophen) after having first been evaluated by our pain psychologist. This medical regimen provided her with modest relief. Because of side-effects and lack of benefit, she ceased taking opioids. We offered her cryoablation at the neuroma sites, but she was apprehensive to try any interventions at the stump site given her history of osteomyelitis.

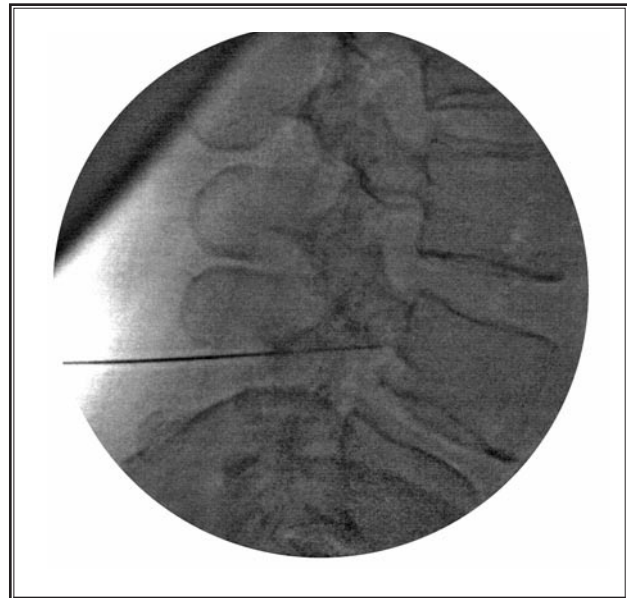


Fig. 1. Fluoroscopy showing dorsal-cranial quadrant of the intervertebral foramen on lateral view.

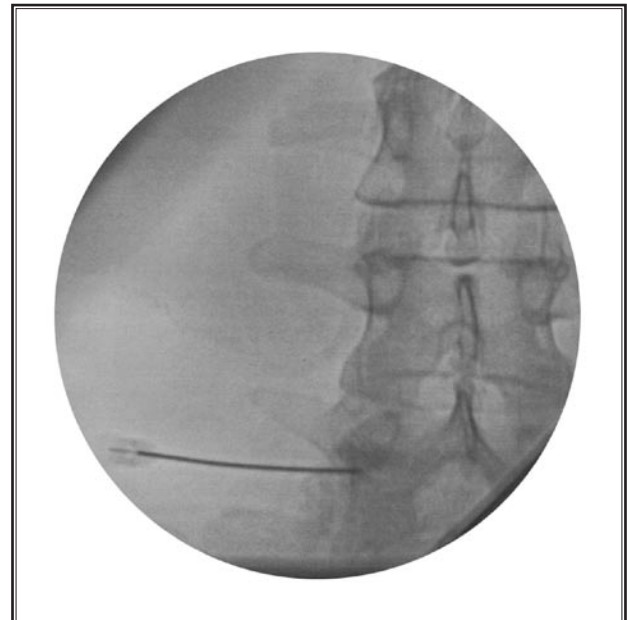


Fig. 2. Fluoroscopy showing dorsal-cranial quadrant of the intervertebral foramen. Antero-posterior view showed tip was located midway into the pedicle column.

After fulfilling our diagnostic criteria, the patient underwent PRF of the L4 and L5 DRG. Sensory stimulation at 50 Hz was felt in the stump and the amputated calf. She reported a 90% pain reduction for 2 months after the procedure. Her pain then returned, albeit to a much more tolerable level than before with an overall reduction of 50% at 6 months follow up. She was able to better tolerate her prosthetic limb and as a result had improved ambulation. She was then lost to follow up.

CASE REPORT # 2

A 48-year-old woman with a past medical history of chronic pain from spondylosis of the neck developed spontaneous gangrene of unclear etiology in her right lower extremity requiring a BKA. She presented to our clinic 3 months after her BKA complaining of constant, sharp, burning pain in her stump radiating up her thigh. Physical examination revealed significant sensitivity on the posterior aspect of the stump with a positive Tinel's sign. At this point, she was already taking gabapentin 2700mg daily, extended-release morphine 100mg BID, and hydromorphone 4mg 1 – 2 tabs per day as needed with an inadequate analgesic effect. We switched her from the morphine to methadone 30 TID and continued with the gabapentin and hydromorphone. She tried lidocaine patches, and citalopram without significant benefit. She was unable to tolerate her prosthetic limb despite trialing various types and participated in no rehabilitation.

She was successfully treated with PRF of the L4 and L5 DRG with a 70% reduction in VAS. She still has some residual, intermittent pain in the medial and posterior aspects of her stump. She stopped her hydromorphone but continued the methadone for chronic neck pain. Also, she was finally able to tolerate her prosthesis and had sustained treatment benefit for 6 months. She expired from other medical causes prior to her return for a repeat PRF treatment.

DISCUSSION

We report on 2 patients with intractable stump pain following BKA who were managed with PRF of the DRG corresponding to the peripheral nerves, mainly sciatic. Both patients responded very favorably for half a year. Interestingly, the patients benefited despite our inability to perform PRF of the S1 and S2 DRG. The reasons for this could be that most of the stump neuroma was influenced by the L4 and L5 lum-

bar DRG or that treatment of those segments is adequate to induce changes in the dorsal horn in a multi-segmental fashion in the conus medularis that lead to pain suppression. In any event, the reduction in pain intensity and time sensitive success are consistent with prior studies and case series (9,10,16-18).

Painful neuromas of an amputated limb represent a significant treatment challenge and there is little in the way of evidence-based medicine to guide therapy (8). Neuromas are thought to be found in 20% of patients complaining of stump pain (8). It has been thought that both peripheral and central mechanisms contribute to the state of stump pain. Peripheral mechanisms include ectopic neural activity originating from afferent fibers in a neuroma or spontaneous activity in DRG neurons due to the activation of tetrodotoxin-resistant (TTX-R) sodium channel subtypes (20). Altered sodium channel expression is common in injured neurons. Central mechanisms include cortical reorganization and spinal cord sensitization (21). Diagnostic blocks therefore at the level of the DRG should help the clinician sort out the degree of peripheral versus central pain generators.

Treatments for stump pain can be divided into those whose aim it is to prevent the formation of stump pain and those targeted for already established stump pain. Lambert et al (22) compared preoperative epidural and intraoperative perineural analgesia for prevention of postoperative stump pain. They demonstrated that a preoperative epidural provided better relief of stump pain than a perineural catheter. Overall investigations of epidural analgesia and peripheral nerve techniques have not been shown provide a definitive benefit and so are not used routinely. Sakai et al (23) theorized that preventing neuroma formation might also significantly decrease the incidence of post-amputation stump pain. Techniques to prevent neuroma formation include, nerve transposition or ligation, embedding the nerve end in bone or muscle, and capping the nerve stump with a nerve graft, epineurium, or atelocollagen (23). However, most of these techniques are still in experimental stages. In short, there is no prevention modality proven to significantly and consistently reduce the incidence of stump pain.

For already established stump pain, treatments can be based on the specific etiology of stump pain. Conservative therapy includes medical management, TENS therapy, refitting of the prosthesis, or trigger point injections (8). Medical management is comprised

of antidepressants, anticonvulsants, opioids, systemic or topical local anesthetics, sympatholytic agents, or capsaicin cream (24). A study by Wu et al (21) demonstrated that intravenous lidocaine helped attenuate stump pain in some patients. Jacobsen et al (25) demonstrated that intrathecal fentanyl was effective in reducing stump pain. In many cases, it is not uncommon for stump pain to fail to respond adequately to a rational poly-pharmacologic approach.

There has been little documentation, even based on anecdotal reports, of effective interventions for stump pain. A study by Kern et al (26) demonstrated that Botulinum toxin can also help alleviate stump pain. Patients may be reluctant to have stump injections because of prior infections or wound healing issues. Sometimes, surgical stump revision which may benefit 50% of patients might be necessary (27). For example, shaving off a bony spur, resecting a neuroma, or debriding an infection at the stump site might be helpful. But one must remember that surgery can further extend the incision and thus the potential for more pain generators. Also, there is always a possibility of creating a new neuroma (28). In the case of neuroma, some pain physicians have tried dorsal root entry zone lesions with unfortunately poor long-term relief (29). Nerve blocks performed at the level of the stump, sympathetic chain, or in the territory of a peripheral nerve with a mixture of local anesthetic and steroid are usually in the majority of patients of transient benefit (8). Finally, spinal cord stimulation may offer more continuous pain alleviation, but the patients may be of significant medical risk since many have diabetes, chronic renal insufficiency, on going infections, and require chronic anticoagulation. The analgesia of spinal cord stimulation may dwindle over time in more than half the patients who initially report good effect (30).

Application of PRF to the DRG(s) corresponding to a painful peripheral nerve injury may offer new advantages. The first is that patient comfort and compliance

are enhanced because there is no direct invasion of a painful area. The second is that local complications of stump infection can be avoided. The third is that the clinician can employ fluoroscopy to effectively guide the needle or electrode to the precise segmental nerve and DRG. This is then followed by physiologic testing that can help discern a more precise level of treatment. The application of PRF to the DRG as opposed to the peripheral nerve may have therapeutic advantages particularly in chronic postthoracotomy pain as suggested by Cohen and Foster (13). In this small retrospective analysis, patients treated with PRF at the DRG experienced on average of 4.74 months of relief as opposed to 2.87 months if the treatment occurred at the level of the intercostal nerve.

Finally most pre-clinical studies have attempted to investigate the mechanisms by which PRF treatment of the DRG brings about analgesia. Higuchi et al (31) demonstrated that PRF to rat DRG produced increased c-fos expression in laminae I and II of the dorsal horn compared to sham treatments. Another study by Van Zundert et al. demonstrated increased dorsal horn c-fos expression in rats that underwent PRF or CRF (at 67°C) of the DRG at 1 week post treatment (15). Interestingly both conventional RF and PRF treatment of the rat DRG induces similar changes in c-fos expression. It is not known how the change in c-fos expression in response to electrical fields then induces analgesia. Needless to say more preclinical and clinical work is needed to elucidate the mechanisms of PRF and its therapeutic applications to daily patient care.

CONCLUSION

Pulsed radiofrequency treatment of the dorsal root ganglia at the L4 and L5 nerve root level may be a treatment option for patients with peripherally mediated intractable stump pain. Decreased VAS scores and improved use of the prosthetic limb was observed in both of our patients.

REFERENCES

- Adams P, Hendershot G, Marano M. Current estimates from the National Health Interview Survey, 1996. Bethesda: National Center for Health Statistics; 1999.
- Ephraim PL, Wegener ST, MacKenzie EJ, Dillingham TR, Pezzin LE. Phantom pain, residual limb pain, and back pain in amputees: Results of a national survey. *Arch Phys Med Rehab* 2005; 86:1910-1919.
- Jensen TS, Krebs B, Nielsen J, Rasmussen P. Phantom limb, phantom pain and stump pain in amputees during first six months following limb amputation. *Pain* 1983; 17:243-256.
- Jensen TS, Krebs B, Nielsen J, Rasmussen P. Immediate and long-term phantom limb pain in amputees: Clinical characteristics and relationship to pre-amputation limb pain. *Pain* 1985; 21:407-414.
- Ehde DM, Czerniecki JM, Smith DG, Campbell KM, Edwards WT, Jensen MP, Robinson LR. Chronic phantom sensations, phantom pain, residual limb pain, and other regional pain after lower limb amputation. *Arch Phys Med Rehab* 2000; 81:1039-1044.
- Hill A. Phantom limb pain: A review of the literature on attributes and potential mechanisms. *J of Pain and Symp Mang* 1999; 17:125-142.
- Nikolajsen L, Ilkjaer S, Kroner K, Christensen JH, Jensen TS. The influence of preamputation pain on postamputation stump and phantom pain. *Pain* 1997; 72:393-405.
- Manchikanti L, Singh V. Managing phantom Pain. *Pain Phys* 2004; 7:365-375.
- Van Zundert J, Patijn J, Kessels A, Lame I, van Suijlekom h. van Kleef M. Pulsed radiofrequency adjacent to the cervical dorsal root ganglion in chronic cervical radicular pain: A double blind sham controlled randomized clinical trial. *Pain* 2007; 127:173-182.
- Van Zundert J, Lame IE, de Louw A, Jansen J, Kessels F, Patijn J, van Kleef M. Percutaneous pulsed radiofrequency treatment of the cervical dorsal root ganglion in the treatment of chronic cervical pain syndromes: A clinical audit. *Neuromodulation* 2003; 6:6-14.
- Shealy CN. Percutaneous radiofrequency denervation of the lumbar facet joints. *J Neurosurg* 1975 43:448-451.
- Sluijter ME. The role of radiofrequency in failed back surgery patient. *Curr Rev Pain* 2000; 4:49-53.
- Cohen SP, Foster A. Pulsed radiofrequency as a treatment for groin pain and orchalgia. *Urology* 2003; 61:645xxi-645xxiii.
- Erdine S, Yucel A, Cimen A, Aydin S, Sav A, Bilir A. Effects of pulsed versus continuous radiofrequency current on rabbit dorsal root ganglion morphology. *Eur J Pain* 2005; 9:251-256.
- Van Zundert J, de Louw AJ, Joosten EA, Kessels AG, Honig W, Dederen PJ, Veening JG, Vles JS, van Kleef M. Pulsed and continuous radiofrequency current adjacent to the cervical dorsal root ganglion of the rat induces late cellular activity in the dorsal horn. *Anesthesiology* 2005; 102:125-131.
- Munglani R. The long term effect of pulsed radiofrequency for neuropathic pain. *Pain* 1999; 80:437-439.
- Rozen D, Parvez U. Pulsed radiofrequency of lumbar nerve roots for treatment of chronic inguinal herniorrhaphy pain. *Pain Phys* 2006; 9:153-156.
- Cohen SP, Sireci BA, Wu CL, Larkin TM, Williams KA, Hurley RW. Pulsed radiofrequency of the dorsal root ganglia is superior to pharmacotherapy or pulsed radiofrequency of the intercostal nerves in the treatment of chronic postsurgical thoracic pain. *Pain Phys* 2006; 9:227-236.
- Stewart JD. The sciatic nerve, the gluteal and pudendal nerves, and the posterior cutaneous nerve of the thigh. In *Focal Peripheral Neuropathies*. Elsevier Science Publishing Co., 1987, pp 270-285.
- Akopian AN, Sivilotti L, Wood JN. A tetrodotoxin-resistant voltage-gated sodium channel expressed by sensory neurons. *Nature* 1996; 379:257-262.
- Wu C, Tella P, Staats PS, Vaslav R, Kazim DA, Wesselmann U, Raja SN. Analgesic effects of intravenous lidocaine and morphine on postamputation pain: A randomized double-blind, active placebo-controlled, crossover trial. *Anesthesiology* 2002; 96:841-848.
- Lambert AW, Dashfield AK, Cosgrove C, Wilkins DC, Walker AJ, Ashley S. Randomized prospective study comparing preoperative epidural and intraoperative perineural analgesia for the prevention of postoperative stump and phantom limb pain following major amputation. *Reg Anesth Pain Med* 2001; 26:316-321.
- Sakai Y, Ochi M, Uchio Y, Ryoke K, Yamamoto S. Prevention and treatment of amputation neuroma by an atelocollagen tube in rat sciatic nerves. *Wiley InterScience, Journal of biomedical materials research* 2005; 73B:355-360..
- Teng J, Mekhail N. Neuropathic pain: Mechanisms and treatment options. *Pain Practice* 2003; 3:8-21.
- Jacobsen L, Chabal C, Brody MC, Mariano AJ, Chaney EF. A comparison of the effects of intrathecal fentanyl and lidocaine on established postamputation stump pain. *Pain* 1990; 40:137-141.
- Kern U, Martin C, Scheicher S, Muller H. Effects of botulinum toxin type B on stump pain and involuntary movements of the stump. *Am J Phys Med Rehab* 2004; 83:396-399.
- Bailey AA, Moersch FP. Phantom limb. *Can Med Assoc J* 1941; 45:37-42.
- Henrot P, Stines J, Walter F, Martinet N, Paysant J, Blum A. Imaging of the painful lower limb stump. *Radiographics* 2000; 20: S219-235
- Saris SC, Laconco RP, Nahold BS Jr. Successful treatment of phantom pain with dorsal root entry zone coagulation. *Appl Neurophysiol* 1988; 51:188-197.
- Krainick JU, Thoden U, Riechert T. Pain reduction in amputees by long-term spinal cord stimulation: Long-term follow-up study over 5 years. *J Neurosurg* 1980; 52:346-350.
- Higuchi Y, Nashold BS, Sluijter M, Cosman E, Pearlstein RD. Exposure of the dorsal root ganglion in rats to pulsed radiofrequency currents activates dorsal horn lamina I and II neurons. *Neurosurgery* 2002; 50:850-856.