

Observational Study

## Continuous Cervical Epidural Analgesia for Rehabilitation after Shoulder Surgery: A Retrospective Evaluation

Samer N. Narouze, MD, MS, Harsh Govil, MD, Maged Guirguis, MD,  
and Nagy A. Mekhail, MD, PhD

From: Cleveland Clinic  
Foundation, Cleveland, OH

Dr. Narouze is Program Director,  
Pain Medicine Fellowship, Pain  
Management Department,  
Cleveland Clinic, Cleveland, OH.  
Dr. Govil is a Pain Management  
Fellow, Cleveland Clinic,  
Cleveland, OH.

Dr. Guirguis is a resident, Pain  
Management Department,  
Cleveland Clinic, Cleveland, OH.

Dr. Mekhail is Chairman,  
Department of Pain  
Management, Cleveland Clinic,  
Cleveland, OH.

Address correspondence:  
Samer N. Narouze, MD, MS  
Program Director,  
Pain Medicine Fellowship  
Pain Management  
Department/C25  
The Cleveland Clinic Foundation  
9500 Euclid Ave.  
Cleveland, OH 44195  
E-mail: narouzs@ccf.org

Disclaimer: There was no external  
funding in the preparation of this  
manuscript.

Conflict of interest: None.

Manuscript received: 07/14/2008

Revised manuscript received:  
10/02/2008

Accepted for publication:  
10/27/2008

Free full manuscript:  
www.painphysicianjournal.com

**Background:** Patients with frozen shoulder who fail conservative therapy need surgical treatment and aggressive post-operative rehabilitation.

**Objective:** To evaluate the effect of continuous cervical epidural analgesia on pain scores and range of motion of the shoulder joint in patients undergoing surgery for treatment of refractory frozen shoulder.

**Methods:** Twenty-one patients with refractory frozen shoulder who had failed conservative treatment and undergone surgical procedure (manipulation under anesthesia or capsular release) were identified and the data were collected retrospectively. These patients had cervical tunneled epidural catheter (TEC) placement for continuous infusion of a mixture of low-dose narcotic and local anesthetics at the time of surgery and were discharged home with the catheter in place. They were then involved in an active physical therapy program to increase the range of motion of the affected shoulder joint.

The patients (N = 21) were followed for a median of 4.7 weeks. They were assessed for range of motion, function, visual analog pain scores (VAS), and opiate use before the surgery and after tunneled epidural catheter removal.

**Results:** Statistically significant changes from the time of placement to the time of removal of the tunneled epidural catheter (TEC) were observed for VAS pain score and range of motion of the shoulder in forward flexion, external rotation, and internal rotation. The mean rate of change among the patients for pain score, forward flexion, external rotation, and internal rotation was also computed. The mean change per week in each of these 4 measurements significantly differed from zero. 33 percent of the patients returned to work within one week.

**Conclusion:** Our data show that the continuous infusion of epidural opioids and local anesthetics through a tunneled cervical epidural catheter during the rehabilitation phase after shoulder surgery for adhesive capsulitis may be a safe and effective tool for post-operative pain control and to facilitate rehabilitation.

**Key words:** Cervical epidural, epidural analgesia, shoulder surgery

**Pain Physician 2009; 12:1:189-194**

**T**he term "frozen shoulder" was first used by Codman (1) in 1934. Frozen shoulder is a descriptive term that refers to a stiffened glenohumeral joint that has lost significant range

of motion. There is a reversible contraction of the joint capsule in almost all cases. Pathologically, the glenohumeral joint has lost its normal distensibility. In long-standing cases, adhesions may form

between the joint capsule and the humeral head. In 1945, Neviaser (2) adopted the term "adhesive capsulitis."

A variety of regimens have been used for the treatment of frozen shoulder, which include non-steroidal anti-inflammatory drugs, intraarticular steroid injections, physical therapy and stretching exercises, manipulation under anesthesia (MUA), arthroscopic release and — as a final resort — open capsulotomy (3-10).

A progressive physical therapy rehabilitation program plays an essential role in the treatment of this condition. The goal is to treat any underlying process and gradually stretch the lining of the glenohumeral joint thereby restoring normal range of motion. In most cases adhesive capsulitis is a self-limited condition that responds well to conservative therapy. Less than 10% of the patients may fail to improve after the conservative therapy and will continue to have long-term problems that require more aggressive surgical therapy (8-10). These patients are frequently referred to as having a refractory or recalcitrant frozen shoulder. There are 2 main surgical approaches; arthroscopic dilatation of the glenohumeral joint (capsular release) (11-14) and MUA (15-19).

Surgery is followed by aggressive physical therapy to improve the range of motion of the affected shoulder joint. The most important factor in the success of the physical therapy rehabilitation program is that the patient should have adequate pain relief after surgery to be able to participate in the exercises. Multiple analgesic modalities have been used to facilitate the rehabilitation program, which include heat, ice, and analgesics (opiates and non-opiates) (8). An alternative to oral analgesics is continuous epidural infusion of local anesthetics and narcotics through a cervical epidural catheter. Continuous epidural infusion represents a viable alternative that has the advantage of the addition of local anesthetics to narcotics to provide better analgesia and improve the range of movement. The risks and complications of this approach (motor block, respiratory depression, hypotension, and urinary retention) can be avoided by careful titration of the infused medications, frequent observation, and adequate patient and family education.

## **METHODS**

After obtaining our institution research review board's approval, the data were collected retrospectively by reviewing the patient's medical records. There were 25 patients with refractory frozen shoulder, who had failed conservative treatment (physical therapy, non-steroidal anti-inflammatory drugs, intraarticular steroid injections) and undergone surgical procedure with continuous postoperative epidural infusion of narcotics and local anesthetics, identified between January 2002 and December 2005. Data were analyzed for 21 patients (N = 21) because of incomplete data for the other 4 patients. These individuals had tunneled cervical epidural catheter placement for continuous infusion of a mixture of low-dose narcotic and local anesthetics prior to the surgery and were discharged home with the catheter in place. They were involved in an active physical therapy program to increase the range of motion of the affected shoulder joint, while having continuous epidural analgesia. All of the patients were assessed for range of motion, function, visual analog scores, and opiates use before the surgery and after tunneled epidural catheter (TEC) removal.

Demographic data, duration of symptoms, duration of treatment, and medications used in the epidural infusion, as well as orally, were recorded. Medical records were also reviewed for complications as well as further follow-up treatments required after removal of the epidural catheters.

Epidural catheters were inserted under strict aseptic surgical techniques at the C7-T1 interspace (Fig.1). With fluoroscopic guidance, the epidural catheters were navigated 2-3 segments cephalad on the ipsilateral side to cover the affected limb (shoulder joint). Catheters were tunneled for 2 to 3 inches under the skin, fixed, and taped to the skin in a sterile fashion. They were placed on prophylactic oral antibiotics for 7 days. Patients were admitted to the hospital for 1-2 days to adjust the epidural infusion and to start the rehabilitation program. A physiotherapy program was started immediately after the surgery. Physiotherapy emphasized the functional planes of motion namely forward flexion, external rotation, and internal rotation. The time in formal physical therapy ranged between 4 to 6 weeks. Oral opioid supplementation was used as needed.

Patients were discharged home with continuous epidural infusion and had aggressive rehabilitation programs at home. They were followed by home care nursing twice a week and returned to the pain clinic as needed or every 2 weeks to check the epidural site for any signs of infection.

The data collected included demographic data, changes in VAS pain scores, changes in range of motion of the shoulder joint, epidural medications use and duration, oral opioid use, complications of cervical tunneled epidural catheter, and ability to return to and performance at work.

### Statistical Methods

Each of the outcomes was measured before TEC placement and after TEC removal. Time from placement to removal was recorded as well.

Difference in VAS pain score, forward flexion, external rotation, and internal rotation from before TEC placement to after TEC removal was computed for each patient, summarized, and tested for equivalence to 0 using a one-sample student's T-test. In addition, the rate of change in these outcomes (defined as the difference from placement to removal divided by the number of weeks of TEC exposure) was analyzed in the same manner.

Binary (yes or no) opioid use was tabulated for the 2 time points (placement and removal), and then tested for equal proportions among the 2 time points using McNemar Test for Dependent Proportions.

### RESULTS

A total of 25 patients were identified and the data were analyzed for 21 patients because of missing data from the other 4 charts. There were 9 men and 12 women with an average age of 47.4 (ages ranged from 27 to 63).

These individuals had tunneled cervical epidural catheter placement in the cervical region for continuous infusion of a mixture of opiates and local anesthetics before shoulder surgery for adhesive capsulitis. The epidural solution consisted of Bupivacaine (0.0625% – 0.1%) and Fentanyl (2–5 mcg/mL). The rate of infusion and the concentration were titrated during the initial hospital stay and the subsequent follow up visits. Titration was guided by acceptable pain control while minimizing side effects.

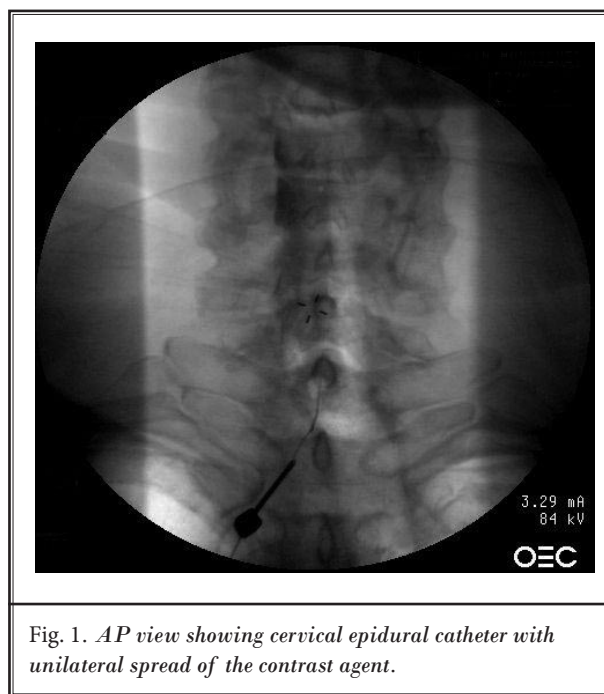


Fig. 1. AP view showing cervical epidural catheter with unilateral spread of the contrast agent.

The outcomes were measured at the time of TEC removal and follow-up appointments at the pain clinic. The TEC was removed when it was decided that pain is no longer a factor limiting the shoulder ROM (VAS is less than 5 with physical therapy).

The patients (N = 21) were followed for a median (quartiles) of 4.7 (2.3, 5.7) weeks in order to measure the outcomes of interest. Summary statistics and tests for change from before TEC placement to after TEC removal are presented in Table 1. Mean differences in VAS pain score, forward flexion, external rotation, and internal rotation were significantly different from 0, and the proportion of patients receiving oral opioids significantly decreased from placement to removal. Oral opioid use varied significantly among the patients prior to surgery and following removal of the epidural catheter. It decreased from a median of 80 mg morphine equivalent daily before catheter placement to a median of 20 mg after catheter removal. The patients received a daily median dose of 180 mcg fentanyl epidurally during the first 1–2 weeks post-operatively and then after the infusions were titrated down and the patients weaned off before catheter removal while transitioning to oral opioids.

Table 1: Summary statistics and one-sample tests for  $N = 21$  patients receiving a tunneled epidural catheter (TEC) for post-operative pain control after undergoing surgery for treatment of refractory frozen shoulder.

Outcome	Placement	Removal	(Removal – Placement)		
	Mean (SD)	Mean (SD)	Mean (SD)	95% CI	P-value
VAS Pain Score (0–10)	5.1 (2.7)	2.5 (2.3)	-2.6 (3.2)	(-4.2, -1.0)	0.003†
ROM – Forward Flexion (Degrees)	95.3 (28.7)	156.7 (21.1)	61.4 (35.4)	(43.8, 79.0)	< 0.001†
ROM – External Rotation (Degrees)	9.4 (10.8)	48.9 (20.8)	39.4 (22.6)	(28.2, 50.7)	< 0.001†
ROM – Internal Rotation (Degrees)	4.6 (6.6)	50.0 (20.0)	45.4 (24.0)	(30.9, 59.9)	< 0.001†
<b>Opioid Use</b>	<b>N (%)</b>	<b>N (%)</b>			
Yes	17 (81.0)	10 (47.6)	—	—	0.02‡
No	4 (19.0)	11 (52.4)	—	—	

† Student's paired T-test for mean difference equal to 0.

‡ McNemar's test for equal proportions receiving opioids before and after TEC placement.

Table 2. Summary statistics and paired student's T-tests for mean weekly rate of change equal to 0 for VAS pain score, forward flexion ROM, external rotation ROM, and internal rotation ROM for  $N = 21$  patients receiving a tunneled epidural catheter (TEC) for postoperative pain control after undergoing surgery for treatment of refractory frozen shoulder.

Outcome	Weekly Rate		
	Mean (SD)	95% CI	P-value†
VAS Pain Score (0–10)	-1.1 (1.8)	(-2.0, -0.2)	0.019
ROM – Forward Flexion (Degrees)	21.1 (24.1)	(9.1, 33.1)	0.002
ROM – External Rotation (Degrees)	12.4 (12.0)	(6.4, 18.3)	< 0.001
ROM – Internal Rotation (Degrees)	12.9 (9.7)	(7.1, 18.8)	< 0.001

† Student's T-test of mean weekly rate equal to 0.

Summary of the mean rate of change (adjusted for the different exposure times) among the patients for VAS pain score, forward flexion, external rotation, and internal rotation are presented in Table 2. The mean change per week in each these 4 measurements significantly differed from 0.

Patients maintained the low VAS pain scores and good ROM for a mean follow-up of 14 months after TEC removal. Seven patients returned to work within one week of TEC removal without any limitations, 2 patients within 3 months, and another 2 within one year. Five patients did not work before and after the surgery as they were retired. No information about

return to work or activity could be gathered for 4 patients due to a change in contact information (phone numbers). In 5 patients the dose of oral opioids was substantially reduced while, 4 patients did not need any oral opioids after the surgery.

The following complications were encountered: 2 patients had catheter tip migration, of which one was replaced without further complication and the other one was pulled out. One patient developed headache, neck pain, and fever and was admitted to the hospital. Epidural abscess was ruled out and he was diagnosed with superficial skin infection and subsequently the catheter was removed.

## Discussion

Frozen shoulder is defined by the American Shoulder and Elbow Society (20) as a condition characterized by the functional restriction of both active and passive range of motion. The primary treatment is a progressive physical therapy rehabilitation program. The goal is to treat any underlying process and gradually stretch the lining of the glenohumeral joint thereby restoring normal range of motion. Traditionally, frozen shoulder has been regarded as a self-limiting condition, lasting 18–30 months and with no significant long-term sequelae. Studies that determined the natural history of this condition have shown that resolution of the disease often takes up to 2–3 years (21). Long-term follow-up studies have shown that at a mean of 7 years from the onset of the condition, 50% of patients still have pain or stiffness of the shoulder, although only 11% report functional limitations (22). To decrease the time to recovery and improve the results of this condition a number of different treatment modalities have been used. These include control of pain and inflammation with nonsteroidal anti-inflammatory drugs, physiotherapy, arthroscopic division of adhesions, and manipulation of the shoulder under anesthesia. Also there was a recent report that showed the diagnostic and therapeutic value of subscapular nerve block and subscapularis trigger points infiltration in a frozen shoulder (23).

Patients who fail to improve after the conservative therapy are referred to as having a refractory frozen shoulder and may need surgical treatment. There are 2 main surgical approaches: arthroscopic dilatation of the glenohumeral joint (capsular release) (11-14) or MUA (15-19). In most of these studies pain control during the rehabilitation phase was a significant issue and it was provided by oral opioid medications.

Cervical epidural anesthesia was reported before as an alternative to general anesthesia for shoulder

surgery (24). However, the purpose of this study was to assess the outcome of a group of patients with refractory shoulder stiffness treated by surgery followed by early physiotherapy under sufficient analgesia by the continuous epidural infusion of a mixture of a low-dose opioid and local anesthetics through a tunneled cervical epidural catheter that was left in place for a few weeks.

Adhesive capsulitis refractory to the conservative therapy is a disabling condition needing surgical intervention followed by an aggressive rehabilitation program. Adequate analgesia is a prerequisite to a good physical therapy program for improving the range of motion of the affected shoulder joint, as this allows full participation of the patient.

## Conclusion

This study demonstrates that statistically significant changes from time of placement to time of removal of the TEC were observed for VAS pain score, forward flexion ROM, external rotation ROM, and internal rotation ROM. These differences were also significantly different from 0 after adjusting for the varying time of exposure to the TEC. Due to the fact that this study was retrospective and there was no control group, it is not at all clear how much of the observed response was due to the TEC. The results of this study can only discuss the change from baseline, and not the “efficacy” of the treatment. A randomized controlled trial would be needed to discuss the efficacy of the TEC compared to some standard.

However our data show that the continuous infusion of epidural opioids and local anesthetics through a tunneled cervical epidural catheter during the rehabilitation phase after shoulder surgery for adhesive capsulitis may be an alternative to oral pain medications, which could be used in conjunction with surgery for management of refractory shoulder stiffness.

## REFERENCES

1. Codman EA. *The Shoulder*. Thomas Todd, Boston, 1934, 216-224.
2. Neviasser JS. Adhesive capsulitis of the shoulder. *J Bone Joint Surg Am* 1945; 27:211-222.
3. Beacon JP, Bayley JIL, Kernhan JG, King RJ. The technique and efficacy of manipulation in the frozen shoulder syndrome. *J Bone Joint Surg Br* 1985; 67: 495-496.
4. Neviasser RJ, Neviasser TJ. The frozen shoulder. Diagnosis and management. *Clin Orthop* 1987; 223:59-64.
5. Shaffer B, Tibone JE, Kerlan RK. Frozen shoulder. *J Bone Joint Surg Br* 1992; 74: 923-927.
6. Ma T, Kao MJ, Lin IH, Chiu YL. A study on the clinical effects of physical therapy and acupuncture to treat spontaneous frozen shoulder. *Am J Chin Med* 2006; 34:759.
7. Wang JP, Huang TF, Hung SC, Ma HL, Wu JG, Chen TH. Comparison of idiopathic, post-trauma and post-surgery frozen shoulder after manipulation under anesthesia. *Int Orthop* 2007; 31:333-337.
8. Dias R, Cutts S, Massoud S. Frozen shoulder. *BMJ* 2005; 331:1453-1456.
9. Farrell CM, Sperling JW, Cofield RH. Manipulation for frozen shoulder: Long-term results. *J Shoulder Elbow Surg* 2005; 14:480-484.
10. Chamblor AF, Carr AJ. Aspects of current management. The role of surgery in frozen shoulder. *J Bone Joint Surg Br* 2003; 85:789-795.
11. Ozbaydar MU, Tonbul M, Altun M, Yalaman O. Arthroscopic selective capsular release in the treatment of frozen shoulder. *Acta Orthop Traumatol Turc* 2005; 39:104-113.
12. Holloway GB, Schenk T, Williams GR, Ramsey ML, Iannotti JP. Arthroscopic capsular release for the treatment of refractory postoperative or post-fracture shoulder stiffness. *J Bone Joint Surg Am* 2001; 83:1682-1687.
13. Klinger HM, Otte S, Baums MH, Haerer T. Early arthroscopic release in refractory shoulder stiffness. *Arch Orthop Trauma Surg* 2002; 122:200-2002.
14. Ogilvie-Harris DJ, Wiley AM. Arthroscopic surgery of the shoulder. A general appraisal. *J Bone Joint Surg Br* 1986; 68:201-207.
15. Dodenhoff RM, Levy O, Wilson A, Copeland SA. Manipulation under anesthesia for primary frozen shoulder: Effect on early recovery and return to activity. *J Shoulder Elbow Surg* 2000; 9:23-26.
16. Hamdan TA, Al-Essa KA. Manipulation under anaesthesia for the treatment of frozen shoulder. *Int Ortho* 2003; 27: 107-109.
17. Hill J, Bogumill H. Manipulation in the treatment of frozen shoulder. *Orthopedics* 1998; 2:1255-1260.
18. Van-Royen BJ, Pavlov PW. Treatment of frozen shoulder by distension and manipulation under local anaesthesia. *Int Ortho* 1996; 20:207-210.
19. Weber M, Prim J, Bugglin R, Michel BA, Gerber H. Long term follow up of patients with frozen shoulder after mobilization under anesthesia, with special reference to the rotator cuff. *Clin Rheumatol* 1995; 14:686-691.
20. Zuckermann JD, Cuomo F, Rokito AS. Definition and classification of frozen shoulder: A consensus approach. *J Shoulder Elbow Surg* 1994; 3:572.
21. Grey RG. The natural history of idiopathic frozen shoulder. *J Bone Joint Surg Am* 1978; 60:564.
22. Reeves B. The natural history of frozen shoulder syndrome. *Scand J Rheumatol* 1975; 4:193-196.
23. Jankovic D, van Zundert A. The frozen shoulder syndrome. Description of a new technique and five case reports using the subscapular nerve block and subscapularis trigger point infiltration. *Acta Anaesthesiol Belg* 2006; 57:137-143.
24. Tsui BC, Bury J, Bouliane M, Ganapathy S. Cervical epidural analgesia via a thoracic approach using nerve-stimulation guidance in adult patients undergoing total shoulder replacement surgery. *Acta Anaesthesiol Scand* 2007; 51:255-260.