

Observational Study

Contrast Flow Selectivity During Transforaminal Lumbosacral Epidural Steroid Injections

Michael B. Furman, MD, MS¹, Thomas S. Lee, MD¹, Ariz Mehta, MD¹,
Jeremy I. Simon, MD², and William G. Cano, MD³

From: ¹Orthopaedic & Spine Specialists, York, PA; ²Rothman Institute, Philadelphia, PA; and ³Performance Spine & Sports, Pottstown, PA

Dr. Furman, Dr. Lee and Dr. Mehta are with the Orthopaedic & Spine Specialists, York, PA. Dr. Simon is with the Rothman Institute, Philadelphia, PA. Dr. Cano is with the Performance Spine & Sports, Pottstown, PA.

Address correspondence:
Michael B. Furman, MD
Orthopaedic and Spine Specialists
1855 Powder Mill Road
York, PA 17403
E-mail: mbfurman@hotmail.com

Disclaimer: There was no external funding in the preparation of this manuscript.
Conflict of interest: None.

Manuscript received: 06/04/2008
Revised manuscript received: 08/05/2008
Accepted for publication: 09/25/2008

Free full manuscript:
www.painphysicianjournal.com

Background: Lumbosacral transforaminal epidural steroid injections (LS-TFESIs) are an accepted procedure used in the comprehensive, conservative care for lumbar disc pathology and/or spinal stenosis induced low back pain with a radicular component. Historically, the terminology used to describe the transforaminal technique of instilling medications into the epidural space and/or exiting structures has varied. These procedures have also been referred to as either diagnostic or therapeutic selective nerve root blocks (SNRBs). Although this procedure is typically used to “selectively” treat isolated pathology, the “SNRB” terminology suggests that one can selectively diagnose or treat a specific nerve root as a pain generator by anesthetizing or blocking it. It has been recently demonstrated that L4 and L5 SNRBs are often non-“selective” by investigating the extent of epidural contrast flow patterns after injecting 1.0 mL of contrast. Our study attempts to identify the minimum injectate volume at which LS-TFESIs may still be considered “selective” with no injectate extending to either the adjacent (superior and/or inferior) levels or to the contralateral side.

Objective: Quantitatively evaluate contrast flow level selectivity noted during fluoroscopically guided lumbosacral transforaminal epidural steroid injections (LS-TFESIs).

Study Design: Prospective, nonrandomized, observational human study.

Methods: Thirty patients (female = 10, male = 20) undergoing LS-TFESIs were investigated. After confirming appropriate spinal needle position with biplanar imaging, 4.0 mL of nonionic contrast was slowly injected. Fluoroscopic images were recorded at 0.5 mL increments. These biplanar contrast flow images were evaluated to determine which 0.5 mL volume increment was no longer specific for the injected level. In particular, we documented when contrast extended either to a superior or inferior spinal segment or crossed the midline spine to the contralateral side.

Results: After injecting 0.5 mL of contrast, 30% of LS-TFESIs performed in this study were no longer “selective” for the specified root level. After injecting 1.0 mL of contrast, 67% of LS-TFESIs performed in this study were no longer “selective” for the specified root level. After injecting 1.5 mL of contrast, 87% of LS-TFESIs performed in this study were no longer “selective” for the specified root level. After injecting 2.5 mL of contrast, 90% of LS-TFESIs performed in this study were no longer “selective” for the specified root level.

Conclusions: Diagnostic LS-TFESI or SNRB blocks limiting injectate to a single, ipsilateral segmental level cannot reliably be considered diagnostically selective with volumes exceeding 0.5 mL. Injectate volumes greater than 0.5 mL are consistently non-selective and cannot be used reliably for diagnostic block procedures in the epidural space.

Key words: Epidural steroid injections, selective nerve root block, transforaminal, contrast flow

Pain Physician 2008; 11:6:855-861

The prevalence of low back pain with or without radicular pain remains high in industrialized countries (1). Although management remains a medical challenge, non-invasive diagnostic options include a thorough clinical evaluation (history, physical examination, imaging, and/or serologic studies). Non-invasive treatment options include physical therapy, manual and behavioral techniques, and medications. Within the realm of percutaneous spinal interventions, diagnostic options include analgesic “block” or pain provocation procedures. For diagnostic purposes, these low volume selective analgesic block procedures are typically done in conjunction with a pain diary to prospectively compare pre-procedural symptoms to post-procedure symptom relief (2). For radicular pain, the ideal diagnostic analgesic block should limit injectate flow to a particular spinal segment. Many practitioners advocate that low volume intraforaminal nerve root flow can be diagnostic and use the term Diagnostic Selective Nerve Root Block (SNRB) to describe this procedure.

Reviewing lumbar spine nerve anatomy, the ventral and dorsal segmental roots reside medial to the pedicle, join and form the segmental spinal nerve in the superior foramen, and then exit the neural foramen. The very short spinal nerve divides into the dorsal and ventral rami immediately outside the foramen. The nerve root resides medial to the pedicle within the dural and epidural space and assumes a different name as it becomes the spinal nerve and exits the foramen inferior to the pedicle.

For diagnostic purposes, volumes ranging from 1.5 mL to 5.0 mL are described to selectively “block,” confirm, and circumscribe the suspected segmental level prior to a therapeutic intervention (3,4). Since the injection is supposedly diagnostic, it should be specific to one, and only one, segment. Therefore, a low anesthetic volume is used to prevent anesthetizing an adjacent segment thus obviating a false-positive result with low specificity. Since the intent is to diagnostically identify a painful and pathologic segment, a false positive result occurs when more than one segmental level is inadvertently anesthetized resulting in limited diagnostic utility. Vassiliev (5) has recently demonstrated that L4 and L5 SNRBs are often non-“selective” by investigating the extent of epidural contrast flow patterns after injecting 1.0 mL of contrast.

The percutaneous therapeutic options for radicular pain include interlaminar or transforaminal epidu-

ral steroid injections (LS-TFESIs). Therapeutic LS-TFESIs are an integral component of comprehensive, conservative care for lumbar disc and/or spinal stenosis mediated low back pain with a radicular component (2,6-9). The theoretical goal is to place a concentrated steroid and anesthetic solution selectively at the pathologic site or along the dorsal root ganglion (DRG) (6,10).

Therapeutic LS-TFESIs volumes range from 2.0 mL to 5.0 mL coating the suspected pathologic site with a concentrated anesthetic/steroid solution (9,11). Although these are commonly described as “selective” injections, the term “selective” is used to describe injecting the pathologic site with a concentrated therapeutic solution that may spread to a closely adjacent spinal segment and is not meant to imply diagnostic specificity. The therapeutic procedure injectate volumes can and should be greater since treating the pathology takes precedence over diagnostic specificity. The “selectivity” of this therapeutic procedure therefore refers to placing an increased medication concentration (often steroid) along a specific anatomical spinal segment that correlates closely with the patient’s clinical and radiographic evaluations.

Our study investigates LS-TFESI contrast flow and volumes that are specific to a single segmental level. In particular, we attempt to identify the minimum volume at which these LS-TFESI procedures may still be considered “selective” at their respective intervertebral foramen with no contrast extending to either adjacent (superior and/or inferior) levels or contralaterally. This study does not attempt to identify the volumes necessary for achieving a clinically successful therapeutic procedure.

METHODS

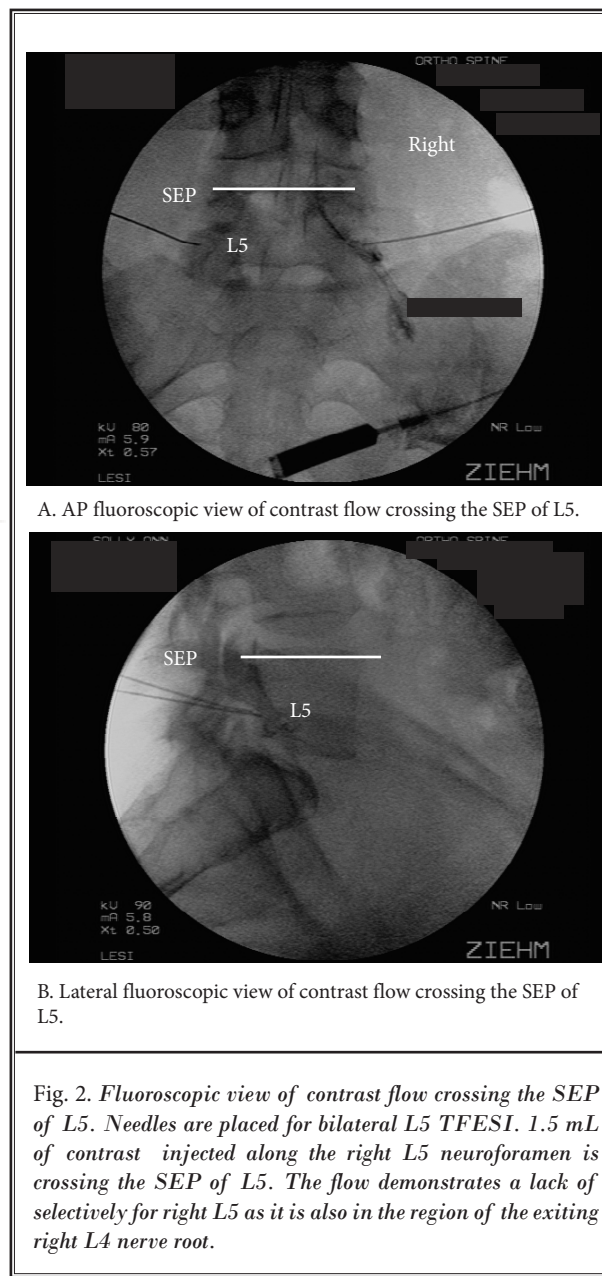
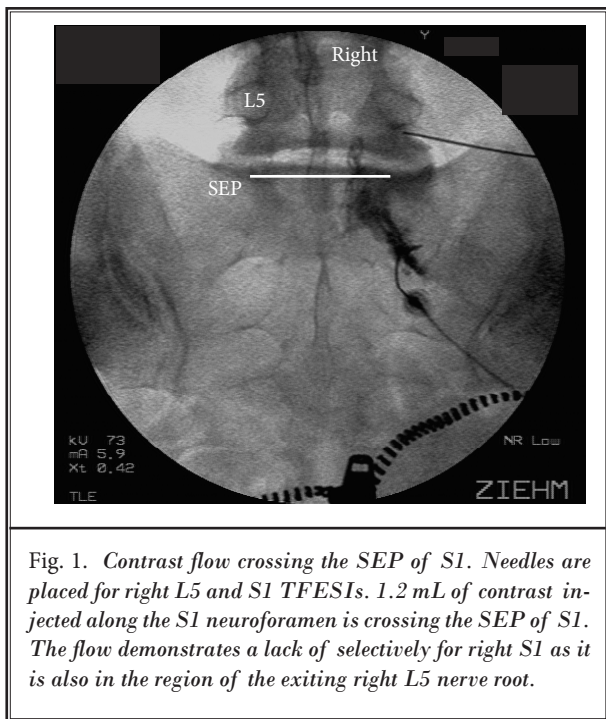
Patients who were clinically appropriate for single or 2 level LS-TFESI were recruited. These included patients with lumbar disc injury/herniation (DI) and/or lumbar central spinal stenosis (SS). Pregnant patients or those with contrast allergy were excluded. The procedure’s risks, benefits, alternatives, and prognosis were reviewed per our standard protocol. Thirty consecutive patients consented and were included in the study, investigating flow patterns at only one level using the Institutional Review Board’s approved study protocol. Those study participants undergoing 2 level injections had only one level investigated using the Institutional Review Board’s approved study protocol. The interventionist (MBF, TSL, or WGC) determined the appropriate injection level according to

the patient's clinical scenario including radiographic imaging studies.

The LS-TFESIs were performed in an outpatient procedure suite. The patients were prepped and draped sterilely in the prone position. A registered nurse obtained intravenous access, provided optional sedation, and monitored appropriate vital signs and pulse oximetry. The appropriate intervertebral foramen's oblique view was fluoroscopically visualized and optimized. The overlying soft tissue was then anesthetized with 1% lidocaine without epinephrine. An appropriate length styleted 22-gauge spinal needle was guided inferior to the pars interarticularis and into the intervertebral foramen using a retroneural approach (7). Using biplanar visualization, the needle was advanced into the "safe triangle" inferior to the pedicle and supero-lateral to the exiting spinal nerve (12,13). For S1 transforaminal injections, the 22-gauge needle was fluoroscopically guided into the foramen's supero-lateral quadrant.

After needle position confirmation, contrast (ISOVUE 320, manufacturer Bracco Diagnostics, Princeton, NJ) was injected slowly at 0.5 mL increments up to a maximum of 4.0 mL (approximately 0.5 mL per 30 seconds) continuously confirming needle position and monitoring contrast flow spread. Fluoroscopic images

were obtained at 0.5 mL increments. These images were evaluated for adjacent level (superior or inferior) or contralateral side contrast spread. Whenever contrast was noted to flow to an adjacent level or to the contralateral side, injectate volumes were recorded. Contrast was documented as flowing to an adjacent superior level when flow crossed its superior end plate (SEP) (Figs. 1-3). Contrast was documented as flowing to an adjacent inferior level when flow crossed



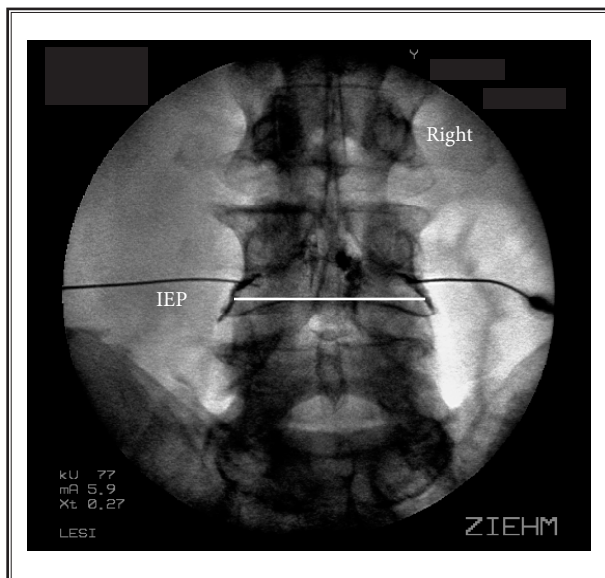


Fig. 3. Contrast flow crossing the IEP of L4. Needles are placed for bilateral L4 TFESIs. 1.0 mL of contrast injected along the right L4 neuroforamen is crossing the IEP of L4. The flow demonstrates a lack of selectivity for right L4 as it is also in the region of the traversing right L5 nerve root.

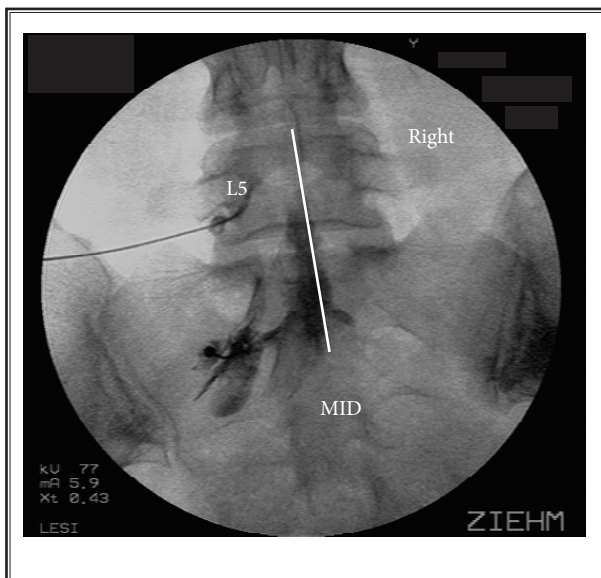


Fig. 4. Contrast flow crossing midline. Needles are placed for left L5 and S1 TFESIs. 2.0 mL of contrast injected along the left S1 neuroforamen is crossing midline. The flow demonstrates a lack of selectivity for left S1 as it is also in the region of the traversing right S1 nerve root. Contralateral flow was noted in a minority of patients with volumes less than 2.5 mL.

its inferior end plate (IEP) (Fig. 4). Contrast was documented as flowing to the contralateral side when it crossed midline. For S1 injections, we only evaluated for contralateral and superior flow. If a fluoroscopically confirmed vascular injection was noted, the patient's data was excluded and they were not included in data analysis. We excluded them from data analysis since we would be unable to quantitate their contrast flow. After completion of this study protocol's data collection, a steroid/anesthetic solution (typically, a 2 mL solution consisting of 80 mg of triamcinolone and remainder of 1% lidocaine) was administered into the epidural space. Patients were excluded from the quantitative analysis if their needle placement was too far lateral and precluded central epidural flow.

In addition to the fluoroscopic images, data collection and analysis included gender, age, diagnosis, presence or absence of previous spinal surgery, level of injection, and injection side.

RESULTS

We originally enrolled 39 patients. Six patients had initial intravascular injections and 3 had primarily extraforaminal flow. We analyzed data on the remaining 30 patients (Tables 1,2).

Table 1. Demographics of study participants.

Demographic	N
Male	n = 20 (66.7%)
Female	n = 10 (33.3%)
Average Age	57.48 years (SD = 17.43)
Percent with prior surgery	n = 6 (20%)

Table 2. *Types of injuries of study participants.*

DX	Frequency	Percent
DI: Lumbar disc injury/herniation	14	46.7
SS: Central spinal stenosis (foraminal excluded)	10	33.3
SS/DI: Both lumbar disc injury/herniation and central spinal stenosis	6	20
Total	30	100

Table 3. *Level breakdown.*

Level	Frequency	Percent
L L4	2	6.7
L L5	5	16.7
L S1	4	13.3
R L3	1	3.3
R L4	2	6.7
R L5	9	30
R S1	7	23.3
Total	30	100

Table 4. *Observed injectate volumes.*

Volumes (mL)	Adjacent N	Contralateral N	Adjacent or Contralateral N	Cumulative %
0.5	9	1	9	30
1	11	2	20	67
1.5	6	2	26	87
2	0	3	26	87
2.5	0	3	27	90
3	0	5	27	90
3.5	0	2	27	90
4	3	1	30	100
Insufficient Contrast Flow	1	11	30	100

Contrast Flow Data

Level breakdown is illustrated in Table 3.

Observed injectate volumes are illustrated in Table 4.

The average contrast volume observed to extend to the superior or inferior level was 1.16 (Range 0.5 mL to 4.0 mL). The average contrast volume observed to extend to the contralateral side was 2.37 (Range 0.5 mL to 4.0 mL). The standard deviation for the superior or inferior level was 0.9 and 1.0 for the contralateral side.

After injecting 0.5 mL of contrast, 30% of LS-TFESIs performed in this study were no longer “selective” (adjacent or contralateral) for the specified root level. After injecting 1.0 mL of contrast, 67% of LS-TFESIs performed in this study were no longer “selective” for the specified root level. After injecting 1.5 mL of contrast, 87% of LS-TFESIs performed in this study were no longer “selective” for the specified root level. After injecting 2.5 mL of contrast, 90% of LS-TFESIs performed in this study were no longer “selective” for

the specified root level. Contralateral flow of contrast was noted in a minority of patients with volumes less than 2.5 mL.

DISCUSSION

LS-TFESIs are a validated treatment option within the comprehensive, non-surgical armamentarium for lumbar disc or spinal stenosis-mediated low back pain with a radicular component (2,6-9). Therapeutically, they are considered “selective” because they can deliver concentrated medication (often steroid) in an anatomical spinal segment that correlates closely with the patient’s clinical and radiographic examinations. These epidural injections are often used inappropriately for diagnostic purposes when their selectivity is misunderstood. Our data collaborates recently published work by Vassiliev (5) in that injectate volumes greater than 1.0 mL are frequently no longer “selective” when performing a SNRB or a LS-TFESI.

The term “selective nerve root block” (SNRB) is frequently used interchangeably with LS-

TFESI, further confusing the delineation between each procedure's potential diagnostic and therapeutic utility. This study attempts to quantify the flow of contrast when injected transforaminally at a specific spinal intervertebral foramen or nerve root level. Based on this study's data, injectate volumes as low as 0.5 mL have been shown to reach adjacent (superior, inferior, and/or contralateral) spinal levels and are thus non-diagnostic and non-selective. Of course, medial spread of injectate can also "block" the adjacent descending nerve root even though it may not be below the inferior end plate of that level. Therefore, when injectate volumes equal or exceed this amount, it is not possible to perform a truly "selective" diagnostic "nerve root block" when using a transforaminal approach. If the intent is to diagnostically identify the pathologic segment via a "selective block," a false-positive result may occur since more than one root level may be inadvertently anesthetized. Injectate volumes above 0.5 mL should instead be considered "non-selective" anatomically with limited diagnostic utility for anesthetizing a single spinal nerve root to determine its contribution to the patient's pain (14-16).

Therapeutic LS-TFESIs result in medication flow into the epidural space. This is the theoretically ideal location for a therapeutic procedure since medications can easily be delivered to the pathologic site. The proposed mechanisms of pain relief include decreasing or diluting inflammatory mediators, reducing edema, interrupting afferent nerve impulses, and possibly providing nerve membrane stabilization. The goal is to maximally concentrate the medication at the pathologic site. To accurately determine the amount of injectate necessary to reach the pathologic level, some authors advocate recording the amount of contrast needed to reach the site and then using this volume for the therapeutic solution (7). However, the present study is not evaluating therapeutic volumes.

Since previous studies have demonstrated no septa in the anterior epidural space at the midvertebral level, contralateral spread is not surprising (17). In those patients where contralateral spread was not observed, one can postulate either a normal midline septum presence or soft tissue contours resulting in ipsilateral contrast flow (18). Ipsilateral level contrast spread is expected since there are no septa or other connective tissue separating the anterior epidural space from ipsilateral superior and/or inferior lumbar vertebral segments. Contrast volume variability neces-

sary to reach adjacent segments can be explained by variations in normal anatomy, final needle tip position relative to the segmental level, or other procedural nuances.

One of this study's potential limitations is due to the contrast, anesthetic and steroid suspension's different viscosity, and potential epidural flow characteristics. We use contrast flow presuming that the anesthetic and/or steroid solutions flow characteristics will be similar to that of contrast. Another limitation is that our sample size was too small to assess statistically the effect of diagnosis (DI versus SS) or prior surgical history on injectate volume. Power analysis of our data estimated that a minimum sample size of 52 patients is needed for this additional analysis.

Another limitation is that we did not monitor the different flow patterns at various time frames post injection. One would assume that selectivity would decrease even more as the injectate diffuses into the soft tissues and other structures. We also did not use volume increments of less than 0.5 mL to truly determine a volume of definitive specificity. However, volumes of less than 0.5 mL could prove to result in limited anesthetic efficacy resulting in a potential false-negative diagnostic procedure (19). Our protocol only used 0.5 mL aliquots. Future investigations could consider determining whether there is a smaller volume to yield a more precise definitive selectivity and will use a larger sample size as suggested by our power analysis.

CONCLUSION

Diagnostic LS-TFESIs or SNRBs limiting injectate to a single, ipsilateral segmental level cannot reliably be considered diagnostically selective with volumes exceeding 0.5 mL. Injectate volumes greater than 0.5 mL are consistently non-selective and cannot be used reliably for diagnostic "block" procedures in the epidural space. The term "selective" when performing interventional spine pain procedures for diagnostic benefit should not be used without closely describing the injection technique and injectate volume. This study does not address contrast flow when performing "selective spinal nerve blocks" (a technique of instilling injectate intraforaminally or lateral to the intervertebral foramen with no flow entering the epidural space). Also, the intent of this study was not to determine the proper volume for therapeutic procedures when using a transforaminal approach, but to quantify the volume at which contrast flow is no longer selective for the specified root level. Further research is needed to

determine recommended therapeutic volumes of injectate to selectively treat spinal pain pathology that correlates anatomically with the patient's clinical and radiographic examinations.

REFERENCES

1. Dooley JF, McBoon RJ. Nerve root infiltration in the diagnosis of radicular pain. *Spine* 1988; 13:79-83.
2. Bogduk N. *Practice Guidelines Spinal Diagnostic Treatment and Procedures First Ed.* International Spine Intervention Society, San Francisco, 2004 p18-19.
3. Aspinall S, Mohammed S. The value of nerve root injection in the evaluation of sciatica in patients with normal MRI scans. *J Bone Joint Surg* 2000; 82B: 279.
4. Herron LD. Selective nerve root block in patient selection for lumbar surgery: Surgical results. *J Spinal Dis* 1989; 2:75-79.
5. Vassiliev D. Spread of contrast during L4 and L5 nerve root infiltration under fluoroscopic guidance. *Pain Physician* 2007; 10:461-466.
6. Ohtori S, Takahashi K, Moriya H, Myers RR. TNF alpha and TNF alpha receptor type I upregulation in glia and neurons after peripheral nerve injury. *Spine* 2004; 29: 1082-1088.
7. Bogduk N. *Practice Guidelines Spinal Diagnostic Treatment and Procedures First Ed.* International Spine Intervention Society, San Francisco, 2004 p177.
8. Kelsey JL, White AA. Epidemiology and impact of low-back pain. *Spine* 1980; 5:133-142.
9. Bogduk N. *Practice Guidelines Spinal Diagnostic Treatment and Procedures First Ed.* International Spine Intervention Society, San Francisco, 2004 p170.
10. Aoki Y, Ohtori S, Takahashi K. Innervation of the lumbar intervertebral disc by nerve growth factor-dependent neurons related to inflammatory pain. *Spine* 2004; 29:1077-1081.
11. Fenton DS, Czervionke LF. *Image-Guided Spine Intervention.* Saunders, Philadelphia, 2003 p74.
12. Bogduk N, Aprill C, Derby R. Selective Nerve Root Blocks. In: Wilson DJ (ed). *Interventional Radiology of the Musculoskeletal System.* Edward Arnold, London, 1995, ch 10, pp 121-132.
13. Bogduk N, Aprill C, Derby R. Epidural Steroid Injections. In: White AH (ed). *Spine Care, Volume One: Diagnosis and Conservative Treatment.* Mosby, St. Louis, 1995, ch 22, pp 322-343.
14. Smuck M, Fuller BJ. Letter to the editor re: 'letter to the editor' re: incidence of simultaneous epidural and vascular injection during lumbosacral transforaminal epidural injections. *Spine J* 2007; 7:749.
15. Manchikanti L, Singh V. Letter to the editor re: incidence of simultaneous epidural and vascular injection during lumbosacral transforaminal epidural injections. *Spine J* 2007; 5: 629-630.
16. Wolff AP, Gerbrangd GJ, Wilder-Smith, OH. Influence of needle position on lumbar segmental nerve root block selectivity. *Reg Anesth Pain Med* 2006; 31:523-530.
17. Whitlock EL, Bridwell KH, Gilula LA. Influence of needle tip position on injectate spread in 406 interlaminar lumbar epidural steroid injections. *Radiology* 2007; 3:804-811.
18. Blomberg R. The dorsomedian connective tissue band in the lumbar epidural space of humans: An anatomical study using epiduroscopy in autopsy cases. *Anesth Analg* 1986; 65:747-752.
19. Furman MB, O'Brien EM. Is it really possible to do a selective nerve root block? *Pain* 2000; 85:526.

ACKNOWLEDGMENTS

We acknowledge Wendy Fuhrman for data collection assistance and Rod Grim, MA, Ted Bell, MS and Kristin Judy, MA, of the Emig Research Center at York Hospital, for statistical analysis assistance.

