

**Cadaveric Study**

## **Confirmation of Needle Placement Within the Piriformis Muscle of a Cadaveric Specimen Using Anatomic Landmarks and Fluoroscopic Guidance**

Peter Gonzalez, MD, Michelle Pepper, MD, William Sullivan, MD,  
and Venu Akuthota, MD

From: University of Colorado School of  
Medicine, Aurora, CO.

Dr. Gonzalez is Assistant Professor, The  
Spine Center, University of Colorado,  
School of Medicine, Aurora, CO.

Dr. Pepper is with the the University  
of Colorado Health Sciences Center,  
Aurora, CO.

Dr. Sullivan is Associate Professor,  
University of Colorado, School of  
Medicine, Aurora, CO.

Dr. Akuthota is an Associate Professor  
and Pain Fellowship Director of  
Physical Medicine and Rehabilitation  
at the University of Colorado School of  
Medicine, Aurora, CO.

Address correspondence:  
Peter Gonzalez, MD  
University of Colorado  
School of Medicine  
PMR

PO Box 6511, Mail Stop F-493  
Aurora, CO 80045

E-mail: peter.gonzalez@uchsc.edu

Disclaimer: There was no external  
funding in the preparation of this  
manuscript.

Conflict of interest: None.

Manuscript received: 02/27/2008

Revised manuscript received:

03/28/2008

Accepted for publication: 04/01/2008

Free full manuscript:  
[www.painphysicianjournal.com](http://www.painphysicianjournal.com)

Of patients presenting to pain clinics, complaints are of low back or buttock pain with or without radicular leg symptoms is one of the most common. Piriformis syndrome may be a contributor in up to 8% of these patients. The mainstay of treatment is conservative management with physical therapy, anti-inflammatory medications, muscle relaxants, and correction of biomechanical abnormalities. However, in recalcitrant cases, a piriformis injection of anesthetic and/or corticosteroids may be considered. Because of its small size, proximity to neurovascular structures, and deep location, the piriformis muscle is often injected with the use of computed tomography (CT), magnetic resonance imaging (MRI), ultrasound (US), fluoroscopy, electrical stimulators, or electromyography (EMG). Numerous techniques have been proposed using one or a combination of the above modalities. However, application of these techniques is limited by unavailability of CT, MRI, and EMG equipment as well as a paucity of trained physicians in US-guided procedures in many pain treatment centers throughout the United States. Fluoroscopy, however, is more widely available in this setting.

This study utilized a cadaveric specimen to confirm proper needle placement for piriformis or peri-sciatic injection utilizing the previously documented landmarks for fluoroscopic guidance as described by Betts. An anteroposterior of the pelvis with inclusion of the acetabular region of the hip and the inferior aspect of the sacroiliac joint was obtained. The most superior-lateral aspect of the acetabulum and the inferior aspect of the sacroiliac joint were identified. A marker was placed one-third of the distance from the acetabular location to the inferior sacroiliac joint, indicating the target location. A 22-gauge, 3.5-inch spinal needle was directed through the gluteal muscles to the target location using intermittent fluoroscopic guidance. The posterior ileum was contacted and the needle was withdrawn 1 –2 mm. This approach found the needle within the piriformis muscle belly 2 –3 cm lateral to sciatic nerve. The present study was the first study, to our knowledge, that has confirmed the intramuscular position of the needle within the piriformis muscle of a cadaveric specimen using these anatomic landmarks and fluoroscopic guidance.

**Key words:** piriformis syndrome, back pain, fluoroscopy, sciatica

**Pain Physician 2008; 11:3:327-331**

**L**ow back or buttock pain with or without radicular leg symptoms is extraordinarily common in pain clinics. Piriformis syndrome may be a contributor in up to 8% of patients presenting with low back pain complaints (1). Parziale et al (2) published 6 cardinal features of a piriformis syndrome:

- 1) history of trauma to the gluteal or sacroiliac region,
- 2) pain in the region of SI joint, greater sciatic notch, and piriformis muscle extending down the leg and causing difficulty walking,
- 3) acute exacerbation of pain by stooping or lifting and moderately relieved by traction,
- 4) palpable, sausage-shaped mass over the piriformis which is tender to palpation,
- 5) positive Lasegue sign, and
- 6) possible gluteal atrophy.

Due to the diagnostic confusion surrounding the term piriformis syndrome, others have attempted to categorize the different clinical entities. The 4 distinct entities as described by Stewart (3) include

- 1) damage to the proximal sciatic nerve by lesions in the vicinity of the piriformis,
- 2) compression damage to the proximal sciatic nerve by the piriformis,
- 3) damage to the sciatic nerve by the piriformis and adjacent tissues from trauma and scarring, and
- 4) chronic buttock pain with no evidence of sciatic nerve damage.

The piriformis muscle originates along the anterior surface of the sacrum and travels posterolaterally through the sciatic notch to insert upon the greater trochanter. It functions as a primary external rotator of the hip when the hip is in the neutral position and an abductor of the hip in hip flexion in an open kinetic chain. In the closed kinetic chain it acts as a hip extensor and external rotator. Hypertrophy or increased muscle tone of the piriformis muscle, as seen following trauma or in persons participating in sporting activities which require excessive use of gluteal muscles, may occur. A resultant compression of the sciatic nerve can result in a sciatic neuropathy with symptoms radiating down the posterior leg to the foot.

The sciatic nerve arises from the lumbosacral plexus (L4-S3) and, typically, exits through the inferior part of the sciatic notch, inferior to the piriformis muscle. Six anatomic variants of the sciatic nerve as it exits the sciatic notch have been described from cadaveric studies. The anatomic variants observed

include:

- 1) undivided sciatic nerve passing below the piriformis muscle,
- 2) divided nerve passing through and below the piriformis muscle,
- 3) divided nerve passing above and through the piriformis muscle,
- 4) divided nerve passing above and below the piriformis muscle,
- 5) undivided nerve passing through the piriformis muscle, and
- 6) undivided nerve passing above the piriformis muscle.

By far the majority of dissections show the undivided sciatic nerve passing below the piriformis muscle (78 – 98.5%) followed by a divided nerve passing through and below the piriformis muscle (12 – 21%) (4-6).

The mainstay of treatment is conservative management with physical therapy, anti-inflammatory medications, muscle relaxants, and correction of biomechanical abnormalities. However, in recalcitrant cases, a piriformis (or peri-sciatic nerve) injection of anesthetic and/or corticosteroids may be considered for either diagnostic or therapeutic purposes. Because of its small size, proximity to neurovascular structures, and deep location, the piriformis muscle is often injected with the use of computed tomography (CT), magnetic resonance imaging (MRI), ultrasound (US), fluoroscopy, electrical stimulators, or electromyography (EMG). Numerous techniques have been proposed using one or a combination of the above modalities. However, application of these techniques is limited by unavailability of CT, MRI, and EMG equipment as well as paucity of trained physicians in US-guided procedures in many pain treatment centers throughout the United States. Fluoroscopy, however, is more widely available in this setting.

The purpose of the present study is to further investigate a previously reported piriformis injection technique (7) with the goal to document the intramuscular position within the piriformis muscle using anatomic landmarks and fluoroscopic guidance.

## **TECHNIQUE**

A previously reported injection technique for piriformis injections under fluoroscopic guidance is described by Betts (7). This technique is performed under fluoroscopy with electrical stimulator guidance. The fluoroscopic view includes an AP of the pelvis with inclusion of the acetabular region of the hip and the

inferior aspect of the sacroiliac joint. The most superior-lateral aspect of the acetabulum and the inferior aspect of the sacroiliac joint are identified. A marker is placed one-third of the distance from the acetabular location to the inferior sacroiliac joint, indicating the target location. Following administration of local anesthetic to the skin and soft tissues, a 22-gauge insulated needle is advanced with both fluoroscopic and electrical stimulator guidance to ensure safe passage to the piriformis muscle without contacting the sciatic nerve. Care is taken to monitor for lower extremity paresthesias or contractions of the leg muscles innervated by the sciatic nerve and its main motor branches. Please refer to the original article for details regarding electrical stimulation parameters. In some instances, the needle can be advanced to contact the posterior ilium and then withdrawn slightly, 1 – 2 mm, entering the piriformis muscle. The electrical stimulator is used to confirm the intramuscular location of the needle within the piriformis muscle by monitoring subtle motion of the needle without overt gluteal contractions. Further confirmation is obtained following the abolition of the motor twitch after anesthetic administration. One ml of radiographic contrast material is injected to obtain a piriformis myogram. After a negative aspiration of blood, 3 mL of 0.25% bupivacaine with or without corticosteroid is administered.

The present study of the above stated technique was performed on a cadaveric specimen with fluoroscopic guidance to document the needle placement in the piriformis muscle strictly using the anatomic landmarks described above. An electrical stimulator was not used. The gluteal region of the cadaver had previously been dissected. The superficial, large gluteal muscles remained attached medially and were able to be reflected back to reveal the deep external rotators of the hip including the piriformis muscle and its relation to the sciatic nerve. The piriformis muscle remained attached to its origin on the anterior sacrum, but its lateral insertion to the greater trochanter was disrupted. Prior to the injection, malleable metallic wiring was placed to outline the superior and inferior borders of the piriformis muscle. A third metallic marker was placed along the sciatic nerve from its point of exit from the piriformis muscle. The gluteal structures were approximated to their anatomic positions. The anatomic landmarks of the inferior sacroiliac joint and the superior-lateral acetabulum were identified using fluoroscopy. As stated above, the target point was one-third the distance from the acetabular landmark to the inferior sacroiliac joint. A 22-gauge, 3.5-inch spinal needle was directed through the gluteal muscles to the target location using intermittent fluoroscopic guidance. The posterior ilium was contacted and the needle was withdrawn 1 – 2 mm (Fig. 1). No further movements of

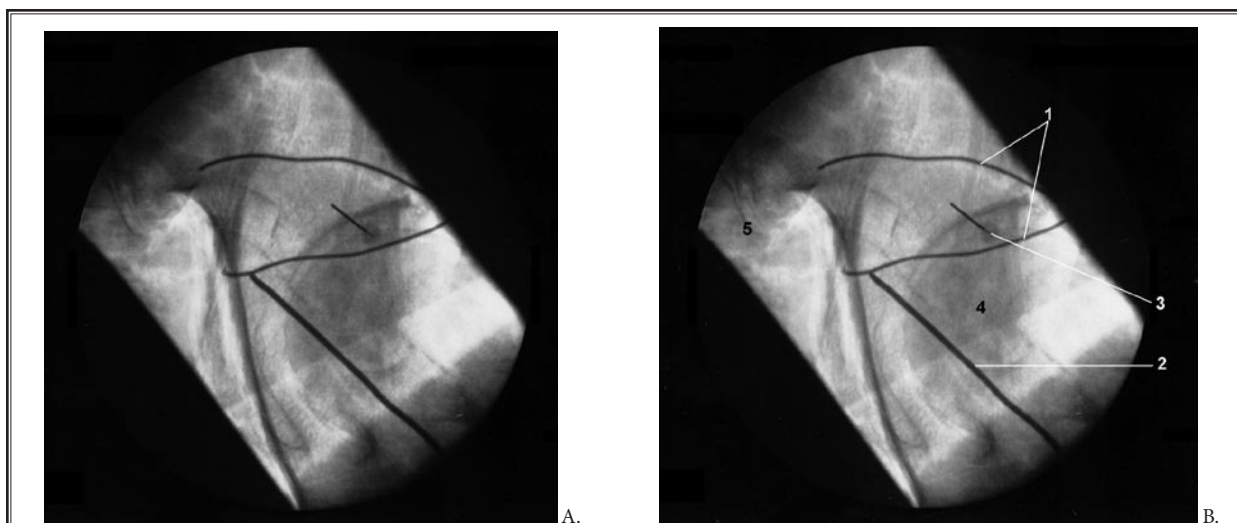


Fig. 1. *A: Fluoroscopic image of described technique on cadaveric specimen. B: Identification of anatomic markers: 1 = metallic wiring outlining piriformis muscle; 2 = metallic wiring outlining lateral border of sciatic nerve; 3 = spinal needle located within the piriformis muscle belly, 2 – 3 cm lateral to sciatic nerve; 4 = femoral head; 5 = inferior aspect of SI joint.*

the needle were made. The superficial gluteal muscles, including the gluteus maximus and medius, were reflected back slightly to identify the final location of the needle. The needle location was documented within the piriformis muscle belly 2 – 3 cm lateral to sciatic nerve.

## Discussion

This study utilized a cadaveric specimen to confirm proper needle placement for piriformis or perisciatic injection utilizing the previously documented landmarks for fluoroscopic guidance as described by Betts (7). Early piriformis injections were made blindly. Pace and Nagle (8) described a technique with the patient in a lateral decubitus position with the affected side up and needle directed to the tender muscle as identified through either intra-rectal or vaginal palpation. In a small study of 6 subjects, Hanania and Kitain (9) utilized an electrical stimulator for location of and injection near the sciatic nerve. The patient was placed in the lateral decubitus or semi-prone position with the affected side up and with hip and knee flexed. This technique provided relief to all 6 of the subjects for up to 18 months. Smith et al (10) have also described a technique for ultrasound guided injections for those physicians with this training. Fishman et al (11) attempted identification of the piriformis muscle by fluoroscopic and EMG guidance. They placed the patient in a prone position and used the greater trochanter, lateral border of the sacrum, and the SI joint as landmarks. Placement of the needle within the piriformis muscle was confirmed with EMG and injection of radiopaque contrast media under fluoroscopy. They found relatively reproducible results with this method, however did not document the depth of the injection nor the patient response to this injection method.

Benzon et al (5) performed a cadaveric study of 36 cadavers looking at the anatomic relationships of and variations in the sciatic nerve, piriformis, and sacroiliac joint. They retrospectively reviewed charts of 19 patients receiving piriformis injection and noted the site of needle insertion with relation to the lower border of the SI joint and the depth of needle insertion that elicited a motor response in the foot with electrical stimulation, indicating stimulation of the sciatic nerve. Of the 66 gluteal dissections (30 bilateral and 6 unilateral) 65 demonstrated sciatic nerve exit anterior and inferior to the piriformis. Only one dissection revealed an anatomic variation (bipartite

piriformis muscle with the tibial portion of the sciatic nerve exiting below the piriformis and the peroneal component passing between the 2 heads) confirming the rarity of anatomic variations believed to result in piriformis syndrome. They described an injection technique at a distance of approximately 1.5 cm lateral and 1.2 cm caudal to the lower border of the SI joint and a depth of 9 cm. The location for the injection as described by Benzon et al (5) is medial to the injection technique as described by Fishman et al (11). Anatomic location of the sciatic nerve from the cadaveric study found it to lay approximately 3 cm lateral and 1 cm caudal to the lower border of the SI joint.

Still others have published studies looking at CT guidance in the identification of the piriformis muscle. Fanucci et al (12) describes a CT-guided technique using 100 units of botulinum toxin type A, 87% of patients reported relief of their symptoms within 5 to 7 days. The remainder received an additional injection which was successful. MRI performed at follow-up 3 months later revealed signal intensity changes consisted with a denervative process or muscle atrophy within the treated piriformis muscle. Porta (13) described a similar technique with CT guidance comparing botulinum toxin type A and methylprednisolone injection followed by physical therapy. Other studies (14,15) looking at injection of botulinum toxin have used similarly described EMG and/or fluoroscopic guidance techniques with good results.

This present study further investigated Betts' above mentioned study (7) which used a combined fluoroscopic and electrical stimulator technique. The original technique placed the patients prone on a fluoroscopy table and an AP view of the hemi-pelvis and acetabular region was obtained. A metallic marker was placed a third of the distance on the line from the most inferior part of the SI joint to the most superior-lateral aspect of the acetabulum. Using electrical stimulation, the needle was advanced through the gluteal muscles until stimulation did not produce gluteal twitch, but only a twitch at the needle hub. The posterior (dorsal) surface of the ileum occurred in some cases and the needle was withdrawn slightly. The patients reported any lower extremity paresthesias and were monitored for contractions of the calf or foot (indicating too close proximity to the sciatic nerve). Radiographic contrast was injected to ensure a satisfactory myographic pattern.

## CONCLUSION

The present study was the first study, to our knowledge, that has confirmed the intramuscular position of the needle within the piriformis muscle of a cadaveric specimen using the above stated anatomic landmarks and fluoroscopic guidance. The final needle position within the piriformis muscle was

observed and documented to be lateral to the sciatic nerve. However, due to potential anatomic variations, further studies are needed on multiple specimens to determine if this technique could be consistently and safely performed under fluoroscopy without electrical stimulation guidance.

## REFERENCES

1. Hallin R. Sciatic pain and the piriformis muscle. *Postgrad Med* 1983; 74:69-72.
2. Parziale JR, Hudgins TH, Fishman LM. The piriformis syndrome. *Am J Orthop* 1996; 25:819-823.
3. Stewart JD. The piriformis syndrome is overdiagnosed. *Muscl Nerve* 2003; 28:644-649.
4. Beason LE, Anson BJ. The relation of the sciatic nerve and its subdivisions to the piriformis muscle. *Anat Rec* 1937; 70:1-5.
5. Benzon HT, Katz JA, Benzon HA, Iqbal MS. Piriformis syndrome: Anatomic considerations, a new injection technique, and a review of the literature. *Anesthesiology* 2003; 98:1442-1448.
6. Pecina M: Contribution to the etiological explanation of eh piriformis syndrome. *Acta Anat* 1979; 105:181-187.
7. Betts A. Combined fluoroscopic and nerve stimulator technique for injection of the piriformis muscle. *Pain Physician* 2004; 7:279-281.
8. Pace JB, Nagle D. Piriformis syndrome. *Western J Med* 1976; 124:435-439.
9. Hania M, Kitain E. Perisciatic injection of steroid for the treatment of sciatica due to piriformis syndrome. *Region Anesth Pain M* 1998; 23:223-228.
10. Smith J, Hurdle MF, Locketz AJ, Wisniewski SJ. *Arch Phys Med Rehab* 2006; 87:164-167.
11. Fishman SM, Caneris OA, Bandman TB, Audette JF, Borsook D. Injection of the piriformis muscle by fluoroscopic and electromyographic guidance. *Region Anesth Pain M* 1998; 23:554-559.
12. Fanucci E, Masala S, Sodani G, Varruciu V, Romagnoli A, Squillaci E, Simonetti G. CT-guided injection of botulinic toxin for percutaneous therapy of piriformis muscle syndrome with preliminary MRI results about denervative process. *Eur Radiol* 2001; 11:2543-2548.
13. Porta M. A comparative trial of botulinum toxin type A and methylprednisolone for the treatment of myofascial pain syndrome and pain from chronic muscle spasm. *Pain* 2000; 85:101-105.
14. Childers MD, Wilson DJ, Gnatz SM, Conway RR, Sherman AK. Botulinum toxin type A use in piriformis muscle syndrome: A pilot study. *Am J Phys Med Rehab* 2002; 81:751-759.
15. Fishman LM, Anderson C, Rosner B. BOTOX and physical therapy in the treatment of piriformis syndrome. *Am J Phys Med Rehab* 2002; 81:936-942.

