

## Cross-sectional Study



## Six-Month Results of Cervical Intradiscal Oxygen-Ozone Mixture Therapy on Patients with Neck Pain: Preliminary Findings

Serbüent Gökhan Beyaz, MD<sup>1</sup>, and Havva Sayhan Kaplan, MD<sup>2</sup>

From: <sup>1</sup>Department of Anesthesiology and Pain Medicine, Sakarya University Faculty of Medicine, Turkey; <sup>2</sup>Department of Anesthesiology and Reanimation, Yuzuncu Yil University School of Medicine, Turkey

Address Correspondence: Serbüent Gökhan Beyaz, MD Sakarya University Training Research Hospital, Korucuk Campus, Anesthesiology and Pain Medicine 54290, Adapazari Sakarya, Republic of Turkey E-mail: sgbeyaz@gmail.com

Disclaimer: There was no external funding in the preparation of this manuscript.

Conflict of interest: Each author certifies that he or she, or a member of his or her immediate family, has no commercial association (i.e., consultancies, stock ownership, equity interest, patent/licensing arrangements, etc.) that might pose a conflict of interest in connection with the submitted manuscript.

Manuscript received: 06-28-2017  
Revised manuscript received: 02-26-2018  
Accepted for publication: 03-06-2018

Free full manuscript: [www.painphysicianjournal.com](http://www.painphysicianjournal.com)

**Background:** Numerous techniques have been developed for the treatment of disc herniation. Oxygen-ozone (O<sub>2</sub>-O<sub>3</sub>) mixture therapy is a minimally invasive percutaneous treatment for disc herniation.

**Objective:** The aim of the study is to investigate the 6-month efficacy and safety of O<sub>2</sub>-O<sub>3</sub> mixture therapy in patients with cervical disc herniation (CDH) and chronic neck pain.

**Study Design:** This is a cross-sectional, single-center study.

**Setting:** The study was conducted from January 2012 to May 2016 on patients visiting Sakarya University Training and Research Hospital's pain clinic.

**Methods:** Each patient was evaluated before the procedure (baseline) and at 2 weeks (W2), 6 weeks (W6), and 6 months (M6) after the procedure using the visual analog scale (VAS) and the Oswestry Disability Index scores.

**Results:** A total of 44 patients with CDH underwent the same treatment with an O<sub>2</sub>-O<sub>3</sub> mixture. Significant pain relief was observed compared with preoperative pain at W2, W6, and M6 according to patient self-evaluation ( $P = 0.01$ ). The mean VAS score was  $7.89 \pm 1.13$  before the procedure,  $4.22 \pm 1.62$  at W2,  $3.03 \pm 1.66$  at W6, and  $2.27 \pm 1.25$  at the end of M6. No significant complications or side effects were reported during or after the procedure.

**Limitations:** Our study was conducted retrospectively, which resulted in problems obtaining follow-up data. In addition, this study was performed in a small patient group.

**Conclusion:** Based on our results, intradiscal injection of an O<sub>2</sub>-O<sub>3</sub> mixture treatment showed a beneficial long-term effect.

**Key words:** Cervical disc herniation, chemonucleolysis, injection, intradiscal, oxygen-ozone mixture, percutaneous treatment

**Pain Physician 2018; 21:E449-E456**

Cervical radiculopathy is an abnormal process involving the nerve root, caused mostly by cervical disc herniation or cervical spondylosis. Symptoms of cervical radiculopathy include neck and brachial-radicular pain (with or without motor weakness or paresthesia) in 80–100% of patients (1). Partial removal of the nucleus has been shown to decompress herniated discs (HD), relieving pressure on nerve roots and, in some cases, relieving disc pain (2).

Stookey (3) described the clinical symptoms and anatomic location of cervical disc herniation (CDH) in 1928. Mixer and Barr (4) established a relationship between HD and sciatica and showed that laminectomy and disc excision could relieve pain associated with radiculopathy. Hijikata (5) first described percutaneous lumbar discectomy and Ascher (6) reported the use of laser discectomy. Considering these studies with the same indications, several other percutaneous techniques have been applied. Ozone

injection into the intradiscal and paraspinal spaces can be used to relieve pain by blocking the release of inflammatory factors and directly expanding the blood vessels to improve local circulation and reduce local nerve root edema and conglutination (7).

Several techniques have been developed to treat disc herniation (8). Percutaneous techniques such as percutaneous discectomy, laser discectomy, and nucleoplasty have minimized the invasive nature of these surgeries and decreased complications such as postsurgical infection (9-12).

To avoid prolonged suffering from unsuccessful conservative treatment and to minimize the morbidity associated with open surgery, many surgeons have explored alternative methods of decompressing a pathological disc. Intradiscal injection of ozone (O<sub>3</sub>) gas was first proposed in the 1980s as a treatment for disc herniation (13). Oxygen-ozone (O<sub>2</sub>-O<sub>3</sub>) mixture therapy is a minimally invasive treatment for disc herniation that exploits the biochemical properties of ozone. The O<sub>2</sub>-O<sub>3</sub> mixture not only oxidizes proteoglycan in the nucleus pulposus leading to shrinkage of the disc that is compressing the nerve roots but also provides anti-inflammatory effects and pain relief (14).

Our cross-sectional study evaluated the results of O<sub>2</sub>-O<sub>3</sub> treatment for CDH and demonstrated the effectiveness of O<sub>2</sub>-O<sub>3</sub> therapy in treating CDH in symptomatic patients.

## METHODS

This is a cross-sectional, observational, single-center study that included 44 patients who were treated with an O<sub>2</sub>-O<sub>3</sub> mixture at Sakarya University Training and Research Hospital, Turkey. Sakarya University's Faculty of Medicine Review Board (71522473/050.01.04/148) approved the study and it was registered on www.ClinicalTrials.gov (NCT03056911).

## Patients

The study was conducted between Jan. 1, 2012 and May 31, 2016 on patients visiting the pain clinic. Patients typically experienced cervical discogenic or radicular pain that was unresolved after conventional treatment or cervical interlaminar/transforaminal epidural steroid injection therapy. Written informed consent was obtained from all patients. A sample of 44 patients who underwent O<sub>2</sub>-O<sub>3</sub> mixture therapy were evaluated and observed until the end of the follow-up period (6 months); patients were excluded if they did not remain in the study for 6 months.

The inclusion criteria were age 18 to 65 years and visual analog scale (VAS) scores of pain between the extremity limits (0 = no pain and >10 = worst pain imaginable), such as a sustained nerve root pain > 4/10 in the upper leg and spreading over a period of ≥ 12 weeks.

Exclusion criteria included any contraindication (coagulopathy or infection) to percutaneous chemonucleolysis techniques, any medical condition or treatment pain, drug allergy, imaging results not supporting the clinical results, the presence of cervical surgery, and incomplete data collection.

By combining anti-inflammatory drugs and physical therapy, conservative treatment can be beneficial. In addition, pressure on the nerve root associated with clinical pain was confirmed based on CT and MR imaging.

## STUDY DESIGN

This study was designed to evaluate the 6-month clinical effects of intradiscal O<sub>2</sub>-O<sub>3</sub> mixture treatment in CDH patients. Information from the medical records and from the hospital electronic record system were used to gather data (in terms of age, gender, and related complications).

During the pre-procedure time intervals (baseline) and at 2 weeks (W2), 6 weeks (W6), and 6 months (M6) after the procedure, we estimated the pain level of each patient based on the VAS and the Oswestry Disability Index (ODI) scores to measure the degree of disability and estimate quality of life for those with pain.

A researcher who was not involved in the study called the patients to the hospital to collect relevant information, interviewed each patient, and recorded side effects and adverse events after the procedure.

## Technique

Procedures were performed under fluoroscopy guidance and aseptic conditions with conscious sedation (C-arm x-ray system, Siemens Healthcare, GY).

A total of 50 µg of fentanyl (Talinat, Vem, TUR) and 2 mg of midazolam (Dormicum, Roche, GY) were applied for sedation, and lidocaine (Aritmal, Osel, TUR) was applied for cutaneous and subcutaneous local anesthesia. One hour before the procedure, 80 mg of gentamicin sulfate (Genta, I. E. Ulugay, TUR) was administered as a prophylactic antibiotic injection.

The patient was extended on the operating table in the prone position and a pillow was placed under his/her shoulders for neck flexion. Next, 16 mg dexamethasone (Dekort, Deva Holding Inc., TR) and 2 mL 0.5%

Bupivacaine (Bustesin 0.5% Vem, TR) were injected into the epidural space from C6-7 or into the C7-T1 interlaminar space under fluoroscopy guidance.

The patient was brought to a supine position for the procedure and a pillow was placed underneath of the neck and shoulders, resulting in a minor hyperextension. All interventions were performed with a 22-gauge/10-cm spinal needle. An anterolateral approach was used to place the needle into the intervertebral disc space. A right-sided approach was preferred in all cases due to the presence of a left esophagus.

The spinal needle was injected through the larynx and jugular-carotid vessels with laryngeal subluxation until reaching the anterior longitudinal ligament with continuous longitudinal fluoroscopic control. The needle was then moved forward towards the center of the disc area. The needle location was confirmed by anterior-posterior oblique and lateral images under fluoroscopy guidance (Fig. 1). A total of 4 to 5 mL of O<sub>2</sub>-O<sub>3</sub> mixture was injected at a concentration of 20 µg/mL. After injection, fluoroscopic imaging was repeated, and the procedure was concluded.

### Post-procedural Care

Patients were monitored for half an hour after the procedure in the post-anesthetic care unit, and were then transferred to the pain service. Three hours after injection, PA and lateral radiographic images were obtained for all patients. Patients were then discharged without any complications and were told to take an anti-inflammatory, antibiotic, and analgesic drug for 10 days. A soft cervical collar was prescribed for 3 days to limit movement of the neck and provide splinting and rest in a relaxed position. Three months after the procedure, the control BT scan was requested.

### Statistical Analysis

Analysis was performed on the VAS, ODI, and DN-4 values collected from all patients before treatment and at W2, W6, and M6 postoperatively. To detect statistically significant changes in the VAS and ODI scores during the post-treatment period compared to the pre-treatment period, we used a paired t test and Wilcoxon matched-pairs signed rank test.

Differences between pain intensities at the 4 time points (baseline, W2, W6, and M6) and between each time and residual pain were assessed using the Kruskal-Wallis or Mann-Whitney test. The influence of categorical variables (gender, disc level, location of the herniation, etc.) was assessed using the t-test, Mann-Whitney

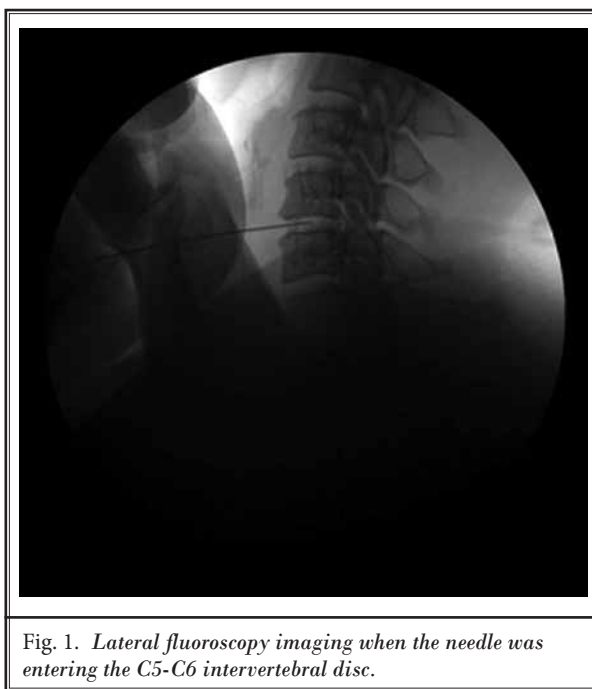


Fig. 1. Lateral fluoroscopy imaging when the needle was entering the C5-C6 intervertebral disc.

test (for multiple comparisons), or the Kruskal-Wallis test followed by Dunn's multiple comparisons test (if the Kruskal-Wallis test was globally significant). Differences in pain intensity across groups defined by the above variables were assessed using the Kruskal-Wallis test (in the event of a significant difference) followed by Dunn's multiple comparisons test. *P*-values < 0.05 were considered significant. We computed 95% confidence intervals (95% CIs). Statistical analyses were performed using SPSS (version 9.0; SPSS, Chicago, IL, USA).

### RESULTS

This cross-sectional observational study was designed to analyze the success of intradiscal injections of an O<sub>2</sub>-O<sub>3</sub> mixture in patients with CDH. Patients were interviewed in person using a follow-up questionnaire. Forty-four [16 men (36.4%) and 28 women (63.6%)] of the 78 (56.4%) were contacted, while the remaining patients did not answer the follow-up questionnaire (*n* = 34) due to either a missed phone call or not wanting to respond. Table 1 summarizes the baseline demographic and clinical characteristics of the 44 patients.

Clinical success with O<sub>2</sub>-O<sub>3</sub> therapy was defined as a 2- and 15-point decrease in the respective VAS and ODI scores compared with baseline values at W2, W6, and M6 after treatment. Successful outcomes were obtained, with patients reporting pain relief at a rate of 93.1%, 95.4%, and 97.7% at W2, W6, and M6, respec-

Table 1. Baseline demographic and clinical characteristics of all patients (n = 44).

Demographics	Baseline (Mean ± SD)
Age, year	
• mean ± SD	47.34 ± 12.38
• range	28-65
BMI (kgm <sup>2</sup> )	
• mean ± SD	25.63 ± 3.21
• range	20.06-32.89
Gender, n (%)	
• Female	28 (63.6%)
• Male	16 (36.4%)
Duration of pain, n (%)	
• < 6 months	8 (18.2%)
• 6 months-1 year	10 (22.7%)
• 1-5 years	20 (45.5%)
• > 5 years	6 (13.6%)
Previous treatment, n (%)	
• pharmacology	44 (100%)
• physical therapy	23 (52.3%)
• other*	4 (9.1%)
• none	0
• Pre-treatment surgery	0
Indication for surgery, n (%)	
• Disc lesion location, n (%)	9 (20.4%)
• C3-C4	2 (4.5%)
• C4-C5	10 (22.7%)
• C5-C6	37 (84.1%)
• C6-C7	24 (54.5%)
• More than single level	25 (56.8%)

Abbreviations: O<sub>2</sub>-O<sub>3</sub>, oxygen-ozone mixture treatment; W2, post-operative 2 weeks; W6, post-operative 6 weeks; M6, post-operative 6 months; Baseline, pre-operative; SD, standard deviation; BMI, body mass index.

\*Chiropractic, mesotherapy, acupuncture, paravertebral infiltration;

\*\*more than one herniation at different spinal levels

tively. Only 1 patient (2.2%) experienced failure in pain control (a poor outcome). The clinical efficacy rates were also evaluated based on patient satisfaction using a 4-grade scale where 1 shows the least satisfaction and 4 shows the highest satisfaction at the final check. After 6 months, 61.3% of patients were extremely satisfied, 27.3% were fairly satisfied, 9.1% were moderately satisfied, and 2.3% were poorly satisfied.

Evaluations of pain intensity values on the VAS and ODI scores at baseline and at W2, W6, and M6 after

the procedure are shown in Figs. 2 and 3, respectively. The mean VAS score was 7.89 ± 1.13 before the procedure, 4.22 ± 1.62 at W2, 3.03 ± 1.66 at W6, and 2.27 ± 1.25 at M6. Statistically significant differences were achieved following treatment when the baseline VAS scores were compared to VAS scores at all follow-up periods (Table 2). The average improvement in the VAS score was 3.68 ± 2.08 points at W2, 4.87 ± 2.10 points at W6, and 5.77 ± 1.94 points at M6. The *P*-value was < 0.0001 for all follow-up points. Furthermore, statistically significant differences were observed between the follow-up periods (*P* < 0.05). Thus, a 73.1% decrease in the average VAS score was observed compared with the baseline values at the final follow-up. As shown in Table 2, statistically significant improvements in the functional status of the patients was achieved based on a 68.9% reduction in the ODI score. The average reduction of ODI from baseline to W2, W6, and M6 was 17.57 ± 6.10, 23.27 ± 5.59, and 28.04 ± 4.04, respectively, with a *P*-value of < 0.0001 (Table 3).

No significant complications or side effects were reported during or after the procedure. After the procedure, one of the patients (2.2%) reported hoarseness and was referred to a specialist, but showed spontaneous improvement over a period of 1 week without any medication. Some of the patients reported discomfort such as sore throat, dysphagia, neck stiffness, and transient increases in pain of CDH after their procedure. These minor side effects spontaneously resolved within the day of the procedure or within one day, and no patients required hospital admission for management.

## DISCUSSION

Minimally invasive approaches for CDH include intervertebral disc discectomy, chemonucleolysis (O<sub>2</sub>-O<sub>3</sub> mixture, radiopaque gelified ethanol, etc.), laser decompression, and radiofrequency ablation (15). Satisfactory clinical outcomes with good patient compliance, cost effectiveness, and decreased length of patient hospital stay are potential benefits of these approaches. Recent studies are exploring O<sub>2</sub>-O<sub>3</sub> therapy for CDH, but studies examining the lumbar disc are more common. Intradiscal ozone therapy has been used to provide long-term relief of lumbar back pain (16). However, current studies have only evaluated the efficacy and safety of intradiscal ozone injection therapy for CDH. This study was designed to evaluate the efficacy of intradiscal O<sub>2</sub>-O<sub>3</sub> mixture chemonucleolysis therapy for CDH.

The suspected mechanism of this method is shrinkage of the nucleus pulposus structure of the HD, as well

as the ability of the O<sub>2</sub>-O<sub>3</sub> mixture to block intraforaminal inflammation so that pain intensity decreases. The treatment mechanism is oxidization of proteoglycans in the nucleus by the O<sub>2</sub>-O<sub>3</sub> mixture. Proteoglycans are one of the major components of the macromolecular material in the nucleus and the main factor maintaining the osmotic pressure and water in the nucleus. After injecting the O<sub>2</sub>-O<sub>3</sub> mixture, the proteoglycans are oxidized directly, and this is thought to destroy the amino acid and CH groups in the proteoglycan complex, which loses fixing charge density. Osmotic pressure then decreases, and water is lost. The O<sub>2</sub>-O<sub>3</sub> mixture alleviates the symptoms quickly. Elawamy et al (19) reported highly significant correlations between HD reduction percentage and VAS, ODI, and patient satisfaction evaluations after 6 months. The HD size reduction was more than 50%; this can be interpreted by the nucleolysis described by Zhang et al (20). They reported that the O<sub>2</sub>-O<sub>3</sub> mixture was sufficient to reduce disc size and alleviate pain. They also recommended use of the O<sub>2</sub>-O<sub>3</sub> mixture before a surgical intervention or when surgery was not possible.

In our study, patient satisfaction was very high due to the high success rate of ozone treatment of disc herniation in the cervical region. In addition, patients experienced improved functional ability and symptom relief with adequate decompression of the neural elements (Fig. 4). Patients unresponsive to conservative care were treated with intradiscal O<sub>2</sub>-O<sub>3</sub>, and 88.6% of patients were satisfied, 9.1% were moderately satisfied, and 2.3% were poorly satisfied. Only one patient (2.2%) considered their treatment a failure. The proposed therapeutic action of cervical intradiscal O<sub>2</sub>-O<sub>3</sub> mixture chemonucleolysis was explained by Alexandre et al (9), who examined a total of 252 patients treated in different centers. Pain symptomatology was eliminated completely in 79.3% of patients (200 patients), improved in 9.9% of patients (25 patients), and poor in 10.7% of patients (27 patients). A previous report by Li et al (2) showed 126 consecutive patients with contained CDHs treated by percutaneous cervical nucleoplasty. The rate of excellent and

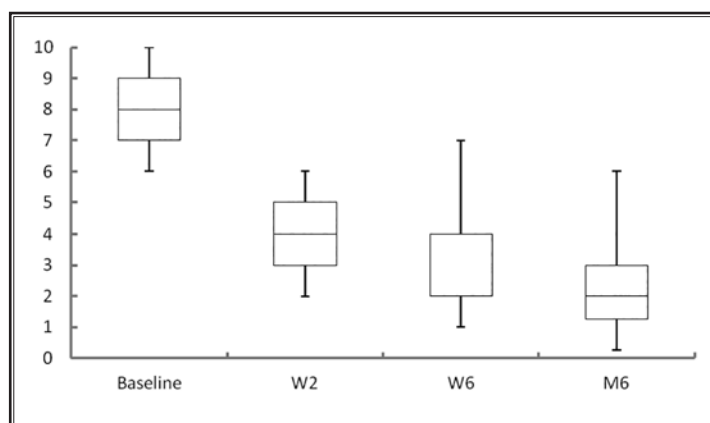


Fig. 2. Boxplot of the data from Oswestry Disability Index (ODI) scores recorded at baseline, 2 weeks (W2), 6 weeks (W6), and 6 months (M6) after intradiscal injection of ozone-oxygen. The index is expressed in percentage points and ranges from 0% to 100%. The lower limit corresponds to the absence of disability and the upper limit to the maximum degree of disability (patients are bed-bound). Before treatment, the distribution of ODI scores (median = 40%; 25th percentile = 34%; 75th percentile = 48%) were negatively skewed (skewness = -0.157), in the posttreatment survey after W2 (median = 21%; 25th percentile = 18%; 75th percentile = 28%) scores were positively skewed (skewness = 0.488), after W6 (median = 16%; 25th percentile = 12.5%; 75th percentile = 20.5%) scores were positively skewed (skewness = 0.725), and after M6 (median = 15%; 25th percentile = 10%; 75th percentile = 18%) scores were positively skewed (skewness = 0.458).

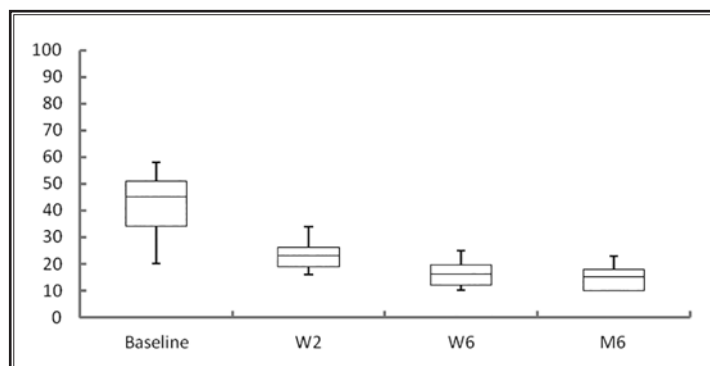


Fig. 3. Boxplot of the data of visual analog scale (VAS) scores recorded at baseline, W2, W6, and M6 after intradiscal injection of ozone-oxygen. At baseline, the VAS scores were mostly in the upper values of the scale (median = 8; 25th percentile = 7; 75th percentile = 9); therefore, this distribution was negatively skewed (skewness = -0.148). The distribution of the VAS scores in the post-treatment survey at W2 (median = 4; 25th percentile = 3; 75th percentile = 6) was skewed positively (skewness = 0.211), at W6 (median = 3; 25th percentile = 2; 75th percentile = 4) was skewed positively (skewness = 0.388), and at M6 (median = 2; 25th percentile = 1; 75th percentile = 3) was skewed positively (skewness = 0.456).

Table 2. Outcome scores of cervical O<sub>2</sub>-O<sub>3</sub> treatment.

	Baseline (Mean ± SD)	W2 (Mean ± SD)	W6 (Mean ± SD)	M6 (Mean ± SD)	P value
VAS	7.89 ± 1.13	4.22 ± 1.62	3.03 ± 1.66	2.27 ± 1.25	0.000
ODI	40.70 ± 10.40	23.14 ± 6.10	17.43 ± 5.59	14.48 ± 4.04	0.000

Abbreviations: O<sub>2</sub>-O<sub>3</sub>, oxygen-ozone treatment; W2, post-operative 2 weeks; W6, post-operative 6 weeks; M6, post-operative 6 months; Baseline, pre-operative; SD, standard deviation; VAS, visual analog scale; ODI, Oswestry Disability Index.

Table 3. Paired differences between preoperative and postoperative pain scores of cervical O<sub>2</sub>-O<sub>3</sub> treatment.

Time	VAS			ODI		
	Mean ± SD	T value	P value	Mean ± SD	T value	P value
Baseline-W2	3.68 ± 2.08	10.74	0.000	17.57 ± 6.10	9.04	0.000
Baseline-W6	4.87 ± 2.10	14.11	0.000	23.27 ± 5.59	12.12	0.000
Baseline-M6	5.77 ± 1.94	15.12	0.000	28.04 ± 4.04	12.04	0.000
W2-W6	1.19 ± 1.31	5.53	0.000	5.70 ± 5.59	6.21	0.000
W2-M6	1.73 ± 1.59	5.55	0.000	8.78 ± 5.34	7.88	0.000
W6-M6	0.65 ± 1.60	2.09	0.047	1.91 ± 3.33	2.76	0.012

Abbreviations O<sub>2</sub>-O<sub>3</sub>, oxygen-ozone treatment; W2, post-operative 2 weeks; W6, post-operative 6 weeks; M6, post-operative 6 months; Baseline, pre-operative; SD, standard deviation; VAS, visual analog scale; ODI, Oswestry Disability Index.

good outcomes was 83.7% (excellent in 62 cases, good in 41 cases) and fair in 23 cases. He et al (7) evaluated the therapeutic effectiveness of cervical intradiscal ozone treatment in 58 cases. They reported complete recovery in 33 (56.9%) out of 58 cases and significant symptom relief in 11 cases (19%) based on MacNab's criteria.

In LDH, Andreula et al (11) compared the success rates of O<sub>2</sub>-O<sub>3</sub> mixture therapy and periganglionic steroid injection at the lumbar level and reported a 70.3% success rate (211/300) in patients treated with O<sub>2</sub>-O<sub>3</sub> mixture therapy alone. In a series of 2,900 patients treated with O<sub>2</sub>-O<sub>3</sub> mixture therapy, Muto et al (12) reported 75% excellent or good satisfaction rates at long-term follow-up (12 months). In a previous study by Muto et al (12), 2,200 patients were treated with intradiscal and foraminal ozone injections and followed for 18 months. The effectiveness of ozone injection was highest in cases of single-level disc herniations (64% excellent and 14% good or fair) where maximum improvement was at 6 months and the results were stable to 18 months. Buric (13) et al treated 108 patients and performed 10-year follow-up through phone interviews for 86 patients after intradiscal ozone injection for LDH. Of the 86 patients that responded, 2 (2%) were "worse," 5 (6%) were "the same," 40 (47%) were "better," and 39 (45%) were "much better." A total of 92% of respondents reported that they did not have an episode of similar radiating pain after injection (13).

A significant decrease in pain and disability score was observed in our study, which continued up to 6 months follow-up after cervical intradiscal ozone injection. Higher ODI and greater VAS pain score improvements were measured for symptoms of CDH during the follow-up period (Table 2). The mean VAS score was 7.89 ± 1.13 before the procedure and a decrease of 73.1% was observed compared with baseline values at the final follow-up. The improvement in functional status of the patients was supported based on a 68.9% reduction in the ODI score. Ankur et al (17) evaluated 31 consecutive patients with lumbar disc herniation (LDH) for the efficacy of intradiscal O<sub>2</sub>-O<sub>3</sub> mixture therapy. Therapeutic outcome was assessed according to the VAS and ODI scores at a follow-up period of 1 year. Ozone resulted in a significant reduction in VAS and ODI scores compared with baseline values (VAS baseline was 72.7, ODI baseline was 45.5) at 2 weeks (63.2 for VAS and 36.5 for ODI), at 1 month (40.9 for VAS and 33.3 for ODI), at 3 months (42.6 for VAS and 28.8 for ODI), and at 6 months (35.8 for VAS and 25.2 for ODI). Muto et al (12) explored intradiscal O<sub>2</sub>-O<sub>3</sub> mixture injection, a minimally invasive percutaneous technique for the treatment of LDH. They evaluated pain relief on VAS scores at long-term follow-up for 12 months compared to baseline and observed a reduction of more than three points in 85% of patients. They also reported the significant therapeutic action of lumbar intradiscal O<sub>2</sub>-O<sub>3</sub> mixture chemonucleolysis

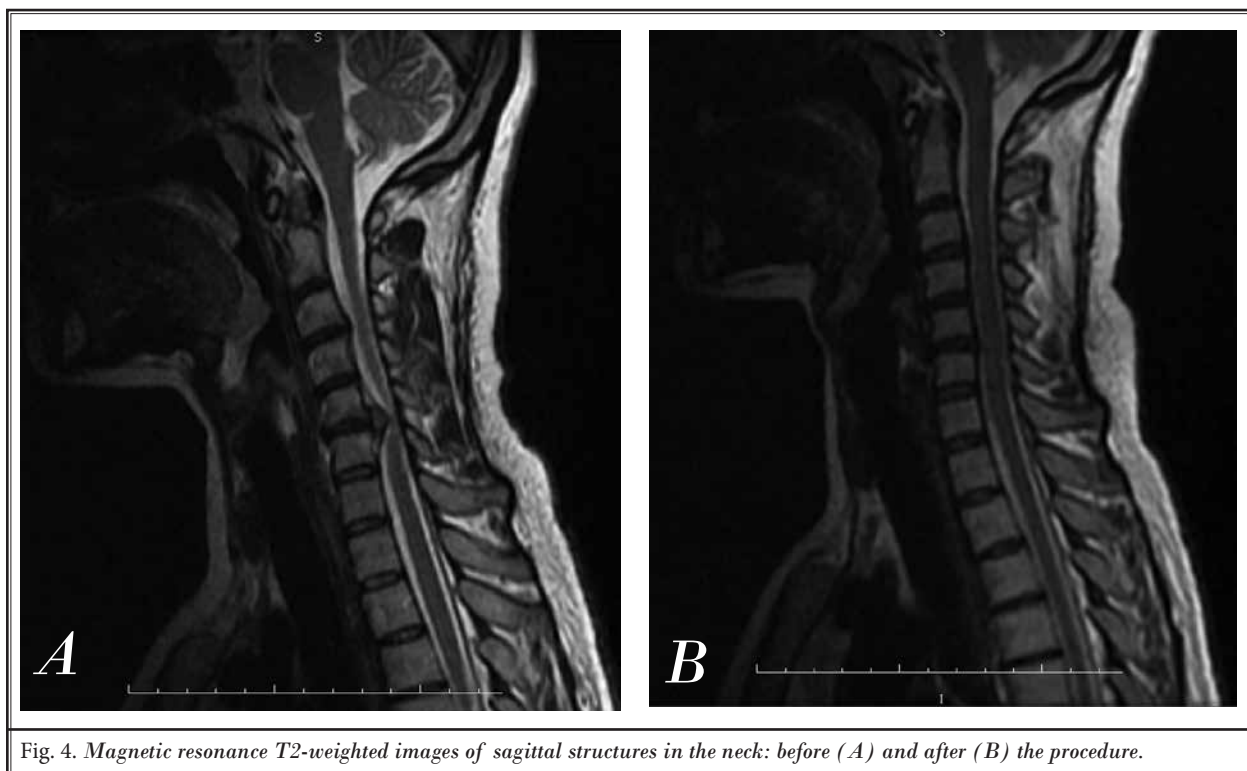


Fig. 4. Magnetic resonance T2-weighted images of sagittal structures in the neck: before (A) and after (B) the procedure.

with an approximately 30% reduction in ODI scores at long-term follow up.

There are several potential complications secondary to  $O_2-O_3$  mixture treatment, including infections, bleeding, nerve damage, worsened pain, failure of the technique, recurrence of herniation, spinal cord injury, carotid artery, jugular vein, and trachea damage (2,7,12). However, a majority of these studies did not evaluate complications. In this report, patients were carefully evaluated to identify any complications. There were no major complications observed associated with the procedure during and after the injection. Only one patient (2.2%) complained of hoarseness at 3 days post-surgery and was referred to a specialist. This symptom was likely due to irritation of the recurrent laryngeal nerve in the injection site and improved spontaneously over a period of 1 week. Some patients experienced minimal discomfort such as sore throat, dysphagia, neck stiffness, and a transient increase in pain at the injection site due to needle insertion, which resolved spontaneously on the day of procedure or within one day. This is a novel application of percutaneous intradiscal techniques for treating spine disorders at the cervical spine; however, complications have been reported. Cervical spondylodiscitis (18), pyogenic discitis, and

spinal epidural abscess (14) have been observed; these complications are rare but have a high morbidity if neurological and functional deficits occur.

Our study has several limitations. First, this study was observational, which limited our ability to obtain follow-up data. In addition, this study was performed using a small patient group. We believe that prospective, multidisciplinary studies with a larger series are required. In addition, it is important to have a control group to evaluate the effectiveness of treatment; the lack of a control group is another limitation of this study.

Our study has several strengths. First, a literature review was conducted on the outcome of cervical intradiscal ozone injections, and we found that primary outcome measures included pain relief (excellent, good, poor) and patient satisfaction (very satisfied, satisfied, or unsatisfied). These studies showed a significant difference between baseline and follow-up periods. However, none of these studies used the VAS score for pain and ODI scores for measuring pain intensity reduction as primary functional outcomes in the cervical region (excluding some studies in the lumbar region). In our study, the primary outcome measures included VAS and ODI scores, as well as patient satisfaction as a secondary outcome measure. Second, all interventional

procedures were performed in one center by the same physician. In addition, all post-procedure evaluations were conducted in person with the patient by a physician who did not take part in the work.

## CONCLUSION

The cervical segment is a high-risk area compared with other locations of the spinal cord. However, few reports have explored cervical O<sub>2</sub>-O<sub>3</sub> mixture therapy. This study shows the efficacy of intradiscal O<sub>2</sub>-O<sub>3</sub> mixture therapy for the treatment of CDH. A significantly higher efficacy after intradiscal injection of the O<sub>2</sub>-O<sub>3</sub> mixture was achieved, with beneficial effects in the cervical region. Based on our results, the intradiscal ozone

can be considered an alternative strategy to surgery in patients with CDH. However, limited studies have described the long-term results of intradiscal ozone injection therapy, and patients may receive additional treatments or spine surgery over time. Hence, longer-term (5 to 10 years) clinical outcomes following intradiscal ozone injection for CDH should be observed to evaluate success rates. In addition, it is important to compare the success rates of cervical intradiscal ozone injection to other intradiscal procedures. We suggest that well-designed, randomized control trials are required to confirm the long-term superiority of intradiscal O<sub>2</sub>-O<sub>3</sub> mixture injection compared with other percutaneous intradiscal procedures at the cervical level.

## REFERENCES

- Ellenberg MR, Honet JC, Treanor WJ. Cervical radiculopathy. *Arch Phys Med Rehabil* 1994; 75:342-352.
- Li J, Yan DL, Zhang ZH. Percutaneous cervical nucleoplasty in the treatment of cervical disc herniation. *Eur Spine J* 2008; 17:1664-1669.
- Stookey B. Compression of the spinal cord due to ventral extradural cervical chondromas. *Arch Neur Psych* 1928; 20:275-291.
- Mixter WJ, Barr JS. Rupture of the intervertebral disc with involvement of the spinal canal. *N Engl J Med* 1934; 211:210-215.
- Hijikata S. Percutaneous nucleotomy. A new concept technique and 12-year experience. *Clin Orthop Relat Res* 1989; 238:9-23.
- Ascher PW. Application of the laser in neurosurgery. *Lasers Surg Med* 1986; 2:91-97.
- He XF, Xiao YY, Li YH, Lu W, Chen Y, Chen HW, Pen J, Zeng QL, Zhao JB, Shen P, Xu XL. Percutaneous intradiscal O<sub>2</sub>-O<sub>3</sub> injection to treat cervical disc herniation. *Rivista di Neuroradiologia* 2005; 18:75-78.
- Smith L. Enzyme dissolution of the nucleus pulposus in humans. *JAMA* 1964; 18:137-140.
- Alexandre A, Corò L, Azuelos A, Buric J, Salgado H, Murga M, Marin F, Giocoli H. Intradiscal injection of oxygen-ozone gas mixture for the treatment of cervical disc herniations. In: Alexandre A, Bricolo A, Millesi H. (eds) *Advanced Peripheral Nerve Surgery and Minimal Invasive Spinal Surgery. Acta Neurochirurgica*, vol 97. Springer, Vienna 2005.
- Andreula C, Muto M, Leonardi M. Interventional spinal procedures. *Eur J Radiol* 2004; 50:112-119.
- Andreula CF, Simonetti L, De Santis F, Agati R, Ricci R, Leonardi M. Minimally invasive oxygen-ozone therapy for lumbar disk herniation. *AJNR Am J Neuroradiol* 2003; 24:996-1000.
- Muto M, Andreula C, Leonardi M. Treatment of herniated lumbar disc by intradiscal and intraforaminal oxygen-ozone (O<sub>2</sub>-O<sub>3</sub>) injection. *J Neuroradiol* 2004; 31:183-189.
- Buric J, Rigobello L, Hooper D. Five- and ten-year follow-up on intradiscal ozone injection for disc herniation. *Int J Spine Surg* 2014; 8:17.
- Bo W, Longyi C, Jian T, Guangfu H, Hailong F, Weidong L, Haibin T. A pyogenic discitis at C<sub>3</sub>-C<sub>4</sub> with associated ventral epidural abscess involving C<sub>1</sub>-C<sub>4</sub> after intradiscal oxygen-ozone chemonucleolysis: A case report. *Spine* 2009; 34:E298-E304.
- Magalhaes FN, Dotta L, Sasse A, Teixeira MJ, Fonoff ET. Ozone therapy as a treatment for low back pain secondary to herniated disc: A systematic review and meta-analysis of randomized controlled trials. *Pain Physician* 2012; 15:E115-E129.
- Gallucci M, Limbucci N, Zugaro L, Barile A, Stavroulis E, Ricci A, Galzio R, Masciocchi C. Sciatica. Treatment with intradiscal and intraforaminal injections of steroid and oxygen-ozone versus steroid only. *Radiology* 2007; 242:907-913.
- Cavanaugh JM, Ozaktay AC, Yamashita T, Avramov A, Getchell TV, King AI. Mechanisms of low back pain: A neurophysiologic and neuroanatomic study. *Clinical Orthopaedics and Related Research*. 1997; 335:166-180.
- Bocci V, Pogni R, Corradeschi F, Busi E, Cervelli C, Bocchi L, Basosi R. Oxygen-ozone in orthopaedics: EPR detection of hydroxyl free radicals in ozone-treated "nucleus pulposus" material. *Rivista di Neuroradiologia* 2001; 14:55-59.
- Elawamy A, Kamel EZ, Hassanien M, Wahba OM, Amin SE. Implication of two different doses of intradiscal ozone-oxygen injection upon the pain alleviation in patients with low back pain: A randomized, single-blind study. *Pain Physician* 2018; 21:E25-E31.
- Zhang Y, Ma Y, Jiang J, Ding T, Wang J. Treatment of the lumbar disc herniation with intradiscal and intraforaminal injection of oxygen-ozone. *J Back Musculoskeletal Rehabil* 2013; 26:317-322.
- Ankur J, Rastogi V, Sujeet G, Ganesh S. Comparative study of oxygen ozone therapy, percutaneous radiofrequency thermocoagulation and their combined effects for the treatment of lumbar disc herniation. *JARMS* 2014; 6:153-158.
- Andrés-Cano P, Vela T, Cano C, García G, Vera JC, Andrés-García JA. Cervical spondylodiscitis after oxygen-ozone therapy for treatment of a cervical disc herniation: A case report and review of the literature. *HSS J* 2016; 12:278-283.