

Prospective Study



Comparison of 3 Anesthetic Methods for Percutaneous Transforaminal Endoscopic Discectomy: A Prospective Study

Yanjie Zhu, MD, Yongzhao Zhao, MD, Guoxin Fan, MD, Shiyu Sun, MD, Zhi Zhou, MD, Dongdong Wang, MD, Yunshan Fan, MD, Shisheng He, MD, PhD, and Guangfei Gu, MD

From: Orthopedic Department,
Shanghai Tenth People's
Hospital, Tongji University
School of Medicine, Shanghai,
China

Address Correspondence:
Guangfei Gu, MD
Orthopedic Department,
Shanghai Tenth People's
Hospital, Tongji University
School of Medicine
301 Yanchang Rd
Shanghai 200072, China
E-mail: 13611757174@163.com

Disclaimer: There was no external funding in the preparation of this manuscript. Conflict of interest: Each author certifies that he or she, or a member of his or her immediate family, has no commercial association (i.e., consultancies, stock ownership, equity interest, patent/licensing arrangements, etc.) that might pose a conflict of interest in connection with the submitted manuscript.

Manuscript received: 06-10-2017
Revised manuscript received:
12-26-2017
Accepted for publication:
01-05-2018

Free full manuscript:
www.painphysicianjournal.com

Background: Percutaneous transforaminal endoscopic discectomy (PTED) under local anesthesia (LA) is growing popular in recent years because of its safety, effectiveness and increased patient demands for minimally invasive procedures. To avoid neural injuries, local anesthesia that can keep the patient conscious is recommended. However, many patients complain about the severe pain during surgery. Epidural anesthesia (EA) is an alternative choice. We put forward an anesthetic method that combined preemptive analgesia (PA) and local anesthesia.

Objectives: The study aimed to assess the effectiveness of 3 methods of anesthesia for PTED, LA, EA and PA.

Study Design: A prospective study.

Methods: Three groups of patients were treated with standard PTED under LA, PA or EA, respectively. The data collected for analysis were operative time, x-ray exposure time, postoperative bed time, visual analog scale (VAS), Oswestry Back Pain Disability Index (ODI), the global outcome based on the Macnab outcome criteria, satisfaction rate of anesthesia, and complications.

Results: A total of 240 consecutive patients were enrolled in this study from January 2014 to December 2016. Among 3 groups, 1-week postoperatively VAS (back and leg) and ODI were improved compared with preoperative data, and the excellent/good rates were all above 90%. However, satisfaction rate of anesthesia showed significant differences among the 3 groups. PA and EA showed significantly better performance in pain management intraoperatively and 1 hour postoperatively. The operation time of group PA was the shortest and group EA was the longest. No severe neural injuries occurred in any of the 3 groups. Transient paresis of lower limbs occurred in all 3 groups and showed no significant differences. Decreased muscle strength of lower limbs postoperatively occurred in 2 patients in group EA. The incidence of nausea and vomiting postoperatively was significantly higher in group PA (6 cases, 7.50%). There were 3 cases of dysuria postoperatively in group EA (3.75%).

Limitation: First, this is a single center study. Second, this study investigated the effects of anesthesia on perioperative period and the follow-up time was relatively short. Third, we choose morphine in group PA and there are other types of anesthetics which may be used in preemptive analgesia in further study.

Conclusion: All 3 of these anesthetic methods are safe to avoid neural injuries. EA and PA showed better performance in pain management but had more anesthesia-related complications.

Key words: Percutaneous transforaminal endoscopic discectomy (PTED), local anesthesia, epidural anesthesia, preemptive analgesia, morphine, ropivacaine, pain management, visual analog scale (VAS), Oswestry Back Pain Disability Index (ODI)

Pain Physician 2018; 21:E347-E353

Percutaneous transforaminal endoscopic discectomy (PTED) under local anesthesia has grown popular in recent years because of its advanced endoscopic visualization and increased patient demands for minimally invasive procedures (1-3). Several randomized controlled studies have confirmed that it is a safe and effective procedure for soft disc herniation (4-8). Moreover, highly experienced surgeons have expanded the indications for PTED and have reported successful results even in cases with migrated disc herniation, foraminal/extraforaminal disc herniation, and disc herniation with spinal stenosis (3,9-13). Compared to open surgeries, PTED has the advantages of smaller incision, shorter operation time, lower estimated intraoperative blood loss, and fewer complications (2,6-8).

For PTED, as a percutaneous surgery with a steep learning curve, local anesthesia (LA) is recommended for avoiding nerve injury (8,14,15). LA can keep patients conscious during surgery. Thus, the surgeon can get feedback from patients when interfering with the nerve during surgery. However, through clinical observation, we found that some patients couldn't tolerate the pain during surgery, especially during the process of working channel insertion, foraminoplasty, and herniation discectomy. Besides, there was a reported study that neural irritation by insertion of instruments during PTED may cause severe pain, because of which the procedure may have to be stopped (8). Therefore, local anesthesia for PTED is still controversial. Epidural anesthesia (EA) is another major method which can keep patients awake during surgery. Through a reasonable choice of narcotic drugs and the control of sensory level, EA can prevent the pain but maintain the function of motor of lower limbs which is called sensory-motor separation. Preemptive analgesia is a new pain management concept that has been developed on the basis of the pathophysiology of acute pain (16). We put forward an anesthetic method that combined preemptive analgesia and local anesthesia (PA). Before surgery, we inject morphine 10mg intramuscularly to the patient and local anesthesia is performed intraoperatively. However, to our best knowledge, there is no study comparing the efficiency of these three anesthetic methods. Thus, we conducted a prospective study to assess the effectiveness of these 3 anesthetic methods.

METHODS

General Information

This study was approved by the Ethics Committee

of Shanghai Tenth People's Hospital. We enrolled 240 consecutive patients from January 1, 2014 to December 31, 2016. All patients were provided with consent forms, and the enrollment of patients is shown in Fig. 1. Each group included 80 patients who underwent PTED under LA, PA or EA, respectively.

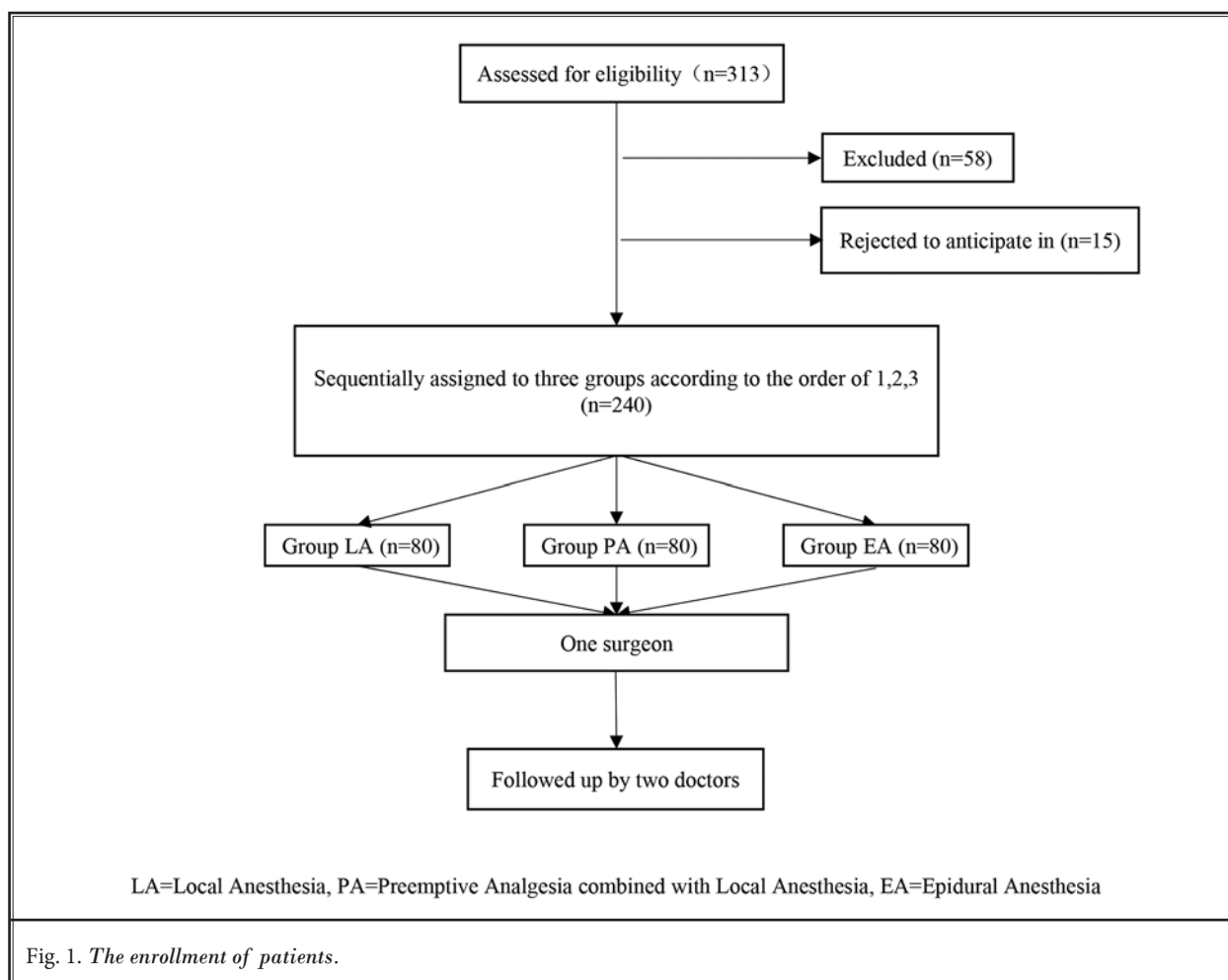
The inclusion criteria were: 1) clinical evidence of soft disc herniation in a single segment; 2) intractable radicular symptoms such as sciatica, a positive straight-leg raising test, sensory and/or motor disturbances; 3) corroborative clinical and radiological findings; 4) more than 6 weeks of conservative treatment that failed to improve intractable leg pain, and functional impairments; 5) definite lumbar herniation with major weakness indicating urgent need for surgical decompression. The exclusion criteria were: 1) spinal malformations (congenital and external acquired) including scoliosis, lumbar sacralization, sacral lumbarization; 2) recurrent LDH; 3) multi segmental LDH; 4) accompanied by a wide range of lumbar spinal canal stenosis, cauda equina syndrome, and segmental instability including spondylolisthesis; 5) highly migrated type of LDH.

Surgical Procedure

In group LA, we infiltrated the skin with 1% lidocaine in 2-3 mL first and then an 18-gauge needle was introduced to anesthetize the trajectory with 8-10 mL lidocaine 1%. When the superior articular process was reached, 2-3 mL lidocaine 1% was used to anesthetize the facet joint. Lidocaine would be added intraoperatively if necessary. In group PA, morphine 10 mg was injected intramuscular half an hour before the surgery and then local anesthesia was the same as group LA. In group EA, the operation was performed by an experienced anesthesiologist according to the standard epidural anesthetic technique. The insertion point was 2 segments above the surgical segment. A total of 1% lidocaine 3 mL was applied initially and if the leg could move 5 minutes later, it indicated that the lidocaine was not in the subarachnoid space. The second time 0.25% ropivacaine was added to adjust the sensory level and achieve the aim of sensory-motor separation. The following operations were performed by one experienced surgeon according to the standard percutaneous transforaminal endoscopic spine system (TESSYS) (5).

Clinical Evaluation

The data collected for analysis were: operative time, x-ray exposure time, postoperative bed time, visual analog scale (VAS), Oswestry Back Pain Dis-



ability Index (ODI), the global outcome based on the Macnab outcome criteria, satisfaction rate of anesthesia, and complications. Operating time included the procedures of anesthesia and surgeries. Back and leg pain was quantified by VAS collected from the patients preoperatively, intraoperatively, 1 hour postoperatively and 1 week postoperatively. The ODI, version 2.0, was used to evaluate how the patient’s leg (or back) condition has affected his/her daily life preoperatively and 1 week postoperatively. The global outcome was assessed as excellent, good, fair, or poor based on the Macnab outcome criteria 1 week postoperatively. A favorable outcome was defined as excellent or good. Satisfaction rate of anesthesia was collected 1 hour postoperatively.

Statistical Assessments

The software of SPSS 21.0 (SPSS, USA) was used

Table 1. *Baseline characteristics of included patients among 3 groups.*

Demographic	Group LA	Group PA	Group EA	P
Gender				
Male	47	44	46	0.887
Female	33	36	34	
Mean age (yrs)	42 ± 16.32	41 ± 17.31	43 ± 20.42	0.554
Mean BMI (kg/m ²)	23.61 ± 6.22	22.56 ± 8.25	22.66 ± 7.46	0.089
Level of disk herniation				0.975
L2-3	2	1	1	
L3-4	15	16	13	
L4-5	29	32	33	
L5-S1	34	31	33	

BMI=body mass index, LA=local anesthesia, PA=preemptive analgesia combined with local anesthesia, EA=epidural anesthesia

Comparison of 3 Anesthetic Methods of PTED

Table 3. Comparison of patient-reported outcomes among 3 groups.

	Group LA	Group PA	Group EA	P
VAS of back pain				
Preoperative	2.64 ± 1.55	2.70 ± 1.25	2.83 ± 1.59	0.714
Intraoperative	7.86 ± 0.59	5.19 ± 0.55	3.62 ± 0.55	< 0.001*
		(‡P < 0.001)	(‡P < 0.001, ∫P < 0.001)	
Postoperative (1 hour)	3.80 ± 0.25	2.54 ± 0.25	1.87 ± 0.22	< 0.001*
		(‡P < 0.001)	(‡P < 0.001, ∫P < 0.001)	
Postoperative (1 week)	1.47 ± 0.27	0.99 ± 0.22	1.01 ± 0.22	< 0.001*
		(‡P < 0.001)	(‡P < 0.001)	
VAS of leg pain				
Preoperative	7.27 ± 1.69	7.46 ± 1.52	7.31 ± 1.41	0.09
Intraoperative	6.87 ± 0.51	5.94 ± 0.48	2.47 ± 0.51	< 0.001*
		(‡P < 0.001)	(‡P < 0.001, ∫P < 0.001)	
Postoperative (1 hour)	3.15 ± 0.36	1.93 ± 0.41	1.23 ± 0.30	< 0.001*
		(‡P < 0.001)	(‡P < 0.001, ∫P < 0.001)	
Postoperative (1 week)	3.06 ± 0.73	2.49 ± 0.80	2.02 ± 0.76	< 0.001*
		(‡P < 0.001)	(‡P < 0.001, ∫P < 0.001)	
ODI				
Preoperative	60.53 ± 5.68	61.62 ± 5.87	62.40 ± 5.51	0.116
Postoperative (1 week)	17.77 ± 8.57	17.26 ± 9.47	14.77 ± 8.61	0.08

Compared with LA, ‡P < 0.05; Compared with PA, ∫P < 0.05; Comparison among three groups, *P < 0.05; LA=local anesthesia, PA=preemptive analgesia combined with local anesthesia, EA=epidural anesthesia; VAS, visual analog scale; ODI, Oswestry Back Pain Disability Index

with group EA while 1 week postoperative showed no significant difference. The intraoperative, 1 hour postoperative and 1 week postoperative, VAS-LP showed significant differences among the 3 groups; group EA was the lowest while group LA was the highest. One week postoperative ODI showed no significant differences among these three groups ($P = 0.08$). All these details are illustrated in Table 3.

Complications

Four cases of transient paresis of lower limbs occurred in group EA, while 2 cases of transient paresis occurred in group LA and 1 case in group PA. Decreased muscle strength of lower limbs postoperatively occurred in 2 patients in group EA. The incidence of nausea and vomiting postoperatively was significantly higher in group PA (6 cases, 7.50%). There were 3 cases of dysuria postoperatively in group EA (3.75%).

Discussion

Our results confirmed that PA and EA more effectively manage the intraoperative pain but the anesthesia-related complication rates were higher than LA comparatively.

Effective and efficient pain management strategies have the potential to improve medical outcomes, enhance patient satisfaction, and reduce costs (17). Thus, pain management is important for PTED. LA has the advantage of being a simpler procedure with less anesthesia-related complications. However, the effectiveness of LA to manage intraoperative pain is poor. Low concentrations of epidural ropivacaine could prevent pain effectively during surgery but maintain the motor function of lower limbs thus the surgeon can still get feedback from the patient. However, compared to LA, the EA procedure is more complicated and prolongs operation time and postoperative bed time. Besides, EA increases the risk of anesthesia-related complications like urinary retention.

Opioid medicines are the most commonly used analgesics in history (18). Before the surgery, we injected morphine 10 mg intramuscularly to the patient. Compared to local anesthesia, PA was more effective in preventing the intraoperative pain while not being as complicated as EA. However, morphine has side-effects, which must be accounted for.

Intraoperative back pain in PETD occurs mainly

from the insertion of the working channel, especially for foraminoplasty, which is needed for reaching the ideal location because of the high iliac crest, large facet joint, and disc space inclination (19). Intraoperative leg pain occurs mainly from the stimulation of the nerve either in the process of working channel insertion or decompression of herniation especially for huge herniations. For those patients with huge herniations, the working channel may increase the compression of the herniation to the nerve. Most patients who were dissatisfied with the surgery under local anesthesia complained about pain during the surgery, which indicated that the effectiveness of local anesthesia has been limited. The management of leg pain was poor in group LA and group PA as the sensory function of the nerve remains during the procedure. However, leg pain of group PA was still lower than group LA mainly thanks to the preoperative morphine. EA showed a satisfactory pain management because of the sensory-motor separation. One-hour postoperative VAS-BP and VAS-LP of group PA and group EA showed significant differences with group LA. Most patients were satisfied with the surgeries 1 week postoperatively as the excellence/good rate of the 3 groups were all above 90%. However, the satisfaction rate of anesthesia showed significant differences among 3 groups with group LA being the lowest.

The operation time and x-ray exposure time were closely related to the cooperation of patients. The management of intraoperative pain was the major factor as the process would stop when the patients could not endure the pain. Although x-ray exposure time showed no significant differences among three groups, we still found in surgeries that the better intraoperative pain was prevented, the less x-ray exposure time. The damage of radiation exposure induced by repeated fluoroscopy cannot be ignored during surgeries. The International Commission on Radiological Protection (ICRP) has recommended radiation limits per year for professionals, specialized body tissues and organs (20). The operation time in group EA was the longest as it took about twenty minutes for these procedures. Also, the postoperative bed time of group EA was the longest because 6 hours' bed rest in the horizontal position is recommended for patients following EA.

It's necessary to keep patients conscious during PTED surgery to minimize nerve root injuries, especially for inexperienced surgeons. That's the reason why general anesthesia is not recommended for PTED. When the nerve root was irritated, patients in group LA and

group PA could inform the surgeons in time. Because the lower limbs' motor function of patients in group EA could be preserved by low concentration ropivacaine, surgeons could detect the nerve injury by observing the movement of the patients' toes. Except for 7 cases of transient paresis, no severe neural injuries occurred in any of the patients included in our study. The transient paresis might be caused by the irritation of nerve root during the removal of herniated disc tissue. Considering that the symptoms alleviated within 6 hours, an excessive dose of ropivacaine might be responsible for the 2 cases of postoperative decreased muscle strength of lower limbs in group EA. The higher rate of complications like nausea and vomiting in group PA, which are common side effects of opioid drugs, could be explained by the utilization of morphine. As for the 3 cases of dysuria in group EA, it's a common side effect of EA that normally disappears in hours.

In addition, respiratory depression and hypotension are side effects of morphine which need to be considered even though they didn't occur in this study, especially for the elderly. In the case of EA, an experienced anesthesiologist is recommended to avoid spinal cord damage/cauda equina damage and for control sensory-motor separation. As for LA, too much lidocaine on the facet joint can easily anesthetize the nerve root thus losing direct nerve root feedback from the patient and increasing the risk of nerve injuries. For this reason, a proper choice of anesthesia for PTED tailored to the patient is important.

Our study had several limitations. First, this is a single center study. Second, this study investigated the effects of anesthesia on the perioperative period and the follow-up time was short. Third, we choose morphine in group PA and there are other types of anesthetics which may be used in PA in future studies.

CONCLUSION

For PETD, all these 3 anesthetic methods (LA, EA, and PA) can get a good clinical results. PA and EA showed a significantly better performance in intraoperative pain management than LA. However, the side-effects of morphine and epidural anesthesia should be considered carefully.

Author Contributions

Dr. Gu had full access to all the data in the study and takes responsibility for the integrity of data and the accuracy of the data analysis. Dr. He, Dr. Zhu, and Dr. Sun designed the study protocol. Dr. Zhu managed

the literature searches and summaries of previous related work and wrote the first draft of the manuscript. Dr. Zhou and Dr. Wang collected the data. Dr. Zhao

performed the data analysis. Dr. Fan provided revision for intellectual content and final approval of the manuscript.

REFERENCES

- Pan Z, Ha Y, Yi S, Cao K. Efficacy of transforaminal endoscopic spine system (TESSYS) technique in treating lumbar disc herniation. *Med Sci Monit* 2016; 22:530-539.
- Gotecha S, Ranade D, Patil SV, Chugh A, Kotecha M, Sharma S, Punia P. The role of transforaminal percutaneous endoscopic discectomy in lumbar disc herniations. *J Craniovertebr Junction Spine* 2016; 7:217-223.
- Ahn Y. Percutaneous endoscopic decompression for lumbar spinal stenosis. *Expert Rev Med Devices* 2014; 11:605-616.
- Gadjradj PS, van Tulder MW, Dirven CM, Peul WC, Harhangi BS. Clinical outcomes after percutaneous transforaminal endoscopic discectomy for lumbar disc herniation: A prospective case series. *Neurosurg Focus* 2016; 40:E3.
- Sairyo K, Egawa H, Matsuura T, Takahashi M, Higashino K, Sakai T, Suzue N, Hamada D, Goto T, Takata Y, Nishisho T, Goda Y, Sato R, Tsutsui T, Tonogai I, Kondo K, Tezuka F, Mineta K, Sugiura K, Takeuchi M, Dezawa A. State of the art: Transforaminal approach for percutaneous endoscopic lumbar discectomy under local anesthesia. *J Med Invest* 2014; 61:217-225.
- Gadjradj PS, Harhangi BS. Percutaneous transforaminal endoscopic discectomy for lumbar disk herniation. *Clin Spine Surg* 2016; 29:368-371.
- Nie H, Zeng J, Song Y, Chen G, Wang X, Li Z, Jiang H, Kong Q. Percutaneous endoscopic lumbar discectomy for L5-S1 disc herniation via an interlaminar approach versus a transforaminal approach: A prospective randomized controlled study with 2-year follow up. *Spine (Phila Pa 1976)* 2016; 41 Suppl 19:B30-b37.
- Ahn Y. Transforaminal percutaneous endoscopic lumbar discectomy: technical tips to prevent complications. *Expert Rev Med Devices* 2012; 9:361-366.
- Lee S, Kim SK, Lee SH, Kim WJ, Choi WC, Choi G, Shin SW. Percutaneous endoscopic lumbar discectomy for migrated disc herniation: Classification of disc migration and surgical approaches. *Eur Spine J* 2007; 16:431-437.
- Lubbers T, Abuamona R, Elsharkawy AE. Percutaneous endoscopic treatment of foraminal and extraforaminal disc herniation at the L5-S1 level. *Acta Neurochir (Wien)* 2012; 154:1789-1795.
- Liu C, Chu L, Yong HC, Chen L, Deng ZL. Percutaneous endoscopic lumbar discectomy for highly migrated lumbar disc herniation. *Pain Physician* 2017; 20:E75-E84.
- Wu X, Fan G, Guan X, Zhu Y, Huang L, He S, Gu X. Percutaneous endoscopic lumbar discectomy for far-migrated disc herniation through two working channels. *Pain Physician* 2016; 19:E675-E680.
- Zheng C, Wu F, Cai L. Transforaminal percutaneous endoscopic discectomy in the treatment of far-lateral lumbar disc herniations in children. *Int Orthop* 2016; 40:1099-1102.
- Ahn SS, Kim SH, Kim DW, Lee BH. Comparison of outcomes of percutaneous endoscopic lumbar discectomy and open lumbar microdiscectomy for young adults: A retrospective matched cohort study. *World Neurosurg* 2016; 86:250-258.
- Ahn SS, Kim SH, Kim DW. Learning curve of percutaneous endoscopic lumbar discectomy based on the period (early vs. late) and technique (in-and-out vs. in-and-out-and-in): A retrospective comparative study. *J Korean Neurosurg Soc* 2015; 58:539-546.
- Kim SI, Ha KY, Oh IS. Preemptive multimodal analgesia for postoperative pain management after lumbar fusion surgery: A randomized controlled trial. *Eur Spine J* 2016; 25:1614-1619.
- Tedore T, Weinberg R, Witkin L, Giambrone GP, Faggiani SL, Fleischut PM. Acute pain management/regional anesthesia. *Anesthesiol Clin* 2015; 33:739-751.
- Chu LF, Angst MS, Clark D. Opioid-induced hyperalgesia in humans: molecular mechanisms and clinical considerations. *Clin J Pain* 2008; 24:479-496.
- Choi KC, Park CK. Percutaneous endoscopic lumbar discectomy for L5-S1 disc herniation: Consideration of the relation between the iliac crest and L5-S1 disc. *Pain Physician* 2016; 19:E301-E308.
- Ahn Y, Kim CH, Lee JH, Lee SH, Kim JS. Radiation exposure to the surgeon during percutaneous endoscopic lumbar discectomy: A prospective study. *Spine (Phila Pa 1976)* 2013; 38:617-625.

